VOLUME 108 (5) — MAY 1999

Cuk- H03724-48-P024703

— Founded in 1892 —

ANNALS

OF OTOLOGY, RHINOLOGY & LARYNGOLOGY

Official Organ of the
AMERICAN LARYNGOLOGICAL ASSOCIATION
AMERICAN BRONCHO-ESOPHAGOLOGICAL ASSOCIATI

48

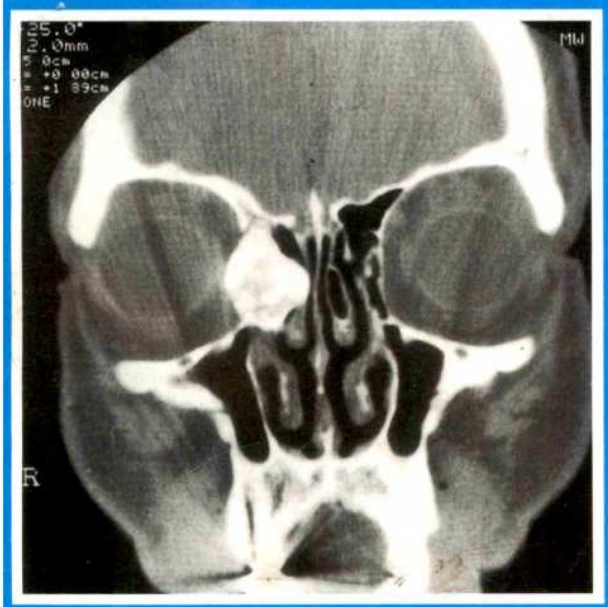

MAKE YOUR DIAGNOSIS. SEE PAGE 523.

ANNALS PUBLISHING CO

WEB SITE—http://www.Annals.com

IMPROVE EAR PROTECTOR EFFECTIVENESS

The majority of Otolaryngologists and Hearing Health Care Professionals in the U.S. believe that patients who wear ear protection, especially custom-molded protectors or preformed rubber ear plugs, should also wear a tight-fitting cap or band for extra protection when swimming or showering.

- PHYSICIANS' CHOICE Head Band improves patient compliance – the stylish PHYSICIANS' CHOICE Head Band is happily worn by boys and girls. The Velcro™ closure allows easy adjustments for a comfortable fit.
- The PHYSICIANS' CHOICE Head Band stays positioned over the ears to help keep water out, and ear protectors in.

PHYSICIANS' CHOICE™ Head Band

You and your patients will appreciate PHYSICIANS' CHOICE Head Band. For more information and to receive a Free PHYSICIANS' CHOICE Head Band sample contact us by phone, mail or fax.

Santa Barbara Medco, Inc.

Our New Website:
www.sbmedco.com
E-mail:
sbmedco@silcom.com

P.O. Box 6843 • Santa Barbara • CA 93160 • FAX 805/683-4864 • PHONE 805/683-1486

ANNALS OF OTOLOGY, RHINOLOGY & LARYNGOLOGY

— Founded in 1892 —

Editor

BRIAN F. McCABE, MD
Iowa City, Iowa

Associate Editors

CHARLES D. BLUESTONE, MD
Pittsburgh, Pa

GEORGE A. GATES, MD
Seattle, Wash

LAWRENCE W. DeSANTO, MD
Scottsdale, Ariz

LEE A. HARKER, MD
Omaha, Neb

Board of Editors

JOHN G. BATSAKIS, MD ..... Kalkaska, Mich
JOEL M. BERNSTEIN, MD, PhD ..... Buffalo, NY
ANDREW BLITZER, MD, DDS ..... New York, NY
DERALD E. BRACKMANN, MD ..... Los Angeles, Calif
POUL BRETLAU, MD, DMSc ..... Copenhagen, Denmark
ITZHAK BROOK, MD ..... Washington, DC
RICHARD A. BUCKINGHAM, MD ..... Park Ridge, Ill
RICHARD A. CHOLE, MD, PhD ..... St. Louis, Mo
JACK D. CLEMIS, MD ..... Chicago, Ill
CHARLES W. CUMMINGS, MD ..... Baltimore, Md
PATRICK J. DOYLE, MD ..... Vancouver, Canada
ALFIO FERLITO, MD ..... Udine, Italy
UGO FISCH, MD ..... Zurich, Switzerland
BRUCE GANTZ, MD ..... Iowa City, Iowa
JEFFREY P. HARRIS, MD, PhD ..... San Diego, Calif
GERALD B. HEALY, MD ..... Boston, Mass
WILLIAM F. HOUSE, MD ..... Los Angeles, Calif
STEVEN K. JUHN, MD ..... Minneapolis, Minn
TIMOTHY T. K. JUNG, MD, PhD ..... Loma Linda, Calif
DAVID W. KENNEDY, MD ..... Philadelphia, Pa
FRANK E. LUCENTE, MD ..... New York, NY
WILLIAM L. MEYERHOFF, MD, PhD ..... Dallas, Tex
JOSEF MILLER, PhD ..... Ann Arbor, Mich
AAGE R. MØLLER, PhD ..... Dallas, Tex
WILLIAM W. MONTGOMERY, MD ..... Boston, Mass
EUGENE N. MYERS, MD ..... Pittsburgh, Pa
JOSEPH B. NADOL, Jr, MD ..... Boston, Mass
YASUYA NOMURA, MD ..... Tokyo, Japan
LORNE S. PARNES, MD ..... London, Canada
FRANK N. RITTER, MD ..... Ann Arbor, Mich
ROBERT J. RUBEN, MD ..... Bronx, NY
JAI H. RYU, PhD ..... Winston-Salem, NC
JACOB SADÉ, MD ..... Tel Aviv, Israel
ISAMU SANDO, MD ..... Pittsburgh, Pa
CLARENCE T. SASAKI, MD ..... New Haven, Conn
RICHARD J. H. SMITH, MD ..... Iowa City, Iowa
HEINZ R. STAMMBERGER, MD ..... Graz, Austria
LESTER D. R. THOMPSON, MD ..... Washington, DC
DEAN M. TORIUMI, MD ..... Chicago, Ill
JAN E. VELDMAN, MD, PhD ..... Utrecht, The Netherlands
BRUCE M. WENIG, MD ..... Bronx, NY
T. J. YOO, MD, PhD ..... Memphis, Tenn

Software Review and Computer Applications Editor

KEVIN T. KAVANAGH, MS, MD ..... Somerset, Ky

Imaging Editor

YUTAKA SATO, MD ..... Iowa City, Iowa

Book Review Editor

DENNIS G. PAPPAS, MD ..... Birmingham, Ala

Emeritus Board Members

WESLEY H. BRADLEY, MD ..... Albany, NY
SEYMOUR COHEN, MD ..... Los Angeles, Calif
ARNDT J. DUVALL III, MD ..... Minneapolis, Minn
JOHN M. FREDRICKSON, MD ..... St Louis, Mo
RICHARD R. GACEK, MD ..... Syracuse, NY
JEROME C. GOLDSTEIN, MD ..... Alexandria, Va
SIR DONALD F. N. HARRISON, MD PhD ..... London, England
SAM E. KINNEY, MD ..... Cleveland, Ohio
JOHN A. KIRCHNER, MD ..... New Haven, Conn
DAVID J. LIM, MD ..... Los Angeles, Calif
FRED H. LINTHICUM, Jr, MD ..... Los Angeles, Calif
MICHEL PORTMANN, MD ..... Bordeaux, France
LORING W. PRATT, MD ..... Waterville, Me
WILLIAM H. SAUNDERS, MD ..... Columbus, Ohio
RUEDIGER THALMANN, MD ..... St Louis, Mo
HARVEY M. TUCKER, MD ..... Cleveland, Ohio
PAUL H. WARD, MD ..... Los Angeles, Calif

P24703

ANNALS OF OTOLOGY, RHINOLOGY & LARYNGOLOGY

— Founded in 1892 —

EDITOR'S OFFICE

Brian F. McCabe, MD
Department of Otolaryngology – Head & Neck Surgery
University Hospitals & Clinics
Iowa City, IA 52242
(319) 356-2310

BUSINESS OFFICE

Annals Publishing Company
4507 Laclede Avenue
St Louis, MO 63108
(314) 367-4987
Fax (314) 367-4988
E-mail: manager@Annals.com

STAFF

Managing Editor
Michol L. Sheridan

Business Manager
Kenneth A. Cooper, Jr

Chief Copyeditor
Edna Hayes Harrison

Copyeditor
Kirsten K. Novak

Circulation Manager
Michelle M. Steuerwald

Editorial Assistant
Timothy I. Watt

ADVERTISING REPRESENTATIVES

— East & Midwest —
Cunningham Associates
180 Old Tappan Rd
Old Tappan, NJ 07675
(201) 767-4170
Fax (201) 767-8065

— West —
Charles B. Healy
PO Box 5213
Palm Springs, CA 92263
(760) 320-0118
Fax (760) 325-5473

EDITORIAL CONTENT

The *ANNALS* publishes original manuscripts of clinical and research importance in otolaryngology – head and neck medicine and surgery, bronchoesophagology, head and neck oncology and surgery, plastic and reconstructive surgery, pediatric otolaryngology, audiology, speech pathology, and related specialties. In-depth studies (supplements), papers of historical interest, computer software reviews and applications in otolaryngology are also published, as well as imaging, pathology, and clinicopathology studies, book reviews, and letters to the editor. All papers and supplements are peer-reviewed. The *ANNALS* is the official journal of the American Laryngological Association and the American Broncho-Esophagological Association.

SUBSCRIPTIONS

1999 Annual Subscription Rates	*USA*	*International Surface Mail (All Regions)*
Institution*	$179.00	$204.00
Individual†	125.00	150.00
Resident/Student†	82.00	98.00

*Institutional (multiple-reader) subscription rates apply to public and private libraries, hospitals, and clinics; city, county, state, provincial, and national government bureaus and departments; and commercial and private institutions and organizations.

†Individual, resident, and student subscriptions must be in the individual's name and must be billed to and paid for by the individual.

Airmail rates are available upon request.

CLAIMS

Claims for missing issues must be received within 60 days of the month of publication for the United States and Canada, and 180 days for other countries. Single copy prices will be charged on missing issues claimed after that date.

BACK ISSUES

A comprehensive inventory of back issues and supplements is available. Prices are furnished on request.

CHANGE OF ADDRESS

Address changes must be received 45 days prior to the effective date so that the subscription will be received without interruption.

MICROFILM

The *ANNALS* is available in microform from University Microfilms International, 300 North Zeeb Road, Ann Arbor, MI 48106.

ANNALS OF OTOLOGY, RHINOLOGY & LARYNGOLOGY (ISSN 0003-4894) is published monthly by Annals Publishing Company, 4507 Laclede Avenue, St Louis, MO 63108. Periodicals postage paid at St Louis, Mo. POSTMASTER: Send address changes to *ANNALS OF OTOLOGY, RHINOLOGY & LARYNGOLOGY* , c/o Annals Publishing Company, 4507 Laclede Avenue, St Louis, MO 63108-2103.

Printed on acid-free paper

COPYRIGHT© 1999, ANNALS PUBLISHING COMPANY

ANNALS OF OTOLOGY, RHINOLOGY & LARYNGOLOGY

VOLUME 108 **MAY 1999** **NUMBER 5**

CONTENTS

OTOLOGY AND AUDIOLOGY

Therapy of Idiopathic Sudden Sensorineural Hearing Loss: Antiviral Treatment of Experimental Herpes Simplex Virus Infection of the Inner Ear
Robert J. Stokroos, MD, PhD; Frans W. J. Albers, MD, PhD; Jurjen Schirm, PhD 423

Outcome of Brain Stem Auditory Electrophysiology in Children Who Survive Purulent Meningitis
Ze D. Jiang, MD, PhD 429

Clinical Presentation and Management of Labyrinthine Fistula Caused by Chronic Otitis Media
Nicolas Y. Busaba, MD 435

Antibiotics in Chronic Suppurative Otitis Media: A Bacteriologic Study
R. Indudharan, MS(ENT), DipNB(ORL); J. Ashraful Haq, MPhil, PhD; Subramania Aiyar, PhD 440

Twenty-Four–Hour Oscillations of Facial Electroneurography Parameters and Their Relationship to Body Temperature
Adrian Paz, MD; Yehuda Kronenberg, MD; Israel Ashkenazi, PhD 446

Effect of Platelet Activating Factor and Its Antagonist on the Mucociliary Clearance of the Eustachian Tube in Guinea Pigs
Chung-Ku Rhee, MD, PhD; Pil-Seob Jeong, MD, PhD; Young-Hoon Kim, MD; Phil-Sang Chung, MD, PhD; Timothy T. K. Jung, MD, PhD 453

RHINOLOGY AND AIRWAY

Prospective Application of a Protocol for Selective Nonsurgical Management of Suspected Orbital Subperiosteal Abscesses in Children
Ali Sajjadian, MD; Usha Chundru, MD; Glenn Isaacson, MD 459

Sinusitis With Contiguous Abscess Involvement of the Clivus and Petrous Apices. Case Report
Dick L. Hoistad, MD; Arndt J. Duvall III, MD 463

Comparative Role of Peptide Leukotrienes and Histamine in the Development of Nasal Mucosal Swelling in Nasal Allergy
Tsutomu Numata, MD; Akiyoshi Konno, MD; Takayuki Yamakoshi, MD; Toyoyuki Hanazawa, MD; Nobuhisa Terada, MD; Hiroshi Nagata, MD 467

Delayed Irradiation Effects on Nasal Epithelium in Patients With Nasopharyngeal Carcinoma. An Ultrastructural Study
Pei-Jen Lou, MD; Wen Pin Chen, PhD; Chung Chieh Tai, MD 474

Flow Cytometric Analysis of BHRF1 Expression Prohibiting Apoptosis Induced by Radiation
Hai Huang, MD, PhD; Xinghua Pan, MD, PhD; Shuimiao Zhou, MD; Zhaoji Li, MD; Long Yu, MD, PhD; Xiantao Kong, MD, PhD; Qiping Zheng, PhD 481

LARYNGOLOGY AND HEAD AND NECK

Glandular Carcinoma of the Larynx: The UCLA Experience
Sassan Alavi, MD; Ali Namazie, MD; Thomas C. Calcaterra, MD; Keith E. Blackwell, MD 485

Carbon Dioxide Laser Debulking for Obstructing Endolaryngeal Carcinoma: A 10-Year Experience
Ollivier Laccourreye, MD; Georges Lawson, MD; Luca Muscatello, MD; Bernard Biacabe, MD; Laurent Laccourreye, MD; Daniel Brasnu, MD 490

Extramedullary Solitary Plasmacytoma of the Head and Neck. A Clinicopathological Study
Michel-André Hotz, MD; Guy Schwaab, MD; Jacques Bosq, MD; Jean-Nicolas Munck, MD 495

Substernal Goiter: Clinical Experience of 72 Cases
José M. Rodriguez, MD; Quiteria Hernandez, MD; Antonio Piñero, MD; Sergio Ortiz, MD; Teresa Soria, MD; Pablo Ramirez, MD; Pascual Parrilla, MD 501

Thoracic Duct Cyst: A Case Report and Review of 29 Cases
Petri S. Mattila, MD, PhD; Jussi Tarkkanen, MD, PhD; Severi Mattila, MD, PhD 505

Postnatal Development of Myosin Heavy Chain Isoforms in Rat Laryngeal Muscles
Akihiro Shiotani, MD; Richard M. Jones, MD; Paul W. Flint, MD 509

Cervical Anatomy of Phrenic Nerve Roots in the Rabbit
Jean-Paul Marie, MD; Yannick Lerosey, MD; Danièle Dehesdin, MD; Marc Tadié, MD, PhD; Jérome Andrieu-Guitrancourt, MD 516

IMAGING CASE STUDY OF THE MONTH

Frontoethmoid Osteoma
Richard H. Vowles, FRCS (ORL-HNS); Nigel R. Bleach, FRCS (Otol) 522

MISCELLANEOUS

Information for Subscribers 2a

Index to Advertisers 9a

ANNALS OF OTOLOGY, RHINOLOGY & LARYNGOLOGY

VOLUME 108 JUNE 1999 NUMBER 6

CONTENTS

OTOLOGY AND AUDIOLOGY

Auditory Screening in Neonates by Means of Transient Evoked Otoacoustic Emissions: A Report of 2,842 Recordings
Didier Aidan, MD; Paul Avan, MD, PhD; Pierre Bonfils, MD, PhD 525

Percutaneous Implants in the Temporal Bone for Securing a Bone Conductor: Surgical Methods and Results
Catharina T. M. van der Pouw, MD, PhD; Emmanuel A. M. Mylanus, MD, PhD; Cor W. R. J. Cremers, MD, PhD 532

Electron Microscopic Temporal Bone Histopathology in Experimental Pneumococcal Meningitis
Jamie M. Rappaport, MD, FRCS(C); Samir M. Bhatt, MD; Robert S. Kimura, MD; Arthur M. Lauretano, MD; Robert A. Levine, MD 537

Relationship of the Utriculus and Sacculus to the Stapes Footplate: Anatomic Implications for Sound- and/or Pressure-Induced Otolith Activation
Douglas D. Backous, MD; Lloyd B. Minor, MD; Edward S. Aboujaoude, MD; George T. Nager, MD 548

Efficacy of an Antiallergic Drug on Otitis Media With Effusion in Association With Allergic Rhinitis. An Experimental Study
Masashi Suzuki, MD; Hideomi Kerakawauchi, MD; Hideyuki Kawauchi, MD; Goro Mogi, MD 554

Course of IL-1β, IL-6, IL-8, and TNF-α in the Middle Ear Fluid of the Guinea Pig Otitis Media Model Induced by Nonviable *Haemophilus influenzae*
Katsuro Sato, MD; Masahiro Kawana, MD; Naobumi Nonomura, MD; Yuichi Nakano, MD 559

Lipid Peroxides in Middle Ear Fluid After Acute Otitis Media in Guinea Pigs
Thomas G. Takoudes, MD; Joseph Haddad Jr, MD 564

RHINOLOGY AND AIRWAY

Treatment of Hypertrophy of the Inferior Turbinate: Long-Term Results in 382 Patients Randomly Assigned to Therapy
Desiderio Passàli, MD; Maria Lauriello, MD; Marco Anselmi, MD; Luisa Bellussi, MD 569

Abnormal Expression of the Cystic Fibrosis Transmembrane Regulator in Chronic Sinusitis in Cystic Fibrosis and Non–Cystic Fibrosis Patients
Marc D. Coltrera, MD; Susan M. Mathison, MD; Tracy A. Goodpaster; Allen M. Gown, MD 576

Effect of Diesel Exhaust on Guinea Pig Nasal Mucosa
Kiyoshi Hiruma, MD; Nobuhisa Terada, MD; Toyoyuki Hanazawa, MD; Minoru Nomoto, MD; Ken-ichi Maesako, PhD; Akiyoshi Konno, MD; Takahiro Kobayashi, PhD 582

Congenital Nasal Hemangiopericytoma: Intrauterine, Intraoperative, and Histologic Findings
Karl Götte, MD; Karl Hörmann, MD; Jürgen Schmoll, MD; Wolf-Dieter Hiltmann, MD 589

Distribution of RANTES and Interleukin-5 in Allergic Nasal Mucosa and Nasal Polyps
Chul Hee Lee, MD; Kang Soo Lee, MD; Chae-Seo Rhee, MD; Sung Ok Lee, MSc; Yang-Gi Min, MD 594

LARYNGOLOGY AND HEAD AND NECK

Graft Healing in Laryngotracheal Reconstruction: An Experimental Rabbit Model
Ian N. Jacobs, MD; Pierre Podrebarac, MD; Scott D. Boden, MD; Michael Chen, MD 599

Swallowing Disorders in Paralysis of the Lower Cranial Nerves: A Functional Analysis
Sophie Périé, MD; Laurent Coiffier, MD; Laurent Laccourreye, MD; Vincent Hazebroucq, MD; Stanislas Chaussade, MD; Jean Lacau St Guily, MD 606

Laryngeal Long Latency Response Conditioning in Abductor Spasmodic Dysphonia
Frederic W.-B. Deleyiannis, MD, PhD; Michael Gillespie; Steven Bielamowicz, MD; Toshiyuki Yamashita, MD, ScD; Christy L. Ludlow, PhD 612

IMAGING CASE STUDIES OF THE MONTH

High Jugular Bulb Adhering to the Eardrum
Takehisa Sato, MD; Koutetsu Lee, MD; Hitoshi Saito, MD 620

Detection of Unknown Primary Cancer With Fluor-Deoxy-Glucose Positron Emission Tomography
Markus Jungehülsing, MD; Klemens Scheidhauer, MD; Uwe Pietrzyk, PhD; Hans Eckel, MD; Harald Schicha, MD 623

MISCELLANEOUS

Book Reviews 627

Information for Subscribers 2a

Index to Advertisers 8a

ANNALS OF OTOLOGY, RHINOLOGY & LARYNGOLOGY

VOLUME 108 **JULY 1999** **NUMBER 7**

CONTENTS

PART 1

OTOLOGY AND AUDIOLOGY

Documentation of the Prevalence of Penicillin-Resistant *Streptococcus pneumoniae* Isolated From the Middle Ear and Sinus Fluid of Children Undergoing Tympanocentesis or Sinus Lavage
Nina L. Shapiro, MD; Seth M. Pransky, MD; Michelle Hartin, MT, SM; John S. Bradley, MD 629

Ability of Nucleus Cochlear Implantees to Recognize Music
Shuji Fujita, MD; Juichi Ito, MD, PhD 634

Objective Evaluation of Normal Facial Function
Henning Scriba, PhD; Sandro J. Stoeckli, MD; Dorothe Veraguth, MD; Anita Pollak, MD; Ugo Fisch, MD 641

Resistance to Antimicrobials Used for Therapy of Otitis Media and Sinusitis: Effect of Previous Antimicrobial Therapy and Smoking
Itzhak Brook, MD, MSc; Alan E. Gober, MD 645

Expression of Intercellular Adhesion Molecule–1 in Rat Inner Ear Due to Bacterial Otitis Media
Michihiko Sone, MD; Henry Q. Russlie; Daniel M. Canafax, PharmD; Michael M. Paparella, MD 648

Spontaneous Cerebrospinal Fluid Otorrhea From a Tegmen Defect: Transmastoid Repair With Minicraniotomy
Rudolf Kuhweide, MD; Jan W. Casselman, MD, PhD 653

Intracochlear Schwannoma and Cochlear Implantation
Jona Kronenberg, MD; Zeev Horowitz, MD; Minka Hildesheimer, PhD 659

Do Cochlear Nuclei Contribute to Auditory Lateralization? A Stereological Evaluation of Neuron Numbers
Erdal Ağar, PhD; Adnan Korkmaz, PhD; Mehmet Bosnak, MSc; Serif Demir, MSc; Mustafa Ayyildiz, PhD; Cafer Marangoz, PhD 661

LARYNGOLOGY AND HEAD AND NECK ONCOLOGY

Results of Partial Laryngectomy for Benign Neural Tumors of the Larynx in Children
Eréa-Noël Garabédian, MD; Vincent Ducroz, MD; Denis Ayache, MD; Jean Michel Triglia, MD 666

Extracapsular Spread and Desmoplastic Pattern in Neck Lymph Nodes: Two Prognostic Factors of Laryngeal Cancer
Maria P. Prim, MD; Juan I. De Diego, MD; David Hardisson, MD; Rosario Madero, MD; Manuel Nistal, MD; Javier Gavilán, MD 672

Leiomyosarcoma of the Larynx. Review of the Literature and Report of Two Cases
Róbert Paczona, MD; József Jóri, MD, PhD; László Tiszlavicz, MD, PhD; Jenö Czigner, MD, PhD, DSc 677

Comparison of Perinatal and Adult Multi-Innervation in Human Laryngeal Muscle Fibers
Sophie Périé, MD; Jean Lacau St Guily, MD; Alain Sebille, MD 683

Comparison of Nerve Banking Techniques in Delayed Laryngeal Reinnervation
K. Linnea Peterson, MD; Robert J. Andrews, MD; Joel A. Sercarz, MD; Kevin Kevorkian, MD; Ming Ye, MD; Keith E. Blackwell, MD; Gerald S. Berke, MD 689

TRACHEA, ESOPHAGUS, AND ENDOSCOPY

Pediatric Tracheostomy: A Changing Procedure?
Ralph F. Wetmore, MD; Roger R. Marsh, PhD; Mary E. Thompson, RN, BSN; Lawrence W. C. Tom, MD 695

Fluorescence-Guided Biopsy in the Diagnosis of an Unknown Primary Cancer in Patients With Metastatic Cervical Lymph Nodes
Boonchu Kulapaditharom, MD; Vipa Boonkitticharoen, PhD; Somyos Kunachak, MD 700

Cautery-Assisted Palatal Stiffening Operation and Nasalance of Speech
CPT Evanne M. Hoolsema, BSC, USAF 705

Computed Tomography Diagnosis of Esophageal Bone Impaction: A Prospective Study
Ron Eliashar, MD; Itzhak Dano, MD; Eric Dangoor, MB, MRCGP; Itzhak Braverman, MD; Jean-Yves Sichel, MD 708

IMAGING CASE STUDY OF THE MONTH

Rare Cause of Blindness in a Patient With Acquired Immunodeficiency Syndrome
Michael A. Cook, DO; Orlando L. Manfredi, MD; David Masini; Jesse J. Lopez, Jr, DO 711

MISCELLANEOUS

Information for Subscribers 4a

Index to Advertisers 9a

PART 2

Neurotransmitters and Neuromodulators Involved in Laryngeal Innervation
Yasuo Hisa, MD; Shinobu Koike, MD; Nobuhisa Tadaki, MD; Hitoshi Bamba, MD; Kazuhiro Shogaki, MD; Toshiyuki Uno, MD

Brain Stem Neural Mechanisms for Vocalization in Decerebrate Cats
Satoshi Nonaka, MD; Akihiro Katada, MD; Takashi Sakamoto, MD; Tokuji Unno, MD ..... Supplement 178

ANNALS OF OTOLOGY, RHINOLOGY & LARYNGOLOGY

VOLUME 108 **AUGUST 1999** **NUMBER 8**

CONTENTS

FROM THE AMERICAN BRONCHO-ESOPHAGOLOGICAL ASSOCIATION

Analysis of the Forces and Position Required for Direct Laryngoscopic Exposure of the Anterior Vocal Folds
Ilan I. Hochman, MD; Steven M. Zeitels, MD; James T. Heaton, PhD 715

Laryngopharyngeal Sensory Discrimination Testing and the Laryngeal Adductor Reflex
Jonathan E. Aviv, MD; John H. Martin, PhD; Ted Kim, MD; Ralph L. Sacco, MD, MS; Jeanne E. Thomson, MS; Beverly Diamond, PhD; Lanny G. Close, MD 725

Severe Pharyngeal Stenosis Treated With Inferiorly Based Sternocleidomastoid Myocutaneous Flap
Jeffrey R. Haller, MD; Steven D. Gray, MD 731

Prevention of Airway Complications in Thyroplasty Patients Requiring Endotracheal Intubation
Paul Friedlander, MD; Erdine Aygene, MD; Dennis H. Kraus, MD 735

Fat Implantation Into Reinke's Space: A Histologic and Stroboscopic Study in the Canine
Peak Woo, MD; Reza Rahbar, MD, DMD; Zhi Wang, MD 738

OTOLOGY

Inner Ear Damage in TORP-Operated Ears: Experimental Study on Danger From Environmental Air Pressure Changes
Hans Wilhelm Pau, MD 745

Mastoid Buffering Properties: I. Gas Partial Pressures
Eyal Raveh, MD; Jacob Sadé, MD; Haya Mover-Lev, PhD; Selcuk Guney, MD 750

Inflammatory Response to Chronic Otitis Media in DiGeorge Syndrome: A Case Study Using Immunohistochemistry on Archival Temporal Bone Sections
Tetsuya Ganbo, MD, DMSc; Isamu Sando, MD, DMSc; Carey D. Balaban, PhD; Chiaki Suzuki, MD, DMSc; Miwa Kitagawa, MD 756

Mucin Gene Expression in the Rat Middle Ear: An Improved Method for RNA Harvest
Jizhen Lin, MD; Samuel Ho, MD; Laurie Shekels, PhD; Michael M. Paparella, MD; Youngki Kim, MD 762

Immunohistochemical Distribution of Extracellular Matrix Components and Keratin in Experimentally Induced Otitis Media
Teruhiko Harada, MD; Steven K. Juhn, MD; Youngki Kim, MD; Yasuo Sakakura, MD 769

LARYNGOLOGY AND ONCOLOGY

Ankle-Arm Index as a Screening Examination for Fibula Free Tissue Transfer
Neal D. Futran, MD, DMD; Brendan C. Stack, Jr, MD; Ajay P. Zachariah 777

Nitric Oxide Synthase Type 3 Is Increased in Squamous Hyperplasia, Dysplasia, and Squamous Cell Carcinoma of the Head and Neck
Brandon G. Bentz, MD; G. Kenneth Haines III, MD; Mark W. Lingen, DDS, PhD; Harold J. Pelzer, DDS, MD; David G. Hanson, MD; James A. Radosevich, PhD 781

Correcting Vocal Fold Immobility by Autologous Collagen Injection for Voice Rehabilitation. A Short-Term Study
Marc Remacle, MD, PhD; Georges Lawson, MD; Monique Delos, MD; Jacques Jamart, MD 788

Leiomyosarcoma of the Larynx. Case Report
Shawn Thomas, MS; Howard S. McGuff, DDS; Randal A. Otto, MD 794

RHINOLOGY

Quantitative Glycohistochemical Characterization of Normal Nasal Mucosa, and of Single as Opposed to Massive Nasal Polyps
Sergio Hassid, MD, PhD; Georges Choufani, MD; Nathalie Nagy, MD; Herbert Kaltner, VMD; Andre Danguy, PhD; Hans-Joachim Gabius, PhD; Robert Kiss, PhD 797

ESOPHAGOLOGY

Esophageal Contractility Synchronous With Expiration
Mitsuhiro Mohri, MD; Naoki Ohtsuki, MD; Mutsuo Amatsu, MD 806

Endoscopic Diverticulotomy for the Treatment of Zenker's Diverticulum: Results in 102 Patients With Staple-Assisted Endoscopy
Surendra Narne, MD; Cesare Cutrone, MD; Luigi Bonavina, MD; Barbara Chella, MD; Alberto Peracchia, MD 810

IMAGING CASE STUDY OF THE MONTH

High-Resolution Magnetic Resonance Imaging of Recurrent Pneumoparotitis
Christian Sittel, MD; Markus Jungehülsing, MD; Roman Fischbach, MD 816

MISCELLANEOUS

Information for Subscribers 2a

Instructions to Authors 7a

Index to Advertisers ..... cover 3

THERAPY OF IDIOPATHIC SUDDEN SENSORINEURAL HEARING LOSS: ANTIVIRAL TREATMENT OF EXPERIMENTAL HERPES SIMPLEX VIRUS INFECTION OF THE INNER EAR

ROBERT J. STOKROOS, MD, PHD
MAASTRICHT, THE NETHERLANDS

FRANS W. J. ALBERS, MD, PHD
GRONINGEN, THE NETHERLANDS

JURJEN SCHIRM, PHD
GRONINGEN, THE NETHERLANDS

Experimental herpes simplex virus type 1 (HSV-1) labyrinthitis provides a model of idiopathic sudden sensorineural hearing loss (ISSHL). Corticosteroids improve the prognosis for hearing recovery in ISSHL, but the effects of acyclovir are unknown. To establish the therapeutic efficacy of acyclovir (Zovirax) and prednisolone in experimental HSV-1 viral labyrinthitis, we induced HSV-1 labyrinthitis in 12 guinea pigs. Three animals received no treatment, 3 received prednisolone, 3 received acyclovir, and 3 received both. Four other animals served as controls, receiving culture medium only. Hearing, HSV-1 antibody titers, and cochlear damage were evaluated. The HSV-1 labyrinthitis caused hearing loss within 24 hours. Combination treatment consisting of prednisolone and acyclovir resulted in earlier hearing recovery and less extensive cochlear destruction compared to prednisolone or acyclovir as a monotherapy. The beneficial effect of this treatment modality remains to be demonstrated in ISSHL.

KEY WORDS — acyclovir, herpes simplex virus, idiopathic sudden sensorineural hearing loss, prednisolone.

INTRODUCTION

Therapy of idiopathic sudden sensorineural hearing loss (ISSHL) is a subject of controversy. The high spontaneous recovery rate of ISSHL (45% to 60%)[1,2] and the low incidence of ISSHL (8 to 13.8 per 100,000) in the Netherlands and Flanders[3] make validation of empirical treatment modalities difficult, and its unknown pathophysiology impedes a rational approach. Earlier therapeutic efforts were aimed at restoring a supposed impaired cochlear circulation, but treatment results did not exceed placebo results.[4] Early application of corticosteroids has a modest beneficial effect on hearing recovery in ISSHL, but its interference with cochlear pathophysiology in ISSHL remains unclear.[5,6]

In the literature, an important role of viral cochlear labyrinthitis in the pathogenesis of ISSHL is assumed, on the basis of clinical and serologic evidence and of a strong resemblance of cochlear histopathology found in experimental labyrinthitis to postmortem temporal bone histopathology in ISSHL patients.[7-9] We have developed an animal model of ISSHL in which herpes simplex virus type 1 (HSV-1) elicits sudden sensorineural hearing loss in the guinea pig inner ear (unpublished observations). In treatment of other manifestations of herpetic infections, the combination of corticosteroids and acyclovir seems to possess a synergistic therapeutic effect.[10] In this study an animal experiment was performed to evaluate the influence of steroids and acyclovir (Zovirax), either as a monotherapy or as a combination therapy, on cochlear function and cochlear histopathology in experimental HSV-1 labyrinthitis. The results may contribute to a more substantive approach to the treatment of ISSHL.

MATERIAL AND METHODS

McIntyre strain HSV-1 was grown in monolayers of human embryonic lung fibroblasts, using culture medium consisting of minimal essential medium and Hanks' salts supplemented with fetal calf serum. When the fibroblasts showed an extensive cytopathic effect, the culture supernatant was cleared by centrifugation at 2,000 rpm for 10 minutes. This cleared supernatant, which contained 8×10^4 U of the median tissue culture infective dose per milliliter, was used for infecting the guinea pigs.

Sixteen healthy male albino guinea pigs (weight 400 to 500 g) with a positive Preyer's reflex received general halothane anesthesia. Via a retroauricular in-

From the Department of Otorhinolaryngology, University Hospital Groningen (Stokroos, Albers), and the Regional Public Health Laboratory (Schirm), Groningen, the Netherlands. This study was done with financial support from the Fokkens-Kerkhoff stichting. This study was also supported by the Heinsius Houbolt Foundation and is part of the research program of our department, Communication Through Hearing and Speech, which is incorporated in the Sensory Systems Group of the Groningen Graduate School for Behavioral and Cognitive Neuroscience (BCN).

CORRESPONDENCE — Robert J. Stokroos, MD, PhD, Dept of Otorhinolaryngology, University Hospital Maastricht, PO Box 5800, 6202 AZ Maastricht, the Netherlands.

TABLE 1. EFFECT OF THERAPEUTIC REGIMENS ON PREYER'S REFLEX IN EXPERIMENTAL HSV-1 VIRAL LABYRINTHITIS

Guinea Pig No.	*Day 1*	*Day 2*	*Day 3*	*Day 4*	*Day 5*	*Day 6*	*Day 7*
HSV-1, untreated							
1	−	−	−	−	±	−	−
2	−	−	−	−	−	−	−
3	−	−	−	−	−	−	−
HSV-1, prednisolone							
4	−	−	−	−	−	−	+
5	−	−	−	−	−	±	+
6	−	−	−	−	−	±	+
HSV-1, acyclovir							
7	−	−	−	−	−	−	−
8	−	−	−	−	−	−	−
9	−	−	−	−	±	−	−
HSV-1, prednisolone-acyclovir							
10	−	−	−	±	+	+	+
11	−	−	+	±	±	+	+
12	−	−	+	+	+	+	+

HSV-1 — herpes simplex virus type 1; − — reflex absent; ± — reflex dubiously present; + — reflex present.

cision, the tympanic bulla of the left ear was exposed and opened. A beveled glass pipette (World Precision Instruments) with a tip measuring 50 μm in diameter was introduced through the round window membrane into the perilymphatic space by means of a micromanipulator (World Precision Instruments). Via a microdosage system (Mitutoya), 2 mL of the HSV-1 suspension was injected in 2 minutes into the perilymphatic space.

Four groups were formed: 3 animals were inoculated with the virus suspension and remained untreated, 3 animals were inoculated with the virus suspension and were treated with prednisolone, 3 animals were inoculated with the virus suspension and were treated with acyclovir (Zovirax, Glaxo Wellcome), and 3 animals were inoculated with the virus suspension and treated with both acyclovir and prednisolone. Treatment began on the day of inoculation. An additional group of 4 animals received the culture medium only. Prednisolone was administered in a dosage of 1 mg/kg, intraperitoneally, once per day for 7 days; acyclovir was administered in a dosage of 10 mg/kg, intraperitoneally, 3 times per day for 7 days. Each day, auditory function was monitored via Preyer's reflex. In a quiet room, a click stimulus of 90 to 95 dB sound pressure level was applied 1 cm lateral to the pinna of the inoculated ear. The contralateral ear was shielded from the stimulus. Only a clearly seen pinna twitch was accepted as a positive response. Three stimuli were given and the reflex was judged positive if at least 2 of the 3 stimuli were able to elicit a pinna twitch, and inconclusive if only 1 pinna twitch was observed (Table 1). Blood samples were obtained both prior to inoculation and just before sacrifice, and herpes simplex virus (HSV) antibody titers were determined in both samples in the following 2 different ways. Complement-fixing HSV antibodies were measured by a modification of the Laboratory Branch complement fixation micromethod,[11] which can also be applied on sera from guinea pigs.[12] The HSV-specific immunoglobulin G (IgG) titers were determined by indirect immunofluorescence on acetone-fixed HSV-infected cells, by means of fluorescein isothiocyanate–labeled goat anti–guinea pig IgG reagent (Southern Biotechnology Associates, Inc). On day 7, all animals were painlessly sacrificed. Primary fixation took place by intralabyrinthine perfusion with 2.5% glutaraldehyde in a 0.08-mol/L sodium cacodylate buffer (pH 7.4). After dissection of the cochlea, immersion fixation with the same fixative was carried out over a period of 3 hours. Decalcification took place in 10% ethylenediaminetetraacetic acid-2Na (pH 7.4). Postfixation was performed with 1% osmium-ruthenium and 1.5% 4-potassium ruthenium 6-cyanide followed by dehydration in graded alcohol. After embedding, midmodiolar sections of the cochlea were stained with toluidine blue and evaluated by light microscopy (Olympus OM2) and judged by a panel of 4 independent observers experienced in the evaluation of inner ear disease. In each animal, morphological and structural damage was assessed for different cochlear structures. If only minute morphological alterations had occurred, damage was categorized as slight. If morphological changes were more severe, but cochlear structures could still be recognized, damage was categorized as moderate. If morphological changes were profound to the extent that cochlear structures could no

TABLE 2. STRUCTURAL CHANGES OF COCHLEA IN EXPERIMENTAL HSV-1 LABYRINTHITIS AND ITS TREATMENT

	HSV-1			*HSV-1, Prednisolone*			*HSV-1, Acyclovir*			*HSV-1, Prednisolone-Acyclovir*		
	1	*2*	*3*	*4*	*5*	*6*	*7*	*8*	*9*	*10*	*11*	*12*
Scala vestibuli	++	++	+++	+	++	++	+++	+++	++	++	+	+
Scala tympani	+	+	+	0	+	+	+	+	+	+	0	0
Scala media	0	0	0	0	+	0	+	0	0	0	0	0
Reissner's membrane	0	0	+	0	0	+	+	0	0	0	0	0
Stria vascularis	++	+++	++	0	+	+	++	+++	++	+	0	0
Supporting cells	+++	+++	++	+	++	++	+++	+++	+++	+	0	0
Outer hair cells	+++	+++	+++	++	++	+++	+++	+++	+++	++	+	+
Inner hair cells	+++	+++	+++	+++	+++	+++	+++	+++	+++	++	++	++
Tectorial membrane	++	+++	+++	++	+++	+++	+++	+++	+++	+	+	+
Nerve fibers	++	+	++	0	+	+	++	+	+	0	0	0
Spiral ganglion cells	++	+	+	0	+	++	++	+	+	0	0	0

Numbers in heading are guinea pig numbers.

+++ — destroyed; ++ — damaged; + — slightly damaged; 0 — normal.

longer be recognized, the structures were considered to be destroyed (Table 2).

RESULTS

Observation of Auditory Function. Preyer's reflex, suggesting the presence of hearing, was positive before inoculation with HSV-1 in all animals (Table 1). Hearing loss occurred in the affected ear within 24 hours in all animals inoculated with HSV-1. The animals inoculated with the culture medium showed no sign of hearing loss.

In the untreated group, hearing did not recover. In the prednisolone-treated group, hearing had recovered by day 7. In the acyclovir-treated group, hearing did not recover. In the acyclovir-prednisolone–treated group, hearing recovery occurred after 3 to 5 days.

Serologic Evaluation. No systemic symptoms of viral infection were observed in any of the animals. However, HSV IgG seroconversions were demonstrated in all HSV-inoculated animals and in none of the control animals. The HSV IgG titers in the second serum samples of the infected animals, as measured by immunofluorescence, varied between 10 and ≥80 (median titer 20). No HSV antibodies were found when the less-sensitive complement fixation test was used.

Light Microscopic Evaluation. In all animals inoculated with the culture medium and in all contralateral ears of the HSV-inoculated animals, the perilymphatic spaces showed no sign of bleeding or fibrosis (Table 2). Reissner's membrane was intact. The stria vascularis showed its normal architecture. The supporting cells were normal, and the outer and inner hair cells were intact. The tectorial membrane was in its normal position, and the tunnel of Corti had its normal shape. Cochlear neural fibers and spiral ganglion cells were not affected.

In animals inoculated with HSV-1 (see Figure, A), we found some blood cells lying peripherally in the scala vestibuli. In the scala tympani, these cells were surrounded by a loose peripheral network of fibrosis. In the scala media, no bleeding or fibrosis was observed. Reissner's membrane was intact and in its normal position. The stria vascularis showed a disturbed architecture: the intermediate cell layer showed dilated blood vessels that were filled with erythrocytes. The stria vascularis was swollen with the presence of increased intercellular spaces in the intermediate cell layer. An inflammatory infiltration was present in the stria vascularis and in the spiral ligament. Supporting cells were flattened or destroyed. Outer and inner hair cells were completely shriveled. The tunnel of Corti was not recognizable. The tectorial membrane was elevated from the organ of Corti and in some cases lying loose in the scala media, but its shape remained unchanged. Both nerve fibers and ganglion cells showed some inflammatory infiltration. Distribution of cochlear damage and severity of cochlear damage were comparable in all HSV-1–inoculated, untreated animals.

In the animals treated with prednisolone after inoculation (see Figure, B), some bleeding was present in the apical portion of the scala vestibuli. This bleeding was more profound in the acyclovir-treated group (see Figure, C) and much less in the acyclovir-prednisolone–treated group (see Figure, D). In the prednisolone-treated group, the scala tympani showed a loose peripheral network of fibrosis lying peripher-

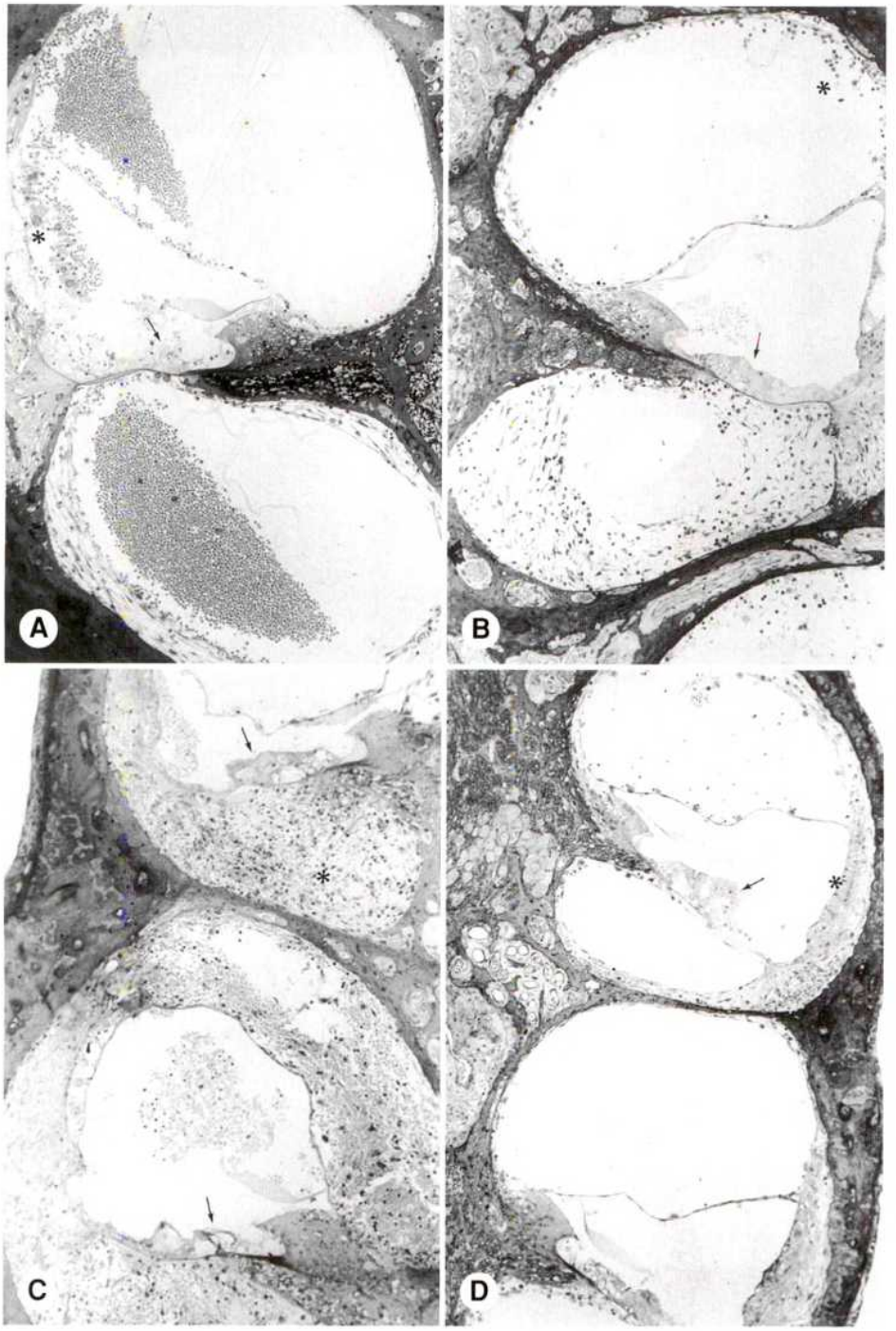

Light microscopy of midmodiolar sections of guinea pig cochleas showing experimental herpes simplex virus type 1 labyrinthitis (original ×100). A) Untreated. There is extensive destruction of organ of Corti and supporting cells (arrow). Stria vascularis shows severe morphological degeneration (asterisk). B) After treatment with prednisolone. There is diminished destruction of organ of Corti and supporting cells (arrow) and less bleeding in scala vestibuli (asterisk) compared to untreated animals. C) After treatment with acyclovir. There is severe destruction of organ of Corti and supporting cells (arrows) and considerable bleeding in scala vestibuli and scala tympani (asterisk). D) After treatment with prednisolone and acyclovir. Organ of Corti and supporting cells are much less affected (arrow) compared to untreated animals and animals receiving monotherapy. Stria vascularis has almost normal architecture (asterisk).

ally in the basal coils of the cochlea. This fibrosis was slightly more dense and accompanied by bleeding in the acyclovir-treated group. In the acyclovir-prednisolone–treated group, a very mild fibrosis lying peripherally in the basal coils was found. Reissner's membrane remained intact in all 3 groups, but appeared slightly thickened in some animals. The stria vascularis showed dilated blood vessels and inflammatory cells in the animals treated with prednisolone and, to a more pronounced degree, in the animals treated with acyclovir. When both prednisolone and acyclovir were applied, pathological changes were almost totally absent. The supporting cells were flattened and damaged in the animals receiving prednisolone. This finding was more pronounced in the animals receiving acyclovir as a monotherapy, and considerably less in the apical coils of the animals receiving both treatment modalities.

Outer hair cell damage was severe in the prednisolone-treated group, profound in the acyclovir-treated group, and less severe in the prednisolone-

acyclovir–treated group, in which the apical windings of the cochlea were unaffected. Inner hair cells were completely destroyed in both groups receiving monotherapy, and were damaged in the basal coils in the group receiving combination treatment. The tectorial membrane was elevated in both groups receiving monotherapy, but remained attached to the cochlea in the animals receiving the combination therapy.

A mild inflammatory reaction existed in nerve fibers and spiral ganglion cells of the animals receiving prednisolone monotherapy, this reaction being greater in the animals treated with acyclovir only. In the group receiving the combination therapy, this reaction could not be established.

The number of animals inoculated in this study is too small to draw strong, statistically significant conclusions from between-group differences. However, both the pattern and the severity of cochlear damage within treatment groups showed a relatively small variability. Between–treatment group differences were more obvious, especially in comparing untreated animals to animals treated with prednisolone or with both prednisolone and acyclovir (Table 2).

DISCUSSION

Auditory Function. Our study was directed primarily toward the assessment of histopathologic damage in treatment of experimental HSV-1 labyrinthitis. The establishment of hearing function was considered to be secondary to this goal. Although behavioral tests such as Preyer's reflex are able to provide information on the presence of hearing,[13-16] measuring electrophysiological parameters is probably more sensitive and more precise in establishing hearing loss. We decided to use Preyer's reflex monitoring because it provides a reproducible estimate of the presence of hearing without any risk of interfering with the histopathology of the labyrinthitis we induced. Second, Preyer's reflex monitoring can be performed rapidly and repeatedly in a relatively large group of animals, in contrast to measuring electrophysiological parameters. Therefore, in this study design, the advantages of Preyer's reflex outweigh the more precise estimate of hearing threshold obtained by measuring electrophysiological parameters.

The HSV-1 labyrinthitis caused rapid hearing loss that recovered within 7 days of treatment with prednisolone. This finding is consistent with our clinical experience. Although the application of acyclovir alone did not lead to hearing recovery, the combined treatment of HSV-1 labyrinthitis with both acyclovir and prednisolone seems to elicit earlier hearing recovery than is observed with prednisolone alone.

Serologic Evaluation. The experimentally induced HSV-1 labyrinthitis, causing both hearing loss and gross structural damage to the cochlea, followed an otherwise symptomless course and was not accompanied by the appearance of HSV-specific complement-fixing antibodies. However, the primary HSV infection in the inoculated animals could be confirmed by HSV IgG seroconversion. Whether a nonprimary, local HSV infection, as might be present in ISSHL, can be detected by serologic evaluation remains to be demonstrated.

Light Microscopic Evaluation. Histopathologic changes found in the cochlea after induction of viral labyrinthitis by HSV-1 included a consistent pattern of severe damage to the stria vascularis, atrophy of the organ of Corti, elevation or loosening of the tectorial membrane, and inflammation of the neural fibers and ganglia. These pathological changes show a strong resemblance to postmortem cochlear histopathology described in ISSHL,[7-9] although in these subjects, the time interval between occurrence of ISSHL and observation of cochlear histopathology was obviously much longer than in our experimental design. This delay might be responsible for the differences between our experimental observations and descriptions of ISSHL postmortem histopathology in the literature.

The results of this study indicate that early application of corticosteroids suppresses the inflammatory reaction to HSV-1, thereby limiting structural damage to the cochlea. However, significant destruction remains, perhaps explaining the modest success of ISSHL treatment with prednisolone. Application of antiviral medication as a monotherapy aimed at the prevention of viral multiplication did not alter the devastating effects of HSV-1 labyrinthitis. Perhaps viral spreading is already too extensive with the perilymphatic inoculation pathway. Theoretically, the combination of prednisolone and acyclovir will lead not only to a suppressive effect of the inflammatory reaction but also to a limitation of viral multiplication and spreading, thereby limiting direct cytopathic effects of the virus.[17,18] In this study, the combination of both prednisolone and acyclovir seems to be synergistic in limiting cochlear damage, compared to prednisolone application as a monotherapy: less damage occurred to the organ of Corti and the stria vascularis, especially in the apical windings of the cochlea. Also, the inflammatory reaction found in neural structures seems to be limited further by this combined treatment.

CONCLUSIONS

Histopathologic changes caused by experimental HSV-1 labyrinthitis show a striking resemblance to

histopathologic changes described in ISSHL patients.[7-9] Consistently, severe deterioration of cochlear function and of cochlear structures occurs, while no systemic manifestations of viral infection are observed. This provides further support for the hypothesis that ISSHL might be caused by a viral labyrinthitis, possibly involving the herpesvirus family. Treatment with corticosteroids seems to alleviate hearing loss and to limit cochlear damage in experimental HSV-1 labyrinthitis. Adding acyclovir to prednisolone treatment leads to earlier relief of the hearing loss and to further limitation of structural cochlear damage in experimental HSV-1 labyrinthitis.

This combination therapy has already proven its effectiveness in Ramsay Hunt syndrome and in herpes zoster oticus. It has also been proposed for treatment of Bell's palsy.[19] The usefulness of early corticosteroid application in ISSHL has been reported in the literature. Our study results suggest a synergistic therapeutic effect of the combination of corticosteroids and acyclovir in the treatment of ISSHL. We are currently investigating this treatment modality in ISSHL patients in a randomized, double-blind, placebo-controlled clinical study.

ACKNOWLEDGMENTS — The authors thank F. P. Schröder for supervising the virus serologic tests. We are obliged to H. Segenhout and J. Verheul for their efforts in performing the experiments.

REFERENCES

1. Byl F. Sudden hearing loss: eight years experience and suggested prognostic table. Laryngoscope 1984;94:647-61.

2. Mattox DE, Simmons FB. Natural history of sudden sensorineral hearing loss. Ann Otol Rhinol Laryngol 1977;86:463-80.

3. Stokroos RJ, Albers FWJ, Van Cauwenberge P. Diagnosis and treatment of idiopathic sudden sensorineural hearing loss (ISSHL). A survey in the Netherlands and Flanders. Acta Otorhinolaryngol Belg 1996;50:237-45.

4. Kronenberg J, Almagor M, Bendet E, Kushnir D. Vasoactive therapy versus placebo in the treatment of sudden hearing loss. A double-blind clinical study. Laryngoscope 1992;102:65-8.

5. Wilson W, Byl F, Laird N. The efficacy of steroids in the treatment of idiopathic sudden hearing loss. Arch Otolaryngol 1980;106:772-6.

6. Moskowitz D, Lee K, Smith H. Steroid use in idiopathic sudden sensorineural hearing loss. Laryngoscope 1984;94:664-6.

7. Schuknecht HF, Donovan ED. The pathology of idiopathic sudden sensorineural hearing loss. Arch Otorhinolaryngol 1986;243:1-15.

8. Yoon TH, Paparella MM, Schachern PA. Histopathology of sudden hearing loss. Laryngoscope 1990;100:707-15.

9. Sando I, Harada T, Loehr A, Sobel JH. Sudden deafness. Histopathologic correlation in temporal bone. Ann Otol Rhinol Laryngol 1977;86:269-79.

10. Wood MJ, Johnson RW, McKendrick MW, Taylor J, Mandul BK, Crooks J. A randomized trial of aciclovir for 7 days or 21 days with and without prednisolone for the treatment of acute herpes zoster. N Engl J Med 1994;330:896-900.

11. Casey HL. Standardized diagnostic complement fixation method and adaptation to microtest. Public Health Monograph No. 74. Washington, DC: US Government Printing Office, 1965.

12. Mulkens PSJZ, Bleeker JD, Schröder FP, Schirm J, Welling S, Segenhout JM. Bell's palsy: a viral disease? An experimental study. In: Portmann M, ed. Facial nerve. New York, NY: Masson, 1985:248-52.

13. Bohmer A. The Preyer reflex. An easy estimate of hearing function in guinea pigs. Acta Otolaryngol (Stockh) 1988;106:368-72.

14. Huang JM, Money MK, Berlin CI, Keats BJ. Auditory phenotyping of heterozygous sound-responsive and deaf mice. Hear Res 1995;88:61-4.

15. Collins PW. Synergistic interactions of gentamicin and pure tones causing cochlear hair cell loss in pigmented guinea pigs. Hear Res 1988;36:249-60.

16. Barron SE, Daigneault EA. Effect of cisplatin on hair cell morphology and lateral wall Na,K-ATPase activity. Hear Res 1987;26:131-7.

17. Woolf NK, Ochi JW, Silva EJ, Sharp PA, Harris JP, Richman DD. Ganciclovir prophylaxis for cochlear pathophysiology during experimental guinea pig cytomegalovirus labyrinthitis. Antimicrob Agents Chemother 1988;32:865-72.

18. Darmstadt GL, Keithley EM, Harris JP. Effects of cyclophosphamide on the pathogenesis of cytomegalovirus-induced labyrinthitis. Ann Otol Rhinol Laryngol 1990;99:960-8.

19. Adour KK, Ruboyianes JM, Von Doersten PG, et al. Bell's palsy treatment with acyclovir and prednisone compared with prednisone alone: a double-blind, randomized, controlled trial. Ann Otol Rhinol Laryngol 1996;105:371-8.

OUTCOME OF BRAIN STEM AUDITORY ELECTROPHYSIOLOGY IN CHILDREN WHO SURVIVE PURULENT MENINGITIS

ZE D. JIANG, MD, PHD
OXFORD, ENGLAND

Brain stem auditory electrophysiology was assessed in children long after purulent meningitis by examining the central components of brain stem auditory evoked response (BAER) at different presentation rates of clicks. Children with peripheral hearing loss were excluded from this study to avoid any possible influence of the loss on the measurements of BAER central components. Of the 70 children who had recovered from meningitis 2 to 8 years earlier, 9 (12.9%) showed abnormalities in BAER central components — mainly a slight reduction of wave V amplitude, at the click presentation rate of 10/s. Of the remaining 61 children who did not show any obvious abnormalities in the BAER at 10/s, an abnormally prolonged I-V interval and a reduced amplitude of wave V were seen in 5 children (8.2%) at the click rate of 90/s. The total BAER abnormality rate was therefore 20.0% (14/70 cases). The results suggest that most children who survive purulent meningitis have a favorable outcome for the brain stem auditory pathway, with about 1 in 5 having mild dysfunction or a suboptimal outcome in the pathway.

KEY WORDS — auditory development, auditory dysfunction, brain stem auditory evoked response, children, evoked potentials, hearing loss, meningitis.

INTRODUCTION

Numerous reports have shown that bacterial meningitis is often accompanied by auditory impairment.[1-6] Although peripheral hearing loss is a well-known sequela of bacterial meningitis, whether there is a sequela pertaining to central auditory function following this disease remains largely unclear. This knowledge is important for planning rational intervention and rehabilitation measures for neurologic sequelae in children who survive purulent meningitis.

Precise assessment of auditory functions in children is often difficult, due to their poor cooperation during examination. The brain stem auditory evoked response (BAER) reflects electrophysiological activity of large numbers of neurons in the brain stem auditory pathway following acoustic stimulation. The various deflections in the response represent neural activity at different levels of the auditory brain stem. Waves I and II are generated in the extracranial and intracranial portions of the eighth nerve, respectively. Subsequent waves are generated from auditory centers at gradually higher levels of the auditory pathway in the brain stem. Wave V, the major deflection of the BAER, is generated, most likely, in the lateral lemniscus and, less likely, in the inferior colliculus, located in the rostral brain stem. This response can be noninvasively recorded from the scalp. Since it is minimally affected by sedatives and consciousness, it has been widely used as an objective test for auditory function in children with various neurologic conditions that affect the brain stem auditory pathway, including bacterial meningitis.[1,3,6-8]

Previous studies have shown that the BAER, elicited by clicks presented at conventional rates (usually 10/s to 21/s), was normal in most children studied who recovered from purulent meningitis.[1,3,6] However, this does not rule out the possibility that some of the children might have had subtle auditory dysfunction or suboptimal auditory function that escaped recognition by the BAER elicited with conventional rates. The method of increasing stimulus rate has been suggested to be a potentially useful "stress test" to improve the sensitivity of the BAER in detecting auditory dysfunction.[9-13] It seems that by presenting a physiological challenge to the auditory neurons, this stimulus stress test could be used to detect suboptimal auditory function in these children.

This study was designed to assess the outcome of brain stem auditory electrophysiology in children long after purulent meningitis and determine the prevalence of residual auditory dysfunction by examining the central components of the BAER. In particular, in order to detect any suboptimal auditory function that may not be shown by the BAER with conventional rates, the BAER was also recorded at higher stimulus rates in the children who did not show any obvious abnormalities in the BAER at 10/s clicks.

METHODS

Subjects. A total of 78 children who had been

From the Department of Child Health, Children's Hospital, Shanghai Medical University, Shanghai, People's Republic of China.
CORRESPONDENCE — Ze D. Jiang, MD, PhD, Dept of Paediatrics, John Radcliffe Hospital, University of Oxford, Headington, Oxford OX3 9DU, England.

found to have purulent meningitis between 8 days after birth and 6 years and were treated in Children's Hospital, Shanghai Medical University, were recruited. In order to avoid any possible influence of peripheral hearing loss on the measurements of BAER central components, 8 children who showed evidence of hearing loss, including an increase in BAER thresholds, were excluded from this study. The remaining 70 children were 39 boys and 31 girls, ranging in age from 2 to 12 years (mean 5 years 6 months). All had a BAER threshold of less than 20 dB normal hearing level (nHL). The study was carried out between 2 and 8 years after the subjects had recovered from meningitis.

All these children underwent neurologic examinations by pediatric neurologists. Clinical and laboratory data from the period of hospitalization were obtained retrospectively from the patients' charts. None had a history of deafness or neurologic disease other than meningitis and its consequences. The main complications during hospitalization included seizures (22 cases), hydrocephalus (8 cases), enlarged ventricles (6 cases), subdural effusion (6 cases), coma (9 cases), nerve palsies (4 cases), and anemia (5 cases). Antibiotics were administered to all subjects. Penicillin sodium was given intravenously for meningococcal (28 cases) and pneumococcal (9 cases) meningitis. Chloramphenicol sodium succinate and ampicillin sodium were given for *Haemophilus influenzae* (18 cases) and unknown organisms (15 cases). The antibiotic treatments lasted for 10 to 15 days in most cases. Normal controls were 92 age-matched healthy children with a normal history of neurologic development and no history or evidence of auditory or neurologic disease.

Recording of BAER. Subjects lay supine on a soft bed in a sound-isolated and electrically shielded room. They were tested during sleep following oral administration of chloral hydrate (40 mg/kg) to reduce muscle artifacts, as was approved by the Academic Committee of the institution and with the consent of the parents. Three silver–silver chloride disk electrodes were placed, respectively, at the forehead in the midline (positive), at the earlobe ipsilateral to the acoustic stimuli (negative), and at the contralateral earlobe (ground). Interelectrode resistance was maintained at 5 kΩ or less. Rarefaction clicks of 100-microsecond duration were used as acoustic stimuli. The clicks were presented at an intensity of 70 dB nHL, delivered monaurally through TDH 39 earphones. The contralateral ear was masked with white noise 40 dB below the ipsilateral click stimuli. All children were tested at a click rate of 10/s. In the children who had a normal BAER at 10/s, the presentation rate was then increased from 10/s to 50/s and 90/s in sequence. In the subjects who remained asleep following these recordings, the test was continued at click rates of 30/s and 70/s.

Brain stem responses to 1,024 clicks were recorded for each run. The recording signals were preamplified ($\times 10^5$), bandpass-filtered between 100 and 2,000 Hz, and processed by an averaging computer. An automatic artifact rejection was used to reduce the inclusion of high-amplitude muscular activity in the averaged responses. The ongoing filtered electroencephalogram and the running averaged BAER were carefully monitored during averaging. Sampling was discontinued whenever there were excessive muscle artifacts on the monitoring oscilloscope.

BAER Measurements and Data Analysis. The main BAER measurements analyzed were the I-V interpeak interval and the wave V amplitude, determined from the positive peak of a BAER component to the immediately following negative trough. Normative criteria of various BAER measures for children were determined as follows. For interpeak intervals, values exceeding 2.5 standard deviations above the means of the normal controls were considered abnormal. The upper limits for the I-III, III-V, and I-V intervals were 2.6, 2.2, and 4.5 milliseconds (ms), respectively. The fifth percentiles of amplitude values seen in the normals were determined as the lower limits for wave amplitudes. The normative lower limit for wave V amplitude was 0.25 μV, and for V/I amplitude ratio was 0.40 (2 to 6 years) or 0.45 (7 to 12 years). The upper limits of normative criteria for I-V interval increments from 10/s to higher rates of the clicks, which were defined as 2.5 standard deviations above the means of the increments in the controls, were 0.85 ms and 1.10 ms for the increment between 10/s and 50/s and for that between 10/s and 90/s, respectively. The amplitude of wave V was reduced less than 40% in 88 of the 92 controls (95.7%) with the increase of click rate from 10/s to 50/s, and less than 55% in 89 (96.7%) from 10/s to 90/s. These reduction rates were defined as the upper limits for the decrement of wave V amplitude.

Neurologic examinations and BAER recording and measurement were performed by different clinical and research staff. The measurement and analysis of BAER recordings were strictly blind to the results of the neurologic examinations.

RESULTS

BAER at Click Rate of Ten Per Second. Most of the children who survived purulent meningitis did not show any obvious abnormalities in BAER waveform morphology, although wave amplitudes tended to be slightly depressed. No significant differences

TABLE 1. COMPARISON OF BAER INTERPEAK INTERVALS IN CHILDREN WHO SURVIVED PURULENT MENINGITIS (N = 70) WITH THOSE IN NORMAL CONTROLS (N = 92) AT DIFFERENT CLICK RATES

Click Rate	*Subjects*	*I-III*	*III-V*	*I-V*
10/s	Normal	2.18 ± 0.17	1.80 ± 0.16	3.97 ± 0.22
	Postmeningitis	2.17 ± 0.19	1.83 ± 0.17	4.01 ± 0.25
50/s	Normal	2.36 ± 0.21	1.96 ± 0.18	4.31 ± 0.26
	Postmeningitis	2.37 ± 0.19	1.99 ± 0.16	4.36 ± 0.24
90/s	Normal	2.51 ± 0.20	2.11 ± 0.19	4.60 ± 0.26
	Postmeningitis	2.58 ± 0.22	2.20 ± 0.21	4.79 ± 0.28*

Data are milliseconds (mean ± SD).

BAER — brain stem auditory evoked respcnse.

*p < .05 by Student's *t*-test for comparison of difference between postmeningitis children and normal controls. None of other differences are statistically significant.

were found between the study children and the normal controls in any of the 3 interpeak intervals (I-III, III-V, and I-V; Table 1). Only the wave V amplitude (0.34 ± 0.12 μV) was reduced slightly compared to that of the controls (0.39 ± 0.10 μV, p < .05).

Abnormal BAER results were seen in 9 of the 70 children (12.9%), including 7 with an amplitude of wave V slightly below the normal lower limit (0.17 to 0.23 μV, Fig 1A), 1 with a decreased V/I amplitude ratio (Fig 1B), and 1 with a prolonged I-V interval (Fig 1C and Table 2). The remaining 61 children did not show any obvious abnormalities and underwent further BAER testing at higher click rates.

BAER at Clicks With Higher Presentation Rates. The rate-dependent changes in the BAERs of the children who survived meningitis and had a normal BAER at 20/s were generally similar to those of the normals. All wave latencies and interpeak intervals were prolonged linearly with an increase in click rate. At the higher rates, BAER latencies and intervals in the study children increased slightly more than in the controls (Table 1), while wave amplitudes decreased slightly more. Statistical analyses showed that only the I-V interval at 90/s differed significantly (Table 1). The wave V amplitude at 90/s in the study children (0.26 ± 0.10 μV) also differed significantly from that in the controls (0.30 ± 0.12 μV; p < .05). Abnormal BAER results at higher click rates were seen slightly more at clicks of 90/s than at 50/s (Table 2). At the clicks of 50/s, 3 of the 61 children (4.9%) had abnormalities in the BAER, including 1 abnormally prolonged I-V interval and 2 abnormally reduced amplitudes of wave V. At the clicks of 90/s, 5 children (8.2%) had either an abnormally prolonged I-V interval (2 cases) or an abnormally reduced amplitude of wave V (3 cases). The total BAER abnormality was increased, from 12.9% at clicks of 10/s, to 17.1% at both 10/s and 50/s, and to 20.0% at both 10/s and 90/s.

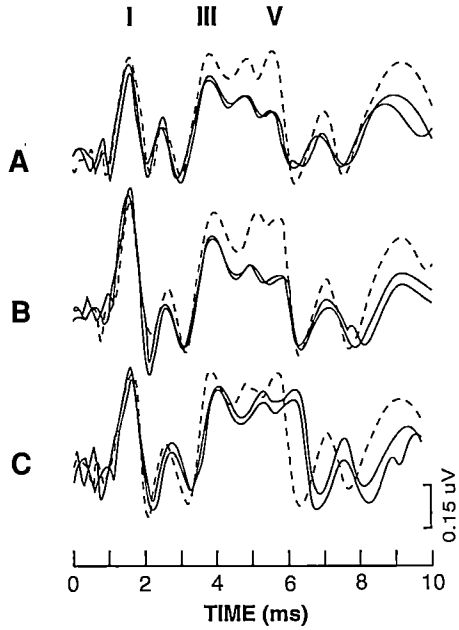

Fig 1. Sample brain stem auditory evoked response recordings from 3 children showing A) reduced amplitude of wave V (patient age 11 years), B) decreased V/I amplitude ratio (patient age 8 years), and C) prolonged I-V interval (patient age 5 years), long after purulent meningitis. Dashed lines are recordings of age-matched controls.

Figure 2 shows representative BAER recordings in 2 children who survived purulent meningitis. The recordings at 10/s and 50/s clicks were all normal.

TABLE 2. NUMBER OF MENINGITIS SURVIVORS WITH ABNORMAL BAER FINDINGS AT VARIOUS CLICK RATES

Click Rate	*Number*	*Prolonged I-V Interval*	*Reduced Amplitude of Wave V*	*Decreased V/I Amplitude Ratio*	*No. of Abnormalities†*	*Total No. of Abnormalities*
10/s	70	1	7	1	9/70 (12.9%)	9/70 (12.9%)
50/s	61*	1	2	0	3/61 (4.9%)	12/70 (17.1%)§
90/s	61*	2	3	0	5/61 (8.2%)	14/70 (20.0%)‡

*Number excludes children who had abnormal BAER at 10/s clicks.

†Number of BAER abnormalities (including prolonged I-V interval, reduced amplitude of wave V, and decreased V/I amplitude ratio) at each click rate.

§Number of BAER abnormalities at both 10/s and 50/s clicks.

‡Number of BAER abnormalities at both 10/s and 90/s clicks.

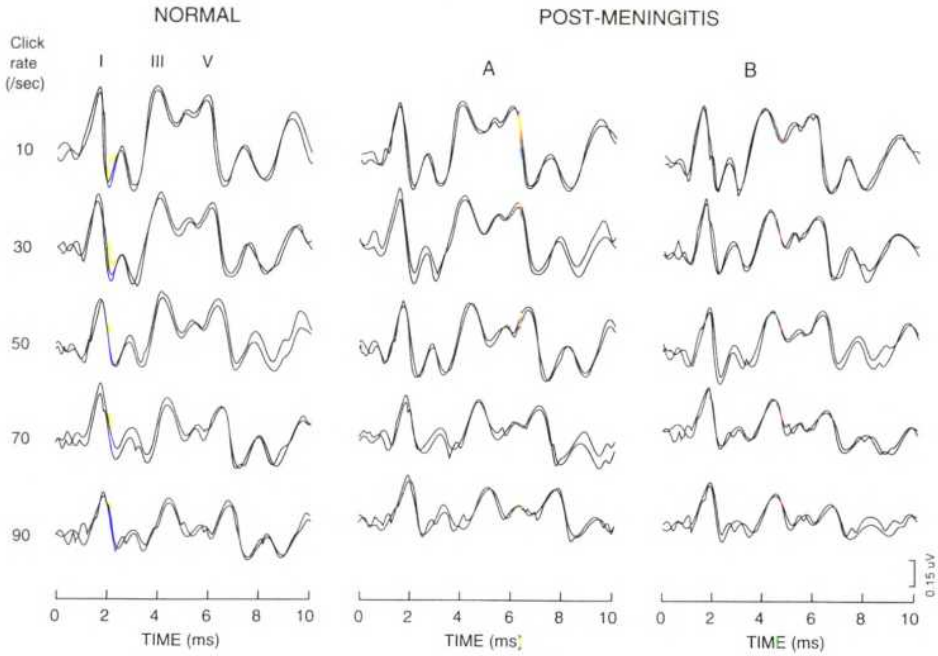

Fig 2. Representative brain stem auditory evoked response recordings in 2 children who survived purulent meningitis in comparison with normal control (9 years old). Recordings at 90/s clicks are abnormal: A — abnormally prolonged I-V interval in 7-year-old; B — abnormally reduced amplitude of wave V in 10-year-old.

At 90/s clicks, 1 of the children showed an abnormally prolonged I-V interval (Fig 2A) and the other showed an abnormally reduced amplitude of wave V (Fig 2B).

Clinical Correlation. During hospitalization, the major complications in the 14 children who showed an abnormal BAER in this study were hydrocephalus (6 cases) and enlarged ventricles (4 cases). No clear correlation was found between the BAER results and the type of causative microorganism. All the children who enrolled in this study had various degrees of signs of elevated intracranial pressure, including irritability, full fontanelle, headache, nausea, papilledema, vomiting, lethargy, altered consciousness, convulsion, signs of herniation, and decorticate posturing. These signs were much more severe in the 14 children with an abnormal BAER than in those who had a normal BAER.

In general, the younger the age at which meningitis occurred, the more likely the BAER was to be abnormal. The BAER abnormalities were seen much more frequently in children who had meningitis at or before 1 year of age (33%) than in those who had meningitis after 1 year of age (13%; $\chi^2 = 4.05$; $p < .05$). This was also the case for neurologic examinations; ie, neurologic sequelae were seen more frequently in children who had meningitis at or before 1 year of age (46%) than in those who had meningitis after 1 year of age (17%; $\chi^2 = 6.16$; $p < .05$).

At the time of this study, physical and neurologic examinations revealed that the children with an abnormal BAER frequently had neurologic sequelae, while most of the children with a normal BAER did not show any apparent sequelae. Of the 9 children with an abnormal BAER at 10/s clicks, 6 (66.7%) had neurologic sequelae, including 2 with petit mal seizures, 1 with spastic hemiparesis, and 3 with hyperactivity. Three of the 5 children who had an abnormal BAER at 90/s clicks (60.0%) but a normal BAER at 10/s clicks also had abnormal neurologic findings (1 with nerve palsies and 2 with hyperactivity). Of the remaining 56 children who had normal BAERs at both 10/s and higher rates of clicks, neurologic sequelae were found in only 10 patients (17.9%), including 3 with psychomotor seizures, 1 with spastic hemiparesis, 2 with nerve palsies, 1 with poor vision and incoordination, and 3 with hyperactivity. Of the 6 children who showed clinical signs of brain stem dysfunction (nystagmus, other eye movement abnormalities, or ataxia), 4 had BAER abnormalities: 2 at clicks of 10/s and the other 2 at 90/s.

DISCUSSION

Abnormalities in BAER central components following bacterial meningitis have been reported by several authors.[1,8] The abnormalities are mostly reversible and can normalize after recovery from the disease. A prolongation of interpeak intervals is the most frequent finding. The present study showed, however, that the major BAER abnormality long after recovery is a reduction of wave V amplitude, while a prolongation of interpeak intervals is uncommon. A likely explanation of the difference between our observations and those of others is a discrepancy between these studies in the time when BAER testing was conducted after the occurrence of meningitis. In this study, the subjects were children who

had recovered from meningitis 2 to 8 years earlier, while in others' studies the subjects were infants who were recovering from meningitis.

In patients with *Brucella* meningitis, Yaqub et al[8] found that 3 to 6 months after completion of antibiotic therapy, prolonged I-III and I-V intervals normalized, while reduced amplitudes of wave V or an absence of wave V showed no change. We also followed 9 infants who were recovering from purulent meningitis. A prolonged I-V interval and a reduced amplitude of wave V were found in 4 and 3 cases, respectively, with 1 of them having both abnormalities. With recovery from meningitis, the abnormalities returned to normal in 3 infants for the prolonged I-V interval and in only 1 for the reduced amplitude. These observations imply that a prolonged I-V interval is a frequent finding in the acute phase of the disease and is mostly reversible during the course of recovery, while a reduced amplitude of wave V is more persistent. This may largely explain why an amplitude reduction of wave V was the major BAER abnormality in our study. This amplitude reduction is most likely due to fewer neurons generating and/or fewer fibers conducting the volley in the brain stem secondary to ischemic insults to the rostral brain stem.[14]

The BAER abnormalities following meningitis could be caused by several pathological conditions. A strong correlation between BAER abnormalities and hydrocephalus, enlarged ventricles, and possibly nerve palsies has been reported in children recovering from meningitis.[1] The present study also showed that hydrocephalus and enlarged ventricles were the major pathological conditions that were associated with BAER abnormalities in children who survived meningitis. These 2 conditions increase intracranial pressure, causing ischemic damage to the brain stem from alterations in blood flow in the penetrating vessels of the basilar or posterior cerebral arteries. Mechanical compression of the upper brain stem interferes with brain stem circulation.[15] This compression ischemia can result in a reduction in wave amplitudes and a prolongation of interpeak intervals in the BAER. For instance, patients with confirmed hydrocephalus, mainly due to a congenital anomaly, meningitis, or intracranial hemorrhage, often showed abnormal results in BAER testing, including a decreased V/I amplitude ratio, a prolonged I-V interval, and abnormal morphology of waves III and V.[16] The present study found that signs of elevated intracranial pressure during hospitalization were much more severe in children who had an abnormal BAER than in those who had a normal BAER. It appears that the BAER abnormalities, indicating long-term or permanent damage to the brain stem, are at least partially related to ischemic insults to the brain stem due to elevated intracranial pressure during the course of meningitis. Seizures, which increase metabolic demands of the brain and result in diffuse damage,[4] decreased hemoglobin level, and hypoxic-ischemic brain injury, may also damage the brain stem.

The present study showed that BAER abnormalities occurred more frequently in the children who had meningitis at or before 1 year of age than in those who had the disease after 1 year of age. This was in good agreement with the findings of neurodevelopmental examinations. It appears that the severity of neurologic sequelae following meningitis is related to the maturity of the brain. Compared to the relatively mature brain, the immature brain is more vulnerable to the damage caused by meningitis.

In this study, 8.2% of the children who survived purulent meningitis showed abnormal results in the BAER only at higher click rates, indicating a suboptimal outcome of the auditory brain stem that cannot be demonstrated by the conventionally used slow stimulus rate (10/s). Similar to those who had an abnormal BAER at the click rate of 10/s, these children also tended to have clinically determined neurologic sequelae. These observations provide further evidence that the stimulus "stress test" could enhance the detection of neural pathophysiology in the brain.[9,10,12] The finding that there were more BAER abnormalities at the repetition rate of 90/s than at 50/s suggests that high rates are more sensitive than moderate rates for detecting suboptimal auditory function.

Patients who survive meningitis may have both peripheral and central auditory impairments. Peripheral hearing loss may affect the measurements of BAER central components, causing amplitude reduction, latency prolongation, and, in the case of high-frequency loss, a I-V interval shortening. At higher presentation rates, these effects tend to become more significant, often making it difficult to determine whether BAER central components are normal or abnormal. In order to avoid these possible influences and to analyze the central components reliably and accurately, the present study only included data from those who did not have any evidence of peripheral hearing loss. Consequently, those who might have had both peripheral and central auditory sequelae were excluded. Due to this limitation, the results of this study should be considered characteristic only of the sequelae of meningitis for those without peripheral hearing loss, and not as generally characteristic.

In conclusion, the present study showed that about 1 in 5 of survivors of meningitis have BAER abnormalities indicative of mild auditory dysfunction or a suboptimal outcome in the pathway. Therefore, central auditory dysfunction is not an uncommon neurologic sequela. The method of increasing click rate can be used to detect suboptimal auditory function that may not be shown by the BAER elicited at 10/s clicks and thus enhances the diagnosis of auditory neuropathology in patients who survive meningitis.

REFERENCES

1. Özdamar Ö, Kraus N. Auditory brainstem response in infants recovering from bacterial meningitis: neurologic assessment. Arch Neurol 1983;40:499-502.

2. Dodge PR, Davis H, Feigin RD, et al. Prospective evaluation of hearing impairment as a sequela of acute bacterial meningitis. N Engl J Med 1984;311:869-74.

3. Vienny H, Despland PA, Lutschg J, Deonna T, Dutoit-Marco ML, Gander C. Early diagnosis and evolution of deafness in childhood bacterial meningitis: a study using brainstem auditory evoked potentials. Pediatrics 1984;73:579-86.

4. Salwën KM, Vikerfors T, Olcën P. Increased incidence of childhood bacterial meningitis: a 25-year study in a defined population in Sweden. Scand J Infect Dis 1987;19:1-11.

5. Pomeroy SL, Holmes SJ, Dodge PR, Feigin RD. Seizures and other neurologic sequelae of bacterial meningitis in children. N Engl J Med 1990;323:1651-7.

6. Jiang ZD, Liu XY, Wu YY, Zheng MS, Liu HC. Long-term impairments of brain and auditory functions of children recovered from purulent meningitis. Dev Med Child Neurol 1990;32:473-80.

7. Kotagal S, Rosenberg C, Rudd D, Dunkle LM, Horenstein S. Auditory evoked potentials in bacterial meningitis. Arch Neurol 1981;38:693-5.

8. Yaqub BA, Kabiraj MM, Shamena A, al Bunyan M, Daif A, Tahan A. Diagnostic role of brain-stem auditory evoked potentials in neurobrucellosis. Electroencephalogr Clin Neurophysiol 1992;84:549-52.

9. Pratt H, Ben-David Y, Peled R, Podoshin L, Scharf B. Auditory brain stem evoked potentials: clinical promise of increasing stimulus rate. Electroencephalogr Clin Neurophysiol 1981;51:80-90.

10. Gerling IJ, Finitzo-Hieber T. Auditory brainstem response with high stimulus rates in normal and patient populations. Ann Otol Rhinol Laryngol 1983;92:119-23.

11. Jiang ZD. Binaural interaction and the effects of stimulus intensity and repetition rate in human auditory brainstem. Electroencephalogr Clin Neurophysiol 1996;100:505-16.

12. Jiang ZD, Brosi DM, Wilkinson AR. Immaturity in electrophysiological response of the neonatal auditory brainstem to high repetition rates of click stimulation. Early Hum Dev 1998;52:133-43.

13. Jiang ZD, Tierney TS. Binaural interaction in human neonatal auditory brainstem. Pediatr Res 1996;39:708-14.

14. Jiang ZD, Tierney TS. Long-term effect of perinatal and postnatal asphyxia on developing human auditory brainstem response: brainstem impairment. Int J Pediatr Otorhinolaryngol 1996;34:111-27.

15. Goodman SJ, Becker DP. Vascular pathology of the brainstem due to experimentally induced intracranial pressure: changes noted in the micro- and macrocirculation. J Neurosurg 1973;39:601-9.

16. Kraus N, Özdamar Ö, Heydemann PT, Stein L, Reed NL. Auditory brain-stem responses in hydrocephalic patients. Electroencephalogr Clin Neurophysiol 1984;59:310-7.

CLINICAL PRESENTATION AND MANAGEMENT OF LABYRINTHINE FISTULA CAUSED BY CHRONIC OTITIS MEDIA

NICOLAS Y. BUSABA, MD
BOSTON, MASSACHUSETTS

To describe the clinical presentation and surgical management of patients with chronic otitis media complicated by labyrinthine fistula and to determine clinical indicators that predict postoperative hearing outcome, I performed a retrospective analysis at an academic tertiary care center. Thirty-four patients with labyrinthine fistula as a complication of chronic otitis media, documented at mastoidectomy, underwent postoperative audiometry. The median age was 50 years, and the duration of otologic symptoms ranged from 2 months to more than 40 years. On presentation, 3 patients had anacusis in the affected ear, while in the others, the pure tone average for bone conduction at the 0.5-, 1-, 2-, and 4-kHz frequencies was 34 dB hearing level. Nineteen patients (56%) complained of dizziness on presentation. The fistula test was positive in 14 of 28 patients (50%). The fistula was detected radiologically in 10 of 24 patients (42%). Cholesteatoma was present in 33 of 34 patients (97%). The lateral semicircular canal was the most common site of labyrinthine fistula. The cholesteatoma matrix was completely removed in 29 of 33 cases and exteriorized in the remaining 4. Of the 31 patients with measurable hearing preoperatively, anacusis occurred in 8 (26%). In 6 of these, the preoperative pure tone average for bone conduction was greater than 50 dB hearing level, and cholesteatoma matrix and granulation tissue invading the membranous labyrinth were found at surgery. I concluded that in chronic otitis media, labyrinthine fistulas occurred almost exclusively in the presence of a cholesteatoma. Postoperative hearing outcome correlated with the size of the fistula and the presence of granulation tissue invading the labyrinth, which could be predicted by the preoperative audiometry.

KEY WORDS — cholesteatoma, chronic otitis media, labyrinthine fistula.

INTRODUCTION

The diagnosis and management of fistulas of the labyrinth with or without a perilymph leak complicating chronic suppurative otitis media remains controversial. The incidence of fistulas found during surgery for chronic otitis media with cholesteatoma has been reported to range between 3.6% and 12.6%.[1-4] The lateral semicircular canal (SCC) is the most common location of erosion of the labyrinth by cholesteatoma matrix.[4-7] The clinical presentation of labyrinthine fistulas is variable, and their management is controversial.

The "fistula sign"[8,9] has been shown to be an unreliable indicator of the presence of a labyrinthine fistula, with a false-negative rate of up to 54%.[5] Computed tomography (CT) has been reported to have an 80% sensitivity and a less than 5% false-positive rate in detecting labyrinthine fistulas in the presence of chronic otitis media,[10,11] making it a more reliable indicator of the presence of fistula than a positive fistula sign.

A variety of techniques have been recommended for management of labyrinthine fistulas, including leaving the cholesteatoma matrix at the site of the fistula and exteriorization of the disease,[12] staging the procedure by removing the cholesteatoma matrix in a planned second-stage surgery,[6,13] and removal of the cholesteatoma and closure of the fistula with connective tissue.[14]

The present study is a retrospective review of the clinical presentation, preoperative imaging studies, surgical technique, and hearing results in 34 patients with surgically confirmed labyrinthine fistula. The purpose of the study was to identify preoperative indicators for the presence of a fistula, and preoperative or intraoperative predictors of hearing outcome.

MATERIALS AND METHODS

A retrospective review of 625 cases of surgery performed for chronic otomastoiditis at the Massachusetts Eye and Ear Infirmary between 1970 and 1995 was done, identifying cases with documented fistula of the otic capsule. A "fistula" was defined as dehiscence of the otic capsule with exposure of the membranous labyrinth with or without leakage of perilymph. Cases with thinning or "blue-lining" of the labyrinth were not included. Thirty-four patients (5.4%) were found to have a labyrinthine fistula intraoperatively.

From the Division of Otolaryngology, Brockton/West Roxbury Veterans Administration Medical Center, West Roxbury, and the Department of Otolaryngology, Massachusetts Eye and Ear Infirmary, and the Department of Otology and Laryngology, Harvard Medical School, Boston, Massachusetts.

Presented at the meeting of the Association for Research in Otolaryngology, St Petersburg, Florida, February 4-7, 1996.

CORRESPONDENCE — Nicolas Y. Busaba, MD, Dept of Otolaryngology, Massachusetts Eye and Ear Infirmary, 243 Charles St, Boston MA 02114.

P24,703

TABLE 1. OTOLOGIC SYMPTOMS ON PRESENTATION

	No.	%
Otorrhea	32	94
Otalgia	3	9
Subjective hearing loss	25	74
Tinnitus	6	18
Vestibular complaints	19	56

Preoperative clinical data included the sex and age of the patients, duration of otologic symptoms related to chronic otitis media, presence of dizziness, fistula sign, and preoperative hearing status. The fistula sign was considered positive if there was visible conjugate deviation of the eyes induced by alternating pressure applied to the ear canal associated with subjective dizziness. The pure tone average for bone conduction thresholds (PTA-bone) in decibels hearing level (HL) for 0.5, 1, 2, and 4 kHz was calculated. When bone conduction thresholds exceeded audiometric limits at any of the above frequencies, a threshold of 75 dB HL was assigned for that frequency in calculating the PTA-bone. The results of polytomography and CT were recorded. Operative findings, including the location and size of labyrinthine fistulas, and the surgical management were also recorded. The postoperative PTA-bone was calculated from the last available postoperative audiogram obtained within 6 months of surgery.

The correlation of postoperative PTA-bone with preoperative PTA-bone, vestibular symptoms, and presence or absence of the fistula sign was statistically evaluated with a χ^2 test. A $p < .05$ was considered significant.

RESULTS

Patient Demographics and Symptoms. A labyrinthine fistula was found at surgery in 34 of the 625 cases of chronic otomastoiditis (5.4%). Of the 34 patients with labyrinthine fistula, 23 were male and 11 were female, with an age range of 16 to 81 years and a median age of 50 years. The duration of otologic symptoms referable to chronic otitis media (otorrhea, otalgia, tinnitus, dizziness, and/or subjective hearing loss) varied from 2 months to more than 40 years. Fifteen patients (44%) had symptoms for more than 10 years. Nineteen (56%) had vestibular symptoms preoperatively, and 2 had persistent vertigo for 4 days prior to presentation.

Preoperative Audiometric and Radiographic Results and Clinical Signs. The fistula test was positive in 14 of 28 patients (50%). The preoperative PTA-bone was less than 30 dB HL in 16 of the 34 patients (47%), between 31 and 50 dB HL in 7 (21%), and more than 51 dB HL in 8 (23%). Three patients (9%) had anacusis in the affected ear at presentation (Table 1). Polytomography of the temporal bone was done preoperatively in 6 patients, and a labyrinthine fistula was diagnosed in 3 (50%). Eighteen cases had preoperative CT, which correctly identified the presence of a labyrinthine fistula in 7 of the 18 patients (39%; see Figure). No imaging studies were performed in 10 cases.

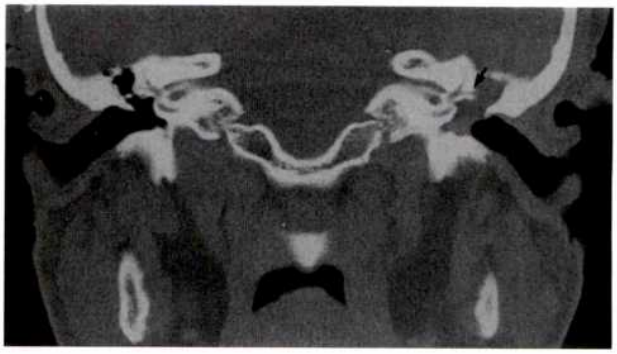

Coronal computed tomography scan, with bone window setting, showed soft tissue density filling left middle ear and mastoid antrum and labyrinthine fistula of lateral semicircular canal (arrow). Fistula was confirmed on surgical exploration.

Intraoperative Findings and Management. Of the 34 cases with labyrinthine fistulas, cholesteatoma was found in the mastoid or middle ear in 33 (97%). The location of the fistula was the lateral SCC in 32 (94%), superior SCC in 1 (3%), posterior SCC in 1 (3%), vestibule in 2 (6%), and promontory in 2 (6%). Four ears had more than 1 fistula (12%): 2 had fistulas in the lateral SCC and promontory, 1 had fistulas in the lateral SCC and vestibule, and 1 had fistulas in the lateral and superior SCCs.

Canal wall–down mastoidectomy was performed in all cases. Normal saline solution was used for irrigation during the surgery. The cholesteatoma was completely removed in 29 of the 33 patients found to have cholesteatoma during surgery and was exteriorized in 4. Exteriorization was done in 1 patient with an only-hearing ear, in 1 with measurable hearing and a fistula of the promontory, in 1 with 2 fistulas involving the lateral and superior SCCs, and in 1 with a fistula of the lateral SCC in which associated granulation tissue was found to invade the membranous labyrinth. The fistula was sealed with a cortical bone chip in 8 and with bone wax in 3. A temporalis fascia graft was used to cover the site of the fistula in all but the 4 patients in whom the cholesteatoma matrix was exteriorized. Tympanomastoid obliteration with an abdominal fat graft was done in 4 patients: 3 patients with preoperative anacusis and 1 patient in whom a labyrinthectomy was necessary to remove the cholesteatoma that involved the vestibule and lateral SCC. Obliteration of the mastoid

TABLE 2. PREOPERATIVE AND POSTOPERATIVE PURE TONE AVERAGE FOR BONE CONDUCTION

	Postop PTA							
	<30 dB HL		31-50 dB HL		>51 dB HL		Anacusis	
Preop PTA	No.	%	No.	%	No.	%	No.	%
<30 dB HL (n = 16)	11	69	5	31				
31-50 dB HL (n = 7)			4	57	1	14	2	29
>51 dB HL (n = 8)					2	25	6	75
Anacusis (n = 3)							3	100

Data are number of ears.

PTA — pure tone average for bone conduction thresholds at 0.5, 1, 2, and 4 kHz; HL — hearing level.

bowl was done with bone paté and an inferiorly based pedicled fascioperiosteal flap in 26 cases.

Postoperative Hearing Result. Of the 16 ears with a preoperative PTA-bone of less than 30 dB HL, the postoperative PTA was in the same range in 11 (69%). In the remaining 5 ears, the PTA fell to 31 to 50 dB HL postoperatively, but none had anakusis. Of the 8 ears with a preoperative PTA-bone of more than 51 dB HL, anacusis occurred postoperatively in 6 (75%; Table 2; $p < .005$). A hearing improvement of 10 dB or more occurred in 3 patients: 2 with a preoperative PTA-bone of less than 30 dB HL, and 1 with a preoperative PTA-bone of 45 dB HL. In the 6 ears in which invasion of the membranous labyrinth by cholesteatoma and granulation tissue occurred, the preoperative PTA-bone was greater than 51 dB HL and anacusis occurred postoperatively. One ear with fistulas involving both the promontory and the lateral SCC and in which the cholesteatoma matrix was exteriorized also had postoperative anacusis.

Correlation of Vestibular Signs and Symptoms With Postoperative Hearing Results. Postoperative hearing was significantly worse in ears with a preoperative positive fistula test compared to those with negative tests ($p = .007$). However, this might be due to the fact that ears with positive tests had worse preoperative hearing than those with negative tests ($p = .02$; Table 3). The presence of preoperative vestibular symptoms did not correlate with the preoperative hearing status ($p = .325$) or postoperative hearing outcome ($p = .066$; Table 4).

DISCUSSION

The reported incidence of labyrinthine fistulas in ears with chronic otitis media as documented intraoperatively varies between 3.6% and 12.6%[1-4] and is similar to the incidence of 5.4% found in the current study. Fistulas occur almost exclusively in the setting of a cholesteatoma.[2,4-7] In the current study, a cholesteatoma was found in 33 of the 34 cases (97%). The lateral SCC was the most common site involved in this study (94%) and in previously reported cases.[4-7]

TABLE 3. CORRELATION BETWEEN FISTULA SIGN AND PREOPERATIVE HEARING STATUS AND POSTOPERATIVE HEARING OUTCOME

	Fistula Sign			
	Positive		Negative	
	No.	%	No.	%
Preop PTA				
<30 dB HL	5	36	11	79
31-50 dB HL	3	21	1	7
>51 dB HL	4	29	1	7
Anacusis	2	14	1	7
Total	14	100	14	100
Postop PTA				
<30 dB HL	2	14	9	65
31-50 dB HL	4	29	3	21
>51 dB HL	2	14	1	7
Anacusis	6	43	1	7
Total	14	100	14	100

Data are number of ears.

PTA — pure tone average for bone conduction thresholds at 0.5, 1, 2, and 4 kHz; HL — hearing level.

A reliable preoperative predictor of a labyrinthine fistula would be clinically valuable. High-resolution CT has been reported to have a sensitivity of around 80% and a false-positive rate of less than 5% for labyrinthine fistulas. Axial cuts are recommended for study of the lateral SCC, and coronal cuts for other sites.[10,11] However, in this study, conventional temporal bone polytomography identified only 50%, and CT scans only 39% of the fistulas documented

TABLE 4. CORRELATION BETWEEN PREOPERATIVE VERTIGO AND PREOPERATIVE AND POSTOPERATIVE HEARING

	Preoperative Vertigo			
	Present		Absent	
	No.	%	No.	%
Preop PTA				
<30 dB HL	8	40	8	58
31-50 dB HL	6	30	1	7
>51 dB HL	5	25	3	21
Anacusis	1	5	2	14
Total	20	100	14	100
Postop PTA				
<30 dB HL	4	20	7	50
31-50 dB HL	7	35	2	14
>51 dB HL	2	10	1	7
Anacusis	7	35	4	29
Total	20	100	14	100

Data are number of patients.

PTA — pure tone average for bone conduction thresholds at 0.5, 1, 2, and 4 kHz; HL — hearing level.

at surgery. Since the cases reviewed in this series occurred over a time span of 25 years, the low sensitivity of CT scans in detecting fistulas may have been due to the poorer resolution of the early-generation scanners and may not necessarily reflect the current state of the art.

The fistula sign is unreliable in the preoperative diagnosis of labyrinthine fistula, with a false-negative rate in the literature of up to 54%,[5,8,9] similar to that of the current study (50%). The reason for the false-negative fistula tests is not clear.

Invasion of the labyrinth by cholesteatoma is reported to occur without subjective vestibular symptoms in approximately 40% of cases,[2,4] consistent with my study (44%). Preoperative hearing status is also not a good predictor of the presence of a fistula. In this series, 47% of the ears had a PTA-bone of less than 30 dB HL. In the absence of a reliable predictor, the presence of a labyrinthine fistula should be suspected in ears with chronic otitis media, especially if associated with cholesteatoma.

The surgical technique most likely to result in hearing preservation in the presence of a fistula remains controversial. Some authors advocate leaving the cholesteatoma matrix undisturbed and exteriorized at the fistula site.[12] On the other hand, Sanna et al[6] advocate intact canal wall tympanomastoidectomy with a planned second-stage procedure 6 months later. The authors describe bony healing of the fistula at the second look in 60% of the cases and report no change in bone conduction in 93% of their patients. These authors advocate open procedures with exteriorization of the disease in cases of only-hearing ears, large defects in the posterior wall of the external auditory canal, or multiple fistulas. Gacek[14] advocates complete removal of the cholesteatoma matrix and coverage of the fistula site if it is small or medium-sized (<2 mm) and exteriorization if the fistula is extensive or involves the cochlea. In the series by Ostri and Bak-Pedersen,[4] the matrix was removed in all the cases and the fistula was repaired with temporalis fascia and a cortical bone chip. The authors report that 6% of ears had postoperative anacusis. Pfaltz[3] removed the matrix in fistulas less than 3 mm in diameter and reported anacusis in 2 of 19 ears. In both ears, extensive labyrinthine invasion by the cholesteatoma was present. Palva and Ramsay[7] removed the matrix in all cases, and the fistula was covered with fibrin glue and fascia or periosteum. Hearing was preserved in all patients in whom removal of the matrix was carried out as the planned last stage of the operation. Patients in our series underwent canal wall–down tympanomastoidectomy. The cholesteatoma matrix was removed in 29 of 33 cases and exteriorized in the remaining 4 patients as described. The fistula site was repaired with a cortical bone chip or bone wax, then covered with temporalis fascia graft and reinforced by an inferiorly based pedicled fascioperiosteal flap used for partial mastoid obliteration.

The operations in the current study were performed by multiple otologists over a 25-year period, and the results may differ among surgeons. However, for the group, the hearing outcome did correlate with the extent of the fistula and the initial hearing status. Postoperative anacusis occurred in all 6 ears in which the cholesteatoma matrix and granulation tissue invaded the membranous labyrinth. Anacusis also occurred in the ear with 2 fistulas involving the lateral SCC and promontory, despite leaving the matrix over the fistula site undisturbed and exteriorized. The preoperative hearing status correlated with operative findings and postoperative hearing outcome. Six of the 8 cases with a preoperative PTA-bone of more than 51 dB HL had postoperative anacusis in the affected ear. (In 5 of 6 the matrix and granulation tissue invaded the membranous labyrinth, and there were 2 fistulas in 1 ear.) Ears with a preoperative PTA-bone of less than 30 dB HL had either no change in bone conduction thresholds (69%) or slight worsening (31%), and none had anacusis postoperatively. The high incidence of postoperative anacusis in this series (8 of 31 patients with preoperative measurable hearing; 26%) as compared to the literature, therefore, may be explained by the number of ears with advanced disease. Eight had a preoperative PTA-bone of >51 dB HL, and 3 more patients had anacusis on presentation. On the other hand, the practice of routinely attempting to remove the cholesteatoma matrix in 1 stage even in the presence of extensive fistula might offer an alternate explanation as to the high incidence of postoperative anacusis. This is supported by the better hearing results reported by other authors, who advocate removing the cholesteatoma matrix in a planned second-stage procedure[6] or base their decision on the size and extent of the fistula.[14]

Ears with a positive fistula sign tend to have greater preoperative hearing loss and worse hearing outcome compared to those with a negative fistula test. This may correlate with the degree of labyrinthine involvement by the fistula. The presence of preoperative vestibular complaints, however, did not seem to correlate with hearing outcome.

Preoperative hearing loss is reversible in some ears with labyrinthine fistula caused by a cholesteatoma, especially in those with a PTA-bone of <30 dB HL, as seen in 3 ears in our series. This may be due to

resolution of a limited inflammatory response in the membranous labyrinth secondary to cholesteatoma.

CONCLUSION

The presence of vestibular symptoms, the results of the fistula sign, and imaging studies are not reliable for the preoperative diagnosis of a labyrinthine fistula. Hearing outcome correlated best with the extent of the fistula and the presence of granulation tissue invading the labyrinth, which was also predicted by the preoperative hearing status. I agree with the statement of Sheehy and Brackmann[8] that an extensive fistula of the labyrinth poses a considerable risk to the inner ear regardless of the operative procedure or method of management of the cholesteatoma matrix. However, it might be advisable to remove the cholesteatoma matrix in a planned second-stage procedure or exteriorize it with minimal manipulation in ears with 1 or more extensive and large fistulas.

ACKNOWLEDGMENT — I acknowledge the otology staff at the Massachusetts Eye and Ear Infirmary for allowing me access to their records and giving me guidance throughout the project.

REFERENCES

1. Palva T, Karja J, Palva A. Opening of the labyrinth during chronic ear surgery. Arch Otolaryngol 1971;93:75-8.

2. Sanna M, Zini C, Bacciu S, Scandellari R, Delogu P, Jemmi G. Management of the labyrinthine fistula in cholesteatoma surgery. ORL 1984;46:165-72.

3. Pfaltz CR. Complications of otitis media. ORL 1982;44:301-9.

4. Ostri B, Bak-Pedersen K. Surgical management of labyrinthine fistulae in chronic otitis media with cholesteatoma by a one-stage closed technique. ORL 1989;51:295-9.

5. Gormley PK. Surgical management of labyrinthine fistula with cholesteatoma. J Laryngol Otol 1986;100:1115-23.

6. Sanna M, Zini C, Gamoletti R, Taibah AK, Russo A, Scandellari R. Closed versus open technique in the management of labyrinthine fistulae. Am J Otol 1988;9:470-5.

7. Palva T, Ramsay H. Treatment of labyrinthine fistula. Arch Otolaryngol Head Neck Surg 1989;115:804-6.

8. Sheehy JL, Brackmann DE. Cholesteatoma surgery: management of the labyrinthine fistula. A report of 97 cases. Laryngoscope 1979;89:78-87.

9. McCabe BF. Labyrinthine fistula in chronic mastoiditis. Ann Otol Rhinol Laryngol [Suppl] 1984;93(suppl 112):138-41.

10. Bates GJEM, O'Donoghue GM, Anslow P, Houlding T. Can C.T. detect labyrinthine fistulae preoperatively? Acta Otolaryngol (Stockh) 1988;106:40-5.

11. O'Reilly BJ, Chevretton EB, Wylie I, et al. The value of CT scanning in chronic suppurative otitis media. J Laryngol Otol 1991;105:990-4.

12. Ritter FN. Chronic suppurative otitis media and the pathologic labyrinthine fistula. Laryngoscope 1970;80:1025-35.

13. Sheehy JL. Management of the labyrinthine fistula. Clin Otolaryngol 1978;3:405-14.

14. Gacek RR. The surgical management of labyrinthine fistulae in chronic otitis media with cholesteatoma. Ann Otol Rhinol Laryngol [Suppl] 1974;83(suppl 10).

ANTIBIOTICS IN CHRONIC SUPPURATIVE OTITIS MEDIA: A BACTERIOLOGIC STUDY

R. INDUDHARAN, MS(ENT), DIPNB(ORL)
KOTA SAMARAHAN, MALAYSIA

J. ASHRAFUL HAQ, MPHIL, PHD
KOTA BARU, MALAYSIA

SUBRAMANIA AIYAR, PHD
KOTA BARU, MALAYSIA

Conservative medical management of chronic suppurative otitis media (CSOM) is an important step in achieving a dry ear. Topical antibiotic ear drops and aural toilet form the mainstay of medical management of noncholesteatomatous CSOM. This study analyzes the causal organisms and their sensitivity to various antibiotics. Out of 382 swabs examined, the major organisms isolated were *Pseudomonas aeruginosa* (27.2%), followed by *Staphylococcus aureus* (23.6%). The sensitivity of *P aeruginosa* was 100% to ceftazidime, 98.9% to ciprofloxacin, 96.3% to gentamicin, and 95.4% to polymyxin B, whereas the sensitivity of *S aureus* was 98.6% to ciprofloxacin, 97.4% to cloxacillin sodium, 96.5% to cotrimoxazole, and 90.7% to gentamicin. *Pseudomonas aeruginosa* was almost completely resistant to ampicillin (97.6%) and chloramphenicol (96.6%), whereas *S aureus* was almost completely resistant to ampicillin (73.8%) and polymyxin B (98.3%). Among the available topical antibiotic preparations for use in the ear, we found that ciprofloxacin and gentamicin are the best choices.

KEY WORDS — antibiotics, bacteriology, chronic otitis media, ear drops, suppurative otitis media.

INTRODUCTION

Chronic suppurative otitis media (CSOM), a persistent and insidious disease, results from an interaction between local infection and the basic disease. It is still a significant health problem, especially in developing countries. Topical antibiotics and aural toilet are the mainstays of medical management of CSOM, which is essential in attaining a dry ear. Information regarding the common pathogens and their antibiotic sensitivities is essential for the proper choice of antibiotic ear drops. Information on the existing offending pathogens and their sensitivity patterns would also be invaluable in documenting changes in the "antibiogram" over time. We believe our data will contribute toward this end.

MATERIALS AND METHODS

All bacteriologic reports of middle ear swabs from patients clinically judged to have noncholesteatomatous CSOM over a period of 2 years (January 1994 to December 1995) were analyzed for causal organisms and antibiotic sensitivity patterns. The criteria for diagnosis of CSOM were 1) those patients without an intact tympanic membrane for more than 3 months and presenting with a history of ear discharge or 2) patients giving a history of 3 months or more of ear discharge and found to have a perforation of the tympanic membrane. Patients with cholesteatoma as revealed by otoscopic examination, patients with immune deficiency, and children with cleft palate were excluded. All specimens were collected with conventional sterile swabs and cultured for aerobic and anaerobic organisms according to standard procedures.[1] Antibiotic sensitivity was performed with the disc diffusion method[2] against 9 antibiotics commonly used in our hospital: ampicillin, ceftazidime, chloramphenicol, cloxacillin, cotrimoxazole, erythromycin, gentamicin, polymyxin B, and ciprofloxacin. The most common offending pathogens and their "antibiograms" were analyzed.

Microbiology. The middle ear swabs, transported in Stuart's transport medium, were inoculated immediately onto blood agar, chocolate agar, and MacConkey's agar. The plates were incubated aerobically at 37°C with a 5% carbon dioxide enrichment for the chocolate agar plates and examined at 24 and 48 hours. Anaerobic incubation was done with the Gas Pak system (Oxoid, United Kingdom). Culture plates were examined at 48-hour intervals. The organisms were identified by the Analytical Profile Index bacterial identification system (Biomerieux, France).

Antibiotic sensitivity was performed by the Kirby-Bauer disc diffusion method using commercially produced impregnated antimicrobial discs. Control sensitivity of known organisms was performed every week (*Escherichia coli* 25922 American Type Culture Collection [ATCC], *Staphylococcus aureus* 25923 ATCC, and *Pseudomonas aeruginosa* 27853

From the Departments of Otorhinolaryngology (Indudharan) and Microbiology (Haq, Aiyar), School of Medical Sciences, Universiti Sains Malaysia, Kota Bharu, Malaysia. A short-term research grant was provided by Universiti Sains Malaysia, Penang, Malaysia.

CORRESPONDENCE — R. Indudharan, MS(ENT), DipNB(ORL), Faculty of Medicine and Health Sciences, Universiti Malaysia Sarawak, 94300 Kota Samarahan, Sarawak, Malaysia.

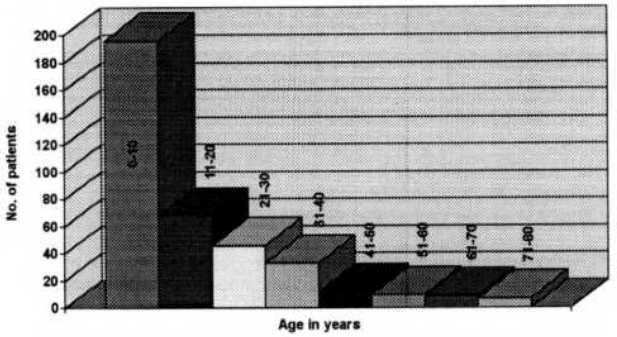

Fig 1. Age groups of patients with chronic suppurative otitis media.

ATCC). The zone sizes for various antibiotics were compared to standard zone sizes determined by the US Food and Drug Administration–National Committee for Clinical Laboratory Standards.

RESULTS

Out of a total of 382 middle ear samples from 381 patients (1 patient had bilateral active CSOM), bacteriologic isolation was possible from 370 (96.86%) samples. The patients were 6 months to 78 years old, with the majority being less than 20 years old (69.3%; SD 17.5; Fig 1). Single organisms were isolated from 253 samples, and multiple organisms from 117 samples. The organisms were 55.4% gram-negative and 44.6% gram-positive. Anaerobes formed an insignificant percentage (see Table).

Among the 500 isolates, *P aeruginosa* was the most common (27.2%), followed by *S aureus* (23.6%), *Staphylococcus epidermidis* (8.8%), *Proteus* sp (7.4%), ß-hemolytic *Streptococcus* (7%), *Haemophilus influenzae* (6.4%), *Enterobacter* (3.6%), *Klebsiella* (3.2%), and others (12.8%). The antibiogram for *P aeruginosa* showed that sensitivity was highest for ceftazidime (100%), gentamicin (96.3%), polymyxin B (95.4%), and ciprofloxacin (98.9%; Fig 2A). Resistance was high for ampicillin (97.6%) and chloramphenicol (96.6%). *Staphylococcus aureus* was found to be sensitive to chloramphenicol (85.7%), cloxacillin (97.4%), cotrimoxazole (96.5%), erythromycin (89.5%), gentamicin (90.7%), and ciprofloxacin (98.6%), whereas it was highly resistant to ampicillin (73.8%) and polymyxin B (98.3%; Fig 2A). Antibiograms for *S epidermidis*, ß-hemolytic *Streptococcus*, *H influenzae*, *Proteus* sp, *Klebsiella* sp, *Enterobacter* sp, and *Pseudomonas* sp, are shown in Fig 2B-D. Ciprofloxacin and gentamicin were also found to be effective against these organisms.

DISCUSSION

Most often, CSOM is the result of unresolved acute otitis media (AOM) and/or eustachian tube dysfunction.[3] The bacterial pathogens of CSOM and AOM vary widely. The most common organisms associated with CSOM are *P aeruginosa* and *S aureus*, whereas those associated with AOM are *Streptococcus pneumoniae*, *H influenzae*, and *Moraxella catarrhalis*. In this study, those patients without an intact tympanic membrane for more than 3 months and presenting with a history of ear discharge were considered to have CSOM, on the basis of previous standard classifications of CSOM.[4,5] It is important to distinguish between cholesteatomatous and noncholesteatomatous CSOM.

BACTERIAL ISOLATES FROM 382 EARS WITH CHRONIC SUPPURATIVE OTITIS MEDIA

Organisms	*No. of Isolates*
Aerobic organisms	
Gram-positive bacteria	
Staphylococcus aureus	118
Staphylococcus epidermidis	44
Group A, β-hemolytic streptococci	35
Streptococcus pneumoniae	8
Diphtheroids	8
Streptococcus viridans	3
Mixed growth of gram-positive organisms	2
Streptococcus milleri	1
Staphylococcus saprophyticus	1
Enterococcus	1
Gram-negative bacteria	
Pseudomonas aeruginosa	136
Proteus species	37
Haemophilus influenzae	32
Enterobacter species	18
Klebsiella species	16
Pseudomonas species	13
Acinetobacter species	11
Mixed growth of gram-negative organisms	6
Escherichia coli	3
Providentia species	2
Serratia marcescens	2
Anaerobic organisms	
Gram-positive bacteria	
Anaerobic streptococci	1
Clostridium species	1
Gram-negative bacteria	1

Criticisms have been aimed at the methods of collection of middle ear specimens. Recent studies advocate the use of an 18- or 24-gauge needle covered by a plastic cannula and a disposable syringe for aspiration of the middle ear specimen.[6-9] The disadvantages associated with this method[10] are 1) possible injury to the middle ear from the sharp and hard needle tip; 2) the beveled edge of the needle not being immersed in the middle ear discharge, as the space

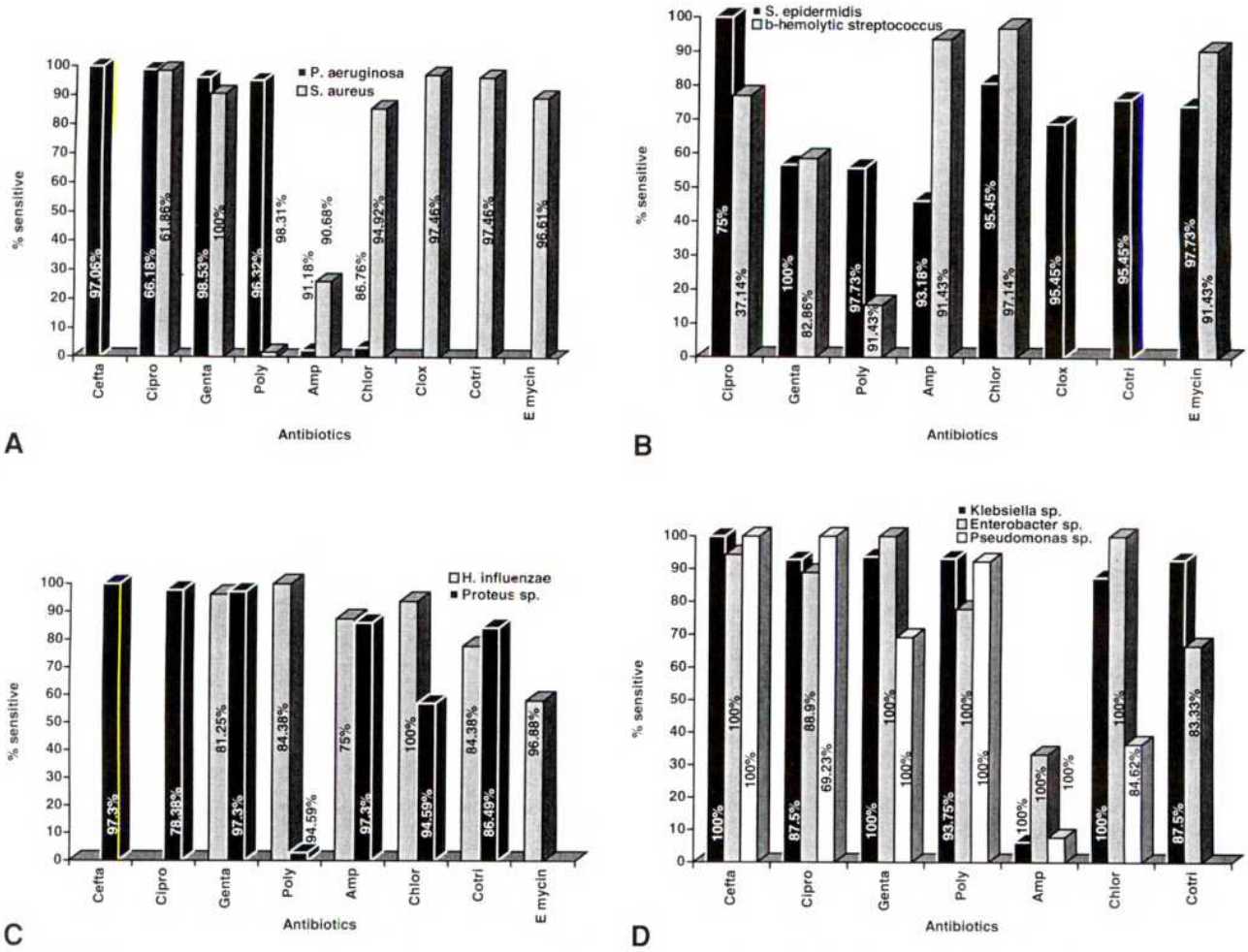

Fig 2. Diagram comparing "antibiograms" of organisms in chronic suppurative otitis media. Cefta — ceftazidime, Cipro — ciprofloxacin, Genta — gentamicin, Poly — polymyxin B, Amp — ampicillin, Chlor — chloramphenicol, Clox — cloxacillin, Cotri — cotrimoxazole, E mycin — erythromycin. Figure on bar of diagram shows percentage of isolated organisms tested for that particular antibiotic. A) *Pseudomonas aeruginosa* (n = 136) and *Staphylococcus aureus* (n = 118). B) ß-Hemolytic *Streptococcus* (n = 35) and *Staphylococcus epidermidis* (n = 44). C) *Haemophilus influenzae* (n = 32) and *Proteus* sp (n = 37). D) *Klebsiella* sp (n = 16), *Enterobacter* sp (n = 18), and *Pseudomonas* sp (n = 13).

in the mesotympanum is only 2 mm or less in depth, even in adults; 3) the middle ear discharge being inadequate to be aspirated into a syringe; and 4) air being aspirated into the needle, inhibiting the survival of anaerobes during the transportation and plating of the specimen for culture. Hence, we chose the conventional sterile swab for collection of middle ear specimens. Injury to the middle ear may be obviated to a certain extent by using a plastic cannula for aspiration, but the other disadvantages still remain. Further, it would be difficult to aspirate middle ear discharge, since a plastic cannula cannot be bent on the syringe, making it unsuitable for use under a microscope. A straight syringe and needle obstruct the view during aspiration under a microscope. The conventional orange stick swab also has the disadvantages of obstructing the view under a microscope, not obtaining an adequate sample due to the narrow external ear canal, especially in children, and yielding a poor anaerobe isolate due to air entrapment within the fibers of the cotton swab tip. Use of a prereduced 28-gauge Nichrome wire swab for collection of middle ear specimens for bacteriology in CSOM, reported by us previously, would eliminate these problems.[10]

This study agrees with previous reports that CSOM is predominantly a pseudomonal and/or staphylococcal disease. There seems to have been no remarkable change in the causal microbial flora for this disease in any part of the world. Our isolation rate of *Pseudomonas* is slightly lower (27.2%) than those in other reports. This difference may be partly due to the exclusion of cholesteatomatous cases from our study. Besides, inclusion of cases with perforation of more than 3 months (warranting the diagnosis of CSOM), but in which the ear discharge was acute, could also have contributed to a lower

pseudomonal isolation. *Pseudomonas* occurs mostly in cases of long-standing ear discharge. The inclusion of cases with a long-standing dry central perforation without infection under CSOM[4,5] needs review, since an acute onset of infection in such cases may have a different behavior than an unresolving discharging ear. Patients' recollection of the duration of ear discharge in active CSOM is also very unreliable, and we found the mean duration to be 103.3 weeks (SD 113.91) in a prospective study (unpublished data).

The role of anaerobes in CSOM, highlighted by others,[11,12] was not confirmed in our study. This may be a true geographic variation, or it may be attributed to the inclusion of noncholesteatomatous cases in our study. It should be stressed that cholesteatomatous cases are less common than noncholesteatomatous cases, probably due to improved health awareness and early surgical intervention for CSOM. Hence, antianaerobic therapy for CSOM[7] cannot be routinely employed for all cases of uncomplicated CSOM.

In uncomplicated cases, medical treatment of CSOM consists of topical antibiotic drops and aural toilet. There are only scant reports addressing the role of antibiotics that are topically effective in this disease. While *P aeruginosa*, the most common pathogen, is sensitive to ceftazidime, ciprofloxacin, gentamicin, and polymyxin B, and *S aureus*, the second most common pathogen, is sensitive to ciprofloxacin, gentamicin, chloramphenicol, cloxacillin, cotrimoxazole, and erythromycin, only ciprofloxacin, gentamicin, chloramphenicol, and polymyxin B are commercially available as topical preparations for use in the ear. *Pseudomonas aeruginosa* was almost completely resistant to ampicillin and chloramphenicol, whereas *S aureus* was highly resistant to ampicillin and polymyxin B. The majority of the remaining organisms were also highly sensitive to ciprofloxacin, gentamicin, and chloramphenicol (Fig 2B-D). However, chloramphenicol sensitivity is only 3.28% for *P aeruginosa*, the main pathogen. Hence, of the commonly available ear drops, chloramphenicol and polymyxin B are not effective in CSOM, leaving only ciprofloxacin and gentamicin for routine use. The high in vitro activity of the fluorinated quinolones against pathogens in CSOM has also been previously reported,[13] and since these quinolones are devoid of ototoxicity, they appear to be the best drugs for ototopical use. Dohar et al[14] reported that neomycin, when tested against polymyxin B, colistin, and norfloxacin, was found to be ineffective for use in CSOM. The same authors[15] have reported susceptibilities of 79% and 94%, respectively, for gentamicin and tobramycin, the 2 aminoglycosides available as topical preparations. The choice of empirical selection of ototopical agents can be based on such studies and may be influenced by the geographic distribution of organisms and their sensitivity. Among the aminoglycosides, only gentamicin is available for topical use in Malaysia, and prescription is restricted to consultants.[16] This may be another reason for the increased efficacy of gentamicin, a drug used with restriction (category A) even topically, resulting in reduced incidence of resistance. Our study suggests that ciprofloxacin, gentamicin, and ceftazidime are the best choices in cases in which active infection demands the use of a systemic antibiotic. Of the oral agents, the combination sulfamethoxazole-trimethoprim has been reported to be the most effective (46%) by Dohar et al.[15] As this drug is a nonpseudomonal antibiotic, we did not test its in vitro effectiveness against *Pseudomonas*. However, it was found to be highly effective against almost all other CSOM-associated microbes. If available, ciprofloxacin appears to be the drug of choice for oral administration.

In developing countries in which ciprofloxacin is not available as a topical preparation, gentamicin appears to be the alternative for routine use. We reaffirm our suggestion of efficacy of topical gentamicin in the treatment of CSOM without complications,[17] in agreement with other authors.[18] In a prospective randomized study[17] on the efficacy of a topical antibiotic versus an antibiotic-steroid combination in the management of CSOM, we found that 3-week treatments with gentamicin sulfate ear drops and gentamicin sulfate–betamethasone sodium phosphate combination ear drops produced clinical improvements (middle ear becoming dry) of 88.9% and 85.7%, and bacteriologic improvements (absence of microbial isolation from middle ear 1 week after stopping the topical antibiotic) of 69.4% and 60%, respectively.

Since ototoxicity has been demonstrated in laboratory animals after topical application of gentamicin and neomycin to the round window membrane and middle ear, it is usual to consider this danger when prescribing these drugs in patients with perforated tympanic membranes or tympanostomy tubes. However, in general, ototoxicity does not commonly occur in human subjects.[19,20] It must also be remembered that the ototoxicity of gentamicin in human subjects is mostly discussed with its systemic use. In animal models in which the ototoxicity of topical gentamicin has been studied, the middle ears were normal; hence, extrapolations from such studies to humans with CSOM were unsuitable.[18] Besides this evidence from clinical studies, the permeability of

the round window membrane, through which the ototoxic particles are believed to enter the inner ear when gentamicin is used topically, has also been questioned. Aminoglycosides are highly polar, poly-cation compounds of high molecular size. Thus, they cannot cross any epithelial membrane (including the round window membrane) unless there are gaps between the cells, as occurs in acute inflammation.[21,22] Most often, CSOM is so chronic and insidicus that the decrease in permeability of the round window membrane prevents penetration of harmful substances.[23,24] Structural studies in rats have shown that the round window membrane in purulent otitis media becomes 6 times as thick as that in controls.[25]

The recent experience in the treatment of Meniere's disease, in which the ototoxicity of intratympanic gentamicin is exploited for therapeutic purposes, should also be interpreted, keeping in mind that the middle ear in such cases is normal.[26,27] On the basis of these reports, we feel that the arguments for limitation of the use of topical gentamicin on the grounds of ototoxicity are mostly theoretical.

We conclude that *P aeruginosa* and *S aureus* continue to be the major offending pathogens in CSOM. Anaerobes appear to be insignificant in the causation of CSOM. In uncomplicated CSOM, ciprofloxacin is the best choice of ear drop for local treatment, followed by gentamicin. Over a 2-year period, there was no increase in antibiotic resistance among the major pathogens.

ACKNOWLEDGMENTS — The authors thank Nujaini Musa, Research Assistant, for secretarial assistance, and Dr Hla Yee Yee for encouragement and support.

REFERENCES

1. Finegold SM, Baron EJ. Infections of the head and neck. In: Carson DC, ed. Bailey and Scott's diagnostic microbiology. 7th ed. St Louis, Mo: CV Mosby, 1986:329-37.

2. Bauer AW, Kirby WMM, Sherris JC, Turck M. Antibiotic susceptibility testing by a standardized single disc method. Am J Clin Pathol 1966;45:493-6.

3. Bluestone CD, Klein JO. Otitis media, atelectasis and eustachian tube dysfunction. In: Bluestone CD, Stool SE, eds. Pediatric otolaryngology. Philadelphia, Pa: WB Saunders, 1990: 320-486.

4. Senturia BH, Bluestone CD, Klein JO, Lim DJ, Paradise JL. Report of the Ad Hoc Committee on Definition and Classification of Otitis Media and Otitis Media With Effusion. Ann Otol Rhinol Laryngol [Suppl] 1980;89(suppl 68):3-4.

5. Goycoolea MV, Hueb MM, Ruah C. Otitis media: the pathogenesis approach. Definitions and terminology. Otolaryngol Clin North Am 1991;24:757-61.

6. Papastavros T, Giamarellou H, Varledjides S. Obtaining specimens of discharge from the middle ear for cultures Laryngoscope 1985;95:1413-4.

7. Brook I. Management of chronic suppurative otitis media: superiority of therapy effective against anaerobic bacteria. Pediatr Infect Dis J 1994;12:355-6.

8. Erkan M, Aslan T, Sevük E, Güney E. Bacteriology of chronic suppurative otitis media. Ann Otol Rhinol Laryngol 1994;103:771-4.

9. Brook I, Santosa G. Microbiology of chronic suppurative otitis media in children in Surabaya, Indonesia. Int J Pediatr Otorhinolaryngol 1995;31:23-8.

10. Indudharan R, Haq JA. Use of pre-reduced swabs in bacteriology of chronic suppurative otitis media. J Laryngol Otol 1996;110:950-1.

11. Brook I. Chronic otitis media in children: microbiological studies. Am J Dis Child 1980;134:564-6.

12. Brook I. Aerobic and anaerobic bacteriology of cholesteatoma. Laryngoscope 1981;91:250-3.

13. Ikeda K, Takasaka T. In vitro activity of ototopical drops against middle ear pathogens. Am J Otol 1993;14:170-1.

14. Dohar JE, Kenna MA, Wadowsky RM. In vitro susceptibility of aural isolates of *Pseudomonas aeruginosa* to commonly used ototopical antibiotics. Am J Otol 1996;17:207-9.

15. Dohar JE, Kenna MA, Wadowsky RM. Therapeutic implications in the treatment of aural *Pseudomonas* infections based on in vitro susceptibility patterns. Arch Otolaryngol Head Neck Surg 1995;121:1022-5.

16. The Director General of Health, ed. List of drugs. Antiinfectives. 3rd ed. Kuala Lumpur, Malaysia: Ministry of Health, 1994:124.

17. Indudharan R, Haq JA, Mohamad H, Mohamad Z. Role of topical antibiotics versus antibiotic-steroid combination in the management of chronic suppurative otitis media. In: McCafferty G, Coman W, Carroll R, eds. XVI World Congress of Otorhinolaryngology, Head & Neck Surgery. Sydney '97. Vol 1. Bologna, Italy: Monduzzi Editore SpA, 1997:1153-7.

18. Browning GG, Gatehouse S, Calder IT. Medical management of active chronic otitis media: a controlled study. J Laryngol Otol 1988;102:491-5.

19. Merifield DO, Parker NJ, Nicholson NC. Therapeutic management of chronic suppurative otitis media with otic drops. Otolaryngol Head Neck Surg 1993;109:77-82.

20. Wong DL, Rutka JA. Do aminoglycoside otic preparations cause ototoxicity in the presence of tympanic membrane perforations? Otolaryngol Head Neck Surg 1997;116:404-10.

21. Chambers HF, Sande MA. Antimicrobial agents: the aminoglycosides. In: Hardman JG, Gilman AG, Limbird LE, eds. Goodman & Gilman's the pharmacological basis of therapeutics. 9th ed. New York, NY: McGraw-Hill, 1996:1103-21.

22. Engel F, Blatz R, Kellner J, Palmer M, Weller U, Bhadki S. Breakdown of the round window membrane permeability barrier evoked by streptolysin O: possible etiologic role in development of sensorineural hearing loss in acute otitis media. Infect Immun 1995;63:1305-10.

23. Ikeda K, Sakagami M, Morizono T, Juhn SK. Permeability of the round window membrane to middle-sized molecules in purulent otitis media. Arch Otolaryngol Head Neck Surg 1990;116:57-60.

24. Goycoolea MV, Muchow DC, Goycoolea HG. Otitis media: 16 years of pathogenesis approach. Otolaryngol Clin North Am 1991;24:967-80.

25. Johansson U, Hellström S, Anniko M. Round window membrane in serous and purulent otitis media. Structural study in the rat. Ann Otol Rhinol Laryngol 1993;102:227-35.

26. Rauch SD, Oas JG. Intratympanic gentamicin for treatment of intractable Meniere's disease: a preliminary report. Laryngoscope 1997;107:49-55.

27. Driscoll CL, Kasperbauer JL, Facer GW, Harner SG, Beatty CW. Low-dose intratympanic gentamicin and the treatment of Meniere's disease: preliminary results. Laryngoscope 1997;107:83-9.

≈

MIDDLE EAR MECHANICS

The Second International Symposium on Middle Ear Mechanics in Research and Otosurgery will be held October 21-24, 1999, in Boston, Massachusetts. For information, contact Harvard MED-CME, PO Box 825, Boston, MA 02117; telephone (617) 432-1525; web site http://www.med.harvard.edu/conted/.

≈

INTERNATIONAL MEETING ON OTOLOGY

The International Meeting on Otology of the Jean Causse Ear Clinic will be held June 5, 1999, in Béziers, France. For more information, please contact Robert Vincent, MD, Jean Causse Ear Clinic, Traverse de Béziers, 34440 Colombiers, France; telephone (33) 4-67-35-62-62; fax (33) 4-67-35-62-00.

TWENTY-FOUR–HOUR OSCILLATIONS OF FACIAL ELECTRONEUROGRAPHY PARAMETERS AND THEIR RELATIONSHIP TO BODY TEMPERATURE

ADRIAN PAZ, MD
PETAH-TIKVA, ISRAEL

YEHUDA KRONENBERG, MD
TEL-HASHOMER, ISRAEL

ISRAEL ASHKENAZI, PHD
TEL-AVIV, ISRAEL

The purpose of the present study was to assess the temporal variation of the facial electroneurography (ENoG) parameters recorded from the nasolabial crease and to compare it to the temporal oscillations of oral and facial cutaneous temperatures. Twelve healthy individuals were examined at 4-hour intervals for 2 consecutive days. Twenty-four-hour rhythms of oral and facial cutaneous temperatures were found in all subjects (troughs on average at 4:20 and 4:00 AM, respectively). Significant 24-hour oscillations of ENoG amplitude were found in all subjects, which were positively correlated to the oscillations of oral and facial cutaneous temperatures (trough on average at 2:40 AM). The compound action potential (CAP) latency fluctuated during the day and was negatively correlated with local temperatures. However, these fluctuations and correlations did not reach statistical significance. We also found a significant reduction of ENoG amplitude in 5 patients with artificial cooling of the face near the facial nerve. Also, there was a small increase in CAP latency with facial cooling. Interpreting ENoG recordings in accordance with oral temperature and recording time of day reduce the intertest variation.

KEY WORDS — amplitude, facial electroneurography, latency, temperature, temporal oscillations.

INTRODUCTION

Facial electroneurography (ENoG) represents the electrophysiological measurement of compound action potential (CAP), as elicited by the supramaximal stimulation of the facial nerve. It is regarded as a valuable method for quantitative assessment of facial nerve function.

When performed within 10 to 21 days after onset of facial nerve paralysis, ENoG is one of the most valuable tests for the prognostic evaluation of Ramsay Hunt syndrome[1] and Bell's palsy.[2,3] When ENoG is performed 1 week after the appearance of a complete facial paralysis resulting from temporal bone fractures, iatrogenic trauma,[4] or surgical removal of acoustic neuromas,[5] it is a good predictor of the final facial outcome. It was also found to be helpful in the preoperative identification of subclinical degeneration of the facial nerve associated with acoustic neuromas[6] and for intraoperative facial nerve monitoring in acoustic neuroma surgery.[7]

The large intertest variability of ENoG[2,8] may diminish its utility. This variability may result from temporal fluctuations, which may be associated with other physiologic rhythms such as that of temperature. Rhythmic oscillations have been defined for many physiological parameters, for example, blood pressure, body temperature, plasma concentration of many hormones, and urinary secretion of different electrolytes.[9]

Twenty-four–hour variations of the latency of brain stem responses[10] and of synapse excitability of the central nervous system[11] have already been reported. However, to our knowledge the 24-hour oscillations of the facial evoked responses have never been investigated. It was also shown that an increase in body temperature has a stimulatory effect on neuronal conduction[12] and increases the amplitude of brain stem auditory evoked responses.[13]

We presumed that by correlating the results of CAP measurement to recordings of the time of day and oral or facial cutaneous temperature, the error due to intertest variance might be reduced and a better standardization of the ENoG would be obtained. The present study was designed to measure the temporal pattern of the facial CAP recorded by serial ENoG in 12 healthy individuals, and to compare it to natural and artificial variations of local temperature.

MATERIALS AND METHODS

Twelve healthy young subjects, 8 men and 4 women, with ages ranging from 17 to 42 years (mean

From the Department of Genetics, Sackler Faculty of Medicine, Tel-Aviv University, Tel-Aviv (Paz, Ashkenazi), and the Otorhinolaryngology Institute, Tel-Hashomer Medical Center, Tel-Hashomer (Kronenberg), Israel.

CORRESPONDENCE — Adrian Paz, MD, 25 Volfson St, Petah-Tikva, 49541, Israel.

29 years) were examined. Each participant received an initial thorough physical examination, including an otolaryngological evaluation. The individuals were exposed to the same environment and the same sleep-wake cycle (alert between 8:00 AM and 10:00 PM and asleep between 10:00 PM and 8:00 AM). The subjects were examined during the same time period. External influences were minimized by having the subjects spend most of their waking hours in a quiet environment.

All examinations were performed by the same person at 4-hour intervals for 2 consecutive days. At each session, the examination order of the subjects was random. Informed consent was obtained from each subject after the nature of the procedures had been fully explained to him or her.

Temperature Recording. Oral temperature was recorded from each oral vestibule with a temperature probe. The skin temperature was recorded with a cutaneous probe placed on the cheek near the stylomastoid foramen. Cooling of the cheek was performed in 5 patients at approximately 4:00 PM in order to assess the influence of temperature variation on ENoG parameters. The cooling was performed with a water-filled plastic bag at 4°C pressed against the face for 1 minute. The ENoG and oral and facial cutaneous temperature were recorded before and immediately after cooling. The temperatures were measured to within 0.1°C and were recorded before and after recording of the CAP waves. The correlations are based on the average temperature reading for each session.

Stimulation. The facial nerve was stimulated with a surface electrode, with the anode just outside the stylomastoid foramen and the cathode in front of the earlobe. The skin resistance was reduced by maintaining sufficient pressure on the electrodes and by using a lubricant gel. Stimulus pulses with a duration of 0.2 millisecond and a maximal intensity of 30 mA were delivered at a manually chosen frequency, at least 15 times consecutively. The stimulating electrode was manipulated to achieve the maximal CAP amplitude, and the optimal position was marked and used in all subsequent studies. Routinely, the stimulus intensity was increased until supramaximal stimulation was achieved (25% above that producing maximal CAP). However, with the occurrence of pain or trigeminal stimulus artifact, the voltage was reduced to avoid these untoward effects.

Positioning of Recording Electrodes. For recording, self-adhesive silver electrodes 5 mm in diameter were used. The skin resistance was reduced by rubbing with an abrasive solution, and thereafter, the electrodes were attached. The glabella was chosen as the site of the reference electrode.

The nasolabial crease was the most convenient position for placing the recording electrode, yielding action potentials marked by a smooth biphasic wave, invariant with minor changes of the electrode position. The optimal position was chosen and marked for further use on the following trials. The interelectrode impedance was checked before each trial and kept below 5 kilo-ohms.

Compound Action Potential Recording. The patient was seated comfortably in a reclining chair. Recording was performed with a Nicolet electroneurograph, implemented with a digital Butterworth filter. First, the left side was investigated, then the right. The 6 optimal CAP waves were recorded on each side.

Parameters Computed. The latency was measured between the stimulation artifact and the beginning of the first deflection of the response, at the standard gain (1 mV/cm), and therefore only the conduction time of the fastest axons was measured. The peak-to-peak amplitude, measuring the height of the positive deflection peak relative to the peak of the negative one, was next computed. The CAP amplitude's side-to-side difference was calculated. This was expressed as the percentual difference relative to the higher value.

Statistical Methods. The values of ENoG parameters and of oral and facial cutaneous temperature were analyzed by the multiple regression method, using the cosine ($\cos[t \times \pi \times 2/24]$) and sine ($\sin[t \times \pi \times 2/24]$) transformations of the time of day (t), as independent variables. Also, the correlations between the ENoG parameters and oral and facial cutaneous temperatures were computed. In addition, the recorded data of each of the ENoG parameters were analyzed by ANOVA. The analysis was carried out with the Statistix II programs on an IBM-PC computer.

RESULTS

Twenty-four–hour rhythms of oral and facial cutaneous temperatures were found in all patients, and their troughs occurred during the night (average 4:20 AM and 4:00 AM, respectively). No significant differences were found between the computed 24-hour rhythms of ENoG parameters recorded from the left and right sides ($p = .45$). Consequently, the parameters recorded from the 2 sides were pooled. Significant 24-hour oscillations of the CAP amplitude were found in all individuals (Table 1 and Fig 1). Most of the individually computed rhythm troughs fell dur-

TABLE 1. RHYTHM PARAMETERS OF CAP AMPLITUDE AND CORRELATIONS TO ORAL TEMPERATURE

Subject	*Mean CAP Amplitude (mV)*	*Oscillation of Amplitude (mV; mean ± SE)*	*Trough of Oscillation (hour value; mean ± SE)*	*Correlation With Oral Temperature (r)**
1	1.99	0.30 ± 0.03	0420 ± 0034	.74
2	1.21	0.20 ± 0.03	0521 ± 0059	.78
3	0.93	0.11 ± 0.01	0744 ± 0047	.84
4	2.97	0.44 ± 0.03	0136 ± 0038	.95
5	1.59	0.23 ± 0.03	0035 ± 0019	.75
6	3.73	0.50 ± 0.04	0647 ± 0032	.90
7	1.15	0.17 ± 0.02	0005 ± 0056	.72
8	0.49	0.08 ± 0.01	2343 ± 0146	.87
9	2.04	0.31 ± 0.02	1523 ± 0031	.78
10	1.86	0.33 ± 0.04	0435 ± 0053	.84
11	1.63	0.27 ± 0.04	0623 ± 0047	.80
12	1.71	0.32 ± 0.04	0316 ± 0025	.91

Hour values are on 24-hour basis.
CAP — compound action potential.
*For all, $p < .001$.

ing the night, and their values approximated 2:40 AM (Table 1 and Fig 2). A statistically significant positive correlation between CAP amplitude and oral and facial cutaneous temperatures was found (overall $r = +.76$ and $r = +.82$, respectively $p < .001$; Fig 3). Only 3 of the 12 individuals exhibited significant circadian oscillations of the latency. Overall, there was no statistically significant CAP latency rhythm ($p = .07$; Fig 2), although there was a negative correlation between CAP latency and oral ($r = -.61$, $p = .08$) and facial cutaneous temperatures ($r = -.63$, $p = .07$; Table 2). However, the accurate calculation of latency was hindered by the smoothness of the upward deflection of some CAP waves. In these cases, the beginning of the wave could not be determined accurately. In order to test the effect of local temperature variations on ENoG parameters, we cooled the faces of 5 patients with a plastic bag filled with cold water (4°C) and performed ENoG before and after cooling. The CAP amplitude was reduced on average by 26.8%, and CAP latency increased on average by 9% (Fig 4). On average, the facial cutaneous temperature dropped from 31.8°C to 21.7°C, and the oral temperature dropped from 36.2°C to 34.3°C (Fig 4). There was a +.79 and +.85 correlation between CAP amplitude and oral and facial cutaneous temperatures, respectively ($p < .001$). There was a negative correlation between CAP latency and oral ($r = -.53$, $p = .1$) and facial cutaneous temperatures ($r = -.58$, $p = .08$).

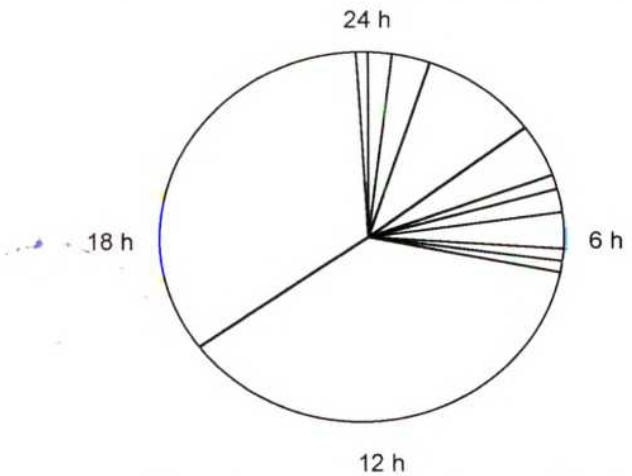

Fig 1. Timing of compound action potential (CAP) amplitude rhythm troughs in 12 healthy subjects.

A mean side-to-side CAP amplitude variation of 7% was found. There was no significant variation of this parameter during the day ($p = .36$), and there was no correlation between it and the fluctuations of oral ($r = .13$, $p = .48$) or facial cutaneous temperature ($r = .17$, $p = .42$). The test-retest variability was 28%. However, the mean test-retest variability between CAP amplitudes recorded at the same time of day was only 8.3%. The variation was reduced to 4.5% and 3.8% when the results were adjusted also for oral or facial cutaneous temperature fluctuations. The individual amplitude mean ranged between 3.93 and 0.51 mV (average 2.09 mV). The individual latency mean ranged between 3.01 and 4.17 milliseconds (average 3.35 milliseconds).

DISCUSSION

The aim of the present work was to reduce the error due to test-retest variance of the CAPs recorded by ENoG. We determined the 24-hour oscillations of its parameters and adjusted the results by the value of the local temperature.

Significant circadian oscillations of the CAP am-

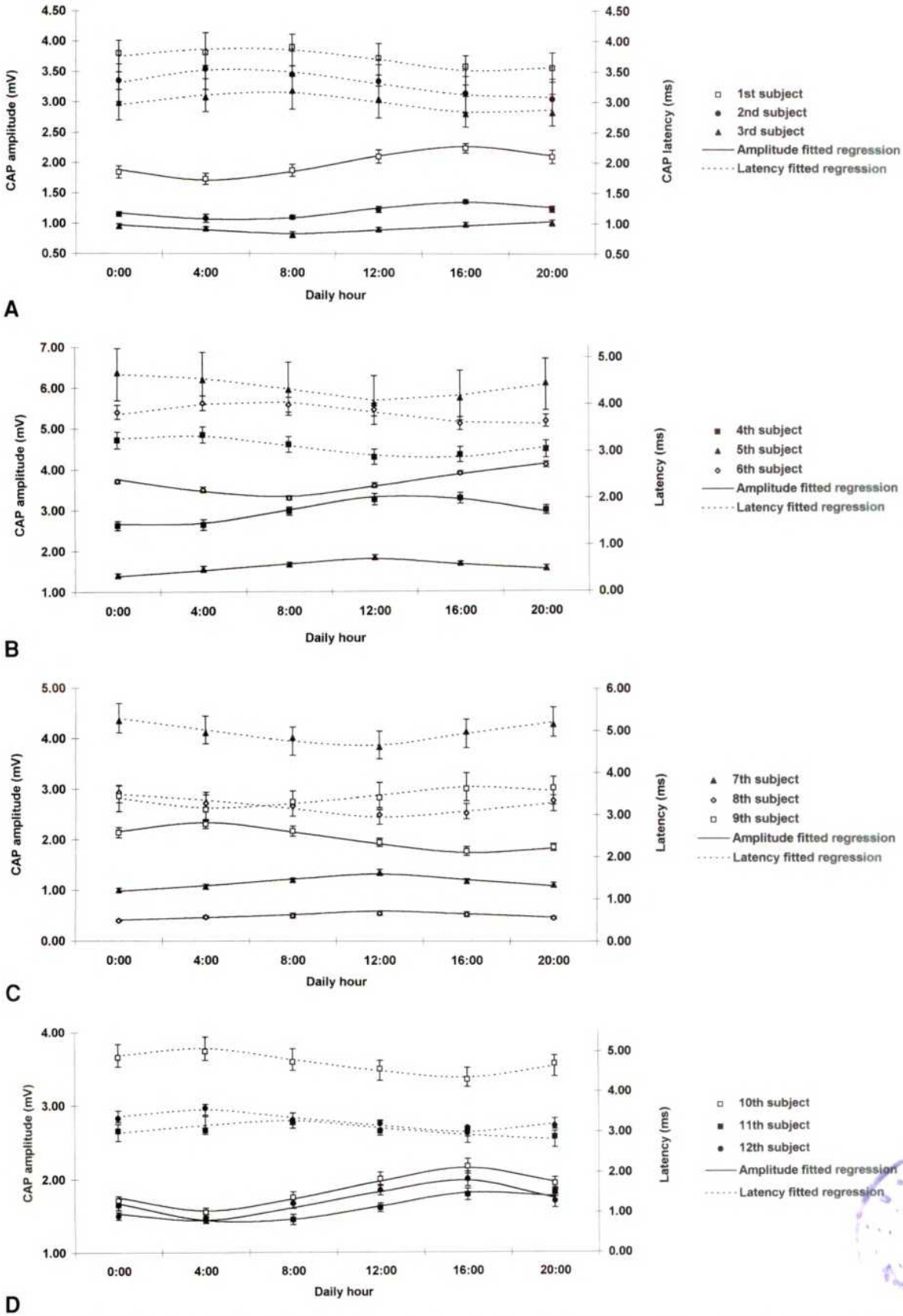

Fig 2. Twenty-four-hour oscillations of CAP amplitude and latency. Depicted are mean, range, and fitted regressions of CAP amplitude and latency recordings in 12 healthy subjects at various times of day (daily hour). Examinees were subjected to same environment and same sleep-wake cycle. A) Subjects 1-3. B) Subjects 4-6. C) Subjects 7-9. D) Subjects 10-12.

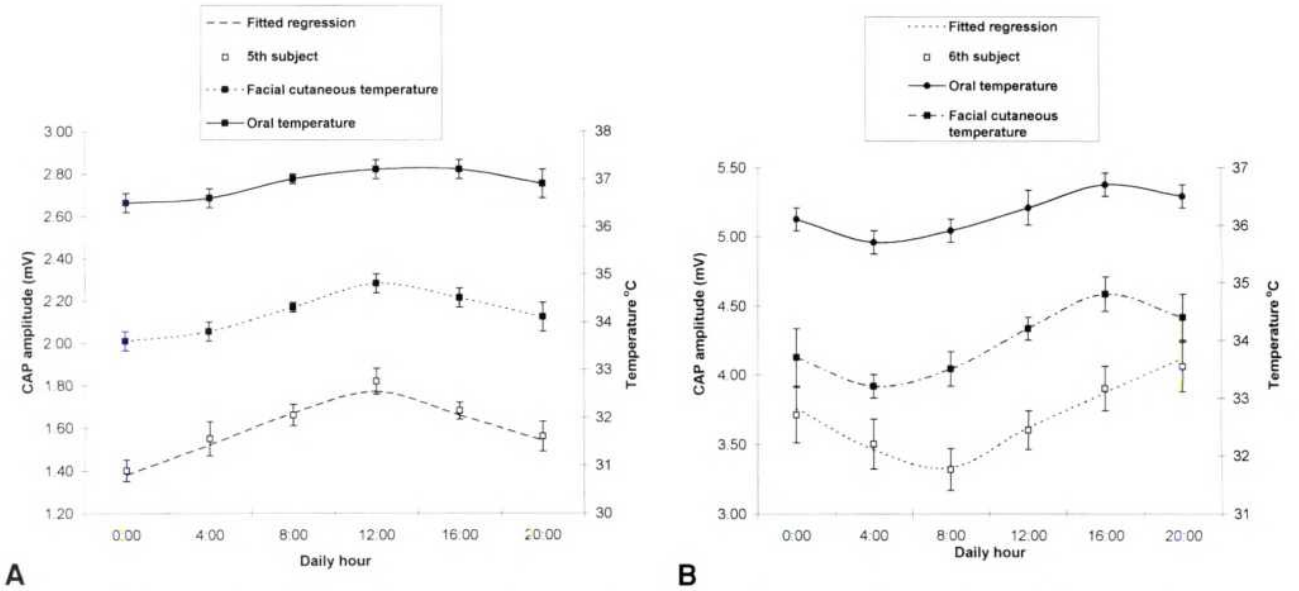

Fig 3. Mean, range, and fitted regressions of CAP amplitude and local temperature of A) subject 5 and B) subject 6 are depicted as function of time of day. CAP and temperature values are shown together on same graph to illustrate positive correlation between these parameters. These 2 subjects were chosen randomly to illustrate this correlation, which was found in all subjects.

plitude, describing a trough on average at 2:40 AM, were delineated in all subjects (Table 1 and Fig 1). In 11 of the 12 subjects, the rhythm trough fell during the night, between midnight and 8:00 AM (Fig 2). The fitted regressions and the temporal rhythm of oral or facial cutaneous temperature explained a large percentage of the variance (68%, 42%, and 49%, respectively). We also tested in 5 subjects the effect of an artificial reduction of local temperature near the facial nerve on ENoG parameters. With cooling, there was a significant reduction of CAP amplitude (29%). In these cases, CAP amplitude positively correlated with local temperature ($r = .68$ and $r = .74$ for oral temperature and for facial cutaneous temperature, respectively). The latency's rhythm proved to be inconsistent. The negative correlation between CAP latency and temperature did not reach statistical significance. We speculate that this loose correlation results from a significant error in determining the beginning of the upward deflection of the CAP wave and in calculating the latency, due to smoothness of some of the CAP waves. It seems that the reported variable accuracy of ENoG might be explained by variations in daily time of recording and local temperature fluctuations. The low test-retest variability of CAP amplitudes measured at the same time of day and adjusted for local temperature may justify this assertion.

TABLE 2. RHYTHM PARAMETERS OF CAP LATENCY AND CORRELATIONS TO ORAL TEMPERATURE

Subject	*Mean CAP Latency (ms)*	*Oscillation of Latency (ms; mean ± SE)*	*Trough of Oscillation (hour value; mean ± SE)*	*Correlation With Oral Temperature (r)*
1	3.72	0.51 ± 0.12	1710 ± 0120	.57
2	3.28	0.63 ± 0.15	1735 ± 0133	.62
3	2.97	0.48 ± 0.12	1837 ± 0156	.65
4	3.10	0.60 ± 0.08	1431 ± 0045	.77*
5	4.37	0.75 ± 0.25	1300 ± 0045	.52
6	3.82	0.66 ± 0.07	1818 ± 0052	.74*
7	4.97	0.83 ± 0.16	1024 ± 0134	.59
8	3.21	0.60 ± 0.08	1242 ± 0037	.62
9	3.42	0.62 ± 0.15	0510 ± 0112	.59
10	4.72	0.86 ± 0.12	1515 ± 0055	.65
11	3.05	0.53 ± 0.08	1917 ± 0110	.66
12	3.28	0.58 ± 0.05	1545 ± 0030	.79*

Hour values are on 24-hour basis.

CAP — compound action potential.

*$p < .001$.

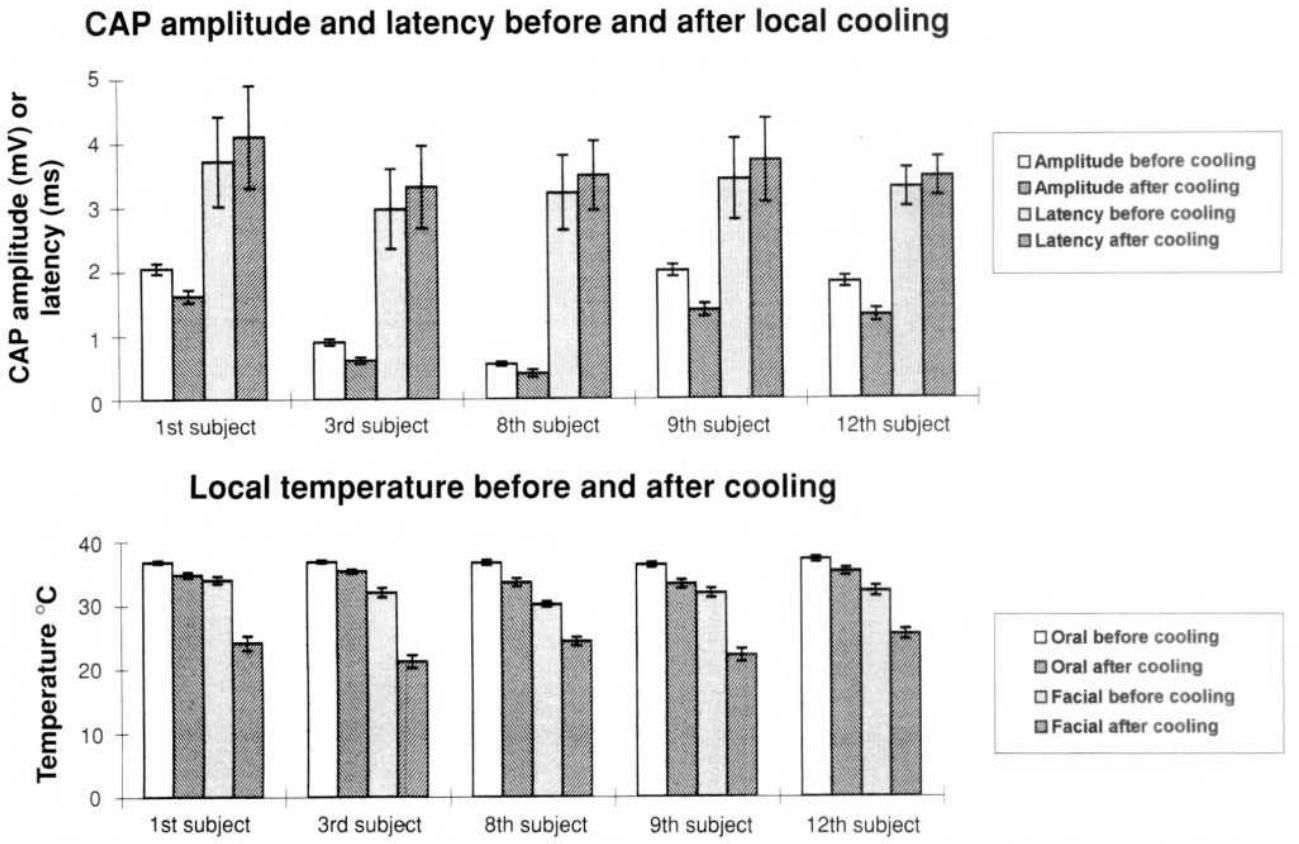

Fig 4. CAP amplitude and latency changes with artificial cooling of face in 5 subjects. Mean and range of CAP amplitude, latency, and oral and facial cutaneous temperatures are shown before and after cooling.

It was shown that reductions in body temperature slow neural transmission time[12] and reduce the amplitude of summation potentials.[13] Therefore, besides the influence of local temperature, body temperature oscillations may indirectly influence CAP amplitude through a systemic effect on neural excitability.

The inconsistency of the test-retest results of ENoG reduces its reliability. In our study, the positions of the stimulating and recording electrodes were marked and were kept constant during the experiment. The intertest variations due to stimulus and recording techniques are random regarding the time of day and could not account for the definite temporal rhythm we encountered. The large number of CAP recordings in each patient resulted in a random variation, which was an order of magnitude smaller than that due to temporal rhythm and temperature oscillations. Adour et al[14] found a test-retest difference of 16% in a group of 33 adults. Raslan et al[8] and Kartush et al[15] reported intertest errors of 20.7% and 19.5%, respectively. However, Gavilan et al[16] reported a test-retest variability of only 3.15%, and Silverstein et al[17] reported an average day-to-day variation of 3%.

Coker,[18] by using a generalizability analysis, found that the largest source of error stems from the inconstancy of results from one test period to another. He concluded that this observation supports the use of averaged ENoG results of repeated tests at the same point in time.

Silverstein et al[17] reported a mean side-to-side CAP amplitude variation of 5.4%, using a standardized recording lead placement on the nose. With a technique of "optimized recording lead placement" in the nasolabial fold, Thomander and Stalberg[19] found an amplitude asymmetry of 5.7%. Gavilan et al[16] found no significant differences between the mean CAP amplitudes recorded from the right side of the face and those recorded from the left side. Accordingly, we found an amplitude asymmetry of 7%, which was not statistically significant. The side-to-side amplitude percentual difference, which is a ratio of CAP values on both sides of the face, did not fluctuate significantly over the course of the day. This constancy results from similar fluctuations over time of ENoG parameters on both sides of the face. However, these results are pertinent to healthy subjects. The results may be different when there is impairment of the facial nerve by an inflammatory or traumatic process. Such situations deserve further study of the fluctuation over time of the side-to-side percentual differences.

The increase in CAP amplitude and reduction of latency with increase in temperature may be explained by studies of axonal action potential at different temperatures. Physiological studies of single axon preparations showed that there is a strong temperature dependency of axonal membrane ionic conductance. With increasing temperature, there is an increase in voltage-sensitive sodium channel conductance that results in increased action potentials. Moreover, with increasing temperature, the latency of action potentials shortens.[20]

CONCLUSIONS

We found 24-hour oscillations of CAP amplitude and a positive correlation between them and local temperature. There was also a significant reduction of CAP amplitude with artificial cooling of the face and a minimal increase in latency. There was a negative correlation, albeit not statistically significant, between latency and local temperature fluctuations.

REFERENCES

1. Kanzaki J. Electrodiagnostic findings in the early stages of Bell's palsy and Ramsay-Hunt's syndrome. Acta Otolaryngol Suppl (Stockh) 1988(suppl 446):42-6.

2. May M, Klein SR, Blumenthal F. Evoked electromyography and idiopathic facial paralysis. Otolaryngol Head Neck Surg 1983;91:678-85.

3. Tojima H, Aoyagi M, Inamura H, Koike Y. Clinical advantages of electroneurography in patients with Bell's palsy within two weeks after onset. Acta Otolaryngol Suppl (Stockh) 1994(suppl 511):147-9.

4. Fisch U. Prognostic value of electrical tests in acute facial paralysis. Am J Otol 1984;5:494-8.

5. Hardy DG, MacFarlane R, Baguley D, Moffat DA. Surgery for acoustic neurinoma. An analysis of 100 translabyrinthine operations. J Neurosurg 1989;71:799-804.

6. Kartush JM, Niparko JK, Graham MD, Kemink JL. Electroneurography: preoperative facial nerve assessment for tumors of the temporal bone. Otolaryngol Head Neck Surg 1987; 97:257-61.

7. Silverstein H, Rosenberg SI, Flanzer J, Seidman MD. Intraoperative facial nerve monitoring in acoustic neuroma surgery. Am J Otol 1993;14:524-32.

8. Raslan WF, Wiet R, Zealear DL. A statistical study of ENoG test error. Laryngoscope 1988;98:891-3.

9. Moore-Ede MC. Physiology of circadian timing system: predictive versus reactive homeostasis. Am J Physiol 1986;250 (suppl):R737-R752.

10. Marshall NK, Donchin E. Circadian variation in the latency of brain-stem responses and its relation to body temperature. Science 1981;212:356-8.

11. Barnes CA, McNaughton BL, Goddard GV, Douglas RM, Adamec R. Circadian rhythm of synaptic excitability in rat and monkey central nervous system. Science 1977;197:91-2.

12. Campbell WW, Robinson LR. Deriving reference values in electrodiagnostic medicine. Muscle Nerve 1993;16:424-8.

13. Rodriguez RA, Audenaert SM, Austin EH 3rd, Edmonds HL Jr. Auditory evoked responses in children during hypothermic cardiopulmonary bypass: report of cases. J Clin Neurophysiol 1995;12:168-76.

14. Adour KK, Sheldon MI, Kahn ZM. Maximal nerve excitability testing versus neuromyography: prognostic value in patients with facial paralysis. Laryngoscope 1980;90:1540-7.

15. Kartush JM, Lilly DJ, Kemink JL. Facial electroneurography: clinical and experimental investigations. Otolaryngol Head Neck Surg 1985;93:516-23.

16. Gavilan J, Gavilan C, Sarria MJ. Facial electroneurography: results on normal humans. J Laryngol Otol 1985;99: 1085-8.

17. Silverstein H, McDaniel AB, Hyman SM. Evoked serial electromyography in the evaluation of the paralyzed face. Am J Otol 1985(Nov suppl):80-7.

18. Coker NJ. Facial electroneurography: analysis of techniques and correlation with degenerating motoneurons. Laryngoscope 1992;102:747-59.

19. Thomander L, Stalberg E. Electroneurography in the prognostication of Bell's palsy. Acta Otolaryngol (Stockh) 1981; 92:221-37.

20. Guttman R, Hachmeister L. Effect of calcium, temperature, and polarizing currents upon alternating current excitation of space-clamped squid axons. J Gen Physiol 1971;58:304-21.

EFFECT OF PLATELET ACTIVATING FACTOR AND ITS ANTAGONIST ON THE MUCOCILIARY CLEARANCE OF THE EUSTACHIAN TUBE IN GUINEA PIGS

CHUNG-KU RHEE, MD, PHD
CHEONAN, KOREA

PIL-SEOB JEONG, MD, PHD
CHEONAN, KOREA

YOUNG-HOON KIM, MD
CHEONAN, KOREA

PHIL-SANG CHUNG, MD, PHD
CHEONAN, KOREA

TIMOTHY T. K. JUNG, MD, PHD
LOMA LINDA, CALIFORNIA

The purpose of this study was to test whether platelet activating factor (PAF) impairs the mucociliary clearance function of the eustachian tube (ET) in a dose-dependent manner and whether PAF antagonist can prevent the impairment of mucociliary function of the ET induced by PAF. Coomassie brilliant blue dye transport time (DTT) in normal guinea pigs was 69 seconds. The DTTs after the application of normal saline and PAF at 1 and 2 μg/mL into bullae were 66, 74, and 157 seconds. The time was over 15 minutes when 4, 8, and 16 μg/mL of PAF were applied. The DTT was 62 seconds when the animals were pretreated with PAF antagonist (WEB 2170). There were significant delays of the DTTs after treatment with 2, 4, 8, and 16 μg/mL of PAF. Histopathologic examination of ETs from groups with a significant delay in DTTs showed intact cilia, mucous plugs, increased inflammatory cells, and exfoliation of cells. This study demonstrated that PAF impaired the mucociliary clearance function of the ET in a dose-dependent manner. This impairment of mucociliary clearance function was prevented by pretreatment with PAF antagonist. The findings of the study suggest that PAF plays an important role in the pathogenesis of otitis media with effusion by impairing the ET clearance function.

KEY WORDS — eustachian tube, mucociliary clearance, otitis media, platelet activating factor.

INTRODUCTION

When inflammatory mediators are released in the middle ear (ME) by viral or bacterial infection, allergy, or eustachian tube (ET) dysfunction, they seem to play a major role in the pathogenesis of otitis media with effusion (OME). Studies have also implicated platelet activating factor (PAF) in the pathogenesis of OME, in addition to other inflammatory mediators such as prostaglandins and leukotrienes.[1] Platelet activating factor is known to have wide-ranging effects on a number of tissues and inflammatory cells.[2] Since the early 1970s, many studies have demonstrated that PAF may play an important role in acute inflammation and allergy. Platelet activating factor is released from human neutrophils, platelets, eosinophils, macrophages, mast cells, and vascular endothelial cells.[2] Its activities include induction of microvascular leakage, chemotaxis, bronchoconstriction, increased bronchial hyperresponsiveness, increased airway mucus secretion, and induction of hypotension, shock, and death.[2] Platelet activating factor has induced ciliary dysfunction and epithelial damage of human paranasal sinus mucosa in vitro.[3] Platelet activating factor has been suggested to affect ET function by decreasing microcirculation of the tubal orifice and increasing the opening pressure of the ET.[4,5] It has been suggested that disruption of the mucociliary system leads to the development of fluid in the ME (ME effusion; MEE), and continued dysfunction of the mucociliary apparatus in the ME and ET may be responsible, in part, for the chronicity of these effusions.[6] Levels of PAF in samples of human MEE have been reported to be in the range of 5.5 μg/mL in purulent otitis media, 7.6 μg/mL in mucoid otitis media, and 31.5 μg/mL in serous otitis media.[7]

A PAF antagonist (WEB-2170) has been studied extensively and is well proven for its inhibitory effects against various PAF actions, including its inhibitory action against PAF-induced OME.[1] The purpose of this study was 1) to test the hypothesis that PAF impairs the mucociliary function of the ET in a

From the Department of Otolaryngology–Head and Neck Surgery, Dankook University College of Medicine, Cheonan, Korea (Rhee, Jeong, Kim, Chung), and the Department of Surgery, Division of Otolaryngology–Head and Neck Surgery, Loma Linda University School of Medicine, Loma Linda, California (Jung). This study was supported by research funds from Dankook University and the Korea Institute of Science and Technology. This study was performed in accordance with the PHS Policy on Humane Care and Use of Laboratory Animals, the NIH *Guide for the Care and Use of Laboratory Animals*, and the Animal Welfare Act (7 U.S.C. et seq.); the animal use protocol was approved by the Institutional Animal Care and Use Commitee (IACUC) of Dankook University.

CORRESPONDENCE — Chung-Ku Rhee, MD, PhD, Dept of Otolaryngology–Head and Neck Surgery, Dankook University College of Medicine, 29 Anseo-Dong, Cheonan, Choongnam-Do, 330-714 Korea.

TABLE 1. EXPERIMENTAL GROUPS

Groups	*Agents in Bullae*	*Intraperitoneal Injection*
Normal saline control group	Normal saline	
1-μg Group	PAF 1 μg/mL	
2-μg Group	PAF 2 μg/mL	
4-μg Group	PAF 4 μg/mL	
8-μg Group	PAF 8 μg/mL	
16-μg Group	PAF 16 μg/mL	
PAF antagonist group	PAF 2 μg/mL	PAF antagonist (WEB-2170)

PAF — platelet activating factor.

dose-dependent manner, and 2) to test whether PAF antagonists can prevent impairment of mucociliary function of the ET induced by PAF.

MATERIALS AND METHODS

Experimental Animals. Healthy adult guinea pigs (300 to 350 g), free of ME infection as determined by otomicroscopy, were used. A total of 78 ears (from 39 animals) were tested. An average baseline dye transport time (DTT) with 5.0% Coomassie brilliant blue dye (CBB, Sigma Chemical Co, St Louis, Mo) was established in 8 ears. Thirty-five animals (a total of 70 ears) were randomly assigned to 7 groups (10 ears from 5 animals in each group): 1) a normal saline (NS) control group, injected with NS into bilateral bullae, 2) a 1-μg group, injected with 1 μg/mL of PAF (Sigma Chemical Co), 3) a 2-μg group, injected with 2 μg/mL of PAF, 4) a 4-μg group, injected with 4 μg/mL of PAF, 5) an 8-μg group, injected with 8 μg/mL of PAF, 6) a 16-μg group, injected with 16 μg/mL of PAF, and 7) a PAF antagonist group, pretreated with PAF antagonist (WEB-2170, Boehringer Ingelheim, Germany) and injected with 2 μg/mL of PAF.

Assessment of Dye Transport. All operations were performed under anesthesia with ketamine (30 mg/kg) and xylazine hydrochloride (2 mg/kg).

Experiment 1 (Normal Dye Transport Time). The anesthetized animals were placed in a prone position, and the postauricular area was infiltrated with 1% Xylocaine to reinforce the anesthesia. Postauricular incisions were carried out, and the posterior tips of the bullae were exposed. The bullae were punctured in order to allow a 23-gauge hypodermic needle to pass through and to allow any excess air to exit. Animals were then placed in a supine position to expose their palates under microscopy. The soft palates were incised to visualize the nasopharyngeal orifices of the ET. The animals were placed back in the prone position, and 0.15 mL of CBB dye was injected into the bullae. The time required for the dye to begin to appear at the nasopharyngeal orifice of the ET was recorded.

Experiment 2 (Control and PAF Groups). The bullae and the nasopharyngeal orifices of the ET were exposed by the same method as in experiment 1 (Table 1). In the control group, 0.2 mL of NS was injected into bilateral bullae. Fifteen minutes later, 0.15 mL of 5% CBB was injected into the same bullae, and the time required for the dye to just become visible at the nasopharyngeal orifices of the ET was recorded as the transport time for the control group. In the PAF groups, 1, 2, 4, 8, or 16 μg/mL of PAF in 0.2 mL of NS was injected into the bilateral bullae of each animal. The DTT was measured with 5% CBB in the same manner as in the control group.

Experiment 3 (PAF Antagonist Group). The animals were pretreated with an intraperitoneal injection of PAF antagonist (WEB-2170), 10 mg/kg, 2 hours prior to the intrabullar injection of 2 μg/mL of PAF in 0.2 mL of NS. The DTT was measured in the same manner as in the previous groups with 5% CBB.

Light Microscopy. Four selected ETs from each group were processed for routine histologic examination. Following in situ fixation of the ETs, by injection of 2.5% glutaraldehyde into the bullae, the tissue was postfixed in 10% formalin, decalcified with 10% ethylenediaminetetraacetic acid (EDTA) in 0.1 mol /L Tris-buffered saline, dehydrated by passage through a graded series of ethanol washes, and embedded in paraffin. Sections were cut to a thickness of 15 μm and stained with hematoxylin and eosin. To examine the same area from each ET, sections were obtained from the tympanic portion and the nasopharyngeal portion. The presence of cilia, the presence of a mucous plug in the tubal lumen, the degree of epithelial exfoliation, and the degree of inflammation in the ET tissues were recorded.

Transmission Electron Microscopy. Four ETs each from the 2- and 4-μg/mL groups were prepared for transmission electron microscopy (TEM) by local fixation with 2.5% glutaraldehyde injected into the bullae. After dissection of the ET from the temporal bone, the tissue was further fixed with 2.5% paraformaldehyde-glutaraldehyde, washed with buffer solution (phosphate buffer pH 7.2 to 7.4), postfixed with 1% osmic acid, dehydrated by passage through a graded series of ethanol washes, and embedded in Epon-araldite solution. The specimens were sectioned, stained for TEM by standard techniques, and examined with a JEOL 100 CX-II transmission electron microscope.

Statistics. All values were assumed to be normally distributed. A 1-way analysis of variance was used

TABLE 2. STATISTICAL ANALYSIS

	Control Group	*Normal Saline Group*	*1-μg Group*	*2-μg Group*	*PAF Antagonist Group*
Control group		NS	NS	$p < .05$	NS
Normal saline group	NS		NS	$p < .05$	NS
1-μg Group	NS	NS		$p < .05$	NS
2-μg Group	$p < .05$	$p < .05$	$p < .05$		$p < .05$
PAF antagonist group	NS	NS	NS	$p < .05$	

One-way analysis of variance was used to determine differences among means. Post hoc analysis was done by Scheffé test.

NS — not significant.

to determine the differences among means. Post hoc analysis was done by Scheffé test. We selected $p < .05$ as the level of significance for all analyses.

RESULTS

Dye Transport. Before initiating CBB dye transport studies, we assessed the effect of volume on transport to avoid either too large a volume, which would lead to passive streaming of the dye down the ET, or too small a volume, which would result in stagnant pooling of the dye in the inferior aspect of the bulla. Volumes of the dye greater than 0.2 mL resulted in immediate pumping appearance of the dye at the ET orifice, while those less than 0.1 mL failed to appear within the 15-minute limit arbitrarily set for the dye transport. A volume of 0.15 mL gave reproducible results and therefore was used throughout these experiments.

The transport time (±SD) of the dye through the ET from the ME cavity to the nasopharyngeal orifice of the normal guinea pigs was 69 ± 7 seconds. The transport time of the dye from the ME cavity to the nasopharyngeal orifice of the ETs after an injection of NS (control group) was 66 ± 5 seconds. The DTTs in the PAF-injected groups were 1-μg group 74 ± 6 seconds and 2-μg group 157 ± 9 seconds. In the 4-μg group, the dye did not appear for 15 minutes in 4 ears, and it took from 130 seconds to 9 minutes in the other 6 ears. We found in this study that the dye was impassable if it did not pass through the ET in 15 minutes. In the 8-μg group, the dye did not appear in the nasopharyngeal orifice for 15 minutes in 6 ears, and it took 8 to 10 minutes in the other 4 ears. In the 16-μg group, dye was not visible for 15 minutes in all 10 ears. In the PAF antagonist group, the dye became visible in 62 ± 5 seconds. The statistical analysis is summarized in Table 2. There was no statistically significant difference among the normal DTT and DTTs of the NS control, 1-μg, and PAF antagonist groups. The differences of DTT between the NS control and 2-, 4-, 8-, and 16-μg groups were significant.

Histopathology of Eustachian Tube. Light microscopy of the ET demonstrated a clear tubal lumen with a minimal amount of mucous plug, minimal inflammatory cell infiltrations, and minimal cell exfoliations in the NS, 1-μg, and PAF antagonist groups (Fig 1). The amount of mucous plug and the numbers of inflammatory cells and cell exfoliations were higher in the 2-, 4-, 8-, and 16-μg groups (Fig 2). In general, the amount of mucous plug and the degree of infiltration of inflammatory cells and cell exfoliations were higher in the prolonged DTT groups than

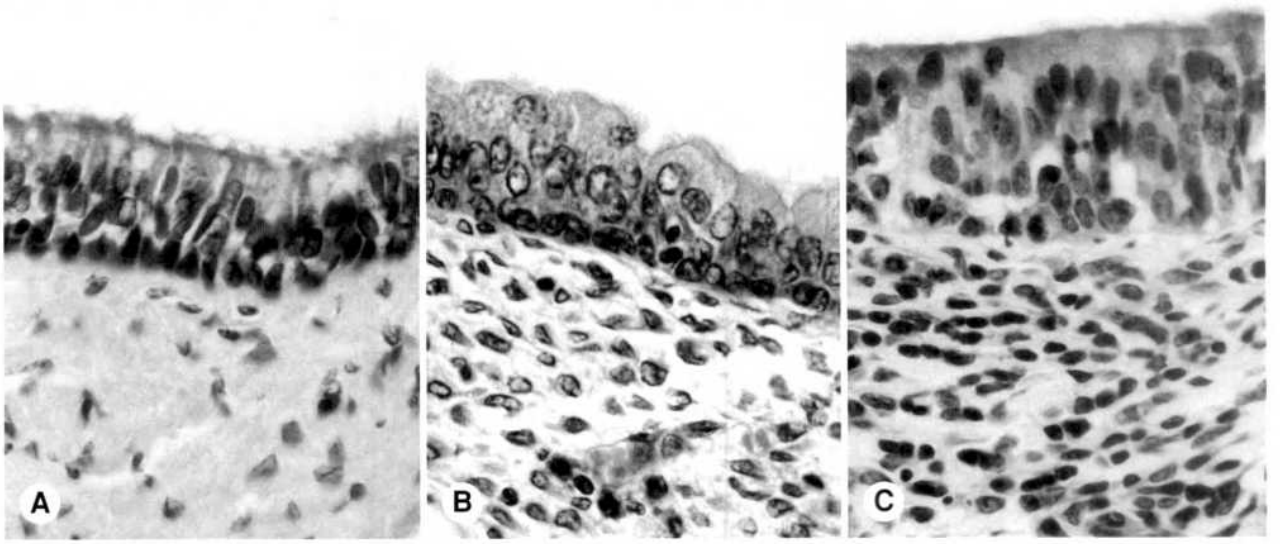

Fig 1. Light micrographs of guinea pig eustachian tube epithelium from A) normal saline group, B) 1-μg platelet activating factor (PAF) group, and C) PAF antagonist group (original ×120). All showed patent tubal lumen and intact cilia with minimal mucous plug, minimal cell exfoliations, and minimal inflammatory cell infiltrations.

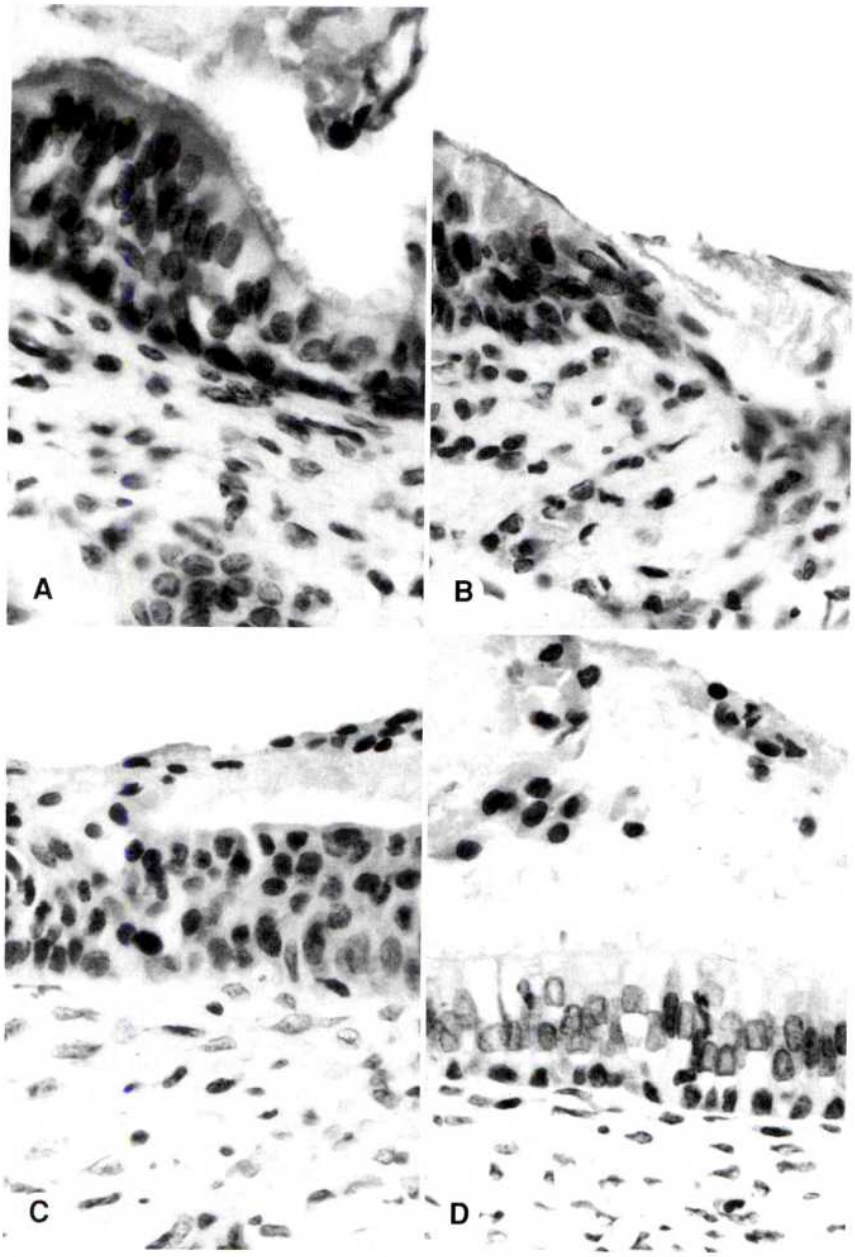

Fig 2. Light micrographs of guinea pig eustachian tube epithelium from A) 2-μg PAF, B) 4-μg PAF, C) 8-μg PAF, and D) 16-μg PAF groups (original ×120). Amount of mucous plug and numbers of inflammatory cells and exfoliated cells were higher in 2-, 4-, 8-, and 16-μg PAF groups than in normal saline, 1-μg PAF, and PAF antagonist groups.

in the nonprolonged groups, as demonstrated in Table 3.

Transmission Electron Microscopy. The morphological integrity of the ciliated cells in the ETs of the 2- and 4-μg groups was well maintained (Fig 3).

DISCUSSION

Measuring DTTs through the ET for assessment of the rate of transport from the ME to the nasopharyngeal orifice of the ET in the chinchilla was established by Bakaletz et al.[8] Using guinea pigs as experimental animals, we obtained normal transport rates similar to those of chinchillas. On light microscopic study, we observed intact cilia in most of the tubal membranes of the experimental groups, although there was an increased rate of cell exfoliation in the 2- to 16-μg groups. These findings indicate that PAF induces partial or complete reduction of the ciliary activity. This reduction of the ciliary activity as shown by DTT was PAF dose–dependent from the 2-μg group to the 16-μg group. The DTT was 157 seconds in the 2-μg group, 130 seconds to 9 minutes in the 4-μg group, and 8 to 10 minutes in the 8-μg group; the dye did not pass for 15 minutes in the 16-μg group. The number of ETs that did not pass the dye also increased in a dose-dependent manner: 4 in the 4-μg group, 6 in the 8-μg group, and 10 in the 16-μg group. The finding of more mucous plug in the 2- to 16-μg PAF groups than in the NS, 1-μg PAF, and PAF antagonist groups may indicate that PAF may have caused increased mucous secretions into the lumen of the ET and that the presence of

TABLE 3. DEGREE OF MUCOUS PLUG, CELL EXFOLIATION, AND INFLAMMATION

	Mucous Plug	*Exfoliation*	*Inflammation*
Normal saline group	2+	0	4+
1-μg Group	2+	1+	2+
PAF antagonist group	3+	1+	3+
2-μg Group	3+	5+	6+
4-μg Group	7+	7+	12+
8-μg Group	9+	8+	8+
16-μg Group	12+	10+	9+

N = 4 in each group. Amount of mucous plug and degrees of cell exfoliation and inflammation were graded from 1+ to 5+ in each animal. Numbers of "+"s from 4 ears of each group were added. Numbers indicate total numbers of "+"s in each group.

this mucous plug contributed to the delay of dye transport through the ET. Only a minimal degree of cell exfoliation and a minimal amount of mucous plug were seen in the NS control, 1-μg PAF, and PAF antagonist groups, leaving the tubal lumen patent and keeping the mucociliary function within normal range. This mucous secretion in the lumen of the ET is supported by the studies of Lin et al,[9,10] who have reported that PAF stimulated secretion of mucous glycoprotein in a dose-dependent manner from chinchilla ME epithelial cells in vitro. In those same studies, PAF antagonist and synthesis inhibitor inhibited PAF-stimulated mucous secretion. The exfoliation of epithelial cells has been observed in human paranasal sinus mucosa after exposure to PAF.[3] The well-maintained morphological integrity of the ciliated cells in the ETs of the 2- and 4-μg PAF groups in the TEM study indicates that the delay of DTT was due to inhibited mucociliary function of the ETs, and not to damage of the ciliated cells.

The mucociliary activity of the ET plays a critical role in the defense system of the ME in humans as well as in animals. Debris and fluid in the ME are drained into the nasopharynx through the ET by mucociliary action.[11] Disruption of this mucociliary function leads to the development of fluid in the ME, and continued dysfunction of the mucociliary apparatus in the ME and ET may be responsible, in part, for the chronicity of MEE.[6] Since PAF is released as inflammation develops in the ME cavity, PAF may disrupt the mucociliary transport function as it flows into the ET from the ME, and it may contribute to the development and maintenance of MEE.

Initially, we failed to observe any delay of DTT through the ET when the bullae were exposed to PAF for only 10 minutes. The delay of dye transport was observed after exposing the bullae for 15 minutes to various concentrations of PAF. It seems that a minimum of 15 minutes is necessary for the tubal mucosa and cilia to react to 2-μg/mL or higher concentrations of PAF. In our previous experiment, 1 μg/mL of PAF in bullae induced OME in 36 hours, while 8 and 16 μg/mL of PAF in bullae started to produce MEE within 1 hour of PAF infusion.[1] When ETs are exposed to higher concentrations of PAF, their clearance function is lost, and MEE is induced in a short period of time. This explains why it took less time to develop MEE with higher concentrations (8 and 16 μg/mL) of PAF than with lower concentrations (1 μg/mL) of PAF.

A PAF antagonist (WEB-2170) prevented the development of PAF-induced OME in our previous study.[1] In animals pretreated with PAF antagonist, the delay of DTT induced by PAF did not occur. The PAF antagonist may prevent the development of

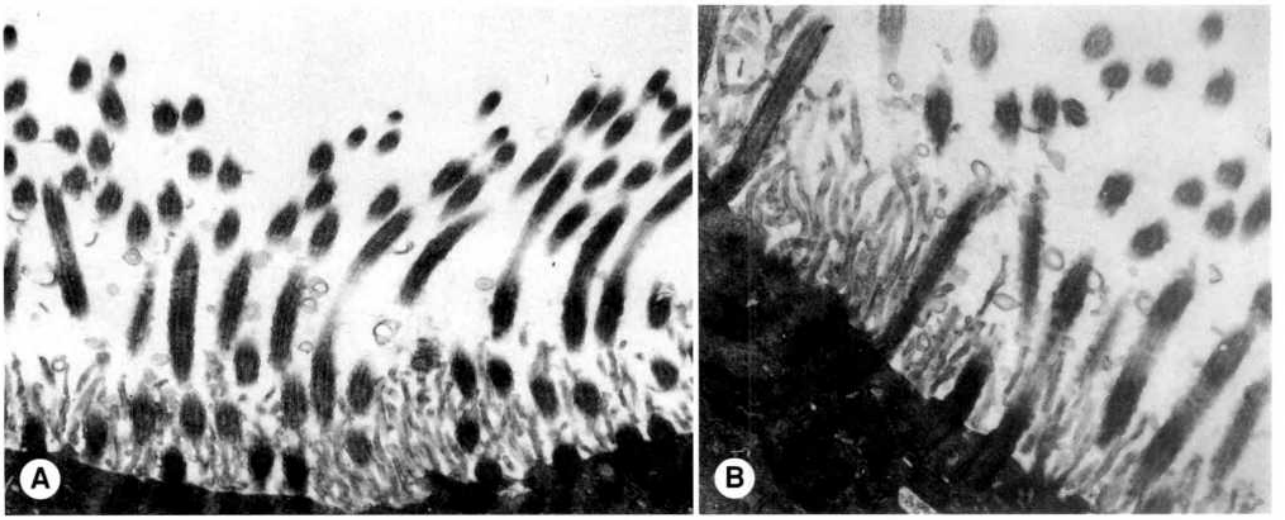

Fig 3. Transmission electron micrographs of guinea pig eustachian tube epithelium from A) 2-μg PAF and B) 4-μg PAF groups (original ×28,000). Morphological integrity of ciliated cells in eustachian tubes of 2- and 4-μg groups was well maintained.

PAF-induced OME by preventing mucociliary dysfunction of the ET.

CONCLUSION

This study demonstrated that PAF impaired the mucociliary clearance function of the ET in a dose-dependent manner in guinea pigs. This inhibition of mucociliary clearance function was prevented by pretreatment with PAF antagonist. The findings of this study suggest that PAF plays an important role in the pathogenesis of OME by impairing the ET clearance function.

REFERENCES

1. Rhee C-K, Jung TTK, Miller S, Weeks D. Experimental otitis media with effusion induced by platelet activating factor. Ann Otol Rhinol Laryngol 1993;102:600-5.

2. Barnes P. Pathobiology of platelet-activating factor. Pathol Immunopathol Res 1986;5:104-17.

3. Ganbo T, Hisamatsu K. Mucosal dysfunction and damage induced by platelet activating factor (PAF). Acta Otolaryngol (Stockh) 1990;110:427-36.

4. Minami T, Kubo N, Tomoda K, Kumazawa T. Effects of various inflammatory mediators on eustachian tube patency. Acta Otolaryngol (Stockh) 1992;112:680-5.

5. Minami T, Kubo N, Tomoda K, Yamashita T, Kumazawa T. Regional blood flow volume in the eustachian tube. Acta Otolaryngol Suppl (Stockh) 1993(suppl 500):80-3.

6. Sade J, Eliezer N. Secretory otitis media and the nature of the mucocilary system. Acta Otolaryngol (Stockh) 1970;70: 351-7.

7. Jung TTK, Rhee CK, Heinrich JA, Hwang SJ, Tambunan DJ. Profile of arachidonic acid metabolites and platelet-activating factor in human middle ear effusion. In: Lim DJ, Bluestone CD, Klein JO, Nelson JD, Ogra PL, eds. Recent advances in otitis media. Philadelphia, Pa: BD Decker, 1993:415-9.

8. Bakaletz LO, Griffith SR, Lim DJ. Effect of prostaglandin E2 and bacterial endotoxin on the rate of dye transport in the eustachian tube of the chinchilla. Ann Otol Rhinol Laryngol 1989;98:278-82.

9. Lin J, Kim Y, Lees C, Juhn SK. Effect of platelet-activating factor on secretion of mucous glycoprotein from chinchilla middle ear epithelial cells in vitro. Eur Arch Otorhinolaryngol 1995;252:92-6.

10. Lin J, Kim Y, Lees C, Juhn SK. Effects of platelet-activating factor (PAF) receptor blockage on mucous glycoprotein secretion in cultured chinchilla middle ear epithelium. Acta Otolaryngol (Stockh) 1996;116:69-73.

11. Takasaka T, Kawamoto K. Mucociliary dysfunction in experimental otitis media with effusion. Am J Otolaryngol 1985; 6:232-6.

RECENT ADVANCES IN OTITIS MEDIA

The 7th International Symposium on Recent Advances in Otitis Media will be held June 1-5, 1999, in Fort Lauderdale, Florida. For information, contact David J. Lim, MD, House Ear Institute, 2100 W Third St, Los Angeles, CA 90057.

PROSPECTIVE APPLICATION OF A PROTOCOL FOR SELECTIVE NONSURGICAL MANAGEMENT OF SUSPECTED ORBITAL SUBPERIOSTEAL ABSCESSES IN CHILDREN

ALI SAJJADIAN, MD

USHA CHUNDRU, MD GLENN ISAACSON, MD

PHILADELPHIA, PENNSYLVANIA

Goodwin et al (1982) and Souliere et al (1990) have proposed a protocol for the selective nonsurgical management of suspected orbital subperiosteal abscesses. This protocol has been routinely applied by the Temple Pediatric Otolaryngology and Ophthalmology services since 1990. During this period, children with computed tomography and physical examination findings consistent with orbital subperiosteal abscesses and visual acuity better than 20/60 were treated with intravenous antibiotics rather than immediate surgery. They were followed with frequent ophthalmologic examinations and operated upon if vision deteriorated or they failed to improve clinically within 48 hours. A review of patients admitted to St Christopher's Hospital for Children, the site of Temple University's pediatric activities in the years from 1991 to 1997, revealed 14 patients with clinical evidence of orbital subperiosteal abscesses. Twelve patients were treated in accordance with the Goodwin-Souliere protocol. All recovered completely without surgical intervention and without any adverse sequelae. Selective nonsurgical treatment of clinically diagnosed orbital subperiosteal abscesses in children is relatively safe and effective.

KEY WORDS — abscess, orbit, subperiosteal abscess.

INTRODUCTION

Orbital subperiosteal abscesses are the most frequent serious complications of ethmoid sinusitis in childhood. They occur when infection breaches the lamina papyracea directly or as the result of retrograde thrombophlebitis via the valveless ophthalmic venous system. This results in the accumulation of purulent material within the orbit but outside the barrier of the orbital periosteum.[1,2] Since the expansion of the potential subperiosteal space may be rapid, optic nerve function can be compromised by mechanical distortion and elevated intraorbital pressure. Traditionally, immediate surgical decompression by either an external or intranasal approach has been advocated.

In 1982, Goodwin et al[1] described the medical management of 3 patients with orbital subperiosteal abscesses who did not have visual impairment. They argued that advances in imaging technology, paired with careful ophthalmologic examination, permitted a more conservative approach in carefully selected patients. Souliere et al[2] presented a series of 10 children with orbital subperiosteal abscesses, 5 of whom were treated medically following the protocol described by Goodwin et al.

Since 1990, it has been the practice of the Temple Pediatric Otolaryngology and Pediatric Ophthalmology services to use initial medical treatment in children with clinical and computed tomography (CT) evidence of orbital subperiosteal abscesses provided 1) initial visual acuity is better than 20/60, 2) visual acuity does not worsen at any time, 3) there is no evidence of intracranial involvement, and 4) the children show evidence of improvement in orbital edema and extraocular movements within 48 hours of treatment onset. This study evaluates the safety and efficacy of this protocol.

MATERIALS AND METHODS

The office records of the Temple Pediatric Otolaryngology service and admission records of St Christopher's Hospital for Children were reviewed to identify all patients treated for suspected orbital subperiosteal abscesses. These records were analyzed to determine initial presenting symptoms, results of CT, procedures performed, length of hospital stay, and outcome in terms of recovery of extraocular movement and visual acuity. Patients with intraconal orbital involvement underwent surgery immediately and were not included in this study.

Full-time pediatric otolaryngology faculty treated all children. An ophthalmologic consultation and

From the Department of Otorhinolaryngology-Bronchoesophagology, Temple University School of Medicine and the Temple University Children's Medical Center, Philadelphia, Pennsylvania.

Presented in part at the Cottle International Rhinology Centennial and XVI International Symposium on Infection and Allergy of the Nose Meeting, Philadelphia, Pennsylvania, June 5-8, 1997.

CORRESPONDENCE — Glenn Isaacson, MD, Dept of Otorhinolaryngology-Bronchoesophagology, Temple University School of Medicine, Kresge West, First Floor, 3400 N Broad St, Philadelphia, PA 19140.

contrast-enhanced CT imaging were obtained routinely for children with history and physical signs suggestive of orbital subperiosteal abscess (nasal discharge, preseptal edema, limitation of gaze, or proptosis). Visual acuity was determined by a pediatric ophthalmologist using a Snellen chart. In young children, an Allen chart or other developmentally appropriate visual acuity charts (eg, illiterate E or other picture charts) were used to assess visual acuity. After initial examination, rechecks of vision were performed by the nursing staff every 2 hours and by the ophthalmology service on at least a daily basis. Infants underwent the fix-and-follow test, funduscopic examination, and observation of afferent pupillary function for assessment of visual function. Such testing does not yield quantitative assessment of visual acuity. The CT results were reviewed by a pediatric radiologist. An orbital subperiosteal abscess was suspected if there was elevation of the orbital periosteum and displacement of the medial rectus muscle by a contrast-enhancing mass in the presence of ethmoid sinusitis. "Ring enhancement" of the lesion by contrast material increased our level of suspicion. Identification of an air-fluid level within the subperiosteal space was considered a definite indication of abscess.

RESULTS

Fourteen patients with orbital subperiosteal abscesses were identified. Twelve had been treated by the Goodwin-Souliere protocol. One child with normal visual acuity, admitted to another service in the hospital, underwent an external ethmoidectomy without a trial of antibiotics and was excluded from the study. One infant with mild symptoms was treated medically, although exact visual acuity could not be determined. The mean patient age was 5.5 years with an age range of 13 months to 12 years. There was a male-to-female ratio of 5.5 to 1. All patients had periorbital edema and erythema at the time of presentation. Other presenting symptoms included chemosis (77%), proptosis (54%), headache (38%), and limited extraocular movements (31%). Blood cultures, performed in 10 patients, and lumbar punctures, obtained in 2 patients, were all negative. Computed tomography typically revealed evidence of ipsilateral or bilateral ethmoid sinusitis. All patients were treated with second- or third-generation cephalosporins and nasal decongestants alone. All improved clinically within 48 hours. None underwent surgical drainage for an abscess. None suffered permanent neurologic sequelae. All patients had a full return of vision and extraocular movements to the premorbid level. The average hospital stay was 6.6 days.

The 13-month-old infant presented to our hospital with his second episode of right orbital subperiosteal abscess, 2 months after hospitalization elsewhere. After complete recovery, an elective endoscopic ethmoidectomy was performed, revealing a large dehiscence of the lamina papyracea in the posterior ethmoid sinuses, with prolapse of intact orbital periosteum. This was thought to represent a congenital defect in the medial orbital wall. Orbital infection has not recurred.

DISCUSSION

The best management of orbital subperiosteal abscesses remains a topic of lively debate among otolaryngologists. It has been argued that immediate surgical drainage of suspected abscesses is mandatory to preserve sight and to limit the length of hospital stay.[3-5] Although surgical management options include open drainage through an external ethmoidectomy approach, the widespread application of endoscopic sinus surgery has made surgery especially attractive in that no external scar results from the intranasal endoscopic approach.[6-9] Enthusiasm for surgery must be tempered by several observations. Schramm et al[10] found that among 303 children treated for orbital complications of sinusitis, only children with visual acuity worse than 20/60 had adverse outcomes. Further, early surgical intervention does not completely ensure against the development of serious ocular sequelae.[4,5,11] Although the sensitivity of CT in detecting the presence of abscess or cellulitis is thought to be high, CT is not specific in differentiating an abscess from cellulitis or edema.[12,13] Further, initial CT findings are often not predictive of the clinical course.[14,15] In addition, CT may overestimate the incidence of orbital subperiosteal abscesses, as a phlegmon in the same location is often indistinguishable from an abscess, especially when no air-fluid level is seen.[16]

On the basis of these observations, several authors have challenged the notion that immediate surgery is always indicated.[1,2] Goodwin et al[1] proposed that the presence of an orbital subperiosteal abscess is only a relative indication for surgical drainage. Three of 13 children in their series were spared surgery after these 3 showed marked clinical improvement within 48 hours of starting medical therapy. Souliere et al[2] reviewed the case histories of children treated at 2 medical centers according to the guidelines described by Goodwin et al. Five of the 10 children in their series had complete clinical and radiographic resolution of orbital subperiosteal abscesses without surgical intervention.[2]

When the senior author (G.I.) began practice at St Christopher's Hospital for Children in 1990, the Tem-

ple Pediatric Otolaryngology and Ophthalmology services, which cared jointly for children with orbital subperiosteal abscesses at that institution, agreed to the uniform application of the Goodwin-Souliere protocol for newly admitted patients. In the ensuing 7 years, no patient has required surgical drainage of an orbital subperiosteal abscess. The average hospital stay, 6.6 days, compares favorably with those of surgical series in the literature.[6-8] Arjmand et al[7] reported an average hospitalization of 7.6 days. Manning[8] reported 5 patients with average hospitalization of 4.4 days. Page and Wiatrak[6] reported average hospital stays of 7.4 days for patients treated with external drainage or a combined approach (external ethmoidectomy and endoscopic approach), and 6.0 days for those treated endoscopically.

Given the small sample size of all reported series, it could be argued that our patient population was different from others in the literature. It is possible that our patients were less ill, since each of our patients had visual acuity of 20/60 or better at presentation and none progressed to more severe disease while receiving medical treatment. Further, the mean patient age in our study (5.4 years) was slightly lower than the average age of children with orbital subperiosteal abscesses reported by other authors (Souliere et al,[2] 8.9 years; Arjmand et al,[7] 9 years; Harris,[4] 8.9 years). Despite these concerns, it is important that our study population was composed of a *consecutive* series of children presenting at or transferred to a major urban tertiary referral hospital over a 7-year period — *not* a group selected for mild disease.

Experience with the treatment of focal infections elsewhere in the head and neck is in accordance with our findings in treating orbital subperiosteal abscesses. Computed tomography–diagnosed "abscesses" of the peritonsillar and retropharyngeal regions have been treated safely with patience and intravenous antibiotics.[3,17-19] This outcome owes in part to the efficacy of currently available intravenous antibiotics in the penetration of inflamed tissues and eradication of common upper respiratory tract pathogens, often with polymicrobial flora.[17,20] Further, when such "abscesses" are approached surgically, pus is found in only a portion of cases. Clearly, contrast-enhanced CT does a poor job of separating inflammatory edema or phlegmon from a true abscess in the absence of an air-fluid level within the tissue.[3,13,14] Since none of our patients underwent surgical exploration, which is the gold standard for abscess diagnosis, it is possible that they actually had cellulitis rather than a true collection of purulent material as CT suggested. By the same token, immediate surgical drainage in the face of "positive" CT may be excessive in many cases.

The safe application of the Goodwin-Souliere protocol demands frequent and accurate assessment of visual acuity. Some have argued that this is not possible in children.[7] We have found that in an institution in which consultation with a pediatric ophthalmologist is readily available, visual acuity can be determined with consistency, and that every-2-hour checks by skilled pediatric nurses are sufficient to allow relatively safe management. In settings in which such services are not available, it is possible that early surgery or transfer to a tertiary-care hospital would be preferable. Further, it should be emphasized that the Goodwin-Souliere protocol has been tested only in young children. Its applicability to adult populations is unknown.

CONCLUSION

The Goodwin-Souliere protocol permits the selective nonsurgical treatment of orbital subperiosteal abscesses without excess morbidity or hospitalization.

ACKNOWLEDGMENT — The authors acknowledge Eric Faerber, MD, of the Department of Diagnostic Imaging at St Christopher's Hospital for Children for his advice and aid in the analysis of computed tomograms of the sinuses.

REFERENCES

1. Goodwin WJ, Weinshall M, Chandler JR. The role of high resolution computed tomography and standardized ultrasound in evaluation of orbital cellulitis. Laryngoscope 1982; 92:728-31.

2. Souliere CR, Antoine GA, Martin MP, Blumberg AI, Isaacson G. Selective non-surgical management of subperiosteal abscess of the orbit: computerized tomography and clinical course as indication for surgical drainage. Int J Pediatr Otorhinolaryngol 1990;19:109-19.

3. Chandler JR, Langenbrunner DJ, Stevens ER. The pathogenesis of orbital complications in acute sinusitis. Laryngoscope 1970;80:1414-28.

4. Harris GJ. Subperiosteal abscess of the orbit. Arch Ophthalmol 1983;101:751-7.

5. Spires JR, Smith RJH. Bacterial infection of the orbital and periorbital soft-tissues in children. Laryngoscope 1986;96: 763-7.

6. Page EL, Wiatrak BJ. Endoscopic vs external drainage of orbital subperiosteal abscess. Arch Otolaryngol Head Neck Surg 1996;122:737-40.

7. Arjmand EM, Luck RP, Muntz HR. Pediatric sinusitis and subperiosteal orbital abscess formation: diagnosis and treatment. Otolaryngol Head Neck Surg 1993;109:886-94.

8. Manning SC. Endoscopic management of medial subperiosteal orbital abscess. Arch Otolaryngol Head Neck Surg 1993;119:789-91.

9. Froehlich P, Pransky SM, Fontaine P, Stearns G, Morgon

A. Minimal endoscopic approach to subperiosteal orbital abscess. Arch Otolaryngol Head Neck Surg 1997;123:280-2.

10. Schramm VL, Curtin HD, Kennerdell JS. Evaluation of orbital cellulitis and results of treatment. Laryngoscope 1982; 92:732-8.

11. Hornblass A, Herschborn BJ, Stern K, Grimes C. Orbital abscess. Surv Ophthalmol 1984;29:169-78.

12. Ungkanont K, Yellon RF, Weissman JL, Casselbrant ML, Gonzalez-Valdepena H, Bluestone CD. Head and neck space infections in infants and children. Otolaryngol Head Neck Surg 1995;112:375-82.

13. Sichel JY, Gomori JM, Saah D, Elidan J. Parapharyngeal abscess in children: the role of CT for diagnosis and treatment. Int J Pediatr Otorhinolaryngol 1996;35:213-22.

14. Harris GJ. Subperiosteal abscess of the orbit: computed tomography and the clinical course. Ophthal Plast Reconstr Surg 1996;12:1-8.

15. Gutowski WM, Mulbury PE, Hengerer AS, Kido DK. The role of CT scans in managing orbital complications of ethmoiditis. Int J Pediatr Otorhinolaryngol 1988;15:117-28.

16. Tom MB, Rice DH. Presentation and management of neck abscess: a retrospective analysis. Laryngoscope 1988;98: 877-80.

17. Johnson JT. Changing concepts in the management of deep neck infection [Abstract]. AAO-HNS Bull 1992;11:17.

18. Hill MK, Sanders CV. Principles of antimicrobial therapy for head and neck infections. Infect Dis Clin North Am 1988; 2:57-83.

19. Brook I, Frazier EH. Microbiology of subperiosteal orbital abscess and associated maxillary sinusitis. Laryngoscope 1996;106:1010-3.

20. Lazor JB, Cunningham MJ, Eavey RD, Weber AL. Comparison of computed tomography and surgical findings in deep neck infections. Otolaryngol Head Neck Surg 1994;111:746-50.

≈

PHONOSURGERY

The European Laryngological Society's Workshop 1999: Phonosurgery will be held, in English, October 9-10, 1999, in Graz, Austria. For more information, contact Prof Dr G. Friedrich, Department of ENT, University of Graz, Medical School, Auenbruggerplatz 20, Graz, Austria; telephone ++43/316/385-2579; fax ++43/316/385-3549; e-mail gerhard.friedrich@kfunigraz.ac.at.

SINUSITIS WITH CONTIGUOUS ABSCESS INVOLVEMENT OF THE CLIVUS AND PETROUS APICES

CASE REPORT

DICK L. HOISTAD, MD ARNDT J. DUVALL III, MD

MINNEAPOLIS, MINNESOTA

A wide spectrum of diseases may involve the clivus, such as primary neoplasms, metastatic disease, and inflammatory, vascular, hematopoietic, and infectious processes. Of these, osteomyelitis of the skull base and/or clival-petrous abscess are unusual, but may occur as a result of contiguous spread from the paranasal sinuses, namely, the posterior ethmoid and sphenoid, as was demonstrated by this patient. In this case report we discuss the pertinent anatomy, imaging studies, pathogenesis, and medical and surgical management of this case.

KEY WORDS — abscess, clivus, osteomyelitis, paranasal sinus, petrous apex, sinusitis.

CASE REPORT

A 38-year-old woman, with no significant past medical history, initially developed upper respiratory tract symptoms 3 days prior to hospital admission. The day before her admission, the patient was evaluated by her primary care physician and received nonsteroidal anti-inflammatory medication for a severe headache in the occiput region. Within the next 24 hours, the patient developed a marked headache, meningismus, emesis, chills, and a fever of 39.5°C. There was no recent history of dental work, travel, or preexisting disease. The patient was subsequently admitted through the emergency room after a lumbar puncture showed 3+ polymorphonuclear cells, a white blood cell (WBC) level of 2,700/100 mL, a glucose level of 54 mg/dL, and a protein level of 185 mg/dL. The initial serum WBC count was 7,100/100 mL with 73% segmented, 7% bands, and an erythrocyte sedimentation rate of 71 mm/h. Electrolytes were within normal limits. The patient was treated with intravenous clindamycin and Rocephin. The cerebrospinal fluid culture grew gram-negative cocci and bacilli consistent with *Haemophilus influenzae*. A computed tomography (CT) scan of the head showed bilateral ethmoid and sphenoid sinus disease with an air-fluid level involving a "pneumatized" clivus.

On physical examination, the patient's vital signs were a temperature of 38°C, a blood pressure of 122/74, a pulse of 76, and a respiratory rate of 18. Sinus endoscopy demonstrated bilateral yellow drainage medial to the middle turbinates, along with bilateral middle and inferior turbinate congestion. An otoscopic examination showed normal findings bilaterally. The pupils were reactive and symmetric. The sinuses were nontender to palpation. The oral cavity and oral pharynx showed no oral lesions and minimal tonsillar enlargement. The neck was stiff on flexion. The remaining physical examination findings were normal, including cranial nerves II to XII.

The patient was then transferred to the University of Minnesota Hospital and was treated with decongestants and intravenous Rocephin, vancomycin hydrochloride, and Flagyl. The clindamycin was discontinued. After determination of culture sensitivities, the patient was treated only with intravenous Rocephin.

A repeat CT scan of the sinuses and of the skull base revealed bilateral opacification of the ethmoid and sphenoid sinuses communicating with a fluid-filled lytic lesion of the clivus, anterior basioccipital bone, and petrous apices bilaterally. The disease involvement was suggestive of sinusitis with a concomitant osteomyelitis, abscess, mucocele, or mass lesion (Fig 1).

The patient was taken to the operating room for transoral drainage of the clivus. A superior posterior pharyngeal mucosal flap was elevated and an anterior opening was drilled into the wall of the clivus. Frank pus exuded under pressure from the clivus and both petrous apices. A flexible endoscope demonstrated exposed dura along the roof and sides of the cavity. The posterior pharyngeal mucosa was closed primarily. The final pathology report of the anterior clival bone showed osteomyelitis. The aerobic culture of

From the Department of Otolaryngology, University of Minnesota, Minneapolis, Minnesota.

CORRESPONDENCE — Arndt J. Duvall III, MD, Dept of Otolaryngology, University of Minnesota, 420 SE Delaware St, UMHC Box 396, Minneapolis, MN 55455.

Fig 1. Computed tomography scan (axial section) of posterior ethmoids and sphenoid sinus, taken during acute sinusitis, shows air-fluid level in sphenoid sinus (arrowheads) with extension into clivus (arrow), anterior basioccipital bone, and bilateral petrous apices (pa).

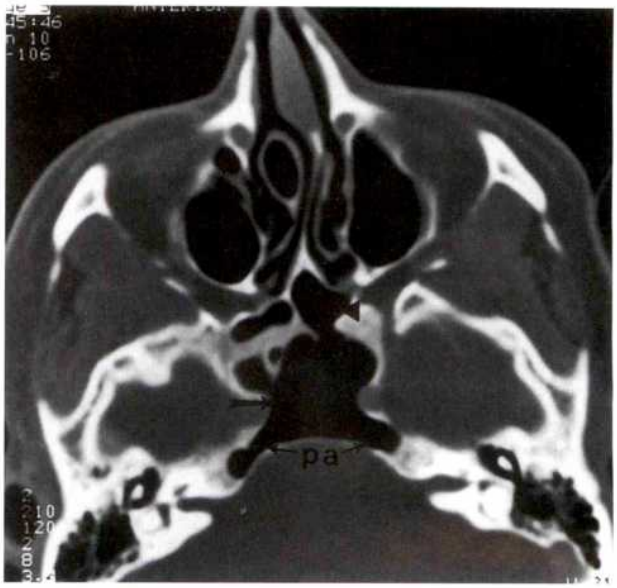

Fig 2. Six-month postsurgical computed tomography scan (axial section) of posterior ethmoids and sphenoid sinus shows pneumatization of sphenoid sinus (arrowhead), clivus (arrow), anterior basioccipital bone, and bilateral petrous apices (pa).

the abscess fluid grew coagulase-negative *Staphylococcus*. Anaerobic, fungal, and acid-fast bacilli cultures were negative.

The patient was discharged home following 7 days of intravenous Rocephin. She was treated with oral Augmentin for the next 6 weeks.

Clinically, at 6-month follow-up, the patient continued to do well, and a repeat CT scan of the sinuses showed the sinuses, clivus, basioccipital bone, and bilateral petrous apices to be well pneumatized without residual inflammatory process or intracranial abnormalities (Fig 2). The cavity was contiguous with the sphenoid sinuses. A sphenoidotomy was performed to allow prompt drainage of any future sinusitis. Two years later, the patient remains asymptomatic. An audiogram demonstrated normal hearing through 14,000 Hz.

DISCUSSION

Common factors predisposing to sphenoid sinusitis include upper respiratory tract infection, intranasal water, maxillofacial trauma, ethmoid sinusitis, diabetes, immune deficiency, and chemotherapy regimens. Our patient did have an upper respiratory tract infection with symptoms 3 to 4 days prior to initial presentation for medical treatment.

Anatomically, the clivus (Latin: hill), situated between the foramen magnum and dorsum sellae, is originally a cartilaginous structure that ossifies to form the basisphenoid and basioccipital bones.[1] It is bounded laterally by the petro-occipital fissure and the synchondrosis between the basioccipital and exoccipital bones. The petro-occipital fissure begins near the cavernous sinus and extends inferiorly to the jugular foramen. The synchondrosis between the basioccipital and exoccipital bones fuses at 3 to 4 years of age, when it forms the lateral margin of the clivus at the foramen magnum. The anterior margin of the clivus abuts the sphenoid sinus, whereas the inferior margin represents the nasopharyngeal surface of the base of the skull. The posterior surface is usually concave or flat and is the anterior surface of the prepontine and premedullary cisterns.[2] Pneumatization of the clivus is rare. It normally consists of bone marrow, as demonstrated by magnetic resonance imaging (MRI).[2]

Our patient did have sinusitis, but a differential diagnosis would include mucocele, nasopharyngeal carcinoma, pituitary adenoma, mucinous adenoma, chondrosarcoma, chordoma, meningioma, neuroma, neurilemoma, craniopharyngioma, carcinoma, and abscess formation.

Most osteomyelitis of the skull base derives from middle ear–mastoid disease or malignant otitis externa.[3,4] However, this patient had well-pneumatized, undiseased mastoid air cell systems. There was sinusitis, and the abscess was open to the sphenoid sinuses. It is possible that this patient already had a pneumatized clivus prior to sinusitis, but this would be most unusual. More probably, virulent bacteria spread directly from the sphenoid sinus to the marrow of the clivus, anterior basioccipital bone, and

the petrous apices, as can occur in Pott's puffy tumor in frontal sinus infection and in the walls of the maxillary sinus.[5] This proceeded to form a large abscess cavity.

No cervical spine or spinal epidural involvement was noted in our patient, but this has in the past been reported to be a sequela of osteomyelitis of the skull base.[1] Bacterial infection of the cancellous bone of the skull originating from the paranasal sinuses usually involves the cranial vault, as was demonstrated in our patient.[6] Additionally, the observed cavity within the clivus allowed a pathway to the epidural space and thus development of meningitis.

Typically, patients with this type of disease process are immunosuppressed or diabetic, and thus, a fungal causation should be considered. *Pseudomonas aeruginosa* is the organism most commonly responsible in malignant otitis externa, and *Staphylococcus aureus* is that most commonly involved in sphenoid sinusitis and spinal epidural abscesses.[1,3,6] Infectious diseases of the sphenoid sinuses usually occur in conjunction with infections of other paranasal sinuses. It is interesting that in this patient *H influenzae* was cultured from the cerebrospinal fluid, and coagulase-negative *Staphylococcus* was cultured from the clivus abscess. The *H influenzae* had probably been eradicated with secondary *Staphylococcus* overgrowth, as is common. The possibility of coagulase-negative *Staphylococcus* being a contaminant is unlikely.

Complications related to sphenoid sinusitis and skull base osteomyelitis include orbital cellulitis and abscess, orbital apex syndrome, superior orbital fissure syndrome, hypopituitarism, cavernous sinus thrombosis, carotid artery thrombosis, meningitis, epidural abscess, and Gradenigo's syndrome.[6] Fortunately for our patient, no neurologic or vascular sequelae occurred, probably because of the prompt, appropriate therapy instituted by the referring otolaryngologist and surgical drainage.

In the past, single photon emission computed tomography (SPECT) was felt to be excellent in localizing the disease, and gallium scintigraphy, in detecting resolution.[4] More recently, MRI has been felt to be superior for evaluation of the clivus, due to its multiplanar capabilities and the lack of beam-hardening artifact seen on CT, thus providing for better anatomic detail. However, high-resolution CT plays an invaluable role for bone changes involving the sinus and skull base, and therefore, high-resolution CT and MRI are complementary to each other for such disease involvement. In our patient, the sinus CT images clearly demonstrated ethmoid and sphenoid sinus disease along with a lytic process involving the clivus and petrous apices (Fig 1). A mucocele with underlying sinusitus could be considered, but is unlikely, due to the acute infectious presentation, the irregularity of the skull base bone changes, and the fact that the abscess fluid was not isodense in comparison to the cerebrospinal fluid.

Management consists of medical and surgical treatment. Medical management for *P aeruginosa* usually requires a 2-week to 6-month course of intravenous antibiotics consisting of an antipseudomonal penicillin along with an aminoglycoside or a third-generation cephalosporin.[7] More recently, fluoroquinolones have been found to play a role, with subsequent oral treatment following an intravenous antibiotic regimen.[8] Infections involving *Staphylococcus* usually require intravenous vancomycin. Another treatment modality consists of hyperbaric oxygen as a possible adjunct, as well.[9] In this patient, a most important aspect of her treatment was the surgical drainage of the abscess, and since her symptoms clinically improved, oral antibiotics were appropriate after a week's duration of appropriate intravenous antibiotics, since there was no evidence of immunosuppression or neurologic sequelae.

Multiple surgical approaches exist, including transnasal, transoral, and sublabial-transseptal approaches, bilateral Le Fort I osteotomies, a transpalatal-transoral approach, external ethmoidectomy with functional endoscopic sinus surgery and sphenoidotomy, Fisch infratemporal fossa approaches consisting of types A, B, and C, and a lateral skull base approach with or without petrous apicectomy.[10-12] The transoral approach was used in our patient, primarily because it was simple and provided the most direct access to the abscess, due to the large amount of involvement of the clivus.

REFERENCES

1. Azizi SA, Fayad PB, Fulbright R, Giroux ML, Waxman SG. Clivus and cervical osteomyelitis with epidural abscess presenting with multiple cranial neuropathies. Clin Neurol Neurosurg 1995;97:239-44.

2. Chaljub G, Van Fleet R, Guinto FC Jr, Crow WN, Martinez L, Kumar R. MR imaging of clival and paraclival lesions. AJR Am J Roentgenol 1992;159:1069-74.

3. Chandler JR. Malignant external otitis: further considerations. Ann Otol Rhinol Laryngol 1977;86:417-28.

4. Nadol JB. Histopathology of *Pseudomonas* osteomyelitis of the temporal bone starting as malignant external otitis. Am J Otolaryngol 1980;1:359-71.

5. Johnson EE, Duvall AJ III, Donaldson JA. Infectious osteonecrosis of the maxilla. Arch Otolaryngol 1962;76:558-61.

6. Holt GR, Standefer JA, Brown WE, Gates GA. Infectious diseases of the sphenoid sinus. Laryngoscope 1984;94:330-5.

7. Kimmelman CP, Lucente FE. Use of ceftazidime for malignant external otitis. Ann Otol Rhinol Laryngol 1989;98:721-5.

8. Lang R, Goshen S, Kitzes-Cohen R, Sadé J. Successful treatment of malignant external otitis with oral ciprofloxacin: report of experience with 23 patients. J Infect Dis 1990 161:537-40.

9. Davis JC, Gates GA, Lerner C, Davis MG Jr, Mader JT, Dinesman A. Adjuvant hyperbaric oxygen in malignant external otitis. Arch Otolaryngol Head Neck Surg 1992;118:89-93.

10. Chandler JR, Grobman L, Quencer R, Serafini A. Osteomyelitis of the base of skull. Laryngoscope 1986;96:245-51.

11. Kumar A, Valvassori G, Jafar J, Mafee M. Skull base lesions: a classification and surgical approaches. Laryngoscope 1986;96:252-63.

12. Chang CYJ, O'Rourke DK, Cass SP. Update on skull base surgery. Otolaryngol Clin North Am 1996;29:467-501.

≈

EUROPEAN SOCIETY OF PEDIATRIC ORL

The Vth International Conference of the European Society of Pediatric ORL will be held July 9-13, 2000, in Graz, Austria. For more information, contact Claire Zwerina, Secretary to Prof Stammberger, ENT-Department, University Hospital, Auenbruggerplatz 20, A-8036 Graz, Austria; fax ++43/316/385/3425.

≈

FUNCTIONAL AESTHETIC NASAL SURGERY

The 17th International Course in Functional Aesthetic Nasal Surgery will be held in English, June 15-18, 1999, in Utrecht, the Netherlands. For information, contact Ms. T. Kortleve, Dept of ORL, University Hospital Utrecht, PO Box 85500, 3508 GA Utrecht, the Netherlands; telephone +31-30-2506645; fax +31-30-2541922; e-mail t.kortleve@kmb.azu.nl.

COMPARATIVE ROLE OF PEPTIDE LEUKOTRIENES AND HISTAMINE IN THE DEVELOPMENT OF NASAL MUCOSAL SWELLING IN NASAL ALLERGY

TSUTOMU NUMATA, MD
AKIYOSHI KONNO, MD
TAKAYUKI YAMAKOSHI, MD
TOYOYUKI HANAZAWA, MD
NOBUHISA TERADA, MD
HIROSHI NAGATA, MD
CHIBA, JAPAN

To evaluate the importance of histamine and peptide leukotrienes (LTs) in the development of nasal mucosal swelling in nasal allergy, H1 receptor antagonist (mequitazine, 6 mg, in 2 divided doses, Rhône-Poulenc Rorer, France) and LT receptor antagonist (ONO-1078, pranlukast, 450 mg, in 2 divided doses, Ono Pharmaceutical Co, Ltd, Osaka) were administered orally for 7 days to 16 subjects with perennial nasal allergy to house dust mites, and the effects of receptor blockers of these chemical mediators on the effective cross-sectional area of the nasal cavity (ECA) at rest, at exercise load, at antigen challenge, and at exercise load following antigen challenge were studied. After the administration of H1 receptor antagonist, ECAs at all measurement points slightly increased, but no statistical significance was observed. On the other hand, LT receptor antagonist inhibited ECAs 10 minutes after exercise load, just after the end of antigen challenge, 10 minutes later, and at exercise load following antigen challenge with statistical significance. These results suggest that LTs are involved markedly, and histamine slightly, in the development of nasal mucosal swelling in nasal allergy.

KEY WORDS — H1 receptor antagonist, nasal allergy, nasal mucosal swelling, peptide leukotriene receptor antagonist.

INTRODUCTION

Among nasal hyperreactive symptoms in nasal allergy, sneezing is caused by a respiratory reflex initiated by stimulation of substance P (SP) and calcitonin gene–related peptide (CGRP)–immunoreactive nerve endings distributed in the nasal mucosa.[1] When various chemical mediators were applied on the nasal mucosa, only histamine could cause significant sneezing, and capsaicin treatment, which depletes SP and CGRP from these nerve endings, inhibited sneezing caused by antigen and histamine challenge on the nasal mucosa significantly both in subjects with hyperreactive nasal symptoms[2,3] and in a guinea pig model of nasal allergy.[4] Nasal hypersecretion is caused mainly by a parasympathetic nerve reflex that starts with sensory stimulation by histamine, and is only partially caused by plasma extravasation induced by direct effects of chemical mediators.[5,6]

On the other hand, nasal mucosal swelling in nasal allergy, which consists of dilatation of the capacitance vessels and plasma extravasation, is caused mainly by direct effects of various chemical mediators on the nasal vasculature, and partially by indirect effects of chemical mediators mediated by parasympathetic nerve reflexes (Numata et al, unpublished observations) and topical reflexes.[7,8]

However, the comparative importance of various chemical mediators in causing nasal vascular responses has not been clarified.

Recently, a potent and pure receptor antagonist to leukotrienes (LTs; ONO-1078, pranlukast, Ono Pharmaceutical Co, Ltd, Osaka)[9] became available for clinical trials. The present study was designed to study the roles of LTs and histamine in the development of nasal mucosal swelling in nasal allergy by evaluating the effects of the LT receptor antagonist ONO-1078 and those of the H1 receptor antagonist mequitazine (Rhône-Poulenc Rorer, France) on mucosal swelling in subjects with nasal allergy.

As nasal mucosal swelling in patients with nasal allergy is subjected markedly not only to nasal vascular reactions to chemical mediators, but also to sympathetic excitation in daily life, the effects of H1 and LT receptor antagonists on nasal mucosal swelling at rest, at exercise, at antigen challenge, and at exercise following antigen challenge were investigated.

SUBJECTS AND METHODS

SUBJECTS

The subjects were 32 patients with perennial nasal allergy to house dust and mites (20 males, 12 females, ages 14 to 44, average age 22). The severity of the nasal allergy symptoms was more than moderate as classified by Okuda's criteria.[10]

From the Department of Otorhinolaryngology, School of Medicine, Chiba University, Chiba, Japan.
CORRESPONDENCE — Tsutomu Numata, MD, Dept of Otorhinolaryngology, School of Medicine, Chiba University, 1-8-1 Inohana, Chuo-ku, Chiba City, Chiba 260-8670, Japan.

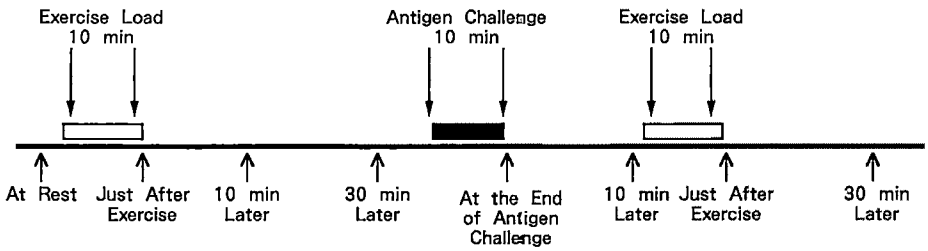

Fig 1. Time schedule for measuring nasal airway resistance (NAR). Following 1-hour rest, NAR at rest was measured. Then NAR was measured just after 10-minute exercise, and 10 minutes and 30 minutes after exercise. At 30 minutes after exercise, antigen challenge for 10 minutes was performed and NAR was measured at end of antigen challenge and 10 minutes later. At 10 minutes following end of antigen challenge, 10-minute exercise was loaded and NAR was measured right after and 30 minutes later.

SCHEDULE OF STUDY

First, the symptoms during the 1-week observation period were checked by a nasal allergy diary. As shown in Fig 1, after a 1-hour rest, nasal airway resistance (NAR) at rest was measured.

The Stress Test System ML-8000 and Treadmill L10 (Fukuda Electronics, Japan), programmed to adjust the volume to 2.7, 3.0, or 3.4 km/h, depending on age and sex, was used for 10 minutes. The NAR was measured just after exercise and 10 minutes and 30 minutes after exercise.

At 30 minutes after the end of exercise, antigen challenge was performed for 10 minutes, and the NAR was measured just after the end of antigen challenge and 10 minutes later. At 10 minutes after the end of antigen challenge, 10 minutes of exercise under the same conditions as before was performed, and the NAR was measured right after the exercise load and 30 minutes later.

Antigen challenge was performed on the bilateral inferior turbinates for 10 minutes using 2 antigen disks containing house dust with 2 to 5 μg protein nitrogen and 7.7 to 12 μg total nitrogen per disk, prepared by Torii Pharmaceutical Co.

The amount of nasal secretion was measured by the tissue paper method, and the frequency of sneezing paroxysms was counted for 10 minutes during antigen challenge.

For measurement of NAR, Rhinomanometer MRP-2200 (Nihon Kohden, Japan) was used, and the effective cross-sectional area of the nasal cavity (ECA) was calculated from a pressure-flow volume curve obtained by the posterior method in accordance with the one mentioned in our previous reports.[11]

To evaluate the effects of each therapy on the degree of hyperreactive nasal symptoms during daily life, the frequency of attacks of sneezing, frequency of nose blowing, and nasal obstruction score were recorded daily according to Okuda's criteria[10] in the allergy diary, starting 1 week before the therapy and going until the end of therapy. A score between 0 and 9 was given daily, depending upon the degree of nasal obstruction.

Then, 6 mg/d of mequitazine, which is an H_1 receptor antagonist, was orally administered in 2 divided doses for 7 days, and on the last day of administration, antigen challenge and exercise load were performed in accordance with the same schedule as that before therapy, and time-course changes in NAR were measured.

Second, after a 3-week washout period, 450 mg/d of LT receptor antagonist (ONO-1078, pranlukast) was orally administered in 2 divided doses for 7 days, and exercise load, antigen challenge, and NAR measurements were performed before and after the therapy in a time-course manner in accordance with the same schedule as before.

STATISTICAL METHODS

The results of each measurement were expressed as mean ± SD, and the effectiveness of each therapy was evaluated by comparing before and after therapy symptom scores in the nasal allergy diary, the number of sneezes, and the weight of nasal discharge observed during a 10-minute antigen challenge and the ECA values during the time course of rest, exercise load, and antigen challenge. Analysis of variance and paired *t*-test were used for statistical analysis.

RESULTS

TIME COURSE CHANGES IN ECA BY EXERCISE LOAD AND ANTIGEN CHALLENGE BEFORE ADMINISTRATION OF H_1 RECEPTOR ANTAGONIST

After a 10-minute exercise load, the ECA increased by 0.153 ± 0.090 cm^2, and it went from L_1 (before the exercise load) to L_2, as shown in Fig 2. At the end of exercise, the ECA rapidly decreased for the first 10 minutes (L_3), gradually decreased afterward, and returned in 30 minutes to almost the same value (L_4) as L_1.

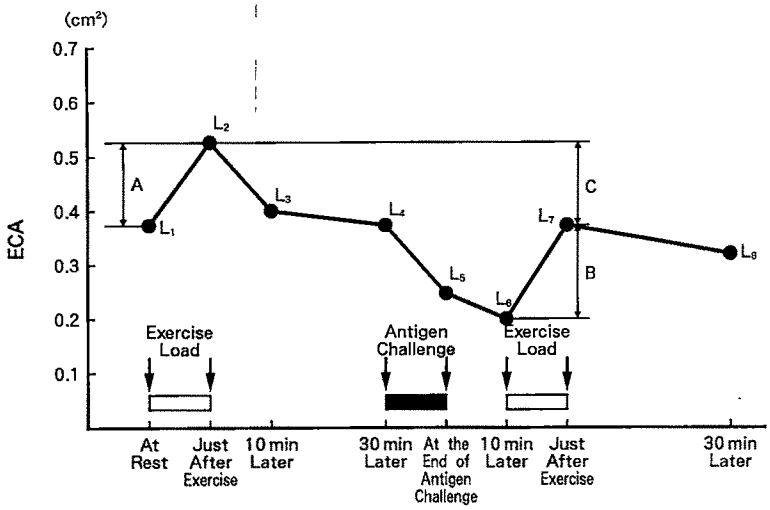

Fig 2. Time course changes in effective cross-sectional area of nasal cavity (ECA) induced by exercise load, antigen challenge, and exercise load following antigen challenge. After 10-minute exercise load, ECA increased from L1 to L2. Along with end of exercise, ECA rapidly decreased for first 10 minutes, gradually decreased afterward, and returned 30 minutes later to almost same value (L4) as one before exercise load (L1). Antigen challenge at this point decreased ECA from L4 to L6 in 20 minutes. Exercise load at 10 minutes following end of antigen challenge increased ECA from L6 to L7. ECA at L7 was approximately same as or slightly above ECA value before antigen challenge (L4). Increases of ECA from L1 to L2 (A) and L6 to L7 (B) indicate norepinephrine-dependent constriction of capacitance vessel, and difference of ECA at L2 and L7 (C) was assumed to indicate norepinephrine-refractory dilatation of capacitance vessel and interstitial edema caused by chemical mediators.

When the antigen challenge was performed at this point, ECA decreased by 0.171 ± 0.091 cm² (L4 to L6) and reached the level of L6 10 minutes after the end of antigen challenge. At this point, exercise was loaded under the same condition as before antigen challenge; then ECA increased from L6 to L7 by 0.186 ± 0.108 cm² in 10 minutes, and the ECA after exercise load (L7) was approximately the same as or slightly above the value of the ECA before antigen challenge (L4). Namely, the decrease in ECA after antigen challenge was almost compensated by the increase in ECA after exercise load. However, the ECA at exercise load after antigen challenge (L7) did not reach the level of the ECA 10 minutes after the first exercise load (L2), and a difference of 0.148 ± 0.094 cm² was observed between L2 and L7.

CHANGES IN NASAL MUCOSAL REACTION AFTER ORAL ADMINISTRATION OF H1 RECEPTOR ANTAGONIST

Nasal Mucosal Swelling. The ECAs (in square centimeters; ±SD) before administration of mequitazine at L1, L2, L3, L4, L5, L6, L7, and L8 were 0.374 ± 0.132, 0.524 ± 0.123, 0.401 ± 0.160, 0.361 ± 0.141, 0.245 ± 0.120, 0.190 ± 0.108, 0.376 ± 0.127, and 0.322 ± 0.151, respectively, and the ECAs (in square centimeters) after therapy were 0.391 ± 0.143, 0.528 ± 0.124, 0.433 ± 0.147, 0.402 ± 0.145, 0.293 ± 0.119, 0.254 ± 0.105, 0.419 ± 0.137, and 0.378 ± 0.117, respectively (Fig 3).

The degrees of decrease in ECA by antigen challenge (L4 to L6) were 0.171 ± 0.091 cm² and 0.148 ± 0.107 cm² before and after administration of mequitazine, respectively, showing a slight inhibition of decrease in ECA by antigen challenge. The ECAs after therapy, at rest (L1), at exercise load (L2), at antigen challenge (L6), and at exercise load after antigen challenge (L7) slightly increased, as shown in Fig 3. However, no statistically significant difference was observed between ECA levels before and after the therapy at any point. The differences between ECA after exercise load following antigen challenge (L7) and ECA at the first exercise load (L2) were 0.148 ± 0.094 cm² and 0.109 ± 0.078 cm² be-

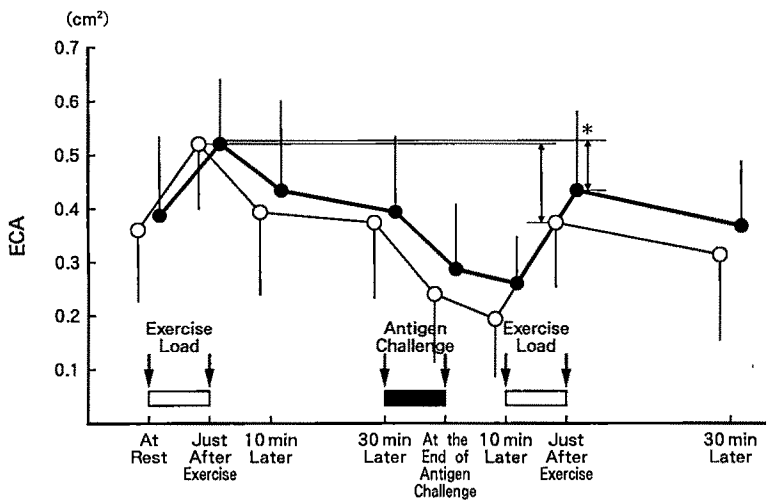

Fig 3. Effects of mequitazine on time course changes in ECA induced by exercise load, antigen challenge, and exercise load following antigen challenge. Mequitazine increased ECA at each point of measurement. However, any increases in ECA values were not statistically significant. Degree of norepinephrine-refractory swelling of nasal mucosa induced by antigen challenge decreased significantly ($p < .05$) after therapy. Open circles — ECA before therapy; filled circles — ECA after therapy; * — $p < .05$.

TABLE 1. EFFECTS OF MEQUITAZINE AND ONO-1078 ON FREQUENCY OF SNEEZING AND AMOUNT OF RHINORRHEA INDUCED BY ANTIGEN CHALLENGE

	Evaluation of Hyperreactive Nasal Symptoms	*Before Therapy*	*After Therapy*	*p*
Mequitazine	Frequency of sneezing in 10 min	7.69 ± 9.64	4.84 ± 6.66	p < .05
	Amount of rhinorrhea in 10 min (g)	2.07 ± 0.95	1.71 ± 0.80	p < .05
ONO-1078	Frequency of sneezing in 10 min	10.06 ± 12.60	6.93 ± 5.64	NS
	Amount of rhinorrhea in 10 min (g)	2.18 ± 0.99	2.03 ± 0.98	NS

Data are mean ± SD.
NS — nonsignificant.

fore and after therapy, respectively, showing a significant decrease (p < .05) with the administration of mequitazine.

Number of Sneezing Paroxysms and Weight of Nasal Discharge at Antigen Challenge. The number of sneezing attacks significantly decreased (p < .05), from 7.69 ± 9.64 before therapy to 4.84 ± 6.66 after therapy. The weight of nasal discharge also significantly decreased (p < .05), from 2.07 ± 0.95 g before therapy to 1.71 ± 0.80 g after therapy (Table 1).

Sneezing, Nasal Discharge, and Nasal Obstruction Score in Nasal Allergy Diary. The degree of hyperreactive nasal symptoms in the 2 days just before starting therapy was compared with that in the last 2 days before finishing therapy. The mean number of sneezing paroxysms per day significantly decreased (p < .05), from 2.83 ± 2.24 before therapy to 2.01 ± 1.45 after therapy. The number of nose-blowings per day significantly decreased (p < .05), from 5.67 ± 3.22 before therapy to 4.36 ± 3.12 after therapy. On the other hand, the score of nasal obstruction (daily average) was 5.10 ± 1.98 before therapy and 5.01 ± 2.04 after therapy, showing no significant improvement by therapy (Table 2).

CHANGES IN NASAL MUCOSAL REACTION AFTER ORAL ADMINISTRATION OF LT RECEPTOR ANTAGONIST

Nasal Mucosal Swelling. The ECAs (in square centimeters) before administration of ONO-1078 at L_1, L_2, L_3, L_4, L_5, L_6, L_7, and L_8 were 0.354 ± 0.172, 0.525 ± 0.137, 0.376 ± 0.156, 0.354 ± 0.164, 0.234 ± 0.130, 0.183 ± 0.116, 0.357 ± 0.120, and 0.316 ± 0.173, respectively. The ECAs (in square centimeters) after therapy were 0.413 ± 0.130, 0.568 ± 0.155, 0.464 ± 0.109, 0.411 ± 0.125, 0.315 ± 0.101, 0.256 ± 0.092, 0.448 ± 0.143, and 0.376 ± 0.109, respectively.

As shown in Fig 4, ONO-1078 increased the ECA 10 minutes after exercise load, just after and 10 minutes after antigen challenge, and at exercise load after antigen challenge with statistical significance.

Number of Sneezing Paroxysms and Weight of Nasal Discharge at Antigen Challenge. The number of sneezing paroxysms decreased, from 10.06 ± 12.60 before therapy to 6.93 ± 5.64 after therapy, and the weight of nasal discharge decreased, from 2.18 ± 0.99 g before therapy to 2.03 ± 0.98 g after therapy. However, these changes were not significant (Table 1).

Sneezing, Nasal Discharge, and Nasal Obstruction Score in Nasal Allergy Diary. The number of nose-blowings per day decreased, from 5.59 ± 3.58 before therapy to 4.06 ± 2.80 after therapy, and the nasal obstruction score (daily average) decreased, from 5.29 ± 1.21 before therapy to 3.89 ± 1.35 after therapy. The number of nose-blowings and the nasal obstruction score showed significant improvement after therapy (p < .01; Table 2). The number of paroxysms of sneezing per day was 2.74 ± 3.03 before therapy and 1.92 ± 1.95 after therapy, showing no significant change.

DISCUSSION

After single antigen challenge on the nasal muco-

TABLE 2. EFFECTS OF MEQUITAZINE AND ONO-1078 ON HYPERREACTIVE NASAL SYMPTOMS EVALUATED BY NASAL ALLERGY DIARY

	Evaluation of Hyperreactive Nasal Symptoms	*Before Therapy*	*After Therapy*	*p*
Mequitazine	Frequency of sneezing per day	2.83 ± 2.24	2.01 ± 1.45	p < .05
	Frequency of nose-blowing per day	5.67 ± 3.22	4.36 ± 3.12	p < .05
	Degree of nasal obstruction (average score for day)	5.10 ± 1.98	5.01 ± 2.04	NS
ONO-1078	Frequency of sneezing per day	2.74 ± 3.03	1.92 ± 1.95	NS
	Frequency of nose-blowing per day	5.59 ± 3.58	4.06 ± 2.80	p < .01
	Degree of nasal obstruction (average score for day)	5.29 ± 1.21	3.89 ± 1.35	p < .01

Data are mean ± SD.

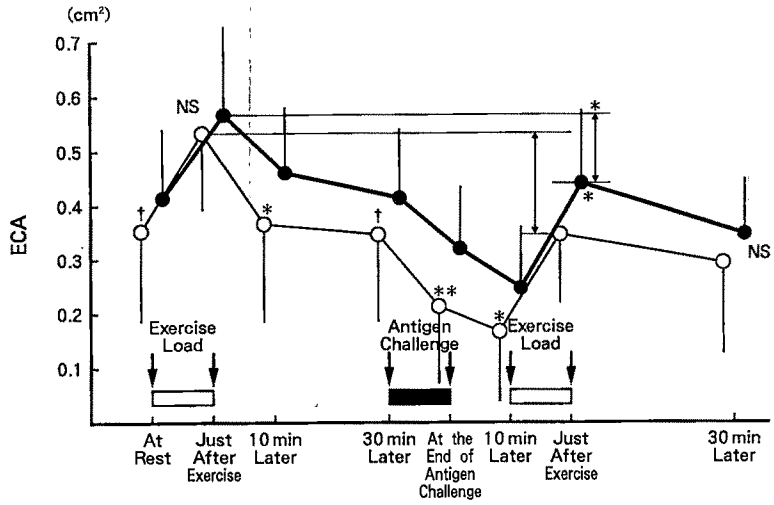

Fig 4. Effects of ONO-1078 on time course changes in ECA induced by exercise, antigen challenge, and exercise load following antigen challenge. ONO-1078 increased ECA significantly at 10 minutes after exercise load, just after and 10 minutes following end of antigen challenge, and just after exercise load following antigen challenge. Open circles — ECA before therapy; filled circles — ECA after therapy; † — $p < .1$; * — $p < .05$; ** — $p < .01$; NS — nonsignificant.

sa in subjects with nasal allergy, various chemical mediators are released in the nasal mucosa.[12-15] Extensive studies have been performed on the vascular effects of individual chemical mediators in the lower airway, nasal mucosa, and skin.[16-23] However, the comparative importance among various chemical mediators in causing nasal vascular responses has not been clarified.

When the relative ability to cause relaxation of the nasal mucosa in a guinea pig model of nasal allergy was compared among various bioactive substances released in the nasal mucosa after antigen challenge by a bioassay method that evaluates the degree of muscular relaxation of the capacitance vessel, LTD4 was the most potent, followed by histamine, prostaglandin D2 (PGD2), platelet activating factor (PAF), and thromboxane A2 on an equimolar basis (Hanazawa et al, unpublished observations).

When the relative ability of chemical mediators applied to the nasal mucosa in subjects with perennial nasal allergy to cause mucosal swelling was compared among histamine, LTD4, and PAF, LTD4 was the most potent, followed by PAF and histamine. The ability of LTD4 to cause a significant increase of NAR was 8 times as potent as that of histamine.[8] However, when the amounts of chemical mediators released in the nasal lavage after antigen challenge were compared, histamine was most abundant, followed by peptide LTs (LTC4, LTD4, and LTE4). During the immediate phase reaction after antigen challenge, the amounts of histamine and LTs observed in the nasal lavages were in a ratio of 143:1 by molar concentration.[15]

In this study, the comparative importance of histamine and LTs in the development of nasal mucosal swelling in nasal allergy was evaluated by means of an H1 receptor antagonist, mequitazine, and an LT receptor antagonist, ONO-1078, which became available for clinical trial recently.

Nasal mucosal swelling consists of both dilatation of smooth muscle of the capacitance vessels and plasma extravasation from the postcapillary venules induced by chemical mediators.

The vascular tonus of the nasal mucosa is also affected by sympathetic excitation in daily life. Nasal mucosal shrinkage observed on exercise or psychic stimulation is caused by vascular contraction induced by norepinephrine released from the sympathetic nerve terminals in the nasal mucosa.[11,24]

In this study, 7-day administration of H1 receptor antagonist reduced sneezing and nasal discharge induced by antigen with statistical significance, and the inhibitory effect on sneezing and nasal discharge evaluated according to a nasal allergy diary was also significant. Oral administration of H1 receptor antagonist increased ECAs slightly at rest under natural exposure to antigen and after antigen challenge. However, these changes were not significant. Nasal mucosal swelling as an immediate reaction reaches a plateau about 30 minutes after antigen challenge.[8] When, however, exercise was performed 10 minutes after the end of antigen challenge, the ECA returned to almost the same value as that before antigen challenge within 10 minutes. The increase in ECA by exercise load after antigen challenge was significantly larger than that with exercise load only. This may suggest that norepinephrine released from sympathetic nerve terminals partially reduced the relaxation of the smooth muscle of the capacitance vessels induced by chemical mediators.

However, the ECA at exercise load after antigen challenge did not reach the level observed at exercise load only. This difference is considered to indicate the degrees of norepinephrine-refractory interstitial edema and of norepinephrine-refractory relax-

ation of capacitance vessel smooth muscle induced by chemical mediators. This value significantly decreased after oral administration of an H1 receptor antagonist ($p < .05$). Oral administration of an LT receptor antagonist for 1 week did not have any significant effect on sneezing or the amount of nasal discharge at antigen challenge. However, it increased the ECA value at 10 minutes after exercise load, and also that just after exercise following antigen challenge, and inhibited the decrease in ECA 10 minutes and 20 minutes after antigen challenge with statistical significance. Also, ECA at rest indicating nasal mucosal vascular reaction to natural provocation showed a tendency to increase after administration of ONO-1078 ($p < .1$). These results suggest that LTs are involved markedly, and histamine only slightly, in the development of nasal mucosal swelling in nasal allergy.

According to the nasal allergy diary, the LT receptor antagonist not only significantly improved nasal obstruction, but also the number of nose-blowings, and although the clinical significance of LTs in nasal secretions observed by nasal allergy diary should be further clarified,[25] improvement in nasal patency may have a role in part of this effect.

CONCLUSION

Oral administration of H1 receptor antagonist (mequitazine) for 7 days significantly inhibited sneezing and hypersecretion or nasal discharge induced by antigen.

The ECAs at rest indicating natural provocation status and status at exercise load, at antigen challenge, and at exercise load after antigen challenge were slightly reduced by oral administration of H1 receptor antagonist, with no significant difference.

On the other hand, oral administration of an LT receptor antagonist (ONO-1078, pranlukast) for 7 days increased the ECA 10 minutes after exercise load, 10 minutes and 20 minutes after antigen challenge, and at exercise following antigen challenge, with statistical significance.

The results of this study suggest that LTs are involved greatly, and histamine only slightly, in the development of nasal mucosal swelling in nasal allergy.

REFERENCES

1. Lundblad L. Protective reflexes and vascular effects in the nasal mucosa elicited by activation of capsaicin-sensitive substance P–immunoreactive trigeminal neurons. Acta Physiol Scand Suppl 1984(suppl 529).

2. Stjärne P, Lundblad L, Anggärd A. Local capsaicin treatment of the nasal mucosa reduces symptoms in patients with nonallergic nasal hyperreactivity. Am J Rhinol 1991;5:145-51.

3. LaCroix JS, Buvelot JM, Polla BS, Lundberg JM. Improvement of symptoms of non-allergic chronic rhinitis by local treatment with capsaicin. Clin Exp Allergy 1991;21:595-600.

4. Konno A, Nagata H, Nomoto M, Motosugi H, Terada N. Role of capsaicin-sensitive trigeminal nerves in development of hyperreactive nasal symptoms in guinea pig model of nasal allergy. Ann Otol Rhinol Laryngol 1995;104:730-5.

5. Konno A, Terada N, Okamoto Y, Togawa K. The role of chemical mediators and mucosal hyperreactivity in nasal hypersecretion in nasal allergy. J Allergy Clin Immunol 1987;79:620-6.

6. Raphael GD, Meredith SD, Baraniuk JN, Druce HM, Banks SM, Kaliner MA. The pathophysiology of rhinitis. II. Assessment of the sources of protein in histamine-induced nasal secretions. Am Rev Respir Dis 1989;139:791-800.

7. Katahashi T, Konno A. Effect of tachykinin receptor antagonists, FK224 and FK888 in guinea pig model of nasal allergy. Rhinology 1997;35:63-6.

8. Konno A, Numata T, Terada N, Hanazawa T, Nagata H, Motosugi H. Role of substance P in the vascular response of nasal mucosa in nasal allergy. Ann Otol Rhinol Laryngol 1996;105:648-53.

9. Obata T, Okada Y, Motoishi M, Kakagawa N, Terawaki T, Aishita H. In vitro antagonism of ONO-1078, a newly developed anti-asthma agent, against peptide leukotrienes in isolated guinea pig tissues. Jpn J Pharmacol 1992;60:227-37.

10. Okuda M. Fundamental and clinical studies on nasal allergy. Otologia Fukuoka 1974;20:297-344.

11. Konno A, Terada N, Nomoto M. The effect of psychic stimulation on plasma catecholamine concentrations and nasal patency in patients with nasal allergy. Ann Otol Rhinol Laryngol 1994;103:375-82.

12. Naclerio RM, Meier HL, Kagey-Sobotka A, et al. Mediator release after nasal airway challenge with allergen. Am Rev Respir Dis 1983;128:597-602.

13. Naclerio RM, Proud D, Togias AG, et al. Inflammatory mediators in late antigen-induced rhinitis. N Engl J Med 1985;313:65-9.

14. Creticos PS, Peters SP, Adkinson NF, et al. Peptide leukotriene release after antigen challenge in patients sensitive to ragweed. N Engl J Med 1984;310:1626-30.

15. Terada N, Ando H, Ito E, et al. Nasal allergy and leukotriene. II. Kinetics of peptide leukotrienes and inflammatory cells in nasal lavage fluid after antigen challenge. J Otolaryngol Jpn 1989;92:1337-44.

16. Dahlen SE, Bjork J, Arfors KE, Hammarstrom S, Lindgren JA, Samuelsson B. Leukotrienes promote plasma leakage and leukocyte adhesion in postcapillary venules. In vivo effects with relevance to the acute inflammatory response. Proc Natl Acad Sci USA 1981;78:3887-91.

17. Drazen JM, Austen KF, Lewis RA. Comparative airway and vascular activities of leukotrienes C-1 and D in vivo and in vitro. Proc Natl Acad Sci USA 1980;77:4354-8.

18. Omini C, Daffonchio L, Berti L. Positive interaction between leukotriene C4 and histamine and other mediators on vascular tissues. Prostaglandins 1985;29:1009-20.

19. Bisgaard H, Olsson P, Bende M. Leukotriene D4 increases nasal blood flow in humans. Prostaglandins 1984;27:599-605.

20. Okuda M, Watase T, Mezawa A, Liu CM. The role of leukotriene D4 in allergic rhinitis. Ann Allergy 1987;60:537-40.

21. Shirasaki H, Asakura K, Kojima T, Sohma S, Kataura A. The roles of histamine, leukotriene C4 and bradykinin on nasal vascular permeability in experimental nasal allergy of guinea pigs. Rhinology 1992;30:41-8.

22. Peck MJ, Piper PJ, Williams TJ. The effect of leukotrienes C4 and D4 on the microvasculature of guinea-pig skin. Prostaglandins 1981;21:315-21.

23. Bisgaard H, Kristensen J, Sondergaard J. The effect of leukotrienes C4 and D4 on cutaneous blood flow in humans. Prostaglandins 1982;23:797-801.

24. Konno A, Togawa K, Itasaka A. Neurophysiological mechanisms of shrinkage of nasal mucosa induced by exercise. Auris Nasus Larynx 1982;9:81-90.

25. Johnson HG, Chinn RA, Chow AW, Bach MK, Nadel JA. Leukotriene C4 enhances mucus production from submucosal glands in canine trachea in vivo. Int J Immunopharmacol 1983;5:391-6.

FUNCTIONAL ENDOSCOPIC SINUS SURGERY

Functional Endoscopic Sinus Surgery — Basic and Advanced Techniques will be held in Graz, Austria, in English (July 1-3, 1999) and in German (September 2-4, 1999). For more information, contact Claire Zwerina, Secretary to Prof Stammberger, ENT-Department, University Hospital, Auenbruggerplatz 20, A-8036 Graz, Austria; fax ++43/316/385/3425.

DELAYED IRRADIATION EFFECTS ON NASAL EPITHELIUM IN PATIENTS WITH NASOPHARYNGEAL CARCINOMA

AN ULTRASTRUCTURAL STUDY

PEI-JEN LOU, MD
TAIPEI, TAIWAN

WEN PIN CHEN, PHD
TAIPEI, TAIWAN

CHUNG CHIEH TAI, MD
TAO-YUAN, TAIWAN

The ostiomeatal complex is responsible for the clearance of most sinus secretions. To evaluate the delayed effects of irradiation, this study examined the infundibulum mucosa of 10 patients who developed sinusitis after receiving radiotherapy for nasopharyngeal carcinoma (NPC). Pathologic findings under the light microscope revealed an increased deposition of dense collagenous fibers in the lamina propria. The epithelial cells also transformed into a stratified arrangement and showed gradual reduction of cytoplasmic volume. Ultrastructural observations detected areas of ciliary loss, intercellular and intracellular vacuolation, and ciliary dysmorphism. Most of these pathologic findings were observed even in a patient 23 years after irradiation. The results presented herein suggest that radiotherapy may cause long-term damage to the nasal epithelium that may be responsible for the prolonged sinusitis of irradiated NPC patients.

KEY WORDS — electron microscopy, irradiation, nasopharyngeal carcinoma, sinusitis.

INTRODUCTION

The incidence of nasopharyngeal carcinoma (NPC) is significantly higher in Taiwan than in Western countries, where cases are rarely seen.[1] Radiotherapy is the mainstay of treatment for NPC, despite complications that may arise from its use. Sinusitis, which significantly decreases the quality of life for patients, is commonly diagnosed following irradiation. In the nasal cavity, the clearance of most sinus secretions is mediated by the ostiomeatal complex. Disease in this area hinders the normal mucociliary clearance and, subsequently, leads to the development of sinusitis.[2] Irradiation, the focus of this study, influences the mucociliary clearance by damaging the ciliary motility. In effect, the clearance of exudate and secretions is delayed. Otitis media with effusion (OME) is commonly found, as supported by animal experiments conducted to evaluate the acute effects of irradiation on the middle ear mucosa.[3-5]

Previous studies have focused primarily on the correlation between irradiation and OME, with only limited attention given to the effects of irradiation on the pathogenesis of sinusitis. One should note that the middle ear mucosa and the nasal mucosa of the NPC patient are inadvertently exposed to different doses of irradiation during the treatment course. Such exposure may lead to differences in the effects of irradiation between these two sites. Thus, the present study was designed to examine the delayed effects of irradiation on the mucociliary system of the nasal infundibulum mucosa in patients with NPC.

SUBJECTS AND METHODS

Ten previously irradiated NPC patients who later received endoscopic choanoplasty for posterior choanal stenosis relief were enrolled in this study. Following the removal of the infundibulum mucosa lying between the uncinate process and the medial wall of the maxillary sinus, the specimen was immediately fixed in Karnovsky's fixative at 4°C overnight. After thorough washing in 0.1 mol/L phosphate buffered saline (PBS, pH 7.4), the samples were cut with a vibratome into 100-μm-thick sections and post-fixed in 1% osmium tetroxide. The post-fixed specimens were washed in PBS for several changes, rinsed in maleate buffer (pH 5.2), and then stained en bloc with uranyl acetate in maleate buffer at 4°C for 1 hour. The samples were then dehydrated in a series of increasing concentrations of acetonitrile and embedded in Epon.[6] Thick sections of 1 μm were made and stained with toluidine blue, and proper areas of sectioning were selected. Thin sections (70 to 90 nm) of the selected area were grid-stained with lead cit-

From the Department of Otolaryngology, National Taiwan University Hospital (Lou), and the Department of Anatomy, College of Medicine, National Taiwan University (Chen), Taipei, and the Department of Otolaryngology, Provincial Tao-Yuan Hospital, Tao-Yuan (Tai), Taiwan.
Supported by research grant 86-17 from the Provincial Tao-Yuan Hospital.

CORRESPONDENCE — Wen Pin Chen, PhD, Dept of Anatomy, College of Medicine, National Taiwan University, 1 Jen-Ai Road, Taipei, Taiwan.

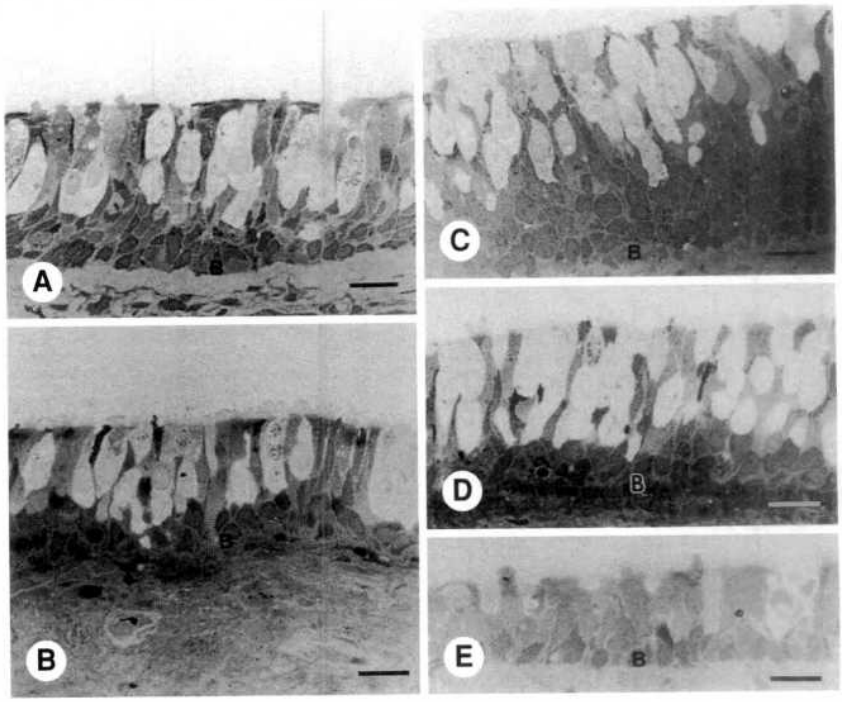

Fig 1. Light micrographs of infundibulum mucosa (toluidine blue stain). B — basal cells, bars — 5 μm. A) Normal. B) (Case 1) 0.8 years after irradiation. C) (Case 5) 4 years after irradiation. D) (Case 9) 10.6 years after irradiation. E) (Case 10) 23 years after irradiation.

rate. Specimens were viewed on a Hitachi H-7100 transmission electron microscope.

Control samples consisted of infundibulum mucosa from 2 groups of subjects: group 1 included 3 subjects who had no previous history of sinusitis and received septoplasty for their nasal septal deviation; group 2 included 3 patients with chronic sinusitis. The clinical history and radiologic findings of the patients with sinusitis were similar to those of the irradiated patients. These samples were collected and processed in the same manner as stated above. No subjects in the control group had prior exposure to irradiation. The above procedures were performed with the consent of the patients.

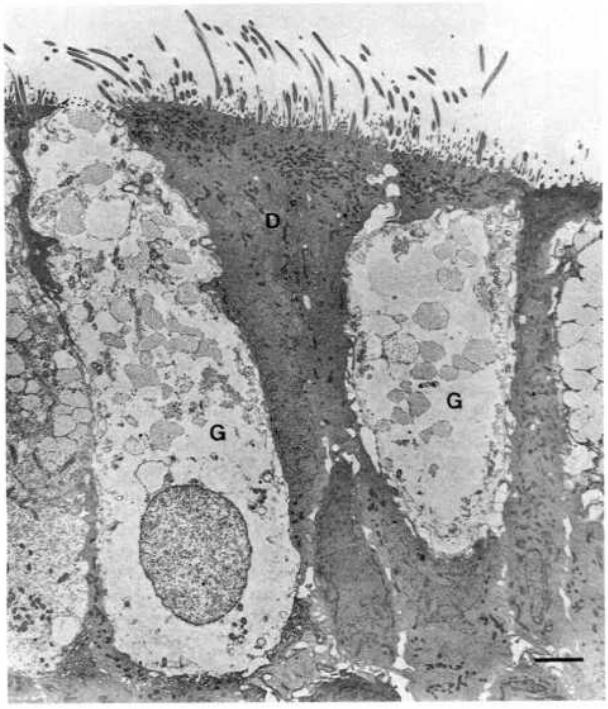

Fig 2. Electron micrograph of normal infundibular epithelium. D — dark cell, G — goblet cells, bar — 2 μm.

RESULTS

The infundibular mucosae of 10 irradiated NPC patients were collected in this study. The patients' mean age at the time of biopsy was 45 years (range 28 to 70 years), and the male-to-female ratio was 7:3. The average irradiation doses to the nasopharynx and infundibulum were 73 Gy (range 70 to 80 Gy) and 21 Gy (range 17.5 to 25 Gy), respectively, and the mean interval between irradiation and biopsy was 5.9 years (range 0.8 to 23 years). All patients suffered from symptoms of sinusitis; 4 received computed tomography and showed radiologic confirmation of sinusitis.

The normal infundibular mucosa consists of pseudostratified columnar epithelium with numerous goblet cells. The lamina propria of this mucosa was loosely arranged (Fig 1A). Following irradiation, the lamina propria showed an increase in deposition of dense collagenous fibers (Fig 1B). The cytoplasmic volume was gradually reduced, and the metaplasia of the epithelial cells assumed a stratified arrangement (Fig 1C-E).

Ultrastructurally, 2 types of ciliated cells could be noted on normal infundibular epithelium according to their electron density. The dark cells, which con-

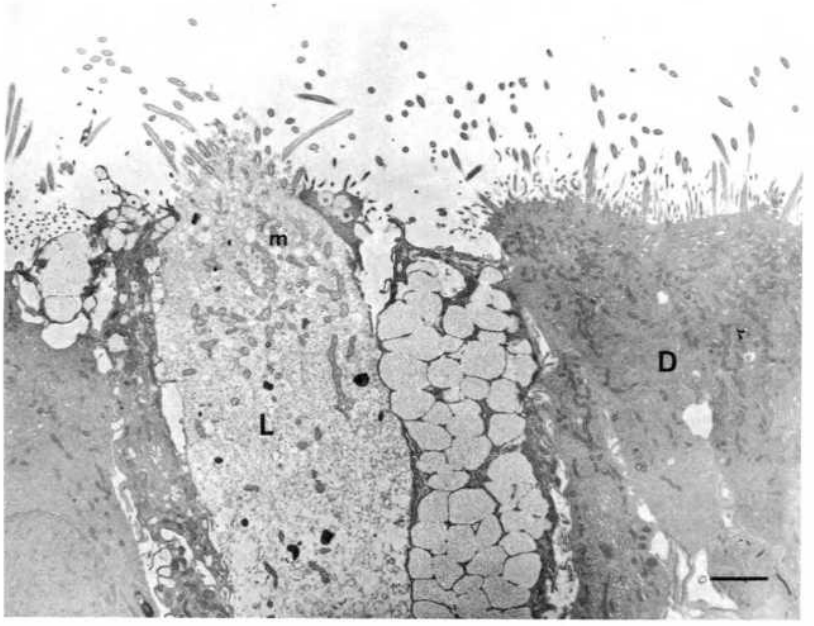

Fig 3. Electron micrograph of normal infundibular epithelium. D — dark cell, L — light cell, m — mitochondria, bar — 2 μm.

stituted most of the epithelial cells, had a cylindrical appearance and a relatively slender nucleus (Fig 2). The light cells, in contrast, were relatively few in number and were ovoid in shape, with a round nucleus. They could be differentiated from goblet cells by the apical accumulation of mitochondria and the lack of secretory granules (Fig 3). In the specimens of chronic sinusitis, areas of epithelial sloughs and ciliary loss could be frequently identified (Fig 4A). Expansion of intercellular spaces and intracellular vacuolations were also seen (Fig 4). Compound cilia could be noted occasionally, but supernumerary mi-

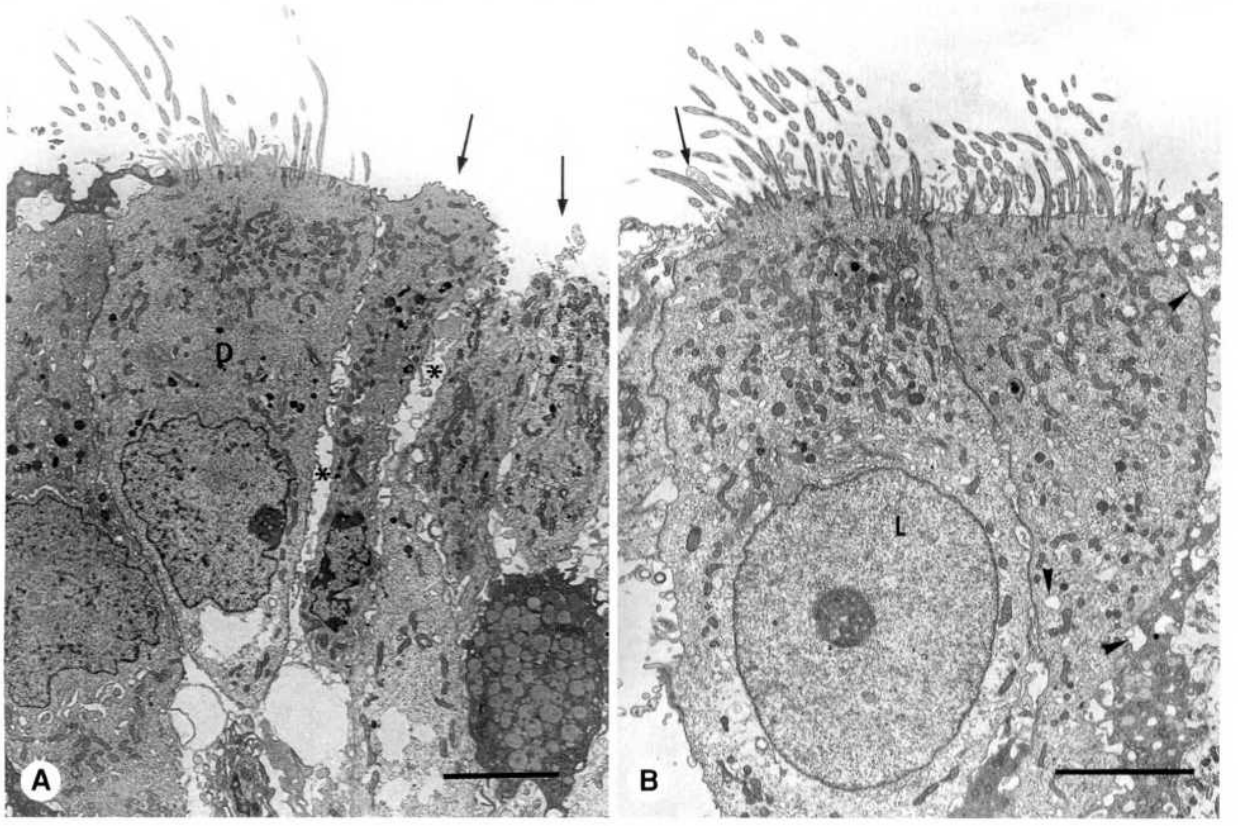

Fig 4. Electron micrographs of infundibular epithelium of chronic sinusitis patients. Bars — 5 μm. A) Expansion of intercellular spaces (asterisks) and loss of cilia (arrows). D — dark cell. B) Intracellular vacuolations (arrowheads) and swelling of microvilli (arrow). L — light cell.

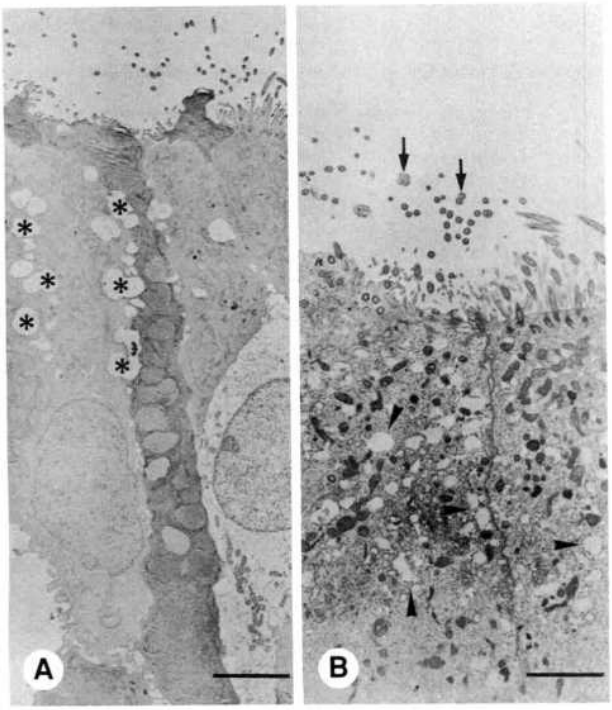

Fig 5. Intercellular and intracellular vacuolation was common finding after irradiation. Bars — 5 μm. A) Intercellular vacuolation (asterisks). B) Intracellular vacuolation (arrowheads) and compound cilia (arrows).

crotubules were not found in this study group.

After irradiation, marked intercellular and intracellular vacuolation was observed in most of the samples examined (Fig 5). Loss of cilia, which occurred mainly in the light cells, and sporadic falloff of the epithelial cells were also noted (Fig 6A). Furthermore, ciliary dysmorphism was clearly seen in areas of severely vacuolated epithelial cells (Fig 6B,C), where the presence of compound cilia (Fig 7A) exceeded that of supernumerary microtubules (Fig 7B,C). The microvilli, however, seemed more resistant to irradiation (Fig 8). Their numbers increased relatively, even in areas of ciliary degeneration. In both cases 9 and 10 of our study, the postirradiation interval surpassed 10 years; although cellular vacuolation was not observed in these cases, marked hyperplasia of the light cells was noted (Fig 9), and ciliary dysmorphism was also found. The Table summarizes the patients' basic information and ultrastructural findings.

DISCUSSION

Previous studies involving the middle ear mucosa have reported that irradiation induces acute effects, including vacuolation of ciliated cells, appearance of compound cilia, expansion of intercellular spaces, hyperreactivity of secretion, and stromal edema.[3-5] Another report evaluates the delayed effects on 6 patients at 6 to 11 months following irradiation; these included reduction of cytoplasmic mass, variable degrees of ciliary loss, and widened intercellular spaces.[7] The present study focused on the delayed effects of irradiation on the nasal epithelium; our results are quite compatible with these prior findings. The normal nasal epithelium is composed of 4 main cell types: ciliated epithelial cells, nonciliated epithelial cells, goblet cells, and basal cells.[8] These cells are arranged in a pseudostratified pattern on an underlying basement membrane. Our data suggest that ciliated cells can be classified into dark and light cells according to their electron density. In the control group, most of the epithelial cells examined were dark cells. Nonciliated epithelial cells were very few in number in the infundibulum area. After irradiation, intercellular and intracellular vacuolation were

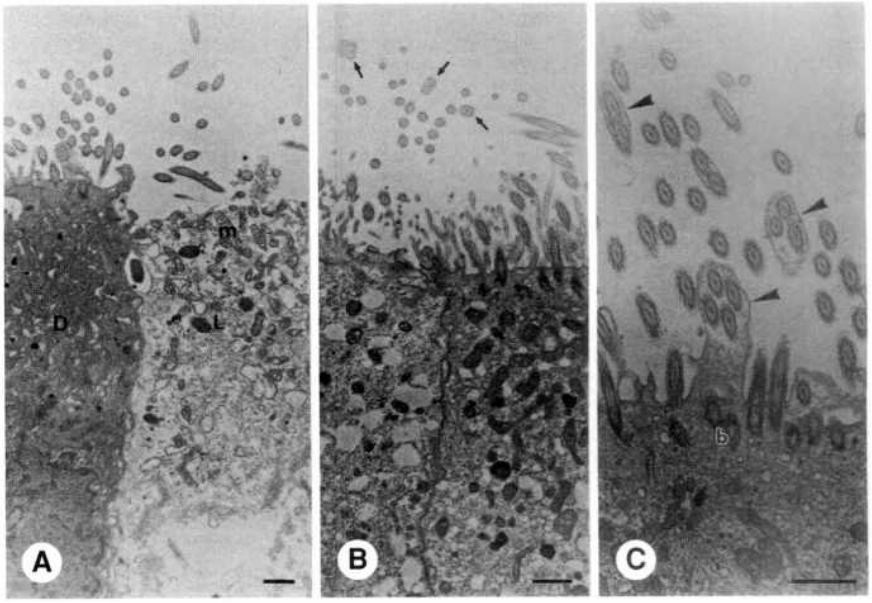

Fig 6. Areas of ciliary loss and dysmorphism. Bars — 1 μm. A) Ciliary loss occurs more frequently in light cells (L) than in dark cells (D). m — mitochondrion. B) Arrows indicate dysmorphic cilia above severely vacuolated cells. C) Higher magnification shows compound cilia (arrowheads) originating from top of epithelial cell. b — basal body.

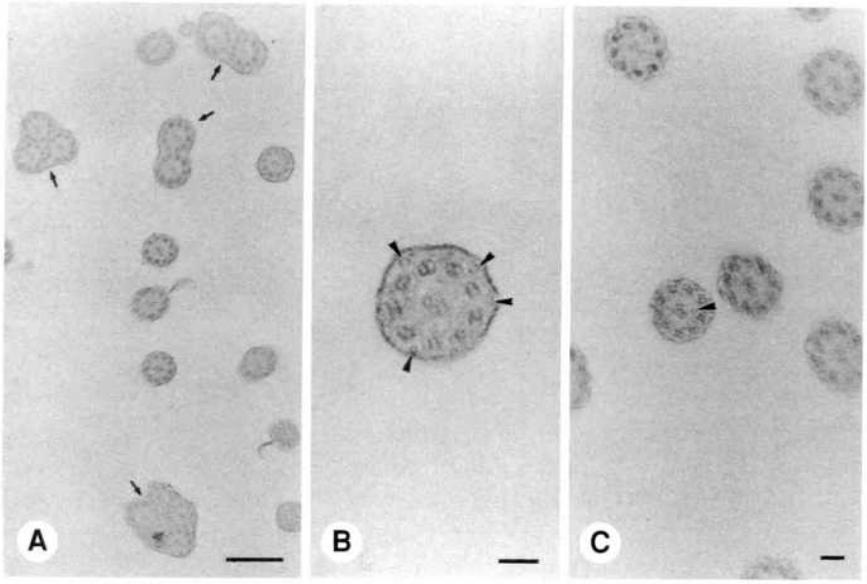

Fig 7. Electron micrographs of dysmorphic cilia cut in cross section. A) Compound cilia (arrows). Bar — 500 nm. B) Supernumerary single microtubules (arrowheads) outside 9 peripheral doublets. Bar — 100 nm. C) Supernumerary single microtubule (arrowhead) inside 9 peripheral doublets. Bar — 100 nm.

common. Areas of epithelial sloughing and ciliary loss were also frequently observed in our patients. However, intercellular or intracellular vacuolation was not noted in the 2 patients who survived beyond 10 years following radiotherapy. On the other hand, marked hyperplasia of the light cells could easily be observed in those 2 cases. The ciliary loss and cytoplasmic derangement seemed to occur mostly on the light cells. The increased numbers of light cells in cases 9 and 10 thus may have been a result of prolonged compensatory hyperplasia following irradiation. The microvilli, on the other hand, seemed to be more resistant than light cells to the effects of irradiation.

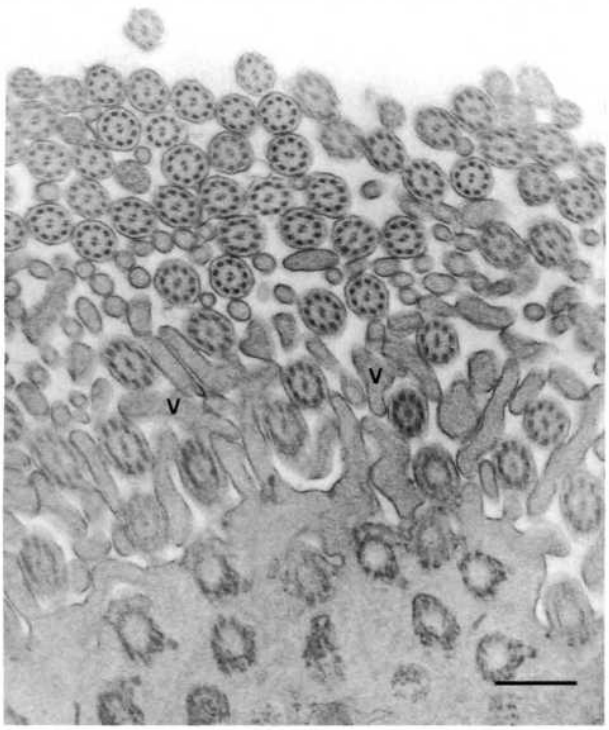

Fig 8. Microvilli (v) seem to be more resistant than light cells to irradiation. Their numbers appeared to increase relatively after irradiation. Bar — 500 nm.

Electron microscopy of normal cilia in cross section reveals a highly ordered configuration of 9 peripheral pairs of microtubules surrounding a central microtubular doublet.[9] Ciliary motility, conferred by bending motions of the ciliary shaft, is accomplished by the sliding of the peripheral pairs of microtubules.[10] In addition, there is evidence to indicate that the mutual alignment of the central ciliary microtubules of adjacent cilia is integral to the maintenance of beat synchrony.[11] Dysfunction of the cilia, which can compromise mucociliary transport, has been related to a variety of ultrastructural defects such as compound cilia[12] or supernumerary microtubules.[12,13] The occurrence of atypical cilia in normal human nasal mucosa is only about 4%.[12] Friedmann and Bird[14] and Takasaka et al[15] have stated that compound cilia are very rare in the nondiseased nose. Our data reveal that in areas of severely vacuolized epithelial cells, ciliary dysmorphism can easily be identified; compound cilia are the most frequently found. Additional single microtubules could also be noted both outside and within the 9 plus 2 complex. The finding of ciliary dysmorphism persisted even in the 2 patients who survived beyond 10 years following radiotherapy. On top of the epithelium of the chronic sinusitis patients in the control study, compound cilia could be occasionally identified. Expansion of the intercellular spaces and intracellular vacuolations could also be found. However, these findings were not as marked as those in the irradiated epithelium. On the basis of these results, we propose that irradiation-induced ciliary dysmorphism may compromise mucociliary transport of the sinuses

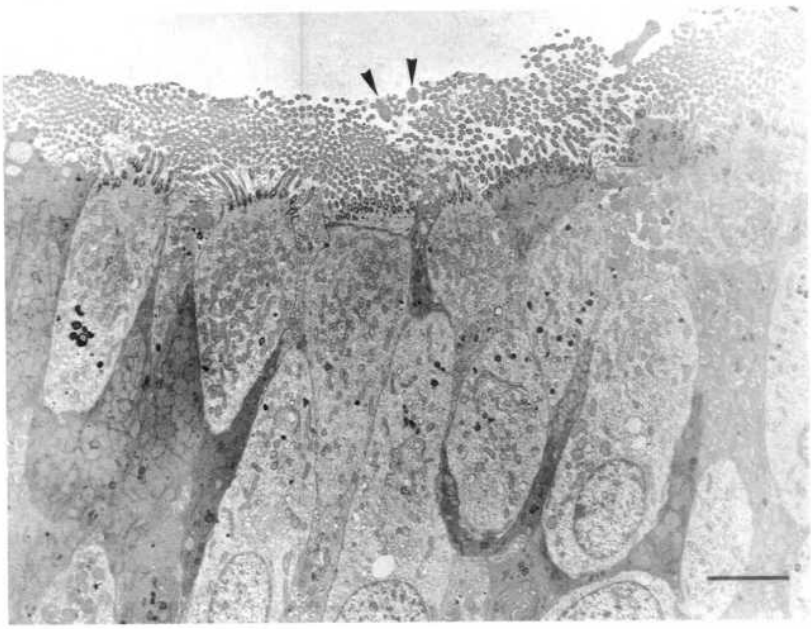

Fig 9. (Case 10) Marked hyperplasia of light cells is observed. Vacuolation is scarcely seen. Compound cilia (arrowheads) can be noted above epithelial cells. Bar — 5 μm.

and result in sinusitis. However, chronic infection itself may also induce the formation of dysmorphic cilia,[15,16] which subsequently exacerbate the already hampered mucociliary transport. This, in effect, becomes a vicious cycle in the pathogenesis of irradiation-induced sinusitis.

Quality of life is of primary concern, even in cancer patients. In the years before this study, we attemped to treat the sinusitis of irradiated NPC patients with functional endoscopic sinus surgery (FESS). Conceptually, the success of FESS is based on normal and healthy mucociliary transport. Compromised mucociliary transport leads to poor surgical results. The data of the present study suggest that irradiation-induced epithelial damage can persist as long as 23 years following radiotherapy, as seen in 1 of our patients. We have reason to believe that the mucociliary function is impaired in these patients. Thus, the effectiveness of FESS for the treatment of such cases should be reevaluated.

In conclusion, we have demonstrated delayed effects of irradiation on nasal epithelium in patients with NPC. The most notable difference from previous reports is that we used a much more representative definition of the "long-term" effects (average 5.9 years after the initial treatment) of irradiation. Pathologic findings included epithelial metaplasia, deposition of collagen fibers on the lamina propria, reduced cytoplasmic volume of the epithelial cells, intercellular and intracellular vacuolation, epithelial sloughing, ciliary loss, and ciliary dysmorphism. The findings presented herein provoke reconsideration of current treatments of sinusitis in irradiated NPC patients.

ULTRASTRUCTURAL CHANGES IN INFUNDIBULAR EPITHELIUM FOLLOWING IRRADIATION

Case	*Age*	*Sex*	*Interval Since Irradiation (y)*	*Estimated Irradiation Dose to Infundibulum (Gy)*	*Cilia Loss*	*Metaplasia*	*Vacuolation*	*Dysmorphic Cilia*
1	32	M	0.8	18	+	−	+	+
2	48	F	1.3	22	+	−	+	+
3	42	M	1.5	17.5	+	−*	−*	−*
4	42	M	1.5	21	+	−	+	+
5	41	M	4	22	+	+	+	+
6	70	F	4.5	22	+	−*	−*	−*
7	56	M	5	21	+	+	+	+
8	55	F	6.5	21	+	+	+	−
9	28	M	10.6	25	+	+	−	+
10	37	M	23	22	−	+	−	+

*Severe fibrosis of epithelium.

REFERENCES

1. Hsu MM, Tu SM. Nasopharyngeal carcinoma in Taiwan: clinical manifestations and results of therapy. Cancer 1983;52: 362-8.

2. Stammberger H. Endoscopic endonasal surgery. Concepts in treatment of recurring rhinosinusitis. Part I. Anatomic and pathophysiologic considerations. Otolaryngol Head Neck Surg 1986;94:143-6.

3. Panossian D, Jung TTK, Weeks D, et al. Effect of the radioprotector WR2721 on irradiation-induced injury to ciliated cells of eustachian tube. Ann Otol Rhinol Laryngol 1992;101: 395-402.

4. Ohashi Y, Nakai Y, Esaki Y, Onoyama Y. An experimental study of mucociliary pathology of the eustachian tube in otitis media with effusion induced by irradiation. Arch Otolaryngol Head Neck Surg 1989;246:428-32.

5. Ohashi Y, Nakai Y, Esaki Y, Ikeoka H, Koshimo H, Onoyama Y. Acute effects of irradiation on middle ear mucosa. Ann Otol Rhinol Laryngol 1988;97:173-8.

6. Edwards HH, Yeh YY, Tarnowski BI, Schonbaum GR. Acetonitrile as a substitute for ethanol/propylene oxide in tissue processing for transmission electron microscope comparison of fine structure and lipid solubility in mouse liver, kidney, and intestine. Microsc Res Tech 1992;21:39-50.

7. Elwany S. Delayed ultrastructural radiation induced changes in the human mesotympanic middle ear mucosa. J Laryngol Otol 1985;99:343-53.

8. Petruson B, Hansson HA, Karlsson G. Structural and functional aspects of cells in the nasal mucociliary system. Arch Otolaryngol 1984;110:576-81.

9. Afzelius BA. The immotile-cilia syndrome and other ciliary diseases. Int Rev Exp Pathol 1979;19:1-43.

10. Satir P. Studies on cilia III. Further studies on the cilium tip and a "sliding filament" model of ciliary motility. J Cell Biol 1968;39:77-94.

11. Eliasson R, Mossberg B, Camner P, Afzelius BA. The immotile-cilia syndrome: a congenital ciliary abnormality as an etiologic factor in chronic airway infections and male sterility. N Engl J Med 1977;297:1-6.

12. Rossman CM, Lee RMKW, Forrest JB, Newhouse MT. Nasal ciliary ultrastructure and function in patients with primary ciliary dyskinesia compared with that in normal subjects and in subjects with various respiratory diseases. Am Rev Respir Dis 1984;129:161-7.

13. Carsson JL, Collier AM, Hu SCS. Acquired ciliary defects in nasal epithelium of children with acute viral upper respiratory infections. N Engl J Med 1985;312:463-8.

14. Friedmann I, Bird ES. Ciliary structure, ciliogenesis, microvilli (electron microscopy of the mucosa of the upper respiratory tract). Laryngoscope 1971;81:1852-68.

15. Takasaka T, Sato M, Onodera A. Atypical cilia of the human nasal mucosa. Ann Otol Rhinol Laryngol 1980;89:37-45.

16. Howell JT, Schochet SS, Goldman AS. Ultrastructural defects of respiratory tract cilia associated with chronic infections. Arch Pathol Lab Med 1980;104:52-5.

FLOW CYTOMETRIC ANALYSIS OF BHRF1 EXPRESSION PROHIBITING APOPTOSIS INDUCED BY RADIATION

HAI HUANG, MD, PHD
STOCKHOLM, SWEDEN

XINGHUA PAN, MD, PHD
NEW HAVEN, CONNECTICUT

SHUIMIAO ZHOU, MD
SHANGHAI, PEOPLE'S REPUBLIC OF CHINA

ZHAOJI LI, MD
SHANGHAI, PEOPLE'S REPUBLIC OF CHINA

LONG YU, MD, PHD
SHANGHAI, PEOPLE'S REPUBLIC OF CHINA

XIANTAO KONG, MD, PHD
SHANGHAI, PEOPLE'S REPUBLIC OF CHINA

QIPING ZHENG, PHD
SHANGHAI, PEOPLE'S REPUBLIC OF CHINA

The Epstein-Barr virus gene BHRF1 has homology with proto-oncogene bcl-2, which can protect cells from apoptosis. In order to investigate the effect of BHRF1 expression on the anti-apoptotic ability of nasopharyngeal carcinoma (NPC) cells after irradiation, a high–BHRF1 expression vector was constructed and transfected into the NPC cell line CNE2. Then, the alteration of proliferation and apoptosis in the cells was tested by flow cytometry after cobalt 60 irradiation. The results showed that BHRF1 expression could increase G1 delay and decrease the cell percentage in S phase before irradiation, and reduce the apoptotic rate of CNE2 cells and increase the cell percentage in S phase after irradiation. The results suggest that BHRF1 expression is able to alter the cell cycle and protect CNE2 cells from apoptosis induced by radiation.

KEY WORDS — apoptosis, BHRF1 gene, radiation.

INTRODUCTION

Cells exposed to radiation may undergo death through apoptosis or mitotic inhibition. Apoptosis has also been reported in a variety of experimental tumor systems following therapeutic irradiation. But some factors, such as bcl-2, p53, and caffeine, can affect cell cycle redistribution and radiosensitivity. The bcl-2 gene family is a molecular target by which radiation-induced apoptosis can be modulated. One feature of bcl-2 is its ability to block apoptosis induced by ionizing radiation. Down-regulation of bcl-2 is closely related to the appearance of DNA fragmentation after exposure to ionizing radiation.[1]

The BHRF1 of Epstein-Barr virus (EBV) is an immediate early protein that has homology with bcl-2 oncogene.[2] In order to determine the effects of BHRF1 expression on the anti-apoptotic ability of nasopharyngeal carcinoma (NPC) cells in vitro, we constructed a high–BHRF1 expression vector, BHRF1-pcDNA3, and transfected it into the NPC cell line CNE2, a non-EBV genome subclone, and then irradiated it with cobalt 60 (^{60}Co) to test the alteration of proliferation and apoptosis in the cells.

MATERIALS AND METHODS

Plasmid Reconstruction of High–BHRF1 Expression Vector. The BHRF1-pSG5 (Dr Dawson, Britain) and pcDNA3 were digested with XBaI and EcoRI (Pharmacia). Fragments of BHRF1 and pcDNA3 were collected and purified by agarose gel electrophoresis, and ligated by T4 DNA ligase (Promega) at 14°C overnight. Then they were transformed to a competent JM109 host and selected with ampicillin sodium. Desired recombinants were selected by XBaI and EcoRI digest analysis.

Stable Transfection of BHRF1-pcDNA3 Plasmid by Liposome. In a 35-mm tissue culture plate, 1×10^5 cells were seeded in 2 mL of RPMI 1640 with 20% fetal calf serum and incubated at 37°C in a carbon dioxide (CO_2) incubator until about 80% confluent. In 1 test tube, 1 μg of BHRF1-pcDNA3 was diluted into 100 μL of serum-free medium, and in another test tube, 20 μL of liposome (Gibco Bio-Rad Laboratories) was diluted into 100 μL of serum-free medium. The 2 solutions were combined, mixed gently, and incubated at room temperature for 45 minutes to allow DNA-liposome complexes to form. Then, 0.8 mL of serum-free medium was added to the tube containing the complexes. The diluted complex solution was mixed gently and overlaid onto the rinsed cells, and then incubated for 5 hours at 37°C in a CO_2 incubator. Following incubation, 1 mL of complete growth medium containing twice the normal concentration of serum was added. The medium was replaced with fresh, complete medium

From the Microbiology and Tumor Biology Center, Karolinska Institute, Stockholm, Sweden (Huang); the Boyer Center for Molecular Medicine, Yale School of Medicine, New Haven, Connecticut (Pan); and the Department of Otolaryngology, Changhai Hospital (Zhou, Li), and the Clinical Immunology Center of the People's Liberation Army, Changzheng Hospital (Kong), the Second Military Medical University; and the State Key Laboratory of Genetic Engineering, Institute of Genetics, Fudan University (Yu, Zheng); Shanghai, People's Republic of China.

CORRESPONDENCE — Hai Huang, MD, PhD, Microbiology and Tumor Biology Center, Box 280 Karolinska Institute, S-171 77 Stockholm, Sweden.

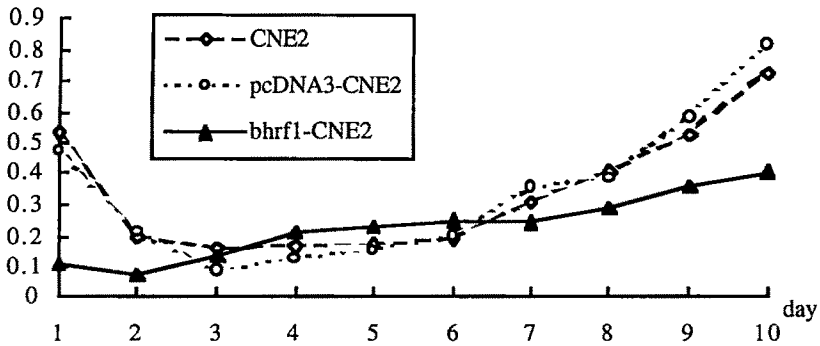

Effect of BHRF1 expression on proliferation of CNE2 cells after irradiation.

at 24 hours following the start of transfection. At 72 hours after transfection, the CNE2 clones expressing BHRF1 had generated with a suitable neoresistant gene. Stable, drug-resistant clones were selected and isolated in medium containing 400 μg/mL G418 (Gibco). A single G418-resistant clone was subsequently expanded for further analysis. At the same time, pcDNA3 plasmid was also transfected into CNE2 cells as a control.

Testing for BHRF1 Expression in Transfectant by Northern Blot Hybridization Analysis. CNE2 cells, pcDNA3-CNE2, and BHRF1-CNE2 cells were cultured in RPMI 1640 with 20% fetal calf serum, 2-mmol/L glutamine, and the antibiotics penicillin (1,000 U/mL) and streptomycin (1 mg/mL) for 24 hours, at 37°C with 5% CO_2. Total RNA was extracted by an Rneasy Total RNA Kit (Qiagen), electrophoresed in 1% agarose gel at 4 V/cm for 3 hours, and transferred to nylon membrane with a capillary blot. The membrane was baked to fix at 80°C for 2 hours, washed, and pretreated for hybridization. BHRF1 fragment was labeled by random priming (Megaprime TM DNA labeling system, Amersham), filtered by a G50 pillar, and boiled for 10 minutes. The probe was added to hybridize 18 hours in an incubator at 42°C. Then the membrane was rinsed and exposed to x-ray film in a film cassette at –80°C.

Testing BHRF1 in Genome of Transfectant by Fluorescent In Situ Hybridization Test. CNE2 cells and BHRF1-CNE2 cells were cultured for 72 hours, fixed with fixative solution, baked at 74°C, digested with 100 μg/mL ribonuclease at 37°C for 1 hour, denatured in formamide/twice sodium chloride and sodium citrate at 70°C for 2 minutes, and treated with 100 ng/mL proteinase K at 37°C for 7 minutes. Biotin-labeled probe (Biotin-Nick Translation Mix, Sigma) was synthesized and hybridized with the cells at 37°C overnight. Then the cells were washed and successively incubated for 30 minutes each with avidin–fluorescein isothiocyanate (FITC), mouse anti-avidin-FITC, rabbit anti-mouse IgG-FITC, and propidium iodide.

Effect of BHRF1 Expression on Proliferation of CNE2 Cells After Irradiation. In a 96-well culture plate, BHRF1-CNE2 cells, vector controls, or CNE2 cells were seeded at a density of 3×10^3 per well. After cultivation for 24 hours, they were irradiated with ^{60}Co at 6 Gy and cultivated for another 10 days. The cell viability in 3 wells of each group was measured with MTT (3-[4,4-dimethylthiazol-2-yl]-2,5-diphenyl tetrazolium bromide) each day.

Cell Cycle Redistribution After Irradiation. BHRF1-CNE2 cells, vector controls, or CNE2 cells were irradiated with ^{60}Co at 8 Gy, harvested as single cell suspensions by 0.25% trypsinization, fixed in 70% ethanol, stained with 0.05% propidium iodide at a final concentration of 10^6 cells per milliliter overnight, and incubated at 37°C with 10 μg/mL ribonuclease for 20 minutes. The DNA distribution was analyzed by FACScan (Becton Dickinson), and the percentage of cell cycle phases was calculated by the SOBR (sum of broadened rectangles) model in cellFIT. Dead and fragmenting cells were gated out in the FACScan analysis.

RESULTS

Analysis of BHRF1-Expressing Recombinants. BHRF1-pcDNA3 and BHRF1-pSG5 were digested with XBaI and EcoRI, and electrophoresed in 1% agarose gel. It was found that there was one 0.9 kb fragment on each plasmid, which suggested that desired recombinants were constructed successfully.

Expression of BHRF1 in Stable Transfectants. By Northern blot hybridization analysis, a positive result was shown in the RNA of BHRF1-CNE2 cells, but not in the control cells.

Testing BHRF1 in Genome of Transfectant by Fluorescent In Situ Hybridization Test. There was a positive reaction in the genome of BHRF1-CNE2 cells, which suggested that BHRF1 expression vectors existed in the genome of the transfectant.

Effect of BHRF1 Expression on Proliferation of CNE2 Cells After Irradiation. The population of vector-CNE2 and CNE2 cells was greater than that of BHRF1-CNE2 cells on the day before irradiation, and obviously reduced after irradiation. The prolif-

FLOW CYTOMETRIC ANALYSIS OF EXPRESSION OF BHRF1 PROHIBITING CELL APOPTOSIS OF CNE2 CELLS INDUCED BY RADIATION

	Before Irradiation				*After Irradiation*			
	Apoptotic Phase	*G1 Phase*	*G2 Phase*	*S Phase*	*Apoptotic Phase*	*G1 Phase*	*G2 Phase*	*S Phase*
CNE2	0.4	46.6	17.2	36.2	14.5	42.6	18.2	39.2
pcDNA3-CNE2	0.5	48.5	18.4	33.1	16.7	46.5	16.4	37.1
BHRF1-CNE2	0.2	59.2	23.2	17.6	3.0	49.1	10.2	40.1

Data are percent.

eration of vector-CNE2 and CNE2 cells was slow from the third day to the sixth day, and increased after the sixth day, while the population of BHRF1-CNE2 cells decreased slightly after irradiation, and obviously increased in the following 2 days. From the fifth day, BHRF1-CNE2 cells showed slow and constant proliferation (see Figure).

Cell Cycle Redistribution After Irradiation. Before irradiation, there was a higher BHRF1-CNE2 cell percentage in G1 phase and a lower cell percentage in S phase than in control groups ($.01 < p < .05$). After irradiation, the BHRF1-CNE2 cell percentage in G1 phase decreased and that in S phase increased, with an extraordinary significant difference before and after treatment ($p < .01$), while there was no significant difference between control groups. The apoptotic rate of BHRF1-CNE2 cells was obviously less than that of control groups ($p < .01$, χ^2 test) after irradiation (see Table).

DISCUSSION

Radiation can induce programmed cell death in the progenitor cells of testicular, intestinal, renal, and neuronal cell renewal systems.[3] But some factors, such as bcl-2, p53, staurosporine, and caffeine, can affect the radiosensitivity of the cells. Overexpression of bcl-2 correlates with resistance to radiation, and low or absent bcl-2 expression generally increases radiosensitivity.[4] One mechanism of enhancing cell killing by radiation is to trigger apoptosis by decreasing the G2 delay induced by irradiation. Caffeine has profound effects on the cell cycle of irradiated cells. Cells undergo a division delay with a prolongation of G2 after irradiation. This G2 delay is greatly reduced by treatment of the irradiated cells with caffeine.[5] Treatment of Hela cells with caffeine has been shown to shorten the G2 delay after irradiation and to decrease their survival.[6] The kinase inhibitor staurosporine also decreases the radiation-induced G2 delay in Hela cells. These reports suggested that reducing the length of the G2 delay can cause increased cell killing.[5-7] Other investigators have shown that apoptosis is promoted by caffeine and staurosporine in Hela cells arrested in S phase by hydroxyurea treatment.[8] Wild-type p53 is required for the induction of a G1 delay by ionizing radiation.[9] Cells that are p53-negative are more susceptible to caffeine potentiation of radiation killing, presumably as a result of the combined loss of the G1 checkpoint.[10]

BHRF1 is an immediate early protein and present in all natural EBV isolates so far examined.[11] BHRF1 has significant colinear sequence similarity with the proto-oncogene bcl-2, which can protect B cells from apoptosis.[12,13] Expression of bcl-2 from retrovirus vectors or from transgenes in mice has led to expanded resting B-cell populations and contributed to B-cell neoplasia.[14,15] The BHRF1 product has been localized at the periphery of the mitochondria in a pattern similar to that of bcl-2. These findings suggest that BHRF1 and bcl-2 are functionally and mechanistically similar in promoting the survival of cells exposed to various apoptotic stimuli. This promotion of cell survival is associated with a block in proliferation.[16] BHRF1 was found to render Burkitt's lymphoma cells more resistant to programmed cell death induced by either serum withdrawal or by addition of calcium ionophore, and also was able to suppress apoptosis induced by various DNA-damaging agents.[17,18]

In our experiment, CNE2 cells were sensitive to ^{60}Co, which prohibited the proliferation of the cells and caused cell apoptosis, while BHRF1 expression increased G1 delay and decreased cells in S phase, thereby reducing the proliferation and the sensitivity to radiation of the cells. After irradiation, BHRF1 reduced the apoptosis of CNE2 cells and increased the cell percentage in S phase; this finding suggested that DNA synthesis in the tumor cells is active in strengthening restorative ability after irradiation. Our data indicate that BHRF1 expression is able to alter the cell cycle and protect CNE2 cells from apoptosis induced by radiation.

REFERENCES

1. Chen M, Quintans J, Fuks Z, Thompson C, Kufe DW, Weichselbaum RR. Suppression of bcl-2 messenger RNA production may mediate apoptosis after ionizing radiation, tumor necrosis factor α, and ceramide. Cancer Res 1995;55:991-4.

2. Dawson CW, Eliopoulos AG, Dawson J, Young LS. BHRF1, a viral homologue of the bcl-2 oncogene, disturbs epithelial cell differentiation. Oncogene 1995;9:69-77.

3. Aruga T, Ando K, Iizuka M, et al. Radiosensitivity and cell cycle redistribution of cultured human tumor cells during fractionated daily 2-Gy irradiations. Int J Radiat Biol 1995;67: 65-70.

4. Mothersill C, O'Malley K, Harney J, Lyng F, Murphy DM, Seymour CB. Further investigation of the response of human uroepithelium to low doses of cobalt-60 gamma radiation. Radiat Res 1997;147:156-65.

5. Palayoor ST, Macklis RM, Bump EA, Coleman CN. Modulation of radiation-induced apoptosis and G2/M block in murine T-lymphoma cells. Radiat Res 1995;141:235-43.

6. Bernhard EJ, Muschel RJ, Bakanauskas VJ, McKenna WG. Reducing the radiation-induced G2 delay causes Hela cells to undergo apoptosis instead of mitotic death. Int J Radiat Biol 1996;69:575-84.

7. Fan S, Smith ML, Duba D, Zhan Q, Kohn KW, O'Connor PM. Disruption of P53 function sensitizes breast cancer MCF-7 cells to cisplatin and pentoxifylline. Cancer Res 1995;55:1649-54.

8. Meikrantz W, Gisselbrecht S, Tam SW, Schlegel R. Activation of cyclin A–dependent protein kinases during apoptosis. Proc Natl Acad Sci U S A 1994;91:3754-8.

9. O'Connor PM, Jackman J, Jondle D, Bhatia K, Magrath I, Kohn KW. Role of the p53 tumor suppressor gene in cell cycle arrest and radiosensitivity of Burkitt's lymphoma cell lines. Cancer Res 1993;53:4776-80.

10. Merritt AJ, Potten CS, Kemp CJ, Hickman JA, Balmain A, Lane DP. The role of p53 in spontaneous and radiation-induced apoptosis in the gastrointestinal tract of normal and p53-deficient mice. Cancer Res 1994;54:614-7.

11. Heller M, Dambaugh T, Elliott K. Epstein-Barr virus DNA. IX. Variation among viral DNAs from producer and nonproducer infected cells. J Virol 1981;38:632-48.

12. Cleary ML, Smith SD, Sklar J. Cloning and structural analysis of cDNAs for bcl-2 and a hybrid bcl-2/immunoglobulin transcript resulting from the t(14;18) translocation. Cell 1986;47:19-28.

13. Hockenbery D, Nunez G, Milliman C, Schreiber RD, Korsmeyer SJ. bcl-2 Is an inner mitochondrial membrane protein that blocks programmed cell death. Nature 1990;348:334-6.

14. McDonnell TJ, Nunez G, Platt FM, et al. Deregulated bcl-2–immunoglobulin transgene expands a resting but responsive immunoglobulin M– and D–expressing B-cell population. Mol Cell Biol 1991;349:254-6.

15. Nunez G, Seto M, Seremetis S, et al. Growth- and tumor-promoting effects of deregulated BCL2 in human B-lymphoblastoid cells. Proc Natl Acad Sci U S A 1989;86:4589-93.

16. Hickish T. Ultrastructural localization of BHRF1: an Epstein-Barr virus gene product which has homology with bcl-2. Cancer Res 1994;54:2808-11.

17. Henderson S, Huen D, Rowe M, Dawson C, Johnson G, Rickinson A. Epstein-Barr virus–coded BHRF1 protein, a viral homologue of bcl-2, protects human B cells from programmed cell death. Proc Natl Acad Sci U S A 1993;90:8479-83.

18. Tarodi B, Subramanian T, Chinnadurai G. Epstein-Barr virus BHRF1 protein protects against cell death induced by DNA-damaging agents and heterologous viral infection. Virology 1994;201:404-7.

GLANDULAR CARCINOMA OF THE LARYNX: THE UCLA EXPERIENCE

SASSAN ALAVI, MD
THOMAS C. CALCATERRA, MD
ALI NAMAZIE, MD
KEITH E. BLACKWELL, MD
LOS ANGELES, CALIFORNIA

Glandular carcinomas of the larynx are rare tumors that constitute less than 1% of all laryngeal malignancies. A retrospective case review of 12 patients with glandular carcinomas of the larynx is presented to identify patient and tumor characteristics, therapeutic modalities, and treatment outcomes. Ten patients underwent surgical excision of the primary tumor, by either supraglottic laryngectomy, vertical partial laryngectomy, or total laryngectomy. Seven of these patients also received postoperative radiotherapy. After a median follow-up period of 23 months, 7 of the 12 patients (58.3%) died as a result of uncontrolled locoregional disease or distant metastases. The 5-year survival rate was 57% in patients who underwent combination therapy versus 50% for those patients who received surgery alone. Surgical resection is the primary treatment modality used in the majority of cases. Neck dissection is reserved for patients with clinically apparent adenopathy, adenocarcinoma, or high-grade mucoepidermoid carcinoma. Combination therapy with surgical resection and radiotherapy may be more effective in achieving tumor remission than is surgical resection alone.

KEY WORDS — carcinoma, gland, larynx.

INTRODUCTION

Squamous cell carcinoma accounts for greater than 99% of all laryngeal malignancies. By comparison, nonsquamous carcinomas are very rare. The distribution of the nonsquamous carcinomas of the larynx follows the anatomic distribution of the laryngeal subepithelial salivary glands and intraepithelial mucous glands. The larynx has a rich supply of salivary glands, primarily of the mixed seromucous type, which function in an exocrine manner. The glands are not uniformly distributed throughout the larynx. They are mostly concentrated in the saccule, the subglottic surface of the anterior commissure, and the ventricular folds. In addition, they are also sparsely distributed on the epiglottis, arytenoids, and ventricular sulci.[1]

Glandular carcinomas of the larynx consist of a histologic array of tumors, most commonly adenoid cystic carcinoma, mucoepidermoid carcinoma, and adenocarcinoma.[2,3] Because of the rarity of this tumor in the larynx, no series has been large enough to permit statistical evaluation of treatment modalities. This report summarizes the University of California Los Angeles (UCLA) experience with glandular carcinomas of the larynx over a 38-year period.

PATIENTS AND METHODS

A computer-assisted search of the UCLA Medical Center Department of Pathology archives revealed 1,891 laryngeal specimens processed between 1950 and 1988 that showed carcinoma, dysplasia, or keratosis. Review of the pathology reports identified 1,547 invasive squamous carcinomas and 15 invasive nonsquamous carcinomas. During this time period, 12 patients with glandular carcinomas of the larynx were treated at UCLA Medical Center. All cases were surgically confirmed to be originating from the larynx and histologically confirmed to be nonsquamous. Tumors that originated from the base of the tongue, hypopharynx, or trachea were excluded from analysis. Table 1 details the site of origin and the distribution of these carcinomas within the larynx.

The medical records of the patients were reviewed to determine tumor histologic type, site, size, presenting symptoms, therapeutic modalities, risk factors, and outcome. In some cases, additional follow-up was obtained by telephone interview of patients or their family members. Follow-up of 10 months to 156 months was available in all 12 cases, with a median follow-up period of 23 months. Survival data were calculated by the Kaplan-Meier life table method. Each patient was staged according to the American Joint Committee on Cancer (AJCC) staging system for laryngeal tumors.[4] Tumor origins were classified as supraglottic, glottic, or subglottic. Postoperative radiotherapy was administered by megavoltage equipment with either cobalt 60 or a 10-MV linear accelerator.

From the Department of Surgery, Division of Head and Neck Surgery, University of California Los Angeles School of Medicine, Los Angeles, California.

CORRESPONDENCE — Keith E. Blackwell, MD, Box 951624 UCLA Medical Center, Los Angeles, CA 90095-1624.

TABLE 1. HISTOPATHOLOGY AS RELATED TO SITE OF ORIGIN

Type	*Glottic*	*Supraglottic*	*Subglottic*	*Total*
Adenoid cystic carcinoma	1	1	3	5
Mucoepidermoid carcinoma	3	2	0	5
Adenocarcinoma	0	2	0	2

The ages of the patients at the time of diagnosis ranged from 46 to 83 years, with a mean age of 61.5 years. There was no significant age variation by tumor histologic type. The average age at presentation was 60 years for adenoid cystic carcinoma, 59 years for adenocarcinoma, and 63 years for mucoepidermoid carcinoma. There were 6 men and 6 women. Seven of the patients had a history of smoking tobacco. The initial presenting complaint of the patients varied depending on the location of the tumor. Five patients with supraglottic tumors presented with dysphagia or hoarseness. Three patients with subglottic tumors presented with shortness of breath, and 4 patients with glottic tumors presented with hoarseness.

The AJCC staging system was used to categorize these tumors.[4] One case was stage T1, 2 cases were stage T2, 7 cases were stage T3, and 2 cases were stage T4 at presentation. Three patients had metastatic cervical adenopathy at the time of presentation. No patient presented with distant metastases. Table 2 demonstrates the stage of tumor as a function of tumor location.

RESULTS

Two patients received no definitive treatment following biopsy. One patient refused any further therapy. The second patient was judged to have an unresectable tumor for which a palliative tracheotomy was performed. One of these patients had a supraglottic adenocarcinoma, while the other presented with a supraglottic mucoepidermoid carcinoma. They died at 10 and 22 months respectively, after diagnosis.

Treatment for attempted cure was undertaken in 10 patients, who underwent surgery. The type of surgical procedure was determined by the location and extent of the tumor. Total laryngectomy was the approach taken in 7 of the 10 patients (70%) who underwent surgery. Two patients underwent vertical hemilaryngectomy, and 1 underwent a supraglottic laryngectomy. The surgical margins were positive in 2 of the 3 patients who underwent partial laryngeal surgery. Of the 7 patients who underwent a total laryngectomy, only 1 had positive margins. Both patients with positive surgical margins and partial laryngeal surgery had extensive submucosal extension that accounted for the presence of tumor at the resection margins. Seven patients received postoperative radiotherapy, including those with positive surgical margins. In the 10 patients who received definitive therapy, uncontrolled local and/or metastatic disease was the cause of death in 5 patients. Three patients died prior to 2 years, 1 patient died after 59 months, and the remaining patient died after 95 months. The overall 2- and 5-year survival rates were 56.5% and 45.2%, respectively, in the 12 patients of this series. These data are summarized in Table 3.

TABLE 2. CLINICAL STAGE ACCORDING TO SITE

Stage	*Glottic*	*Supraglottic*	*Subglottic*	*Total*
I	0	0	1	1
II	1	0	0	1
III	2	3	1	6
IV	1	2	1	4

TABLE 3. ACTUARIAL SURVIVAL DATA ACCORDING TO TUMOR TYPE

Survival (y)	*Adenocarcinoma*	*Adenoid Cystic Carcinoma*	*Mucoepidermoid Carcinoma*	*Total*
2	0	100	33.3	56.5
5	0	75	33.3	45.2

Data are percent.

Seven patients in this study received combination therapy consisting of surgical excision and postoperative radiotherapy, while 3 patients underwent surgical excision alone. The 5-year survival rate was 57% in patients who underwent combination therapy versus a 5-year survival rate of 50% for those patients receiving surgical excision as their sole mode of therapy. Given the small size of this series of patients, this difference was not statistically significant ($\chi^2 = 0.032$, $p > .05$). Table 4 depicts survival by treatment modality. Of the 3 patients who underwent partial laryngectomy, 2 died within 2 years of diagnosis and 1 was alive at 18 months of follow-up without evidence of recurrent disease. Both patients who died had positive surgical margins. Of the patients who had a total laryngectomy performed, 2 were dead within 5 years of diagnosis and 1 patient died within 10 years of diagnosis. Of these, only 1 had positive surgical margins.

TABLE 4. ACTUARIAL SURVIVAL DATA ACCORDING TO TREATMENT MODALITY

Survival (y)	*No Treatment*	*Surgery and Radiotherapy*	*Surgery Alone*
2	0	57	100
5	0	57	50

Data are percent.

DISCUSSION

Minor salivary glands are found throughout the oral cavity, oropharynx, larynx, and hypopharynx, and these structures may give rise to various types of neoplasms.[5-9] The palate is the most common site of occurrence of minor salivary gland tumors.[10] Minor salivary gland tumors are rare in the larynx. The prevalence of these tumors in the larynx ranges from 0.1% to 1% of all laryngeal neoplasms.[11,12] At our institution, nonsquamous carcinomas represented only 0.96% of 1,562 laryngeal carcinomas diagnosed by the Department of Pathology during a 38-year period. In the past 30 years, there have been approximately 200 cases of laryngeal glandular carcinomas reported in the English-language literature. Within the larynx, these glandular neoplasms are almost always malignant[9] and comprise a great histologic diversity.[13,14] Adenocarcinoma, adenoid cystic, and mucoepidermoid carcinomas are most commonly reported, and no etiologic factor has been clearly demonstrated in their pathogenesis.

Tobacco exposure is the most frequently identified etiologic agent for squamous cell carcinoma of the larynx. While approximately 90% of patients who develop laryngeal squamous cell carcinoma report a history of tobacco exposure,[15] only 58% of the patients in the current series reported a history of tobacco usage. While squamous cell carcinoma of the larynx occurs more frequently in men, there was an equal proportion of men and woman with laryngeal glandular carcinoma in the current study. This study found no difference in the average age of patients presenting with squamous versus nonsquamous carcinoma of the larynx, nor with adenoid cystic carcinoma versus adenocarcinoma of the larynx. This latter finding is in contrast to previous studies, which found a younger age at presentation with adenoid cystic carcinoma.[16,17]

Glandular carcinomas of the larynx originate from subepithelial glands,[18] tend to spread submucosally, and usually present as an exophytic growth with intact overlying mucous membrane. Because of this predilection for submucosal growth, most patients present with locally advanced tumors at the time of diagnosis. Eighty-three percent of our patients presented with T3 or T4 lesions at the time of diagnosis. While many epidermoid cancers of the glottis present at an early stage due to early-onset hoarseness, patients with glottic glandular tumors tend to present with advanced-stage disease, due to extensive submucosal tumor spread.

Tumor distribution closely follows the distribution pattern of minor salivary glands within the larynx. There is an increase in the density of minor salivary glands as one proceeds from the subglottis to the supraglottis. In the current series, 75% of tumors originated from the glottis and supraglottis, in areas of high glandular concentration. Thus, the appearance of a submucosal mass at the anterior commissure, saccule, or epiglottis should alert the examiner to the possibility of a glandular carcinoma.[13,18,19]

Presenting symptoms depend upon the tumor location. With subglottic tumors, patients usually present with shortness of breath related to airway obstruction, while patients with glottic tumors usually present with hoarseness. With supraglottic tumors, presenting symptoms depend on the size and location of the tumor, as well as the degree of involvement of adjacent structures. Inferior extension to the vocal folds will produce hoarseness. Posterior, lateral, or superior extension may produce dysphagia. A bulky supraglottic tumor may eventually also produce airway compromise. While other series report pain as a prominent symptom in adenoid cystic carcinoma,[19,20] this was not observed in this series. None of the patients in the current series reported pain as their presenting symptom.

At the time of diagnosis, 4 patients presented with regional metastases, while none had evidence of distant metastatic disease. Batsakis et al[11] found a higher incidence of lymph node involvement in adenocarcinoma as compared to adenoid cystic carcinoma — a difference also noted in this series. Both of the patients in this study presenting with adenocarcinoma were found to have cervical adenopathy at the time of presentation. The other 2 patients with regional metastases exhibited intermediate to high-grade mucoepidermoid carcinoma. None of the patients with adenoid cystic carcinoma presented with cervical metastasis. In the patients with neck metastasis, 3 of the primary lesions were located in the supraglottic region and only 1 was located in the glottis.

Different treatments have been suggested for nonsquamous carcinomas of the larynx, ranging from laryngeal sparing surgery to total laryngectomy and ipsilateral neck dissection, regardless of the tumor type or extent.[16,18,20] Given the rarity of glandular carcinomas of the larynx, it is difficult to make definitive treatment recommendations. It would be impossible to accrue enough patients to compare treatment modalities in a prospective fashion, and indeed it is unlikely that any single institution's experience would be large enough to perform a retrospective analysis that achieved statistical significance. The 5-year survival of patients who had a total laryngectomy performed was 67%, as compared to 33% for those who had a partial laryngectomy. Surgical margins were positive in 67% of patients who had a par-

tial laryngectomy, while those who received a total laryngectomy had only a 14% incidence of positive surgical margins. Due to the high incidence of submucosal tumor spread and the resulting incomplete tumor excision, it appears that partial laryngectomy may be an inadequate approach when compared to total laryngectomy in the treatment of glandular carcinomas of the larynx. On the basis of our limited experience with glandular carcinomas of the larynx and our larger experience with minor salivary gland cancers of other sites in the upper aerodigestive tract, we recommend ipsilateral neck dissection for patients who present with cervical adenopathy, adenocarcinoma, or high-grade mucoepidermoid carcinoma. According to our data, glandular carcinomas of the supraglottis have a higher chance of cervical metastasis than those of the glottis or subglottis.

Postoperative radiotherapy has been recommended in the past for treatment of glandular carcinomas of the larynx.[21] We suggest postoperative radiotherapy, especially in cases in which the surgical margins are close or there are regional metastases. A previous series from our institution demonstrated the benefit of postoperative radiotherapy for minor salivary gland carcinomas when the surgical margins are close.[22] Postoperative radiotherapy may eliminate residual microscopic disease at the primary site or in regional lymphatics. The fact that 70% of patients in this study received postoperative radiotherapy may account for the higher survival rate found in this study when compared to other studies. Furthermore, combination therapy with surgery and radiotherapy proved to be superior to surgical excision alone in terms of 5-year survival, although this difference was not statistically significant because of the small series size.

CONCLUSION

In conclusion, laryngeal cancer of the minor salivary glands is rare when compared to epidermoid carcinoma. The diagnosis should be considered when evaluating a patient with a submucosal mass of the larynx. Due to submucosal tumor spread, most patients present with T3 or T4 primary tumors, regardless of the site of laryngeal involvement. Surgical resection of the tumor is advisable for advanced-stage disease. We have no experience treating early-stage disease for cure with primary radiotherapy. At any rate, this is an unusual situation, as demonstrated by the fact that only 1 of 12 patients (8%) in the current series presented with a stage T1 primary tumor. From this patient series, it appears that partial laryngectomy may be inadequate compared to total laryngectomy in the treatment of glandular carcinomas of the larynx, when the overall disease-free survival and surgical margins are considered. Neck dissection should be reserved for patients with clinical adenopathy, adenocarcinoma, and high-grade mucoepidermoid carcinoma. Most patients appear to benefit from a course of postoperative radiotherapy.

REFERENCES

1. Bak-Pedersen K, Nielsen KO. Subepithelial mucous glands in the adult human larynx. Studies on number, distribution and density. Acta Otolaryngol (Stockh) 1986;102:341-52.

2. Batsakis JG, Rice DH, Solomon AR. The pathology of head and neck tumors: squamous and mucous-gland carcinomas of the nasal cavity, paranasal sinuses, and larynx, part 6. Head Neck Surg 1980;2:497-508.

3. Heffner DK. Sinonasal and laryngeal salivary gland lesions. In: Ellis GL, Auclair PL, Gnepp DR, eds. Surgical pathology of the salivary glands. Philadelphia, Pa: Saunders, 1991: 544-59.

4. American Joint Committee for Cancer Staging and End Results Reporting. Clinical staging system for carcinoma of the larynx, revision. Chicago, Ill: 1972:1-16.

5. Ahued SV. Cylindroma of the epiglottis. Arch Otolaryngol 1956;63:366-71.

6. Donald PJ, Krause CJ. Papillary cystadenoma of the larynx. Laryngoscope 1973;83:2024-8.

7. Jokinen K, Seppala A, Palva A. Laryngeal pleomorphic adenoma. J Laryngol Otol 1974;88:1131-4.

8. New GB, Erich JB. Adenocarcinoma of the larynx. Ann Otol Rhinol Laryngol 1941;50:706-14.

9. Spiro RH, Lewis JS, Hajdu SI, Strong EW. Mucus gland tumors of the larynx and laryngopharynx. Ann Otol Rhinol Laryngol 1976;85:498-503.

10. Chaudhry AP, Vickers A, Gorlin RJ. Intraoral minor salivary gland tumors: an analysis of 1414 cases. Oral Surg Oral Med Oral Pathol 1962;14:1194-223.

11. Batsakis JG, Luna MA, El-Naggar AK. Nonsquamous carcinomas of the larynx. Ann Otol Rhinol Laryngol 1992;101: 1024-6.

12. Sessions DG, Murray JP, Bauer WC, Ogura JA. Adenocarcinoma of the larynx. Can J Otolaryngol 1975;4:290-2.

13. Toomey JM. Adenocarcinoma of the larynx. Laryngoscope 1967;77:931-61.

14. Seifert G. Histological typing of salivary gland tumours. World Health Organization. International histological classification of tumours. 2nd ed. Berlin, Germany: Springer-Verlag, 1991.

15. Blackwell KE, Calcaterra TC, Fu Y-S. Laryngeal dysplasia: epidemiology and treatment outcome. Ann Otol Rhinol Laryngol 1995;104:596-602.

16. Cohen J, Guillamondegui OM, Batsakis JG, Medina JE. Cancer of minor salivary glands of the larynx. Am J Surg 1985; 150:513-8.

17. Levine HL, Tubbs R. Nonsquamous neoplasms of the larynx. Otolaryngol Clin North Am 1986;19:475-88.

18. Olofsson J, Van Nostrand AWP. Adenoid cystic carcinoma of the larynx: a report of four cases and a review of the literature. Cancer 1977;40:1307-13.

19. Batsakis JG. Tumors of the head and neck: clinical and pathological considerations. 2nd ed. Baltimore, Md: Williams & Wilkins, 1979:86-90.

20. Whicker JH, Neel HB III, Weiland LH, Devine KD. Adenocarcinoma of the larynx. Ann Otol Rhinol Laryngol 1974;83: 487-90.

21. Horiuchi J, Shibuya H, Suzuki S, Takeda M, Takagi M. The role of radiotherapy in the management of adenoid cystic carcinoma of the head and neck. Int J Radiat Oncol Biol Phys 1987;13:1135-41.

22. Tran L, Sidrys J, Sadeghi A, Ellerbroek N, Hanson D, Parker RG. Salivary gland tumors of the oral cavity. Int J Radiat Oncol Biol Phys 1990;18:413-7.

≈

FIFTH INTERNATIONAL CONFERENCE ON HEAD AND NECK CANCER

The Fifth International Conference on Head and Neck Cancer will be held July 29–August 2, 2000, in San Francisco, California. For information, contact Concepts in Meetings & Events, Robin L. Wagner, President, 7819 Lloyd Ave, Pittsburgh, PA 15218-1941; telephone (412) 243-5156; fax (412) 243-5160; e-mail rlwa@med.pitt.edu.

CARBON DIOXIDE LASER DEBULKING FOR OBSTRUCTING ENDOLARYNGEAL CARCINOMA: A 10-YEAR EXPERIENCE

OLLIVIER LACCOURREYE, MD
PARIS, FRANCE
BERNARD BIACABE, MD
PARIS, FRANCE
GEORGES LAWSON, MD
YVOIR, BELGIUM
LAURENT LACCOURREYE, MD
ANGERS, FRANCE
LUCA MUSCATELLO, MD
PARIS, FRANCE
DANIEL BRASNU, MD
PARIS, FRANCE

The results of the carbon dioxide (CO_2) laser debulking procedure for obstructing endolaryngeal carcinoma were analyzed in terms of efficiency, complications, secondary tracheotomy rate, and peristomal recurrence rate in a series of 50 patients consecutively managed at our department. The CO_2 laser was used to reestablish a safe airway without resorting to tracheotomy and without performing a transoral resection. Our series included 42 patients in a pre–definitive treatment group (group 1) and 8 patients in a palliation group (group 2). Complications included death, pneumonia from inhalation, and cutaneous burns in 2 patients, 1 patient, and 1 patient, respectively. Thirty-two percent of patients required a repeat laser treatment to maintain the airway. Overall success rates of 92.8% and 87.5% were achieved in group 1 and group 2 patients, respectively. None of the variables under analysis could predict the success of the CO_2 laser debulking procedure. The overall incidences for secondary tracheotomy were 4.7% and 0% in group 1 and group 2 patients, respectively. Peristomal recurrence was not encountered in patients managed with definitive therapy with curative intent.

KEY WORDS — carbon dioxide laser debulking, endolaryngeal carcinoma.

INTRODUCTION

Until the advent of the carbon dioxide (CO_2) laser, emergency tracheotomy and emergency laryngectomy were the treatment policies used in patients with an obstructing endolaryngeal carcinoma. Emergency tracheotomy yielded various complications and was suspected to be one of the factors that might increase the incidence of stomal recurrence by encouraging tumor cell implantation at the tracheotomy site.[1-6] With the recent advent of cisplatin-based neoadjuvant chemotherapy laryngeal organ preservation strategies,[7] emergency laryngectomy in patients with an obstructing endolaryngeal carcinoma is no longer, in our opinion, a valid option.

The concept of laser debulking of obstructing laryngeal tumor to secure the airway and avoid tracheotomy was pioneered by Vaughan et al[8,9] and the Boston University group in the late 1970s. In the current textbooks on management of obstructing endolaryngeal tumors, the use of laser debulking is now discussed as an alternative option along with tracheotomy. Various authors[10-13] have reported the successful use of the CO_2 laser debulking procedure for obstructing laryngeal tumor.

To secure the airway and avoid emergency tracheotomy in patients with an obstructing endolaryngeal carcinoma, the CO_2 laser debulking procedure was introduced at our department in the 1980s.[14] The present retrospective study was designed to review our experience in a series of 50 patients with obstructing endolaryngeal squamous cell carcinomas consecutively managed with a CO_2 laser debulking procedure either as a bridge before definitive therapy for cure or as a strictly palliative treatment. Our series included 42 patients in the pre–definitive treatment group and 8 patients in the palliation group. The present study documents and analyzes the complications, efficiency, secondary tracheotomy rate, and peristomal recurrence rate. A univariate analysis for potential correlation between various variables and the efficiency of the CO_2 laser debulking procedure was performed.

PATIENTS AND METHODS

The medical files and operative charts of all patients with an obstructive endolaryngeal carcinoma consecutively managed with a CO_2 laser debulking procedure to secure the airway and avoid emergency tracheotomy at Laënnec Hospital between 1983 and 1994 were retrospectively reviewed. There were 49 men and 1 woman, with ages ranging from 38 to 96 years (mean age 59 years).

Thirteen patients had previously treated endolaryngeal squamous cell carcinomas. Staging of the remaining 37 untreated patients, according to the

From the Department of Otorhinolaryngology–Head and Neck Surgery, Laënnec Hospital, Assistance Publique des Hôpitaux de Paris, University Paris V, Paris, France (O. Laccourreye, Muscatello, Biacabe, L. Laccourreye, Brasnu), and the Department of Otorhinolaryngology–Head and Neck Surgery, University Hospital of Mont-Godinne, Louvain University, Yvoir, Belgium (Lawson).

CORRESPONDENCE — Ollivier Laccourreye, MD, Dept of Otorhinolaryngology–Head and Neck Surgery, Laënnec Hospital, 42 rue de Sèvres, 75007, Paris, France.

TABLE 1. STAGING OF 37 PREVIOUSLY UNTREATED PATIENTS

	T1	T2	T3	T4
N0			11	11
N1			5	5
N2			1	3
N3				1

All cases were initially classified as M0.

1988 American Joint Committee on Cancer Staging classification system,[15] is presented in Table 1. Past medical history revealed chronic obstructive pulmonary disease in 10 patients.

Our series included 42 patients for whom the CO_2 laser debulking procedure preceded definitive therapy with curative intent (group 1) and 8 patients for whom the CO_2 laser debulking procedure was considered part of palliative treatment (group 2) due to an unresectable tumor (3 patients), poor general condition (3 patients), or the patient's refusal to undergo any curative treatment (2 patients).

On admission, 3 patients had a tracheotomy and 1 was intubated. To establish a safe airway in the remaining patients, who were stridulous with dyspnea at rest, orotracheal intubation was performed. Awake intubation was successfully performed in 36 patients. In the other 10 patients, awake orotracheal intubation was not successful and a rigid tracheobronchoscopy allowing insertion of a guide into the trachea was performed to facilitate the endotracheal intubation. Fiberoptic-controlled intubation was not used in the present series. Intubation was performed with a protected endotracheal tube in the early years, and a laser-compatible endotracheal tube with an inflatable cuff since 1990. A laser laryngoscope with an operating microscope was positioned. The extent of the tumor and the laryngeal mobility were assessed (Table 2). A frozen section was carried out in patients with a previously untreated tumor. The debulking procedure was then performed with a Sharplan 1040 CO_2 laser (Laser Industries). The CO_2 laser was set at a 15-W continuous mode on average (range 7 to 30 W). The duration of the debulking procedure was 35 minutes on average (range 15 to 60 minutes). During surgery, the plume and the tumor debris were constantly evacuated. Transoral resection of the cancer was not attempted in the present series. Rigid tracheobronchoscopy was not performed after the debulking procedure. Forty patients were extubated in the operating room by the end of the debulking procedure. Due to poor general condition and/or intubation difficulties, the remaining 10 patients were kept intubated overnight. On recovery, the patients were routinely nursed with humidified oxygen, prophylactic broad-spectrum antibiotherapy, oral steroids, and chest therapy.

TABLE 2. TUMOR EXTENT AND LARYNGEAL MOBILITY

	Group 1 (n = 42)	Group 2 (n = 8)
Endolaryngeal tumor location		
True vocal cord	4	7
Arytenoid cartilage	41	5
Anterior commissure	37	5
Posterior commissure	5	0
Infraglottis	39	6
Supraglottis	4	7
Preepiglottic space	7	2
Extralaryngeal spread		
Oropharynx	3	1
Pyriform sinus	4	0
Retrocricoid	1	0
Trachea	5	2
True vocal cord fixation		
Unilateral	38	6
Bilateral	4	1
Arytenoid cartilage fixation		
Unilateral	31	3
Bilateral	0	0

No patients were lost to follow-up. The CO_2 laser debulking procedure was considered successful if it allowed for extubation, removal of a prior tracheotomy, and disappearance of dyspnea and/or stridor. The CO_2 laser debulking procedure was considered unsuccessful if the patient had to be reintubated or died of laser-related complications, if dyspnea and/or stridor recurred, or if a subsequent tracheotomy had to be performed. The independent factors of age, tumor location, laryngeal mobility, laser parameters, and surgeon's experience were also tested for potential correlation with the efficiency of the debulking procedure and the complications encountered (with $p \leq .05$ considered significant).

RESULTS

Group 1 Patients. The initial success rate was 64.2% (27/42). Fifteen patients in group 1 failed the debulking procedure. One patient, initially staged as T4N1, died 5 days after the debulking procedure. Review of the medical and operative files noted enlargement of the mediastinum immediately after the procedure without pneumothorax or subcutaneous emphysema. This patient was kept within our department and died suddenly on the fifth postoperative night without any symptoms of laryngotracheal obstruction. Autopsy was denied by the relatives. Among the 14 remaining patients, 12 were successfully managed with a second CO_2 laser debulking procedure and 2 required a tracheotomy prior to definitive treatment with curative intent. Therefore, an overall 92.8% (39/42) success

TABLE 3. DIAGNOSIS, MANAGEMENT, AND OUTCOME IN GROUP 2 PATIENTS

Age	*Sex*	*Past History*	*Management*	*Outcome (Time From Laser Procedure)*
64	M	Partial laryngectomy + radiotherapy failure	15-W laser + chemotherapy	Died (35 d)
67	M	Partial laryngectomy failure	10-W laser	Died (48 h)
65	M	Chemotherapy + radiotherapy failure	7-W laser	Died (2 y)
60	M	Unresectable T4	30-W laser + radiotherapy	Died (8 mo)
72	M	Chemotherapy + radiotherapy failure	10-W laser	Died (2 mo)
51	M	Unresectable T4	10-W laser + chemotherapy	Died (2 mo)
81	M	Radiotherapy failure	10-W laser	Died (8 mo)
90	F	Chemotherapy + radiotherapy failure	9-W laser	Died (5 mo)

rate was achieved. Bronchospasm as a perioperative complication was noted in 2 patients. The only postoperative complication was pneumonia from aspiration in 1 patient. Univariate analysis did not demonstrate any statistical relationship between the efficiency of the CO_2 laser debulking procedure, the complications encountered, and the variables under analysis. Peristomal recurrence was not encountered after definitive treatment with curative intent.

Group 2 Patients. The initial success rate was 37.5% (3/8). Five patients failed the debulking procedure. One patient died suddenly at night, 48 hours after the debulking procedure. Review of the medical and operative files noted that the debulking procedure and the postoperative course were uneventful in this 67-year-old man with an endolaryngeal recurrence after partial laryngectomy who refused any form of salvage treatment. The 4 remaining patients were successfully managed with a second CO_2 laser debulking procedure without the need for a tracheotomy. Therefore, an overall 87.5% (7/8) success rate was achieved. The only perioperative complication was a lip burn, noted in 1 patient. Postoperative complications were not encountered. Univariate analysis did not demonstrate any statistical relationship between the efficiency of the CO_2 laser debulking procedure, the complication encountered, and the variables under analysis. As noted in Table 3, all patients in group 2 ultimately died, but none died of tracheolaryngeal obstruction or required a tracheotomy.

DISCUSSION

Vaughan et al,[8,9] in the late 1970s, were the first authors to report, in 2 patients, the successful use of the CO_2 laser to debulk an obstructive endolaryngeal tumor prior to definitive therapy. Since then, other reports from the same Boston University group have documented the usefulness of the CO_2 laser in securing a safe airway without resorting to tracheotomy in cases of obstructing laryngeal lesions.[10,13] However, to our knowledge, only 2 reports from other departments, with limited series of 10 and 11 patients, have documented the results achieved with the CO_2 laser debulking procedure for obstructing endolaryngeal tumor.[11,12] The relative lack of data prompted us to review a large series of patients with an obstructing endolaryngeal carcinoma consecutively managed at our department with a CO_2 laser debulking procedure in an effort to assess the efficiency, complications, and long-term results.

Perioperative complications were infrequent in our series, as well as in the prior reports by Vaughan et al,[8,9] Davis et al,[10] Robson et al,[11] McGuirt and Koufman,[12] and Zeitels et al.[13] The only perioperative complications encountered in the series of Robson et al were hemorrhage and bronchospasm in 1 patient. In our series, bronchospasm and lip burn were noted in 2 patients and 1 patient, respectively. Such data are in agreement with the reports of Healy et al[16] and Ossoff et al,[17] who noted a low rate of perioperative complications in large series involving all types of CO_2 laser surgery when the appropriate precautions were taken. However, Fried,[18] in an analysis of 229 questionnaires with a 92% response rate, reported that increased experience with the laser did not necessarily guarantee fewer complications, and that only 49% of the physicians who responded had used the laser without complications.

One of the most critical management issues in patients with airway obstruction from laryngeal tumor is the achievement of a safe airway prior to the completion of the CO_2 laser debulking procedure. As demonstrated by Cozine et al[19] in a survey of 15,701 patients managed with a CO_2 laser laryngeal procedure, ventilation with the use of an endotracheal tube resulted in fewer complications when compared with Venturi jet ventilation. However, as noted by Griebie and Adams,[20] endotracheal intubation might be a risk for patients with large obstructing lesions. Therefore, at our department, in patients with an obstructive endolaryngeal carcinoma we advocate the completion of an awake orotracheal intubation without the use of Venturi jet ventilation. In our series, awake orotracheal intubation was unsuccessful in 10

patients. In such cases, a tracheobronchoscopy is performed to set a guide within the endolarynx and trachea. Such a guide always allowed for a safe and reliable endotracheal intubation without the need for an emergency tracheotomy. Ignition of the endotracheal tube directly related to impact from the laser is recognized as the most serious of all complications.[18] Such a complication was not encountered in our series. This, in our opinion, is related to the systematic use of the protected endotracheal tube in the early years and the use of a specially designed endotracheal tube and laryngoscope since 1990. The continuous removal of all lasered tissue, the use of a low power setting (15 W on average), and the protection of the inflated cuffs with moist cottonoids are the other maneuvers that explain the low rate of perioperative complications noted in our series.

Postoperatively, 2 fatalities were noted in our series. The cause of death remains unknown in both patients, who died suddenly 2 and 5 days, respectively, after the CO2 laser debulking procedure. Even though the fatalities did not appear to be directly related to endolaryngeal obstruction, these fatalities demonstrate that the CO2 laser debulking procedure should be considered a major surgical procedure with a non-negligible mortality. This is further documented by the fact that 1 patient in our series, as well as 1 in the series by Robson et al,[11] experienced aspiration pneumonia after the CO2 laser debulking procedure.

In our experience a 92.8% overall success rate was achieved in patients in whom the CO2 laser debulking procedure preceded definitive therapy with curative intent, and an 87.5% rate in patients in whom the CO2 laser debulking procedure was part of palliative treatment. Achievement of such rates required the completion of a second CO2 laser debulking procedure in 32% (16/50) of patients. Such a figure is significantly higher than that described in prior reports from other groups.[8-13] An explanation for this is the fact that in our series all patients in group 1 had a cisplatin-based neoadjuvant chemotherapy laryngeal organ preservation strategy after the CO2 laser debulking procedure. Regrowth of the tumor in patients who did not respond to neoadjuvant chemotherapy led to a secondary debulking procedure prior to total laryngectomy. In our series, none of the variables under analysis could predict the success of the CO2 laser debulking procedure. Further, the experience gained with the laser did not appear to improve our results, perhaps because in the present series transoral resection of the cancer was not attempted, as our goal was only to reestablish a safe airway without resorting to tracheotomy, and not to perform a transoral resection of larynx cancer. The overall incidence of secondary tracheotomy was 4% (2/50). Our intraoperative experience, as well as the analysis of the tumor extent and laryngeal mobility (Table 3), did not suggest limitations to the use of the CO2 laser debulking procedure in patients with an obstructing endolaryngeal carcinoma. In our series, peristomal recurrence was not encountered in patients managed with definitive therapy with curative intent (group 1). However, no strict oncological conclusions can be drawn, as the other factors in peristomal recurrence — infraglottic extent of tumor, preventive paratracheal lymph node dissection, margins of resection, and postoperative radiotherapy — were not assessed in the present retrospective study.

As noted in Table 3, all patients in group 2 ultimately died, but none died of tracheolaryngeal obstruction or required a tracheotomy. Therefore, the use of the CO2 laser debulking procedure in patients managed with palliative treatment (group 2) appeared to be highly successful, as it always avoided the need for a tracheotomy, resulting, therefore, in a better quality of life for this group of patients.

CONCLUSION

Our study confirms that the CO2 laser debulking procedure is a valuable treatment modality in patients with obstructing endolaryngeal squamous cell carcinoma, and a viable alternative to tracheotomy prior to definite treatment. It confirms that this approach to the management of cancer that obstructs the larynx should become more mainstream. Further, the use of the CO2 laser in patients undergoing palliative treatment allows for a better quality of life.

However, the otolaryngologist–head and neck surgeon should be aware 1) that such a procedure yields a non-negligible risk during the first postoperative week, making, in our opinion, a close follow-up during this period mandatory, and 2) that if a neoadjuvant chemotherapy organ preservation strategy is initiated after the initial debulking procedure, a second CO2 laser debulking procedure will be required in approximately one third of patients to avoid tracheotomy.

REFERENCES

1. Stell PM, Van den Broek P. Stomal recurrence after laryngectomy: aetiology and management. J Laryngol Otol 1970; 85:131-40.

2. Weisman RA, Colman M, Ward PH. Stomal recurrence following laryngectomy. A critical evaluation. Ann Otol Rhinol Laryngol 1979;88:855-60.

3. Keim WF, Shapiro MJ, Rosen HO. Study of postlaryngectomy stomal recurrences. Arch Otolaryngol 1965;81:183-

6.

4. Baluyot ST Jr, Shumrick DA, Everts EC. "Emergency" laryngectomy. Arch Otolaryngol 1971;94:414-7.

5. Bonneau RA, Lehman RH. Stomal recurrence following laryngectomy. Arch Otolaryngol 1975;101:408-12.

6. Wickham MH, Narula AA, Barton RP, Bradley PJ. Emergency laryngectomy. Clin Otolaryngol 1990;15:35-8.

7. The Department of Veterans Affairs Laryngeal Study Group. Induction chemotherapy plus radiation compared with surgery plus radiation in patients with advanced laryngeal cancer. N Engl J Med 1991;324:1685-90.

8. Vaughan CW. Transoral laryngeal surgery using the CO_2 laser: laboratory experiments and clinical experience. Laryngoscope 1978;88:1399-420.

9. Vaughan CW, Strong MS, Jako GJ. Laryngeal carcinoma: transoral resection utilizing the CO_2 laser. Am J Surg 1978;136: 490-3.

10. Davis RK, Shapshay SM, Vaughan CW, Strong MS. Pretreatment airway management in obstructing carcinoma of the larynx. Otolaryngol Head Neck Surg 1981;89:209-14.

11. Robson AK, Herrema I, Stafford FW. Laser debulking for obstructing laryngeal tumours. Clin Otolaryngol 1994;19: 430-2.

12. McGuirt WF, Koufman JA. Endoscopic laser surgery. An alternative in laryngeal cancer treatment. Arch Otolaryngol Head Neck Surg 1987;113:501-5.

13. Zeitels SM, Vaughan CW, Domanowski GF, Fuleihan NS, Simpson GT 2d. Laser epiglottectomy: endoscopic technique and indications. Otolaryngol Head Neck Surg 1990;103: 337-43.

14. Laccourreye H, Lacau Saint-Guily J, Brasnu D, et al. Utilisation du laser CO_2 dans le traitement d'urgence des dyspnées du cancer du larynx. Ann Otolaryngol Chir Cervicofac 1984;101:39-42.

15. Beahrs OH, Henson DE, Hutter RVP, Myers M, eds. American Joint Committee on Cancer. AJCC cancer staging manual, 3rd ed. Philadelphia, Pa: JB Lippincott, 1988:39-44.

16. Healy GB, Strong MS, Shapshay S, Vaughan C, Jako G. Complication of the CO_2 laser surgery of the aerodigestive tract: experience of 4416 cases. Otolaryngol Head Neck Surg 1984;92: 13-8.

17. Ossoff RH, Werkhaven JA, Dere H. Soft tissue complications of laser surgery for recurrent respiratory papillomatosis. Laryngoscope 1991;101:1162-6.

18. Fried MP. A survey of complications of laser laryngoscopy. Arch Otolaryngol 1984;110:31-4.

19. Cozine K, Stone JG, Shulman S, Flaster ER. Ventilatory complications of carbon dioxide laryngeal surgery. J Clin Anesth 1991;3:20-5.

20. Griebie MS, Adams GL. "Emergency" laryngectomy and stomal recurrence. Laryngoscope 1987;97:1020-4.

EXTRAMEDULLARY SOLITARY PLASMACYTOMA OF THE HEAD AND NECK

A CLINICOPATHOLOGICAL STUDY

MICHEL-ANDRE HOTZ, MD
BERNE, SWITZERLAND
JACQUES BOSQ, MD
VILLEJUIF, FRANCE
GUY SCHWAAB, MD
VILLEJUIF, FRANCE
JEAN-NICOLAS MUNCK, MD
VILLEJUIF, FRANCE

Monoclonal extramedullary plasmacytoma (EMP) is a rare, low-grade lymphoma found predominantly in the head and neck region. Only since the introduction of immunophenotyping techniques 2 decades ago has it been possible to differentiate EMP from benign polyclonal plasma cell proliferation. The purpose of this study was to trace the evolutionary profile of the disease under consideration of monoclonality assessment. The records of 24 patients with morphologically diagnosed EMP treated in a single institution underwent clinical and pathological review. Only 14 patients had true monoclonal plasmacytoma. No EMP-related deaths occurred. Two patients had local recurrence, and 2 patients developed multiple myeloma. Review of the literature confirms the low-grade malignancy of EMP. Diagnostic procedures must exclude benign polyclonal plasmacytoma, multiple myeloma, and solitary bone plasmacytoma. The slow natural progression of the disease and the rarity of secondary multiple myeloma favor nonmutilating local surgery whenever possible to avoid the long-term sequelae of radiotherapy.

KEY WORDS — extramedullary plasmacytoma, head and neck, immunophenotyping, myeloma, soft tissue tumor.

INTRODUCTION

Extramedullary plasmacytomas (EMPs) are rare tumors initially described by Schridde[1] in 1905. A review of the literature shows that some salient features seem to typify an autonomous lymphoid disease whose natural history is distinct from that of solitary plasmacytoma of the bone marrow. However, the EMP tumor cells resemble mature or immature plasma cells in the absence of other lymphoid cells, and therefore cannot be differentiated from cells of solitary plasmacytoma of the bone marrow or of multiple myeloma. According to the literature, most EMPs are solitary and have a quasi-exclusive distribution in the head and neck area.[2-4] This may be partially due to the abundant lymphoid tissue in this part of the body, and for this reason, patients are usually referred to otolaryngologists. The tumors arise predominantly in submucosal tissues of the nasopharynx, paranasal sinuses, nasal fossa, tonsils, oral cavity, or larynx, and masses extending from bone cannot be considered as EMPs. Their incidence in males is nearly threefold higher than that in females, with the 50- to 70-year age group being the most affected.[5] The frequency of abnormal globulin in the serum is evaluated diversely, but most of the series were published before reliable methods of detection were available. While progression toward multiple myeloma is inexorable for solitary plasmacytomas of the bone marrow, this event seems to be much less frequent for EMPs, whose destructive growth is essentially local. The rarity of the disease also accounts for the lack of codified therapy, which should be based on a more precise evaluation of the risk of distant dissemination. For this reason, we have reviewed all the cases of EMP seen at the Institut Gustave-Roussy from 1980 to 1994, a period during which new and reliable immunophenotyping methods were introduced that have led to accurate case selection.

PATIENTS AND METHODS

The records of all patients with diagnoses of EMP of the head and neck seen at the Institut Gustave-Roussy between 1980 and 1994 were reviewed. Surgical specimens fixed in 10% buffered formalin or AFA (acetic acid, formalin, alcohol), embedded in paraffin, and stained with hematoxylin and eosin, Giemsa, and periodic acid–Schiff were available for all patients. The slides of all patients were reviewed, and immunophenotyping was redone with the panel of antibodies listed in Table 1.[6,7] The pathological requirement necessary to qualify for EMP diagnosis was a morphologically typical plasma cell lesion, restricted to soft tissue, with demonstration of monoclonality.

Clinical staging included a bone marrow aspirate,

From the Departments of Head and Neck Surgery (Hotz, Schwaab), Pathology (Bosq), and Medicine (Munck), Institut Gustave-Roussy, Villejuif, France.

CORRESPONDENCE — Michel-André Hotz, MD, Clinique ORL, Hopital de l'Ile, 3010 Berne, Switzerland.

TABLE 1. COMPLETE IMMUNOPHENOTYPING OF MONOCLONAL EXTRAMEDULLARY PLASMACYTOMA

Patient	*CD15*	*CD20*	*CD45RA*	*CD45RB*	*EMA*	*IgD*	*IgA*	*IgG*	*κ*	*λ*
1	–	–	–	+	±	–	+	–	–	+
2	–	–	±	±	+	–	+	–	–	+
3	–	–	±	±	+	–	+	–	+	–
4	–	–	±	±	+	–	–	+	+	–
5	ND	ND	ND	±	ND	ND	ND	ND	–	+
6	–	–	–	±	+	–	–	+	–	+
7	ND	ND	ND	±	ND	ND	ND	ND	+	–
8	–	–	+	+	±	–	+	–	–	+
9	–	–	–	±	–	–	–	+	–	+
10	–	–	+	+	±	–	–	+	+	–
11	–	±	+	+	±	–	+	–	+	–
12	–	–	–	±	±	+	–	–	–	+
13	–	–	±	+	+	–	–	+	+	–
14	–	–	+	+	+	–	–	+	+	–

CD refers to nomenclature for human leukocyte differentiation antigens following Boston Workshop 1993.[6]
+ — Majority of tumor cells were positive; ± — some tumor cells were positive; – — all tumor cells were negative; ND — not done.
Antibodies used for phenotyping were as follows: for CD15, Becton-Dickinson, Pont de Claix, France; for CD20, CD45RB, EMA [epithelial membrane antigen[7]], IgD, IgA, IgG, Dako SA, Trappes, France; for CD45RA, AMD, Euroblo, Les Ulis, France; for κ, Biogenex, Menarini Diagnostics, Chevilly la Rue, France; for λ, Immunotech SA, Marseille, France.

a blind bone marrow biopsy from the posterior iliac crest, radiographs of the whole skeleton, serum electrophoresis, and serum and urine immunoelectrophoresis. Patients qualified for the study if the histologic diagnosis of EMP was associated with a normal bone marrow with less than 5% of plasma cells and absence of lytic bone lesions. Patients not meeting these 3 criteria could not be considered as having EMP and were excluded from the study. The presence of multiple soft tissue lesions or of a monoclonal peak on serum and/or urine electrophoresis was not a reason for exclusion.

Treatment options for monoclonal EMP included surgery, radiotherapy, laser therapy, and chemotherapy. After therapy, the patients with monoclonal EMP were followed up every 3 months during the first year and every year thereafter. In case of relapse, the above-mentioned criteria were reevaluated with a new staging procedure.

RESULTS

Between 1980 and 1994, EMP was diagnosed in 24 patients exclusively on the basis of morphological criteria. The biopsies were characterized by a diffuse infiltration of well-differentiated plasma cells not associated with immunoblasts, plasmablasts, or lymphocytes. The mitotic rate was always low. Periodic acid–Schiff–positive inclusions were observed in 5 cases. Immune peroxidase light chain reaction showed polyclonality in 10 patients and monoclonality in 14 patients.

The polyclonal group included 7 men and 3 women, whose average age was 63 (range 30 to 88). Nine patients had single lesions, and 1 patient had multifocal masses. Sites of polyclonal EMP were the gingivae (n = 3), velum (n = 2), lip (n = 2), tonsils (n = 1), nasal fossa (n = 1), floor of the mouth (n = 1), larynx (n = 1), and base of the tongue (n = 1). None of these patients had a monoclonal peak in serum or urine. Only 4 of the 10 patients had symptoms due to the tumor. All these patients were considered free of malignant disease, and no specific treatment was undertaken after biopsy. The patient with multifocal masses in the epipharynx, the nasal fossa, and the larynx had a follow-up for 5 years with no sign of disease progression.

The group with monoclonal plasmacytomas is described in Table 2 and included 12 men and 2 women, with a median age of 55 years (range 23 to 77). The 2 women were younger than the 12 male patients. Three patients had multifocal expression of their EMP, and 11 patients had a single lesion. The sites of EMP were the nasal fossa (n = 3), tonsils (n = 3), nasopharynx (n = 6), soft palate (n = 1), larynx (n = 2), posterior wall of the oropharynx (n = 1), maxillary sinus (n = 1), and base of the tongue (n = 1). Thirteen of the 14 patients had symptoms due to mechanical obstruction by the tumor. The mean interval between the onset of symptoms and the first medical consultation was 8 weeks. Only patient 12 had a serum and urine monoclonal globulin peak, which disappeared postoperatively after removal of the tumor.

Complete immunophenotyping is described in Table 1. In all cases, tumor cells expressed CD45RB. Epithelial membrane antigen (EMA) was positive in 11 cases and not determined in 2; CD45RA was positive in 8 cases, negative in 4, and not determined in 2; CD15 was negative in 12 cases and not determined in 2; and CD20 was positive in a few tumor

TABLE 2. DESCRIPTION AND TREATMENT REGIMEN OF PATIENTS WITH MONOCLONAL EXTRAMEDULLARY PLASMACYTOMA

Patient	*Age*	*Initial Symptom*	*Site*	*Therapy*	*Follow-up (mo)*	*Status at Follow-up*
1	45	Epistaxis	Nasal fossa	S/45 Gy	36	MM
2	67	Dysphagia	Tonsil	S/55 Gy	60	NED
3	60	Otalgia	Velum	S/45 Gy	105	NED
4	63	Dyspnea	Larynx, nasal fossa, nasopharynx	S/40 Gy	108	NED
5	77	Conductive hearing loss	Nasopharynx, tongue	S/45 Gy	19†	AWD
6	59	Nasal obstruction	Nasopharynx	S/40 Gy	157	NED
7	44	No symptom	Nasopharynx	S	0*	
8	23	Epistaxis	Nasal fossa	S/50 Gy	18*	NED
9	56	Dental abscess	Maxillary sinus	S/40 Gy	88	NED
10	67	Dysphagia	Tonsil	S/40 Gy	51†	NED
11	57	Dysphagia	Tonsil	S/40 Gy	132	NED
12	42	Dysphagia	Posterior pharyngeal wall	S	150	NED
13	45	Dysphagia	Nasopharynx, larynx	S/55 Gy	108	AWD
14	63	Nasal obstruction	Nasopharynx	S/45 Gy	116	MM

S — surgery, Gy — grays of radiotherapy, MM — multiple myeloma, NED — no evidence of disease, AWD — alive with residual or relapsing disease.
*Definitively lost to follow-up.
†Death.

cells in only 1 case. Light chain staining of the cytoplasm was found in all 14 patients: 7 patients were κ-positive, and 7 had λ light chain positivity. Six cases stained for IgG, 5 for IgA, and 1 for IgD. No case stained for IgM or IgE.

First-line therapy options for monoclonal EMP were surgery and/or radiotherapy. Diagnostic procedures allowed complete macroscopic removal of the plasmacytoma by surgery in 8 cases. Six patients had bioptic, incomplete surgery in nonamenable anatomic sites such as the nasopharynx. Afterward, all patients except 2 received radiotherapy, with doses ranging from 40 to 55 Gy. One of the 2 patients (patient 12) who refused radiotherapy has been free of disease for more than 10 years, while the second was lost to follow-up after initial therapy.

Twelve of the 14 patients were followed up over a long period of time (mean follow-up of 8.5 years), but 2 patients were lost to follow-up after 1 and 18 months. Two patients died of causes unrelated to their disease, 19 and 51 months after diagnosis, but no EMP-specific death was recorded. Two patients with multifocal lesions (patients 5 and 13), initially treated by surgery and radiotherapy, developed a recurrence in the irradiated primary sites, 19 and 47 months after initial treatment. Local control was again complete after surgery for the first patient, who died within the same month due to a heart attack; the second received laser therapy followed by chemotherapy, but an unresectable, histologically proven, positive residual mass is still present 8 years after relapse, with no increase in tumor volume or any critical organ compression. Two patients developed multiple myeloma, 24 and 93 months after diagnosis of EMP. Twelve and 15 months after diagnosis of multiple myeloma, these 2 patients are still alive.

DISCUSSION

Extramedullary monoclonal plasmacytoma is an extremely rare disease whose natural history and treatment are not clearly established. Since its initial description, about a dozen publications have described characteristics that typify a lymphoid neoplasm that is distinct from both myeloma and solitary plasmacytoma of the bone marrow.[2-5,8-18] In the Kiel classification, EMP is considered as non-Hodgkin's lymphoma, while in the REAL (Revised European-American Lymphoma) classification, EMP and multiple myeloma are summarized in the group plasmacytoma/plasma cell myeloma.[19] Clinically, most of the authors exclude tumors that arise from bone to avoid confusion with solitary bone plasmacytomas and insist on having a normal bone marrow biopsy result and an absence of lytic bone lesions to eliminate multiple myeloma. Today, magnetic resonance imaging (MRI) is considered the most sensitive method for assessment of lytic lesions.[20] Application of MRI as a staging procedure is still limited, because of the large amount of time involved. Bone scans are of no value, because the nuclear medicine isotopes are taken up only in areas of osteoblastic, but not osteolytic, activity. Pathologically, it is usually easy to diagnose EMP. When the monotone cell pattern makes it difficult to distinguish between plasmacytoma and undifferentiated epithelial tumors, immunophenotyping solves the problem. Immunostaining also proves the monoclonality of the tumor and characterizes the plasma cells. In our study, in which immunophenotyping was applied to all cases, we ex-

TABLE 3. REVIEW OF PUBLISHED SERIES OF EXTRAMEDULLARY PLASMACYTOMA OF HEAD AND NECK

Authors	Year	No. of Patients	Upper Respiratory or Digestive Tract	Assessment of Monoclonality	Monoclonal Protein*	Secondary Multiple Myeloma	Specific† Deaths	Status at Last Follow-up	Therapy	Remarks
Ewing and Foote[2]	1952	7	7	ND	ND	1	1 MM	3 NED, 1 AWD, 1 NSD	RT alone 3	
Kotner and Wang[3]	1972	20	20	ND	0/4	3	1 LD, 2 MM	11 NED, 3 AWD, 2 NSD	RT alone 17, Surg alone 2	3 Local recurrences after RT
Gromer and Duvall[4]	1973	7	6	ND	0/2	1	1 LD, 1 DM	3 NED, 2 NSD	RT 5, Surg alone 2	No recurrence after Surg
Petrovich et al[8]	1977	7	7	ND	ND	0	1 DM	6 NED	RT 7	
Yao and Perzin[9]	1978	10	10	ND	3/10	2	1 DM, 2 MM	4 NED, 1 AWD	RT 9, Surg alone 1	4 Local recurrences
Corwin and Lindberg[10]	1979	12	10	ND	4/12	2	2 MM	8 NED, 2 AWD	RT 12	2 Local recurrences after RT
Woodruff et al[11]	1979	16	14	ND	ND	0	1 DM	12 NED, 3 NSD	RT 16	1 Local recurrence after RT
Mendenhall et al[12]	1980	6	5	ND	2/6 (1 with subsequent MM)	2	1 MM	4 NED, 1 AWD	RT 6	No local recurrence
Medini et al[13]	1980	7	7	ND	ND	0	0	7 NED	RT 7	No local recurrence
Harwood et al[14]	1981	23	18	ND	8/23 (1 with subsequent MM)	4	4 MM	12 NED, 4 AWD, 3 NSD	RT 22	1 Local recurrence; MM in patients with initial bone destruction
Kapadia et al[15]	1982	20	14	9/16	4/10	4	4 MM	6 NED, 2 AWD	RT 14	2 Local recurrences
Knowling et al[16]	1983	25	16	ND	8/25	3	2 LD, 1 DM, 2 MM	15 NED, 3 AWD 2 NSD	RT 24	3 Active residual masses
Meis et al[17]	1987	13	13	11/13	2/13	3	2 MM	9 NED, 1 AWD	RT 11, Surg alone 2	No local recurrences
Wax et al[18]	1993	4	2	4/4	0/4	0	0	4 NED	Surg + RT 3, Surg alone 1	1 Local recurrence
Susnerwala et al[21]	1997	22	20	22/22	1/22	2	1 MM, 4 LD	1 AWD, 9 NSD, 8 NED	RT alone 17, RT + CH 4, Surg + RT 1	5 Local recurrences after RT
This series		14	10	14/14	1/14	2	0	9 NED, 2 AWD	Surg + RT 12, Surg alone 2	2 Local recurrences after RT

ND — not determined, MM — multiple myeloma, NED — no evidence of disease, AWD — alive with disease, NSD — nonspecific (to extramedullary plasmacytoma) death, RT — radiotherapy, LD — local disease, Surg — surgery with complete excision, DM — distant metastases, CH — chemotherapy.

*Ratio between positive cases and cases in which investigation was done.

†Specified if related to LD, MM, or DM.

cluded 10 of 24 patients (42%) with a polyclonal tumor that otherwise might have been included. Polyclonal and monoclonal lesions were found, predominantly in the upper respiratory and digestive tracts.

In contrast to the patients with monoclonal lesions, most patients with polyclonal lesions showed no symptoms. No conclusive reports about an etiologic or evolutionary relationship between reactive disease and neoplastic disease are available.

In the literature review (Table 3[2-4,8-18,21]) we considered clinicopathological multicase publications from 8 radiotherapeutic and 7 pathology-otolaryngology institutions on EMP arising in the head and neck, excluding cases of extramedullary tumors occurring during the evolution of multiple myelomas. The studies cover an observation interval between 14 and 30 years. The assessment of monoclonality was partially achieved in only 4 of the reports we analyzed,[15,17,18,21] probably because most of the other cases were diagnosed before the era of routine immunophenotyping in the early 1980s.

There is no evidence that treatment improves the outcome of EMP.[20] Diagnostic surgery may also be therapeutic, especially in surgically easily accessible areas. Two of our patients were treated by surgery alone, and at least 1 of them is free of recurrence. Several studies have also shown a disease-free survival after surgery alone.[3,5,17] Nonmutilating surgery alone is an alternative as first-line therapy to avoid the long-term sequelae of radiotherapy. Radiotherapy is accepted as standard treatment even though no studies showing a survival advantage have been published. Also, a definite relationship between the radiation dose and local control of EMP has not been demonstrated.[16] Doses of 36 to 40 Gy, usually delivered to lymphomas, seem to be sufficient, but infield relapses are not exceptional. In our series, 2 local relapses occurred that were amenable to either secondary surgery or laser therapy and chemotherapy. Local persistence or recurrence did not contribute to death. For surgically inaccessible anatomic sites such as the nasopharynx, radiotherapy is the preferred therapeutic modality. Surgical debulking may increase the probability of local radiotherapeutic control. Fortunately, in our series, no postirradiation complications such as local cellulitis, granulation tissue, or blindness[15] occurred.

The prognosis of EMP is probably not so much influenced by local growth as by the possible evolution of the disease into multiple myeloma. Many authors confirmed local relapses as a major problem encountered in the follow-up of EMP, but deaths due to local progression were infrequent in most reports.[15,16] Although not observed in our series, disease-specific deaths after distant spread (without the features of multiple myeloma) confirm the neoplastic nature of the disease.[10,11,16] In 2 of our 14 patients, multiple myeloma was diagnosed 24 and 93 months after the onset of EMP. Such a dismal outcome was not found in reports of several authors.[8,10,11,13] The risk of developing multiple myeloma during the course of clear-cut EMP exists, but with a much lower frequency than in cases of solitary bone marrow plasmacytoma: in 3 studies in which patients were homogeneously staged and treated in the same institutions, the proportions of patients developing multiple myeloma after diagnosis of EMP or of solitary bone plasmacytomas were 2/12, 4/16, 3/13, and 6/12, 12/25, 8/22, respectively.[10,16,17] Such atypical sites of EMP manifestation as the orbit or sphenoid sinus must raise the questions of initially misdiagnosed solitary bone plasmacytoma and secondary locations of multiple myeloma with secondary extension to soft tissues. The prognosis of an evolutionary multiple myeloma after EMP seems to be better than that of classic multiple myeloma.[22,23] Despite improved laboratory, radiologic, and clinical examination, it is still not possible to identify which cases will progress into an overt multiple myeloma. There is no apparent link between the detection of monoclonal immunoglobulins or light chains in the serum and secondary development of multiple myeloma. The 2 patients in our study who developed multiple myeloma had no abnormal protein peak in serum or urine at the time of EMP diagnosis. On the other hand, the patient with the pathological serum protein peak, which disappeared after complete local control, has no evidence of disease more than 12 years after the diagnosis of EMP. Recently, Susnerwala et al[21] found a correlation between histologic grading (originally proposed by Bartl et al[24] in 1987 for multiple myeloma grading) and local aggressiveness, but not for overall survival of EMP disease. That article[21] also includes 3 cases of EMP of bone, which usually is considered a separate pathologic entity.[23]

In conclusion, EMPs are predominantly localized tumors, at least initially. Standard criteria for the initial diagnostic procedure, based on modern radiologic assessment of extension and complete immunohistologic analysis, may help to clarify the relationship between this disease, whose behavior is akin to that of low-grade lymphoma rather than solitary bone plasmacytoma, and multiple myeloma.

REFERENCES

1. Schridde H. Weitere Untersuchungen über die Koernelungen der Plasmazellen. Zentralbl Allg Pathol Anat 1905;6:433-5.

2. Ewing MR, Foote FW. Plasma-cell tumors of the mouth and upper air passages. Cancer 1952;5:499-513.

3. Kotner LM, Wang CC. Plasmacytoma of the upper air and food passages. Cancer 1972;30:414-8.

4. Gromer RC, Duvall AJ. Plasmacytoma of the head and

neck. J Laryngol Otol 1973;87:861-73.

5. Batsakis JG. Plasma cell tumors of the nead and neck. Ann Otol Rhinol Laryngol 1983;92:311-3.

6. Kipps TJ. The cluster of differentiation (CD) antigens. In: Beutler E, Lichtman MA, Coller BS, Kipps TJ, eds. Williams hematology. 5th ed. New York, NY: McGraw Hill, 1995:113-40.

7. Delsol G, Gatter KC, Stein H, et al. Human lymphoid cells express epithelial membrane antigen. Implications for the diagnosis of human neoplasms. Lancet 1984;2:1124-8.

8. Petrovich Z, Fishkin B, Hittle RE, Acquarelli M, Barton R. Extramedullary plasmacytoma of the upper respiratory passages. Int J Radiat Oncol Biol Phys 1977;2:723-30.

9. Yao FS, Perzin H. Nonepithelial tumors of the nasal cavity, paranasal sinuses and nasopharynx. A clinicopathological study. IX. Plasmacytomas. Cancer 1978;42:2399-406.

10. Corwin J, Lindberg RD. Solitary plasmacytoma of bone vs extramedullary plasmacytoma and their relationship to multiple myeloma. Cancer 1979;43:1007-13.

11. Woodruff RK, Whittle JM, Malpas JS. Solitary plasmacytoma. I: Extramedullary soft tissue plasmacytoma. Cancer 1979;43:2340-3.

12. Mendenhall CM, Thar TL, Million RR. Solitary plasmacytoma of bone and soft tissue. Int J Radiat Oncol Biol Phys 1980;6:1497-501.

13. Medini E, Rao Y, Levitt SH. Solitary extramedullary plasmacytoma of the upper respiratory and digestive tracts. Cancer 1980;45:2893-6.

14. Harwood AR, Knowling MA, Bergsagel DE. Radiotherapy of extramedullary plasmacytoma of the head and neck. Clin Radiol 1981;32:31-6.

15. Kapadia SB, Desai U, Cheng VS. Extramedullary plasmacytoma of the head and neck. A clinicopathologic study of 20 cases. Medicine (Baltimore) 1982;61:317-29.

16. Knowling MA, Harwood AR, Bersagel DE. Comparison of extramedullary plasmacytomas with solitary and multiple plasma cell tumors of bone. J Clin Oncol 1983;1:255-62.

17. Meis JM, Butler JJ, Osborne BM, Ordonez NG. Solitary plasmacytomas of bone and extramedullary plasmacytomas. Cancer 1987;59:1475-85.

18. Wax MK, Yun KJ, Rawhi AA. Extramedullary plasmacytomas of the head and neck. Otolaryngol Head Neck Surg 1993;5:877-85.

19. Harris NL, Jaffe ES, Stein H, et al. A revised European-American classification of lymphoid neoplasms: a proposal from the International Lymphoma Study Group. Blood 1994;84:1361-94.

20. Salmon SE, Cassady JR. Plasma cell neoplasms. In: DeVita VT, Hellman S, Rosenberg SA, eds. Cancer principles and practice of oncology. 5th ed. Philadelphia, Pa: Lippincott-Raven, 1997:1984-2025.

21. Susnerwala SS, Shanks JH, Banerjee SS, Scarffe JH, Farrington WT, Slevin NJ. Extramedullary plasmacytoma of the head and neck region: clinicopathological correlation in 25 cases. Br J Cancer 1997;75:921-7.

22. Wiltshaw E. The natural history of extramedullary plasmacytoma and its relation to solitary myeloma of bone and myelomatosis. Medicine (Baltimore) 1976;55:217-38.

23. Galien M, Russo D, Petrucci MT, Bucalossi A, Tura S. Solitary plasmacytoma of bone and extramedullary plasmacytoma: two different entities. Ann Oncol 1995;6:687-91.

24. Bartl R, Frisch B, Fatch-Moghadan A, Ketner G, Jaeger K, Sommerfield W. Histological classification and staging of multiple myeloma. A retrospective and prospective study of 674 cases. Am J Clin Pathol 1987;87:342-55.

SUBSTERNAL GOITER: CLINICAL EXPERIENCE OF 72 CASES

JOSÉ M. RODRIGUEZ, MD
QUITERIA HERNANDEZ, MD
ANTONIO PIÑERO, MD
SERGIO ORTIZ, MD
TERESA SORIA, MD
PABLO RAMIREZ, MD
PASCUAL PARRILLA, MD
MURCIA, SPAIN

The aim of this work was to study the clinical management and surgical approach of substernal goiters. We studied the clinical data, preoperative evaluation, surgical treatment, histopathologic data, complications, and follow-up of 72 patients found to have substernal goiter over a period of 15 years, from a total of 780 patients with goiter who underwent surgery. In this group, 83% were women, and the mean age was 61 years. The most common symptoms were the existence of a palpable cervical mass (93% of cases) and dyspnea (40%). The most successful study to diagnose substernal goiter was computed tomography (100%), followed by chest radiography (75%), gammagraphy (19%), and ultrasound (15%). All but 7 patients received a Kocher cervicotomy, and 49% of the cases underwent a total thyroidectomy. The histologic study revealed 3 carcinomas (4%). There was 1 permanent unilateral recurrent laryngeal nerve injury (1.4%) and 1 instance of permanent hypoparathyroidism (1.4%). We regard surgery as the most successful treatment for patients with substernal goiter, even in those without compressive symptoms. We base our choice on the low morbidity and zero mortality obtained.

KEY WORDS — substernal goiter, surgical approach.

INTRODUCTION

The number of patients with goiter has decreased considerably since the introduction of iodized salt as a prophylactic treatment.[1] However, there are still patients with long-term goiters, some of which have a substernal component. Even though it is usually benign, this intrathoracic growth conveys a potential morbidity.

Surgery is the most accepted form of treatment,[2,3] as it solves problems of compression and rules out the possibility of an occult cancer.[4-6] Nevertheless, in the treatment of substernal goiter (SSG) we must consider matters such as suitable timing for surgery, the effect on elderly patients, which studies to use preoperatively, and the most appropriate surgical approach. This study records our experience in 72 patients with SSGs.

PATIENTS AND METHOD

Between 1978 and 1993, 780 patients underwent surgery for goiter in the General Surgery Department of the Virgen de la Arrixaca University Hospital in Murcia. Seventy-two patients (9.2%) had an SSG. Regarded as such, as also defined by Sanders et al,[6] are those with a major intrathoracic component that requires exploration of the mediastinum for dissection and removal. The mean age was 61.3 years (range 19 to 90 years); 60 patients were women (83%) and 12 were men (17%). The following areas were assessed.

1. Clinical data. Family history of goiter, and prevalent symptoms (cervical mass, dyspnea, dysphagia, dysphonia, and symptoms of venous compression).

2. Preoperative studies. In all cases, triiodothyronine, tetraiodothyronine, and thyroid-stimulating hormone determinations were made. Simple chest radiology was performed in 72 patients, gammagraphy with iodine 131 or technetium 99 in 47, ultrasound in 40, and computed tomography (CT) in 18. Fine needle aspiration (FNA) was performed in 34 patients. Indirect laryngoscopy was carried out in 7 patients, barium esophagography in 6, and cavography in 1.

3. Surgical treatment, including the surgical approach (Kocher cervicotomy, thoracotomy, sternotomy), surgical technique (total thyroidectomy, bilateral subtotal thyroidectomy, and lobectomy), and need for fibroscope-assisted intubation. The surgical technique employed is the cervical incision of Kocher, separating or, if necessary, sectioning the prethyroid muscles. The thyroid dissection usually begins at the smallest and least intrathoracic hemithyroid, to simplify the removal of the goiter. The upper pole is always released first, to reduce the risk of injury to the recurrent laryngeal nerves and the parathyroid glands. Thyroid lobectomy was performed in cases with only 1 pathological side. If the goiter was bilateral, we performed subtotal thyroidectomy during the early years of this series of patients, but now perform total thyroidectomy.

From the Department of General Surgery, "Virgen de la Arrixaca" University Hospital, Murcia, Spain.
CORRESPONDENCE — José M. Rodriguez, MD, Dept of General Surgery, "Virgen de la Arrixaca" University Hospital, 30120 Murcia, Spain.

TABLE 1. CLINICAL DATA ON SUBSTERNAL GOITERS

Symptoms	*No. of Cases*	*%*
Cervical mass	67	93
Dyspnea	29	40
Dysphagia	12	17
Dysphonia	12	17
Stridor	8	11
Thyroid hyperfunction	5	7
Superior vena cava syndrome	5	7
Horner's syndrome	1	1

4. Histologic study according to the World Health Organization classification.

5. Complications and progress. Postsurgery complications (injury to the recurrent laryngeal nerve, hypoparathyroidism) and recurrence.

RESULTS

Clinical Data. Only 2 patients had a family history of goiter, and 3 others had undergone previous surgery for either goiters or thyroid nodules. Fifteen patients (21%) had received thyroxine treatment earlier in the course of the goiter. Of the 72 patients, 21 (29%) were admitted for an increase in size of a previously acknowledged goiter, 20 (28%) for dyspnea, 12 (17%) for a cervical mass, 4 (6%) for symptoms of hyperthyroidism, 3 (4%) for dysphonia, and 1 (1%) for dysphagia. Another 11 cases (15%) were accidentally discovered through chest radiology applied for other reasons. All the patients were symptomatic, and the clinical data of these patients are shown in Table 1. Sixty-seven patients showed a palpable cervical mass (suggesting a substernal prolongation in 34 cases). Five patients had no palpable goiter, but were symptomatic (3 dyspnea and 2 dysphagia). Five patients presented with superior vena cava syndrome, and 1 with unilateral Horner's syndrome.

Complementary Exploration. The thyroid hormone levels were high in 5 patients and normal in the rest. Cervicothoracic radiology (see Figure, A) demonstrated the substernal component of the goiter in 54 cases. Tracheal deviation was revealed in 48 patients, and tracheal compression in 7. Another 7 patients were normal in terms of tracheal deviation or compression. Gammagraphy (see Figure, B) was performed in 47 patients. Five of these patients pre-

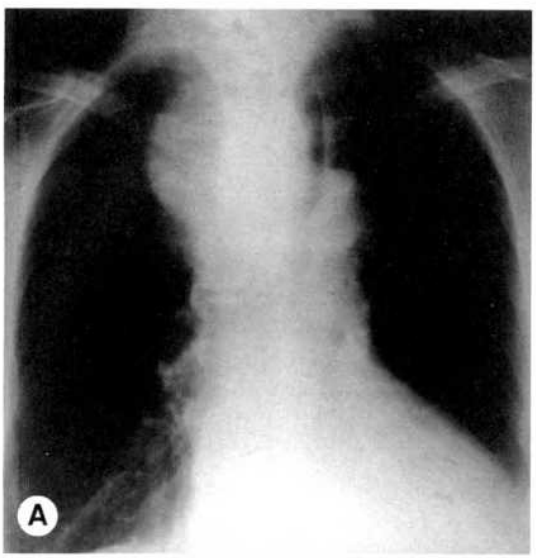

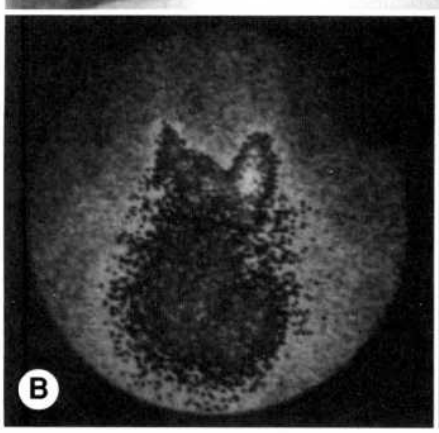

Substernal goiters. A) Chest radiograph showing intrathoracic goiter with major tracheal deviation. B) Gammagraphy showing large intrathoracic goiter. C) Computed tomography scan showing mediastinal goiter.

TABLE 2. EFFICIENCY OF EXPLORATORY TECHNIQUES FOR DIAGNOSING SUBSTERNAL GOITER

Exploratory Technique	Diagnosis of Substernal Goiter No.	%
Chest radiography (n = 72)	54	75
Gammagraphy (n = 47)	9	19
Ultrasonography (n = 40)	6	15
Computed tomography (n = 18)	18	100
Clinical exploration (n = 72)	34	47

sented with a hot nodule, and 42 with a cold multinodular goiter. (Nine showed a gammagraphically substernal component and 6 tracheal deviation.) Ultrasonography was performed in 40 patients, revealing a solid multinodular goiter in 31 of them, and a solid cystic component in 9. Six patients had intrathoracic spread of the goiter, and 3 had tracheal deviation. A CT scan disclosed a mediastinal mass in the 18 patients in whom it was performed (see Figure, C). Nine were, further, found to have tracheal deviation, 2 to have esophageal compression, and another 2 to have mediastinal vascular compression. An FNA suggested a benign lesion (colloid nodule) in 34 patients and a suspicious lesion (follicular proliferation) in 5 patients. Indirect laryngoscopy detected alterations in the motion of the vocal cords in 3 of the 7 explorations carried out. A barium esophagogram was applied in 6 patients, all with dysphagia, and we found a mass effect in 5 of them. Only 1 patient received cavography, which revealed compression and deviation of the superior vena cava. The results of the complementary explorations are shown in Table 2.

Surgical Treatment. The surgical approach was Kocher cervicotomy in 67 patients (93%), sternotomy in 3 (4%), and right thoracotomy in 2 (3%). We performed total thyroidectomy in 35 cases (49%), bilateral subtotal thyroidectomy in 13 (18%), lobectomy in 22 (30%), and simple resection of an intrathoracic ectopic thyroid residue in 2 (3%). One patient required emergency surgery for acute respiratory insufficiency. Only 1 patient was intubated with the aid of a fiberscope. No patient required a tracheotomy.

Histologic Study. The definitive histologic report was follicular adenoma in 18 cases (25%) and multinodular goiter in 54 (75%). We found 3 occult carcinomas (4%), including 2 papillary carcinomas and 1 follicular carcinoma measuring between 0.1 and 0.6 cm.

Complications and Progress. There was 1 patient with permanent unilateral vocal cord paralysis (1.4%) and 1 patient with permanent hypoparathyroidism (1.4%). Both were patients with subtotal thyroidectomy. The permanent recurrent laryngeal nerve injury was in a patient with preoperative dysphonia; the intrathoracic goiter partly compressed the left recurrent nerve. In spite of the identification of the nerve and meticulous dissection, the paralysis of the vocal cord persisted postoperatively. There was an iatrogenic pneumothorax in 1 case. Two patients required prolonged (48 hours) intubation due to respiratory problems. The mean follow-up was 10 years (range 3 to 18), and we recorded no cases of recurrent goiter. Additionally, 2 of the 3 patients with carcinoma remain asymptomatic; the other patient (with papillary carcinoma) shows cervical adenopathies.

DISCUSSION

The percentage of SSGs in relation to the total number of goiters varies considerably (1% to 15%), depending on the series, probably due to the differences in definition. Following the Lahey Clinic criteria,[6] we regard as SSGs those that require dissection in the upper mediastinum for removal. This generally implies that most of the goiter is substernal, and this is the criterion used by Katlic et al.[7]

An SSG may originate from the growth of a cervical goiter toward the thorax, which is basically explained by anatomic factors (development toward the least resistant area, the weight of the thyroid tissue itself, negative thoracic pressure, and even constitutional factors).[8] It may also happen that in its growth the cervical connection becomes thinner, ending up as a fibrous tract that acts as a vascular pedicle and has the appearance of aberrant thyroid tissue.[9] The other possibility is that it is real ectopic thyroid tissue with no cervical connection, and with thoracic vascularization that may be located between the base of the tongue and the diaphragm due to alterations in the embryological migration of the thyroid.[9-12] Two of our cases had no connection with the cervical thyroid; these were the only 2 of the 72 with a posterior mediastinal location.

The most common symptoms in our series were respiratory difficulties, which were more severe in patients over 70 years old, as is consistent with other series.[2,6,13] Reports of hyperthyroidism range from 0%[3,7] to probably in excess of Crile's 50%[14]; we recorded 7%, in line with others.[15,16] Superior vena cava syndrome is associated with mediastinal malignant tumors in over 95% of cases[17]; however, it can occasionally be associated with SSGs,[18-21] in which case a correct differential diagnosis becomes necessary. Remission with medical treatment is minimal[1]; 21% of our patients had received previous thyroxine treatment.

The possibility of an occult cancer is another reason for indicating surgery. We found 4% of our cases to be carcinomas — a ratio similar to that of other groups,[3-5,13,22-25] though no greater than that found in all other initially benign thyroid surgeries. Only Sanders et al[6] report 21% carcinomas.

Advances in anesthetic techniques and the use of small-caliber endotracheal tubes facilitate proper perioperative management, even in patients with significant respiratory compression symptoms. In this series, only 1 patient was intubated with the aid of a fiberscope, without intubation being attempted in the conventional way. This caused a tracheal rupture, which was sutured during the operation; the patient showed favorable progress after surgery.

Cervical incision is generally adequate, with few exceptions, such as very large posterior goiters, recurrent goiters, or carcinomas requiring mediastinal dissection.[2,3,6,23,26-28] In these cases, sternotomy is indicated. Thoracotomy is useful in cases of a posterior goiter,[12,27] and we used it in our 2 patients. As far as surgical technique is concerned, we performed total thyroidectomy in almost 50% of our patients. Our experience proved it does not increase complications (no hypoparathyroidism or permanent recurrent laryngeal nerve lesion in any of the 35 cases), it prevents recurrences, and in many cases it is technically easier than a subtotal thyroidectomy. In order to avoid injuries to the recurrent laryngeal nerve, we recommend 1) systematic identification of the recurrent nerve, 2) *not* enucleating the intrathoracic side of the goiter first, and 3) meticulous dissection to avoid stretching the nerve (this is more frequently found in the left side).

Further, the rare cases with tracheomalacia secondary to prolonged compression of the trachea caused by the mass need to be observed for postoperative airway compromise.[24] Fifteen patients were over 80 years old, and no particular problems were observed in this group of elderly patients.

Thus, in view of the low morbidity and zero mortality rates, we consider early surgical resection the most appropriate treatment in patients with SSG, even in the absence of compressive symptoms, since there is no other effective method to arrest the growth of the goiter and prevent acute airway obstruction.

REFERENCES

1. Miralles JM, Corrales JJ, Mories MT. Etiopatogenia del bocio simple esporádico. Endocrinologia 1985;32:25-33.
2. Allo MD, Thompson NW. Rationale for the operative management of substernal goiters. Surgery 1983;94:969-77.
3. Katlic MR, Grillo HM, Wang C. Substernal goiter. Analysis of 80 patients from Massachusetts General Hospital. Am J Surg 1985;149:283-7.
4. De Souza FM, Smith PE. Retrosternal goiter. J Otolaryngol 1983;12:393-6.
5. Sand ME, Laws HL, McElvein RB. Substernal and intrathoracic goiter: reconsideration of surgical approach. Arch Surg 1983;49:70-5.
6. Sanders LE, Rossi RL, Shahian DM, Williamson WA. Mediastinal goiters. The need of an aggressive approach. J Am Surg 1992;127:609-13.
7. Katlic MR, Wang C, Grillo HM. Substernal goiter. Ann Thorac Surg 1985;39:391-9.
8. Lahey FH, Swinton NW. Intrathoracic goiter. Surg Gynecol Obstet 1934;59:627-37.
9. Hall TS, Caslowitz P, Popper C, Smith GH. Substernal goiter versus intrathoracic aberrant thyroid: a critical difference. Ann Thorac Surg 1988;46:684-5.
10. Dundas P. Intrathoracic aberrant goiter. Acta Chir Scand 1964;128:729-31.
11. Nwafo DC. Heterotopic mediastinal goiter. Br J Surg 1978;65:505-8.
12. Ziter FMH. Ectopic mediastinal thyroid. Dis Chest 1966; 49:641-4.
13. Torre G, Borgonovo G, Amato A, et al. Surgical management of substernal goiter: analysis of 237 patients. Am Surg 1995;61:826-31.
14. Crile G Jr. Intrathoracic goiter. Cleve Clin Q 1939;6:313-22.
15. Fui NT, Prior J, Saunders AJ, Maisey MN. Posterior intrathoracic goiter as a cause of hyperthyroidism. Br J Radiol 1979;52:995-8.
16. Lamke LO, Bergdahl L, Lamke B. Intrathoracic goiter: a review of 29 cases. Acta Chir Scand 1979;145:43-7.
17. Davies PF, Sheveland JE. Superior cava obstruction: an analysis of seventy-six cases, its comments on the safety of venography. Angiology 1985;36:354-7.
18. Cengiz K, Aykin A, Demirci A, Diren A. Intrathoracic goiter with hyperthyroidism, tracheal compression, superior cava syndrome and Horner's syndrome. Chest 1990;97:1005-6.
19. Escalante CP. Causes and management of superior vena cava syndrome. Oncology 1993;7:61-8.
20. Kessler P, Olmedo J, Jareño J, Pascual T. Síndrome de vena cava superior en un bocio retroesternal. An Med Int 1989; 6:479-80.
21. Wilfrido MS, Lao RS, Seo S. Scintigraphy features of superior vena cava obstruction due to substernal non-toxic goiter. Br J Radiol 1982;55:301-3.
22. Bashist B, Ellis K, Gold RP. Computed tomography of intrathoracic goiters. Am J Radiol 1983;140:455-60.
23. Madjar S, Weisberg D. Retrosternal goiter. Chest 1995; 108:78-82.
24. Newman E, Shara AR. Substernal goiter. J Surg Oncol 1995;60:207-12.
25. De Andrade MA. A review of 128 cases of posterior mediastinal goiter. World J Surg 1977;1:789-94.
26. Mack E. Management of patients with substernal goiters. Surg Clin North Am 1995;75:377-94.
27. Shahian DM, Rossi RL. Posterior mediastinal goiter. Chest 1988;94:599-602.
28. Proye CAG. Substernal goiters. Surgical technique. Curr Pract Surg 1992;5:72-7.

THORACIC DUCT CYST: A CASE REPORT AND REVIEW OF 29 CASES

PETRI S. MATTILA, MD, PHD
JUSSI TARKKANEN, MD, PHD
SEVERI MATTILA, MD, PHD
HELSINKI, FINLAND

Cysts of the thoracic duct are rare. We report a case of a cervical thoracic duct cyst and review 29 thoracic duct cysts reported previously (19 mediastinal, 9 cervical, and 1 abdominal). The mean age of the patients was 47.6 years (range 17 to 86 years). Fourteen (46.7%) of the patients were asymptomatic. When symptoms were present, they ranged from retrosternal pain, dysphagia, and dyspnea to respiratory insufficiency and superior vena cava compression. Diagnosis of the cyst can be made after computed tomography or ultrasonography. The cystic fluid contains T lymphocytes and triglycerides in excess. The symptoms in a patient with a thoracic duct cyst are related to compression of adjacent structures. The most profound symptoms are likely to be produced by mediastinal cysts above the aortic arch. Treatment consists of surgical removal of the cyst and ligation of all lymphatics connected to the cyst.

KEY WORDS — supraclavicular tumor, thoracic duct.

INTRODUCTION

Cysts of the thoracic duct are uncommon. Nineteen cases of mediastinal thoracic duct cysts,[1-19] 1 case of abdominal thoracic duct cyst,[20] and 9 cases of cervical thoracic duct cysts have previously been reported in the literature.[21-29] We describe a case of a cervical thoracic duct cyst and review the symptoms of the 29 previously reported cases of thoracic duct cysts. The age, sex, and symptoms of the patients and the locations of the cervical and mediastinal cysts are given in Tables 1[21-29] and 2.[1-19]

CASE REPORT

The patient was a 49-year-old woman who had previously been healthy. She experienced swelling of the left side of her neck for the first time during a trip to the Middle East in 1992. This discomfort subsided when she returned home, but it recurred in May and July 1993. She was then admitted to another hospital. At ultrasonography, a 16 × 16-mm cyst was seen in the left supraclavicular region. She was given corticosteroids and the mass disappeared. In October 1996, she was admitted to our hospital because of swelling of the left side of the neck and left arm and discomfort in breathing.

On admission, a soft mass was palpated in the left supraclavicular region. At ultrasonography, a 16 × 20-mm cystic lesion was detected at the junction of the left internal jugular and subclavian veins (Fig 1). This was confirmed by computed tomography (Fig 2). Needle aspiration of the cystic content revealed milky fluid that contained a triglyceride level of 26 mmol/L, a cholesterol level of 1.6 mmol/L, and a protein level of 27 g/L, of which 26.2 g/L was albumin. The cell count of the cystic fluid was 0.8×10^9 cells per liter. Microscopic analysis revealed that

TABLE 1. REPORTS ON 10 CASES OF CERVICAL THORACIC DUCT CYST

Sex	*Age*	*Location*	*Symptoms*	*Authors*	*Year*
F	18	Right	Asymptomatic	Steinberg[21]	1964
F	76	Left	Asymptomatic	Barlow and Gracey[22]	1965
F	28	Left	Supraclavicular pain	Steinberg and Watson[23]	1966
F	55	Left	Asymptomatic	Kolbenstvedt and Aanese[24]	1986
M	17	Left	Asymptomatic	Arnault et al[25]	1990
F	63	Left, extending to mediastinum	Asymptomatic	Sakamoto et al[26]	1991
M	56	Left	Asymptomatic	Wax and Treolar[27]	1992
F	64	Left	Sore throat, sense of pressure in neck	Masuda et al[28]	1992
M	59	Left, extending to mediastinum	Dyspnea, cough	Okazaki et al[29]	1996
F	49	Left	Swelling of neck	This report	

From the Departments of Otorhinolaryngology (P. S. Mattila) and Surgery (S. Mattila), Helsinki University Central Hospital, and the Department of Pathology, Haartman Institute, University of Helsinki (Tarkkanen), Helsinki, Finland. This work received financial support from the Paulo Foundation.

CORRESPONDENCE — Petri S. Mattila, MD, PhD, Dept of Otorhinolaryngology, Helsinki University Central Hospital, Haartmaninkatu 4E, FIN-00290 Helsinki, Finland.

TABLE 2. REPORTS ON 19 CASES OF MEDIASTINAL THORACIC DUCT CYST

Sex	*Age*	*Location*	*Symptoms*	*Authors*	*Year*
F	20	Hilus of right lung	Substernal pain, dyspnea, cough	Emerson[1]	1950
M	42	Above diaphragm	Epigastric pain	Bakst[2]	1954
M	35	Above diaphragm	Chest pain	Cohen and Kompaniez[3]	1962
M	43	Above aortic arch	Asymptomatic	Thomas et al[4]	1966
F	46	Above diaphragm	Asymptomatic	Beasley and Mills[5]	1971
F	35	Above aortic arch	Respiratory insufficiency, superior vena cava compression	Fromang et al[6]	1975
M	42	Below aortic arch	Postprandial retrosternal pain	Cervantes-Peres and Fuentes-Maldonado[7]	1976
F	45	Above aortic arch	Dyspnea	Gowar[8]	1978
F	56	Below aortic arch	Asymptomatic	Luosto et al[9]	1978
M	60	Hilus of right lung	Asymptomatic	den Otter[10]	1979
M	40	Below aortic arch	Retrosternal pain, dysphagia, dyspnea	Hori et al[11]	1980
F	49	Below aortic arch	Eructation	Tsuchiya et al[12]	1980
M	57	Below aortic arch	Asymptomatic	Morettin and Allen[13]	1986
F	27	Below aortic arch	Asymptomatic	Adachi et al[14]	1989
M	72	Above aortic arch, on right side	Dysphagia	Takahashi et al[15]	1990
M	86	Above aortic arch	Severe dyspnea and cyanosis	Mori et al[16]	1992
M	33	Above aortic arch	Asymptomatic	Muramatsu et al[17]	1992
M	45	Above aortic arch	Asymptomatic	Okabe et al[18]	1993
M	57	Below aortic arch	Retrosternal pain, cough	Lamers and van Belle[19]	1994

the cells of the cystic fluid were lymphocytes and that neutrophils, macrophages, and epithelial cells were absent. Flow cytometric analysis showed that more than 99% of the lymphocytes were CD3-positive T lymphocytes. Natural killer cells were absent. The high level of triglycerides and the result of the cellular analysis of the cystic fluid were highly suggestive of a thoracic duct cyst.

An operation was planned. However, when the mass disappeared after aspiration, the patient refused to be operated on. In 6 weeks, the mass reappeared and the patient was again admitted for operation. At operation, the cyst was exposed by dividing the left sternocleidomastoid muscle above its insertion at the clavicle. We had given 100 mL of cream to the patient orally 2.5 hours before the surgery to facilitate the location of the cyst at the operation. The cyst was located at the junction of the internal jugular and left subclavian veins, anteromedial to the anterior scalenus muscle. The cyst was multilocular, was $38 \times 25 \times 20$ mm in dimension, and contained milky lymphatic fluid. The wall of the cyst was thin com-

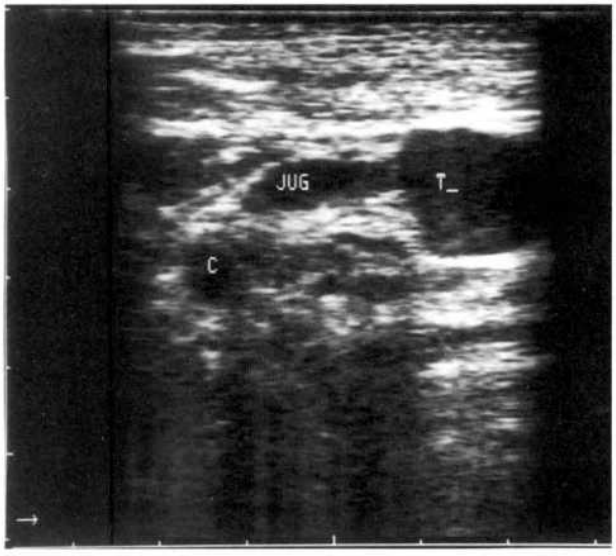

Fig 1. Ultrasonography of cyst. Thoracic duct cyst (T), jugular vein (JUG), and carotid artery (C) are indicated.

Fig 2. Contrast-enhanced computed tomography of cyst. Thoracic duct cyst (T) can be seen below left sternocleidomastoid muscle, adjacent to jugular vein (J).

pared with the walls of several lymphatics, 0.5 to 3 mm in diameter, connected to the cyst. The cyst was removed, and the connecting lymphatics were ligated with 3-0 Dexon. A vacuum drain was left in place for 4 days. The patient was kept on a low-fat diet during her stay in the hospital. After removal of the drain, some lymphatic discharge continued for 1 day. At reexamination 3 weeks postoperatively, the patient had recovered uneventfully, with a well-healed operative wound. Microscopic analysis of the removed cyst was in agreement with the clinical diagnosis of a thoracic duct cyst.

DISCUSSION

The thoracic duct originates from the cisterna chyli, which drains the small lymphatics of the intestine. It runs upward to the right side of midline, to the level of the fifth or sixth thoracic vertebra, where it crosses to the left side to run between the aorta and the azygos vein. It enters the left side of the neck posterior to the innominate artery and arches 3 to 5 cm above the clavicle, running anteriorly to the phrenic nerve, thyrocervical trunk, and subclavian artery. It lies posterior to the carotid artery, vagus nerve, and internal jugular vein in the majority of cases. It empties into the junction of the left subclavian vein and internal jugular vein.[30] The wall of the thoracic duct is relatively thick in the thoracic region. It contains collagenous and elastic fibers with a few longitudinally arranged smooth muscle fibers. The cervical portion is made up of a thin subendothelial layer of connective tissue without any internal elastic lamina and a thin layer of smooth muscle fibers. The flow in the thoracic duct depends on several factors, including respiratory pressure changes, transmitted pulsations from adjacent vessels, and active peristaltic contractions of the duct.

The causes of thoracic duct cysts are uncertain. Congenital weakness of the cystic wall and degeneration due to infection or inflammation of the duct are thought to be causative factors.[22-25,27] Obstruction of the thoracic duct inlet into the vein may predispose to cystic dilatation.[22] In the present case, the cyst itself was very thin-walled macroscopically, and inflammatory changes were missing. No direct communication of the duct into the subclavian or internal jugular vein was found at operation. Therefore, obstruction of the lymphatic flow and weakness of the ductal wall were the most probable causes of the cyst in the present case.

Fourteen (47%) of 30 patients with a thoracic duct cyst were asymptomatic (Tables 1 and 2). If symptoms related to the cyst were present, they were due to compression of adjacent structures. They ranged from retrosternal or substernal pain, dysphagia, cough, and dyspnea to respiratory failure with cyanosis[16] or severe compression of the trachea and superior vena cava[6] (Table 2). Seven of the 10 patients with cervical cysts were female, but only 7 of the 19 cases with mediastinal cysts were female; however, gender did not statistically correlate with cervical or mediastinal location ($p = .064$, Fisher's exact test). Thoracic duct cysts can also occur in the abdomen. Hvid-Jacobsen et al[20] described a large, painless abdominal cyst of 13 × 20 × 25 cm that simulated ascitic fluid in a 54-year-old man. Most of the cysts occur in patients 40 to 60 years of age.

Diagnosis of the thoracic duct cyst can be made after puncture of the cyst. Aspiration of milky fluid confirms the nature of the cyst. The cystic fluid contains triglycerides in excess, and an analysis of the cells of the fluid reveals the presence of lymphocytes and the absence of neutrophils, macrophages, and epithelial cells. Water-soluble contrast medium can be injected into the cyst and may visualize the cyst and the thoracic duct down to the lumbar level.[24] Computed tomography and magnetic resonance imaging are helpful for more accurate location of the cyst. In addition to malignancies, the differential diagnostic possibilities include lateral (branchiogenic) or medial (thyroglossal duct) cysts and cystic hygroma. The presence of lymphocytes and triglycerides differentiates thoracic duct cyst from cystic hygroma, which is also lined by endothelium.

The therapy is simple excision with ligation of the lymphatics connected to the cyst. Ligation of the thoracic duct itself is possible at any level. If it is accidentally transected, it can be ligated without any associated morbidity, since numerous anastomoses between the thoracic duct and the hemiazygos vein can receive the lymphatic drainage. In the previously reported cases, excision of the thoracic duct cysts resulted in cure without any adverse effects besides a self-limiting chylous leakage. This was also the case in our patient.

REFERENCES

1. Emerson GL. Supradiaphagmatic thoracic duct cyst. N Engl J Med 1950;242:575-8.

2. Bakst AA. Blind supradiaphragmatic thoracic duct cyst. Ann Surg 1954;140:250-3.

3. Cohen EB, Kompaniez E. Supradiaphragmatic thoracic duct cyst. N Engl J Med 1962;266:1319-21.

4. Thomas MJ, Sanger PW, Taylor FH, Robicsek F. Thoracic duct cyst of the mediastinum; a case report. Lancet 1966; 86:579-80.

5. Beasley WE, Mills M. Chylous cystectomy with prosthet-

ic reconstruction of the diaphragm and esophageal hiatus. J Thorac Cardiovasc Surg 1971;61:324-9.

6. Fromang DR, Seltzer MB, Tobias JA. Thoracic duct cyst causing mediastinal compression and acute respiratory insufficiency. Chest 1975;67:725-7.

7. Cervantes-Peres P, Fuentes-Maldonado R. Thoracic duct cyst of the mediastinum. Chest 1976;70:411.

8. Gowar FJS. Mediastinal thoracic duct cyst. Thorax 1978; 33:800-2.

9. Luosto R, Koikkalainen K, Jyrälä A, Mäkinen J. Thoracic duct cyst of the mediastinum. Scand J Thorac Cardiovasc Surg 1978;12:261-3.

10. den Otter G. Thoracic duct cyst in the anterior mediastinum. Arch Chir Neerl 1979;31:107-10.

11. Hori S, Harada K, Morimoto S, Uchida H, Okumura K. Lymphangiographic demonstration of thoracic duct cyst. Chest 1980;78:652-4.

12. Tsuchiya R, Sugiure Y, Ogata T, Suemasu K. Thoracic duct cyst of the mediastinum. J Thorac Cardiovasc Surg 1980; 79:856-9.

13. Morettin LB, Allen TE. Thoracic duct cyst: diagnosis with needle aspiration. Radiology 1986;161:437-8.

14. Adachi A, Watanabe J, Kurohiji T, Nishimura Y, Edakuni S, Kakegawa T. A case report of thoracic duct cyst. Nippon Kyobu Geka Gakkai Zasshi 1989;37:1586-9.

15. Takahashi C, Hanyuda M, Fukaya Y, Nohara H, Morimoto M, Iida F. Thoracic duct cyst. A case report. Nippon Kyobu Geka Gakkai Zasshi 1990;38:1214-8.

16. Mori M, Kidogawa H, Isoshima K. Thoracic duct cyst in the mediastinum. Thorax 1992;47:325-6.

17. Muramatsu M, Tamura N, Doi Y, et al. A case of a mediastinal lymphatic cyst possibly originating from the right thoracic duct. Nippon Kyobu Shikkan Gakkai Zasshi 1992;30: 1136-40.

18. Okabe K, Miura K, Konishi H, Hara K, Shimizu N. Thoracic duct cyst of the mediastinum. Scand J Thorac Cardiovasc Surg 1993;27:175-7.

19. Lamers RJS, van Belle AF. Thoracic duct cyst in the middle part of the mediastinum. Am J Roentgenol 1994;161:675.

20. Hvid-Jacobsen K, Nielsen SL, Jensen VJ, Thomsen HS. Demonstration of the thoracic duct by 123-I heptadecanoic acid. Report of a case. Acta Radiol 1987;28:783-4.

21. Steinberg I. Roentgen diagnosis of persistent jugular lymph sac. Radiology 1964;82:1022.

22. Barlow D, Gracey L. Cystic dilatation of the thoracic duct. Br J Clin Pract 1965;19:101-2.

23. Steinberg I, Watson RC. Lymphangiographic and angiographic diagnosis of persistent jugular lymph sac. Report of a case. N Engl J Med 1966;275:1471-4.

24. Kolbenstvedt A, Aanese J. Cystic dilatation of the thoracic duct presenting as a supraclavivular mass. Br J Radiol 1986;59:1228-9.

25. Arnault G, Winants D, Charles M, Gosepath J, Schafer K. Kystes du canal thoracique. A prospes d'une localisation sus-claviculaire. J Radiol 1990;71:61-4.

26. Sakamoto H, Uda H, Sato A, Tanaka S, Kuwabara H, Miyauchi A. Thoracic duct cyst of the neck: a case report. Lymphology 1991;24:130-4.

27. Wax MK, Treolar ME. Thoracic duct cyst: an unusual supraclavicular mass. Head Neck 1992;14:502-5.

28. Masuda R, Furuhata Y, Kasahara D, Tanaka I, Inonue M, Takemura T. Preoperative diagnosis of a thoracic duct cyst arising in the supraclavicular fossa. Surgical case report. Nippon Kyobu Geka Gakkai Zasshi 1992;40:320-5.

29. Okazaki T, Shinkai M, Fujiwara H, Nasu M, Nishiushi S, Shiyoumura T. Thoracic duct cyst. A case report. Nippon Kyobu Geka Gakkai Zasshi 1996;44:830-4.

30. Fuchs WA. Normal radiologic anatomy of the lymphatics and lymph nodes. In: Abrahams HL, ed. Abraham's angiography: vascular and interventional radiology. Boston, Mass: Little, Brown, 1983:1997-2002.

POSTNATAL DEVELOPMENT OF MYOSIN HEAVY CHAIN ISOFORMS IN RAT LARYNGEAL MUSCLES

AKIHIRO SHIOTANI, MD
TOKYO, JAPAN

RICHARD M. JONES, MD
BALTIMORE, MARYLAND

PAUL W. FLINT, MD
BALTIMORE, MARYLAND

The developmental transitions of myosin heavy chain (MHC) isoforms of rat posterior cricoarytenoid (PCA), thyroarytenoid (TA), cricothyroid (CT), and lateral cricoarytenoid (LCA) muscles were examined by means of sodium dodecyl sulfate–polyacrylamide gel electrophoresis (SDS-PAGE) and Western blot techniques. The muscles were microscopically dissected from animals on postnatal days 0, 3, 7, 10, 14, 21, 28, 35, 45, and 55 and from adult animals. Silver-stained SDS-PAGE gels of each muscle were analyzed densitometrically to measure the composition of MHC isoforms, and Western blot was carried out to identify specific bands. Characterizations of the internal laryngeal muscles determined by the composition of MHCs were correlated with their function in the adult. Temporally, differentiation reflects onset of function. Differentiation of isoforms and transition to adult forms occur first in the TA muscle, followed by the PCA, LCA, and CT muscles. Expression of type IIL was observed only in muscles innervated by the recurrent laryngeal nerve. Postnatally observed developmental differences of myosin phenotypes suggest that regulation of MHC expression is influenced by neural activity or other environmental factors.

KEY WORDS — development, laryngeal muscle, myosin heavy chain, sodium dodecyl sulfate–polyacrylamide gel electrophoresis, Western blot.

INTRODUCTION

The intrinsic laryngeal muscles have different functional roles and physiological characteristics. Recent advances in the technique of gel electrophoresis make it possible to determine the composition of myosin heavy chains (MHCs). The MHC fiber type determines the maximum contraction speed of a given muscle fiber.[1-3] The MHC phenotype, or relative composition of MHCs, reflects the physiological demands on each specific muscle.[4,5] Within the larynx, the MHC composition can be correlated with laryngeal function: airway protection, respiration, and phonation. Previous studies[6-10] have characterized MHC fiber types within laryngeal muscles. Muscles associated with glottic closure and airway protection maintain predominantly fast fiber types, while muscles with respiratory function maintain a mixed population of fast and slow fiber types.[6] The thyroarytenoid (TA) muscle was shown to contain the superfast extraocular MHC in rabbits.[11] In subsequent reports on MHC components in rat laryngeal muscle, the superfast extraocular fibers are referred to as type IIL.[6,12]

In this study, we investigate the developmental transition of MHC isoforms in rat intrinsic laryngeal muscles from birth to adulthood. Understanding the developmental transition of MHCs in the intrinsic laryngeal muscles will give us insight into how laryngeal motoneurons modulate their target muscles during the course of normal development and may be applicable to study of nerve regeneration following recurrent laryngeal nerve injury. This information will also provide a better understanding of the chronological sequence of laryngeal muscle maturation and the functional significance of this process.

MATERIALS AND METHODS

Tissue Preparation. Institutional guidelines, in accordance with the Animal Welfare Act of 1966 and all subsequent revisions, including those made in 1985 and National Institutes of Health guidelines, were followed for the handling and care of laboratory animals. Sprague-Dawley rats were chosen as the investigational species, as this animal has been used extensively in our laboratory for related studies.[13,14]

The animals were anesthetized with a lethal dose of sodium pentobarbital. Laryngeal muscles from each animal — posterior cricoarytenoid (PCA), TA,

From the Department of Otolaryngology–Head and Neck Surgery, Johns Hopkins University School of Medicine, Baltimore, Maryland. Dr Shiotani is currently at the Department of Otolaryngology–Head and Neck Surgery, Keio University School of Medicine, Tokyo, Japan. This research was supported, in part, by National Institutes of Health/National Institute on Deafness and Other Communication Disorders grants 5K08 DC0081-03 and 5T32 DC00027-07. This study was performed in accordance with the PHS Policy on Humane Care and Use of Laboratory Animals, the NIH *Guide for the Care and Use of Laboratory Animals*, and the Animal Welfare Act (7 U.S.C. et seq.); the animal use protocol was approved by the Institutional Animal Care and Use Committee (IACUC) of Johns Hopkins University.

Presented at the American Academy of Otolaryngology–Head and Neck Surgery Research Forum, Washington, DC, September 30, 1996.

CORRESPONDENCE — Paul W. Flint, MD, PO Box 41402, Baltimore, MD 21203-6402.

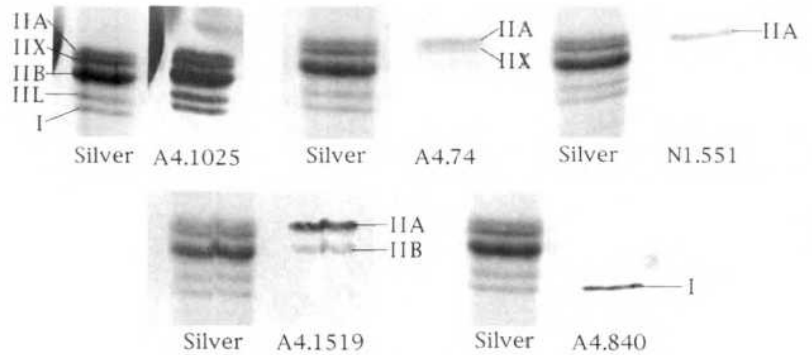

Fig 1. Representative results of Western blots of adult posterior cricoarytenoid (PCA) muscle. I — type I myosin heavy chain (MHC); IIA — type IIA MHC; IIB — type IIB MHC; IIL — type IIL MHC; IIX — type IIX MHC.

cricothyroid (CT), and lateral cricoarytenoid (LCA) — were rapidly microdissected from animals on postnatal days 0, 3, 7, 10, 14, 21, 28, 35, 45, and 55 and from adult animals (more than 115 days). A minimum of 4 rats were processed at each stage.

SDS-PAGE. Muscle tissue was sonicated in relaxing buffer containing 0.1-mol/L potassium chloride, 5-mmol/L ethyleneglycoltetraacetic acid, 5-mmol/L ethylenediaminetetraacetic acid, and 1-mmol/L dithiothreitol, centrifuged, and prepared in sample buffer containing 150-mmol/L Tris, 4% sodium dodecyl sulfate (SDS), and 10% ß-mercaptoethanol at pH 6.8.[15] Sodium dodecyl sulfate–polyacrylamide gel electrophoresis (SDS-PAGE) was performed with a 0.75-mm-thick 5.5% acrylamide–35% glycerol separating gel and a 3% acrylamide stacking gel. Running conditions were set at 7 mA (constant current) for 22 to 24 hours, and the temperature was kept below 10°C.[16] The running buffer was 0.3% Tris, 1.44% glycine, and 0.1% SDS.[6] The gels were developed with silver stain to visualize the protein bands by means of the Silver Stain Plus Kit (Biorad, Hercules, Calif). The stained gels were recorded and analyzed densitometrically with NIH image 1.58f software (Scientific Computing Resource Center, Bethesda, Md).

Western Blot. Western blotting was carried out on the protein bands obtained from the SDS-PAGE gel for identification of specific bands. The protein bands were transblotted onto a polyvinylidene difluoride membrane at 35 mA for 1 hour at 4°C.[17] The membranes were blocked for 1 hour in blocking buffer (5% nonfat dry milk in Tween 20 in Tris-buffered saline) prior to antibody staining. Antibodies specific for MHCs (A4.840, A4.1519, N1.551, A4.74, A4.1025, N3.36, and F1.652)[18-22] were diluted 1:3 or 1:4 in blocking buffer immediately before incubating with membranes for 2 hours at room temperature. Membranes were washed and incubated with alkaline phosphatase–labeled goat anti-mouse Ig antibodies (Southern Biotechnology Associate, Birmingham, Ala) diluted 1:1,000 in blocking buffer for 45 minutes at room temperature. Membranes were then washed and developed with an alkaline phosphatase conjugate substrate kit (Biorad).

All monoclonal antibodies were developed by H. M. Blau[18-22] and were obtained from the Developmental Studies Hybridoma Bank maintained by the Department of Pharmacology and Molecular Sciences, Johns Hopkins University School of Medicine, Baltimore, Md, and the Department of Biological Sciences, University of Iowa, Iowa City, Iowa, under contract N01-HD-2-3144 from the NICHD.

RESULTS

Identification of MHC Bands. Identification of the MHC bands was determined by silver-stained SDS-PAGE gel and Western blot techniques. Previous reports have identified each myosin band with the SDS-PAGE technique.[16,17,23-27] The slowest-migrating band is type IIA. Type IIX, neonatal-embryonic type, and type IIB follow sequentially. The fastest-migrating band is type I. Type IIL, discovered recently, falls between types IIB and I.[6] The order of migration in this study, from top to bottom, is IIA, IIX, neonatal-embryonic, IIB, and I, as is consistent with previous reports.[25,26] Localization of specific MHC bands was also confirmed in this study by Western blot. The sequence differs from that reported by Termin et al,[24] wherein the embryonic band separates between IIA and IIX. The observed difference in separation may be explained by differences in the separating gels. Termin et al utilized a gradient gel (5% to 8%), and a 5.5% acrylamide + 35% glycerol gel was applied in the present study. Comigration of embryonic and neonatal bands has been reported previously on a 5% acrylamide separating gel.[26]

Representative results of Western blots are shown in Fig 1 for adult PCA muscle. Antibodies A4.840, A4.1519, N1.551, A4.74, and A4.1025 were applied to transblotted membrane and are shown with the corresponding silver-stained gel. According to Cho et al,[18] immunostaining of type IIA occurs with A4.1519, N1.551, and A4.74. Weak staining of type

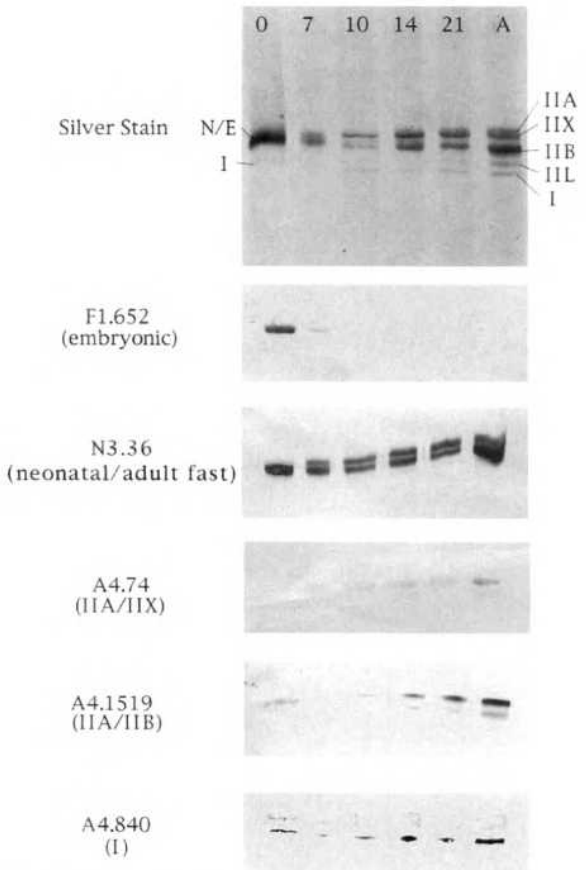

Fig 2. Representative results of Western blot and silver-stained gel demonstrating developmental transition in PCA muscle. N/E — neonatal and embryonic MHC.

IIX occurs with N1.551 and A4.74, but not with A4.1519. Weak reactivity with type IIB occurs with A4.1519, but not with N1.551 or A4.74. Immunostaining of type I occurs with A4.840.[22] Type IIL is identified with A4.1025, which reacts with all MHCs. Type IIL does not immunostain with A4.1519, N1.551, A4.74, and A4.840 antibodies. Antibody F1.652 reacts with embryonic MHC, while N3.36 reacts with neonatal and adult fast fiber types.

Figure 2 is an example of Western blots and the corresponding silver-stained gel demonstrating developmental transition in the PCA muscle. With F1.652, embryonic MHC is recognized from day 0 to day 7 and is not detectable at day 10. With N3.36, neonatal and adult fast MHCs are recognized in all the periods. Antibody A4.74 demonstrates reactivity with type IIA and/or IIX on day 7. A very light band is seen on the membrane of A4.74 at day 7. Antibody A4.1519 reacts strongly with IIA and reacts weakly with IIB. Emergence of IIA and IIB occurs on day 10 and day 14, respectively. However, by SDS-PAGE, both IIX and IIB can be seen at day 3. The positive band on A4.1519 at day 0 is thought to be a transitional MHC, previously described by Cho et al,[18] appearing early in development and distinct from both F1.652 (embryonic)–positive and N3.36 (neonatal)–positive MHC bands. Antibody A4.840, which reacts with type I, appears from day 0 to adulthood. Very slight cross-reactivity with fast MHCs is seen on this blot.

Developmental Transition of MHC. Representative samples of SDS-PAGE gels for the PCA, TA, CT, and LCA muscles (day 0 to adulthood) are shown in Figs 3-6. The graphs next to each SDS-PAGE gel (Figs 3-6) demonstrate percent MHC composition of all samples analyzed densitometrically. In PCA gels, separation of IIA and IIX permitted measurement of both fiber types independently. In CT and LCA gels, incomplete separation of IIA and IIX occurred, and IIA and IIX are therefore measured as 1 band. In the Table, the adult phenotypes of the PCA, TA, CT, and LCA muscles are also shown.

In the PCA muscle, heavy neonatal-embryonic and light type I bands are seen on day 0 (Fig 3). Types IIB and IIX are apparent on day 3 and reach adult levels at day 21 and day 10, respectively. Type IIA appears on day 10 and reaches the adult level on day 14. The neonatal-embryonic component decreases gradually and is undetectable on day 14. (By Western blot the embryonic band is undetectable on day 10, whereas the neonatal persists up to day 10.) Type IIL appears on day 10 and reaches the adult level on

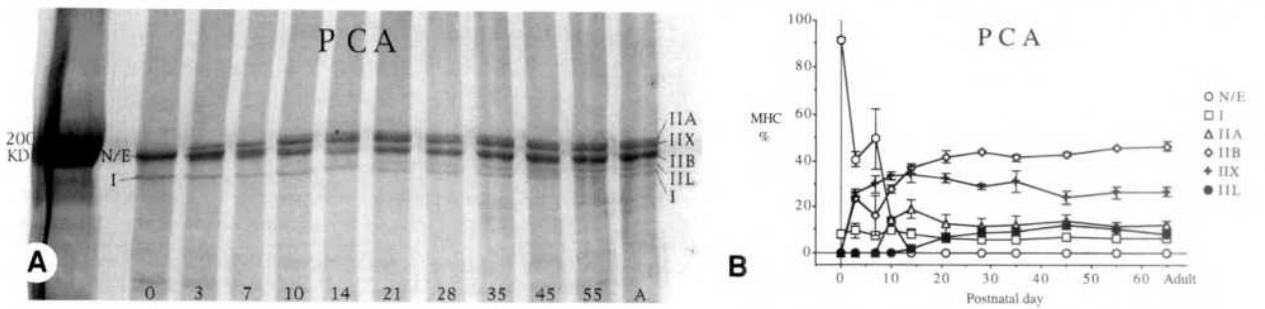

Fig 3. PCA muscle. A) Sodium dodecyl sulfate–polyacrylamide gel electrophoresis (SDS-PAGE) gels of representative samples of PCA muscle from day 0 to adulthood. Numbers at bottom indicate postnatal days. Molecular weight marker (200 KD) is shown in first lane on left. B) Densitometric analysis of relative percentage of each MHC component of PCA muscle at given postnatal days (mean ± SE).

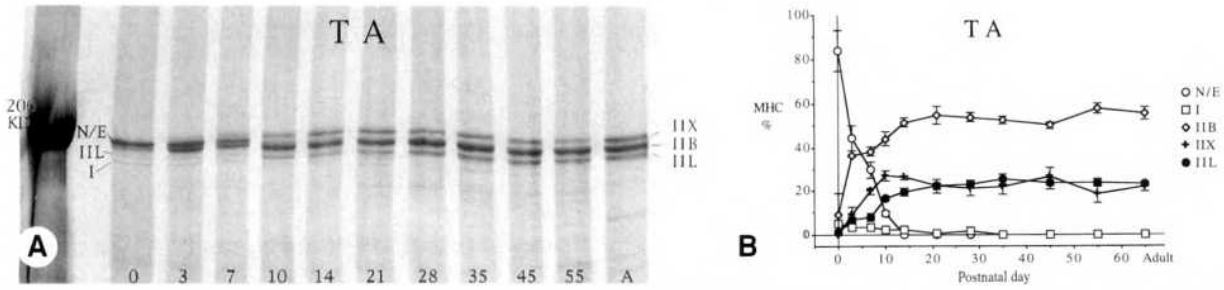

Fig 4. Thyroarytenoid (TA) muscle. A) SDS-PAGE gels of representative samples of TA muscle from day 0 to adulthood. Numbers at bottom indicate postnatal days. Molecular weight marker (200 KD) is shown in first lane on left. B) Densitometric analysis of relative percentage of each MHC component of TA muscle at given postnatal days (mean ± SE).

day 21. From day 21 to adulthood, there is little demonstrable change in myosin phenotype expression.

In the TA muscle, heavy neonatal-embryonic and light type IIB, IIL, and I bands are already present on day 0 (Fig 4). The type I band decreases gradually and is undetectable by day 28. This band does not react with anti-slow antibody (A4.840) and may represent an immature or different type I MHC subtype.[22] The neonatal-embryonic band is not detectable on day 14. (By Western blot, the embryonic band is undetectable on day 10.) Types IIB and IIL reach the adult level on day 14 and day 10, respectively. Type IIX appears on day 3 and reaches the adult level on day 10. From day 28 through adulthood, there is no demonstrable change in myosin phenotype. Type IIA MHC is not detectable in rat TA muscle.

In the CT muscle, heavy neonatal-embryonic and light type I bands are observed from day 0 to day 3 (Fig 5). On day 7, IIX appears, followed by IIA and IIB on day 10. The neonatal-embryonic band is undetectable at day 21. (By Western blot, the embryonic band is undetectable at day 14.) From day 21 to adulthood, there is no demonstrable change in myosin phenotype. Type IIL is not observed during any stage of development of the CT muscle.

In the LCA muscle, heavy neonatal-embryonic and light type I bands are observed on day 0 (Fig 6). Type IIX appears on day 3, and type IIA, IIB, and IIL components appear on day 10 (Fig 6). The neonatal-embryonic band is undetectable on day 21. (By Western blot, the embryonic band is undetectable on day 10.) From day 21 to adulthood, there is no demonstrable change in myosin phenotype.

The adult MHC phenotypes for rat PCA, TA, CT, and LCA muscles are described in the Table and shown as the relative percentages of MHC expressed. Notable differences in MHC expression include absence of type I and type IIA fibers in the TA muscle, and absence of type IIL in the CT muscle. The highest percentage of IIL is observed in the TA muscle. Both the PCA and LCA muscles express the entire spectrum of MHCs.

DISCUSSION

Adult Phenotype of Internal Laryngeal Muscles. The MHC type determines the maximum contraction speed of a given muscle fiber.[1-3] Type I fibers have slow-contracting and fatigue-resistant characteristics.[28] Type II fibers have fast-contracting characteristics. Among type II fibers, IIA has a high oxidative enzyme capacity and a fatigue-resistant character, and IIB is easily fatigable.[29] Type IIX has an intermediate resistance.[29] The MHC composition in rat PCA and TA muscles has recently been studied by adenosinetriphosphatase staining, immunohistochemistry, and SDS-PAGE.[6] The PCA muscle expresses types IIA/IIX (incomplete separation), IIB, IIL, and I, and the TA muscle expresses types IIA/IIX, IIB, and IIL.[6] Type IIL is considered to be the

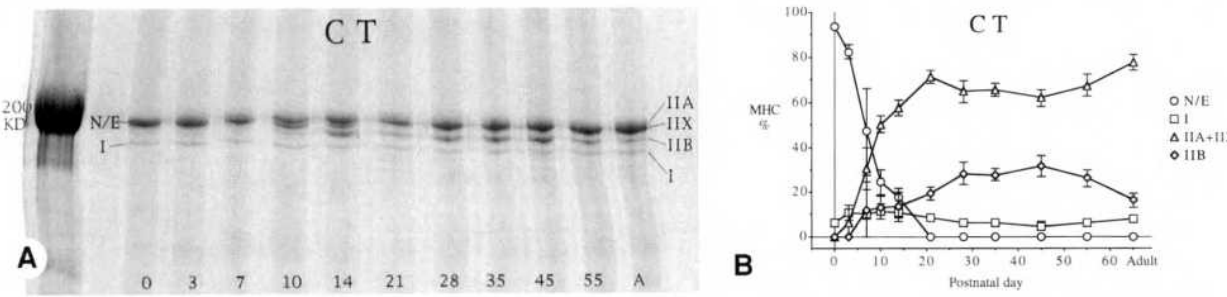

Fig 5. Cricothyroid (CT) muscle. A) SDS-PAGE gels of representative samples of CT muscle from day 0 to adulthood. Numbers at bottom indicate postnatal days. Molecular weight marker (200 KD) is shown in first lane on left. B) Densitometric analysis of relative percentage of each MHC component of CT muscle at given postnatal days (mean ± SE).

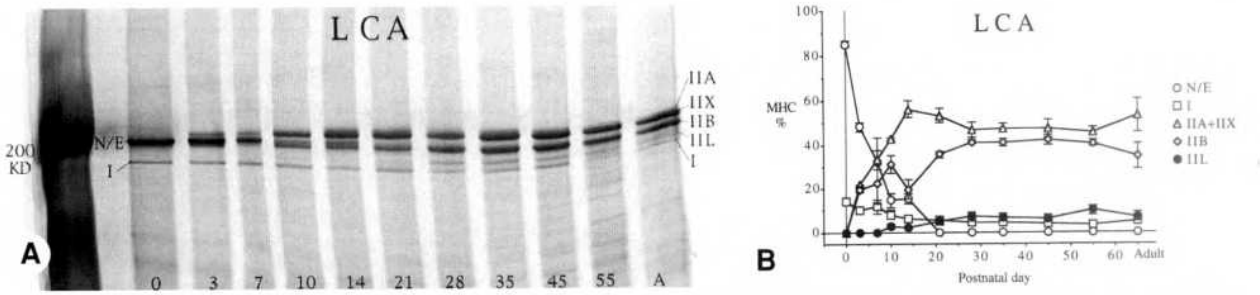

Fig 6. Lateral cricoarytenoid (LCA) muscle. A) SDS-PAGE gels of representative samples of LCA muscle from day 0 to adulthood. Numbers at bottom indicate postnatal days. Molecular weight marker (200 KD) is shown in first lane on left. In this composite gel, adult IIL appears artificially as doublet. In individual gels, IIL in adult LCA muscle appears as single band. B) Densitometric analysis of relative percentage of each MHC component of LCA muscle at given postnatal days (mean ± SE).

same as or similar to type EOM, a superfast MHC found in extraocular muscles in rabbits and rats.[11,12]

Our results (see Table) show the MHC composition of the internal laryngeal muscles to be predominately fast-contracting (IIA, IIB, and IIX). The composition of types I and IIL further characterizes each muscle. For example, the CT muscle has the largest percent composition of type I MHCs, followed by the PCA and LCA muscles. The TA muscle does not express type I; however, the TA muscle has the largest percent composition of type IIL, followed by the PCA and LCA muscles. The CT muscle does not express type IIL.

The MHC composition can be correlated with muscle function. The PCA muscle requires fatigue resistance in order to function continuously during the respiratory cycle as an abductor and would be expected to have a relatively larger composition of type I MHC and a smaller percentage of type IIL MHC. Conversely, the protective function of the adductor muscles would be enhanced by a relatively larger proportion of superfast IIL and IIB MHCs, as seen in the TA muscle. This composition of MHCs may be more suitable for a protective function, rather than phonation and swallowing. Another main adductor, the LCA muscle, has a relatively larger composition of type I and smaller composition of type IIL when compared to the TA muscle, which may reflect specialization of function during phonation and swallowing. The CT muscle contains the largest composition of type I and does not express type IIL. The higher concentration of type I MHC observed in the CT muscle is consistent with respiratory function, shared with the PCA muscle. Previous studies,[30-33] investigating the contraction properties of intrinsic laryngeal muscles in various animals, are consistent with our findings. The fastest contraction times are observed in the TA muscle, and the slowest are seen in the CT muscle. The LCA muscle has also been shown to have a slower contraction time relative to the TA muscle.[32]

The absence of expression of type IIL in the CT muscle is notable. The CT is the only muscle studied that is innervated by the superior laryngeal nerve. All other muscles expressing type IIL are innervated by the recurrent laryngeal nerve. This observation supports the concept that the motoneuron may influence MHC isoform expression during development. In contrast, Hoh and Hughes[34] reported that expression of superfast MHCs in regenerating cat jaw muscle was independent of innervation and was more likely determined by cell lineage. Further investigation is necessary to establish a relationship between the motoneuron and expression of superfast MHCs in specific laryngeal muscles.

Developmental Transition of MHCs. Transition of MHC isoforms in skeletal muscle during postnatal development has been studied in rat soleus muscle by SDS-PAGE and Western blot techniques.[35] Slow MHC is present in the soleus muscle at all time points

ADULT PHENOTYPES OF LARYNGEAL MUSCLES AS RELATIVE PERCENTAGES OF MYOSIN HEAVY CHAIN EXPRESSED

Muscle	*Type I*	*Type IIA*	*Type IIX*	*Type IIB*	*Type IIL*
PCA	6.5% ± 0.7%	12.0% ± 2.0%	26.8% ± 2.2%	46.3% ± 2.3%	8.3% ± 1.2%
TA	0%	0%	21.8% ± 2.1%	55.6% ± 3.0%	22.9% ± 1.1%
CT	8.5% ± 1.2%	77.8% ± 3.4%*		16.7% ± 3.2%	0%
LCA	5.3% ± 0.7%	52.7% ± 7.4%*		34.6% ± 5.7%	7.3% ± 2.2%

Data are mean ± SE.

PCA — posterior cricoarytenoid, TA — thyroarytenoid, CT — cricothyroid, LCA — lateral cricoarytenoid.

*Type IIA + type IIX.

examined, whereas the neonatal MHC diminishes in quantity between 2 and 3 weeks and is undetectable in the adult. Myosin isoform transitions occur sequentially from embryonic to neonatal to adult fast fiber types.[35] A similar pattern of development with sequential change from embryonic to neonatal to adult fast fiber types can be seen in our study. The disappearance of type I MHC during the course of TA development observed in this study suggests that slow fibers may also be influenced by environmental factors during postnatal development. This observation has not been previously reported. The type I band detected on the TA SDS-PAGE gel is not reactive with anti-slow antibody (A4.840) and may represent an immature fiber type or a different subtype of type I MHC as reported by Hughes et al.[22]

Myoblast differentiation is a complex process that appears to be influenced not only by cell lineage but also by external environmental factors.[20,36] Cell lineage may predominate during early stages of development, when initial myoblast migration occurs.[36] Subsequent MHC expression appears to be influenced by the local environment and may occur independent of nerve-muscle interaction.[20] By use of genetically marked myoblasts in vivo, myoblast clones in developing postnatal rat muscle have been shown to contribute to the entire spectrum of fast and slow fiber types.[20] Extrinsic signals appeared to override any predetermined commitment of myoblasts to follow a specific sequence of phenotype expression.[20] Subsequent changes in MHC expression and fiber patterns as a result of neural influence have not been defined.

Brozanski et al[26] studied the expression of MHCs in the rat during postnatal development and demonstrated temporal differences in transition of MHC isoforms between the genioglossus and diaphragm muscles. Neonatal MHC in diaphragm muscle can be detected up to day 21 and is found in genioglossus muscle up to day 25. LaFramboise et al[37] studied myosin isoforms in neonatal rat extensor digitorum longus, diaphragm, and soleus muscles. Their electrophoretic analysis of native myosin revealed that neonatal bands were undetectable from day 21 in extensor digitorum longus, and from day 30 in diaphragm muscle. The rate of elimination of neonatal MHC was fastest in extensor digitorum longus muscle, intermediate in diaphragm muscle, and slowest in soleus muscle. Similar, although earlier, transitions of myosin isoforms were observed in our study. In laryngeal muscle, neonatal MHC bands are undetectable on day 14 in the TA and PCA muscles and undetectable on day 21 in the LCA and CT muscles. Observed developmental differences of myosin phenotypes suggest that regulation of MHC expression is influenced by neural activity or other environmental factors.

Transition of muscle phenotypes from embryonic to adult isoforms can also be correlated with functional maturation. The TA muscle expresses the greatest degree of MHC isoform differentiation at birth, which may be influenced by in utero swallowing activity. The PCA muscle follows the TA in degree of MHC isoform differentiation and precedes both the LCA and CT muscles. Respiratory function, essential at birth, may necessitate early differentiation. The relative lag in LCA and CT transition may signify delayed functional challenges or environmental changes associated with respiratory function and airway protection. Whether these MHC isoform transition patterns are modulated by the prenatal and postnatal activity levels or simply represent temporal differences in nerve-muscle interaction cannot be determined by our observations. Further investigations at a molecular level, exploring gene regulation in relation to nerve-muscle interaction, will be necessary to answer this question.

CONCLUSIONS

1. The composition of laryngeal muscle MHCs is correlated with muscle function in the adult rat.

2. Temporally, muscle differentiation reflects onset of function. Differentiation of isoforms occurs first in the TA muscle, followed by the PCA, LCA, and CT muscles.

3. Expression of type IIL is observed only in muscles innervated by the recurrent laryngeal nerve.

4. Although cell lineage may impact early stages of myoblast differentiation, postnatally observed developmental differences of myosin phenotypes suggest that regulation of MHC expression is influenced by neural activity or other environmental factors.

Future studies will be directed toward gene regulation of nerve-muscle interaction and mechanisms by which the superior and recurrent laryngeal nerves influence fiber type expression.

REFERENCES

1. Reiser PJ, Moss RL, Giulian GG, Greaser ML. Shortening velocity in single fibers from adult rabbit soleus muscles is correlated with myosin heavy chain composition. J Biol Chem 1985;260:9077-80.

2. Ranatunga KW, Thomas PE. Correlation between shortening velocity, force-velocity relation and histochemical fibre-type composition in rat muscle. J Muscle Res Cell Motil 1990; 11:240-50.

3. Lännergren J. Contractile properties and myosin isozymes of various kinds of *Xenopus* twitch muscle fibres. J Muscle Res Cell Motil 1987;8:260-73.

4. Allemeier CA, Fry AC, Johnson P, Hikida RS, Hagerman FC, Staron RS. Effects of sprint cycle training on human skeletal muscle. J Appl Physiol 1994;77:2385-90.

5. Staron RS, Leonardi MJ, Karapondo DL, et al. Strength and skeletal muscle adaptations in heavy-resistance-trained women after detraining and retraining. J Appl Physiol 1991;70: 631-40.

6. DelGaudio JM, Sciote JJ, Carroll WR, Esclamado RM. Atypical myosin heavy chain in rat laryngeal muscle. Ann Otol Rhinol Laryngol 1995;104:237-45.

7. Teig E, Dahl HA, Thorkelsen H. Actomyosin ATPase activity of human laryngeal muscles. Acta Otolaryngol (Stockh) 1978;85:272-81.

8. Sahagal V, Hast MH. Histochemistry of primate laryngeal muscles. Acta Otolaryngol (Stockh) 1974;78:277-81.

9. Malmgren LT, Gacek RR. Histochemical characteristics of muscle fiber types in the posterior cricoarytenoid muscle. Ann Otol Rhinol Laryngol 1981;90:423-9.

10. Rosenfeld DB, Miller RH, Sessions RB, Patten BM. Morphologic and histochemical characteristics of laryngeal muscle. Arch Otolaryngol 1982;108:662-6.

11. Lucas CA, Rughani A, Hoh JFY. Expression of extraocular myosin heavy chain in rabbit laryngeal muscle. J Muscle Res Cell Motil 1995;16:368-78.

12. Merati AL, Bodine SC, Bennett T, Jung HH, Furuta H, Ryan AF. Identification of a novel myosin heavy chain gene expressed in the rat larynx. Biochim Biophys Acta 1996;1306: 153-9.

13. Jones RM, Soliman AMS, Flint PW. Neuroanatomic study of rat laryngeal embryogenesis [Abstract]. Otolaryngol Head Neck Surg 1995;113(2):129.

14. Soliman AMS, Jones RM, Flint PW. Cell adhesion molecules in normal laryngeal development. Otolaryngol Head Neck Surg 1999;120:73-7.

15. Laemmli UK. Cleavage of structural protein during the assembly of the head of bacteriophage T4. Nature 1970;227: 680-5.

16. Talmadge RJ, Roy RR. Electrophoretic separation of rat skeletal muscle myosin heavy-chain isoforms. J Appl Physiol 1993;75:2337-40.

17. Sugiura T, Murakami M. Separation of myosin heavy chain isoforms in rat skeletal muscles by gradient sodium dodecyl sulfate–polyacrylamide gel electrophoresis. Biomed Res 1990;11:87-91.

18. Cho M, Hughes SM, Karsch-Mizrachi I, Travis M, Leinwand LA, Blau HM. Fast myosin heavy chain expressed in secondary mammalian muscle fibers at the time of their inception. J Cell Sci 1994;107:2361-71.

19. Webster C, Silverstein L, Hays AP, Blau HM. Fast muscle fibers are preferentially affected in Duchenne muscular dystrophy. Cell 1988;52:503-13.

20. Hughes SM, Blau HM. Muscle fiber pattern is independent of cell lineage in postnatal rodent development. Cell 1992; 68:659-71.

21. Cho M, Webster SG, Blau HM. Evidence for extrinsic regulation of slow myosin heavy chain expression during muscle fiber development. J Cell Biol 1993;121:795-810.

22. Hughes SM, Cho M, Karsch-Mizrachi I, et al. Three slow myosin heavy chains sequentially expressed in developing mammalian skeletal muscle. Dev Biol 1993;158:183-99.

23. Schiaffino S, Gorza L, Sartore S, et al. Three myosin heavy chain isoforms in type 2 skeletal muscle fibers. J Muscle Res Cell Motil 1989;10:197-205.

24. Termin A, Staron RS, Pette D. Myosin heavy chain isoforms in histochemically defined fiber types of rat muscle. Histochemistry 1989;92:453-7.

25. LaFramboise WA, Daood MJ, Guthrie RD, et al. Emergence of the mature myosin phenotype in the rat diaphragm muscle. Dev Biol 1991;144:1-15.

26. Brozanski BS, Daood MJ, Watchko JF, LaFramboise WA, Guthrie RD. Postnatal expression of myosin isoforms in the genioglossus and diaphragm muscles. Pediatr Pulmonol 1993; 15:212-9.

27. Rossini K, Rizzi C, Sandri M, Bruson A, Carraro U. High-resolution sodium dodecyl sulfate–polyacrylamide gel electrophoresis and immunochemical identification of the 2X and embryonic myosin heavy chain in complex mixtures of isomyosins. Electrophoresis 1995;16:101-4.

28. Nemeth P, Pette D. Succinate dehydrogenase activity in fibres classified by myosin ATPase in three hind limb muscles of rat. J Physiol (Lond) 1981;320:73-81.

29. Larsson L, Edstrom L, Lindegren B, Gorza L, Schiaffino S. MHC composition and enzyme-histochemical and physiological properties of a novel fast-twitch motor unit type. Am J Physiol 1991;261:C93-C101.

30. Hast MH. The primate larynx. A comparative physiological study of intrinsic muscles. Acta Otolaryngol (Stockh) 1969; 67:84-92.

31. Hirose H, Ushijima T, Kobayashi T, Sawashima M. An experimental study of the contraction properties of the laryngeal muscles in cat. Ann Otol Rhinol Laryngol 1969;78:297-306.

32. Martensson A, Skoglund CR. Contraction properties of intrinsic laryngeal muscles. Acta Physiol Scand 1964;60:318-36.

33. Hall-Caggs EC. The contraction time and enzyme activity of two rabbit laryngeal muscles. J Anat 1968;102:241-5.

34. Hoh JF, Hughes S. Expression of superfast myosin in aneural regenerates of cat jaw. Muscle Nerve 1991;14:316-25.

35. Butler-Browne GS, Whalen RG. Myosin isozyme transitions occurring during the postnatal development of the rat soleus muscle. Dev Biol 1984;102:324-34.

36. Schafer DA, Miller JB, Stockdale FE. Cell diversification within the myogenic lineage: in vivo generation of two types of myoblasts from a single myogenic progenitor cell. Cell 1987;48:659-70.

37. LaFramboise WA, Daood MJ, Guthrie RD, Butler-Browne GS, Whalen RG, Ontell M. Myosin isoforms in neonatal rat extensor digitorum longus, diaphragm, and soleus muscle. Am J Physiol 1990;259:L116-L122.

CERVICAL ANATOMY OF PHRENIC NERVE ROOTS IN THE RABBIT

JEAN-PAUL MARIE, MD
YANNICK LEROSEY, MD
DANIÈLE DEHESDIN, MD
MARC TADIÉ, MD, PHD
JÉROME ANDRIEU-GUITRANCOURT, MD
ROUEN, FRANCE

The cervical anatomy of the different nerve contributions that constitute the phrenic nerve (phrenic nerve roots and accessory phrenic nerve) were studied in rabbits. In 55 dissections, 6 main root arrangement types were observed. The roots that issued from the fourth and fifth cervical nerves (C4 and C5 roots) were constant. The C4 root was either short or long. The C6 root was at times absent, or sometimes double. An accessory phrenic nerve was present in 43% of the right and 28% of the left dissections. The distribution of the phrenic nerve roots often displayed left-right asymmetry. We conclude that a better knowledge of the cervical anatomy of the phrenic nerve is useful both in physiological studies involving diaphragm denervation and in experimental laryngeal reinnervation.

KEY WORDS — cervical anatomy, phrenic nerve, rabbit.

INTRODUCTION

The phrenic nerve has previously been used for experimental laryngeal reinnervation.[1-9] The rhythmic inspiratory firing of this nerve makes it ideal for neurotization of the posterior cricoarytenoid (PCA) muscle. In addition to the problem of functional reinnervation of the larynx, hemidiaphragmatic paralysis induced by phrenicotomy prevents routine application of this technique in humans. Interest has been reported in other nerves such as the ansa hypoglossi, the resection of which does not create a severe handicap.[10-12] However, the lack of firing of the ansa during quiet breathing is an obstacle to its application as a source for PCA muscle reinnervation.

In order to use the phrenic nerve as a possible nerve transplant in humans, it would be necessary to preserve functional motoneurons for the hemidiaphragm. One solution might be the use of only some of the roots of the phrenic nerve.[5,7-9] Theoretically, the accessory phrenic nerve (APN) could also be used.

Thus, we undertook a series of animal experiments in order to study the functional consequences of resection of 1 or a few roots of the phrenic nerve,[13,14] and to study the possibility of muscular neurotization using only 1 phrenic nerve root (PNR).[15] Rabbits were chosen for these experiments. Their phrenic nerves are mainly constituted by 3 cervical roots, as is the case in dogs and humans. Rabbits have been extensively used in physiological studies and are not expensive. However, since the anatomic arrangement of the PNRs in the rabbit has been poorly described in the literature, it soon became apparent that it would be necessary to examine these nerves in some detail.

MATERIAL AND METHODS

Forty-nine New Zealand rabbits (Charles River, France) weighing 1,500 to 4,000 g were included in this study. Fifty-five cervical dissections were performed: 37 on the right side and 18 on the left side, of which 6 were bilateral dissections. They were performed either on animals anesthetized with ketamine hydrochloride (12.5 mg/kg) and chlorpromazine hydrochloride (0.625 mg/kg) before resection of the PNRs, or just after sacrifice. The experiments were carried out in accordance with French laws concerning the use of animals in experimental research.

Each animal was supine, with the head and upper limbs extended. After shaving from the submental region to the sternum, a median cervicotomy was performed. Then, the superficial fascia was incised. The sternocephalic muscle was resected, and the sternocleidomastoid muscle was exposed on the back side. The external jugular vein was separated externally, and the anastomosis with the internal jugular vein was coagulated. The neck was exposed downward as far as the clavicle and the pectoral muscles, which were then resected. The phrenic nerve and the PNRs were exposed on the ventral scalene muscles. (The branches from the ventral primary rami of the

From the Department of Otorhinolaryngology and Head and Neck Surgery (Marie, Lerosey, Dehesdin, Andrieu-Guitrancourt) and the Experimental Surgery and Microsurgery Laboratory (Marie, Lerosey, Dehesdin, Tadié), Charles Nicolle Hospital, University of Rouen, Rouen, France, and the European Group for Research on the Larynx (Marie, Dehesdin).

CORRESPONDENCE — Jean-Paul Marie, MD, Service ORL et Chirurgie Cervico-faciale, Centre Hospitalier et Universitaire, 76031 Rouen Cedex, France.

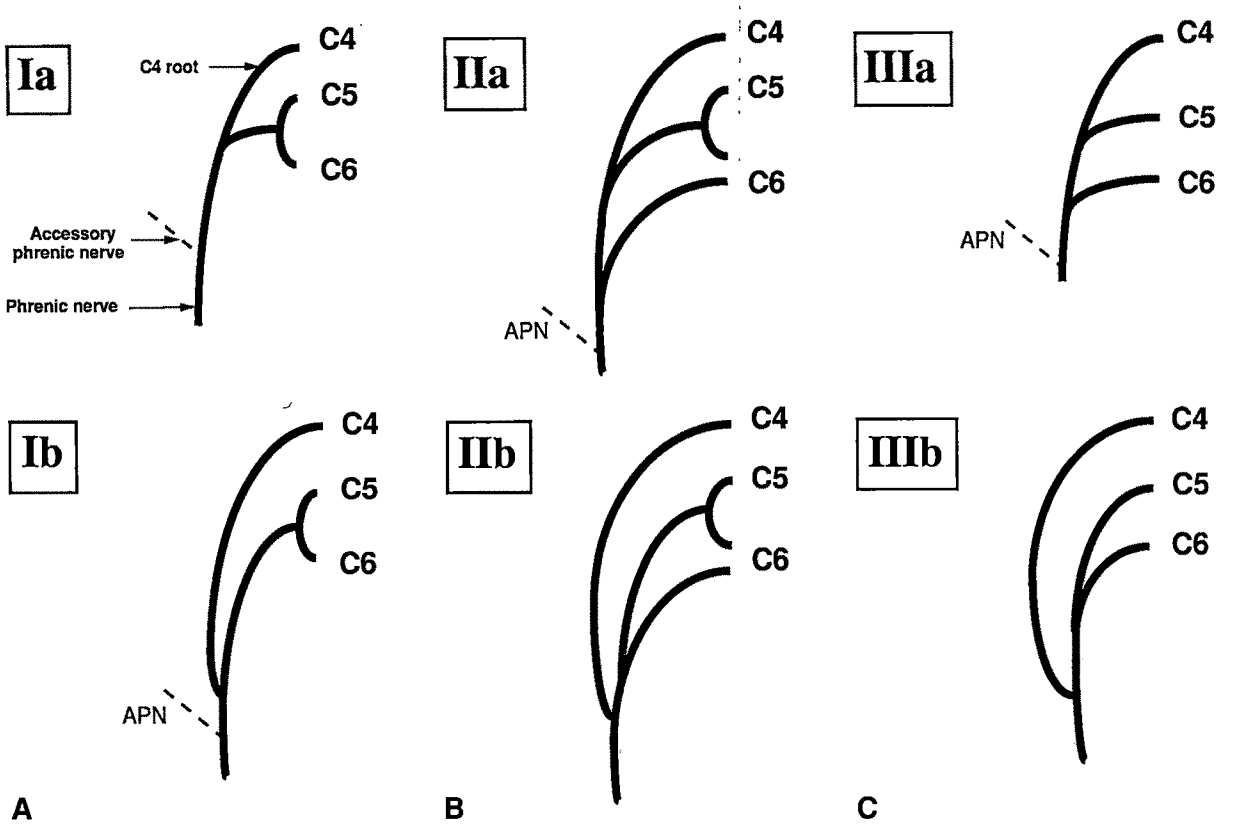

Fig 1. Schematic representation of phrenic nerve root arrangements. Branches issuing from ventral rami of fourth, fifth, and sixth cervical nerves (C4, C5, and C6) are termed phrenic nerve roots. They join to constitute main phrenic nerve. Dotted line is accessory phrenic nerve (APN). See explanation in text. A) Types Ia and Ib are differentiated by length of C4 root. B) Types IIa and IIb. C) Types IIIa and IIIb.

cervical nerves that constitute the phrenic nerve were termed PNRs by analogy to the terminology used for the brachial plexus or the ansa hypoglossi in humans.)

In living animals, identification of the PNR was controlled by the abdominal motion induced by an electric stimulation of 2.5 pulses per second of 0.1-mA intensity (nerve stimulator GN 15, Aesculap, Tuttlingen, Germany). In dead animals, the PNRs were located in a retrograde manner from the phrenic nerve trunk (PNT). Dissection of the different roots was then carried out with the help of an operating microscope (Zeiss, Germany) and microsurgical instruments. The same dissection procedure was performed on the right and left sides.

The following points were investigated: 1) the origin of the PNRs (which ventral primary rami of the cervical nerve), 2) the modalities of anastomosis between PNRs, and 3) the presence (or absence) of an APN. In this study, an APN was defined as a branch of a cervical nerve that, after a common route, joins the main phrenic nerve below the neck or in the upper thorax, at least 1 cm lower than the projection of the sixth cervical nerve or below the level of the clavicle. Therefore, the phrenic nerve was exposed for 3 cm beside the sixth cervical nerve. Statistical analysis was performed with Pearson χ^2 tests.

RESULTS

Six types of PNR arrangements were observed. In type I (Fig 1A), the highest root originated from the fourth cervical nerve (C4). An anastomosis was observed between branches originating from the fifth and sixth cervical nerves (C5 and C6), which join to form a common branch that becomes a root for the phrenic nerve, which then connects to the root issuing from C4, thus constituting the phrenic nerve (Fig 2A). An APN in some cases joined the phrenic nerve about 1 cm or more below the C6 level (Fig 2B).

Depending on the level at which the C4 root joined the C5 root, we distinguished type Ia (Fig 1A), in which the C5 root was joined above the C6 level (short root), and type Ib (Fig 1A), in which the C5 root was below the C6 level (long root). The exact length of the root was not measured.

In type II (Fig 1B), an additional short root issuing from C6 completed the above-mentioned arrangement (type I). Depending on the length of the C4 root, 2 types were observed: type IIa, with a short

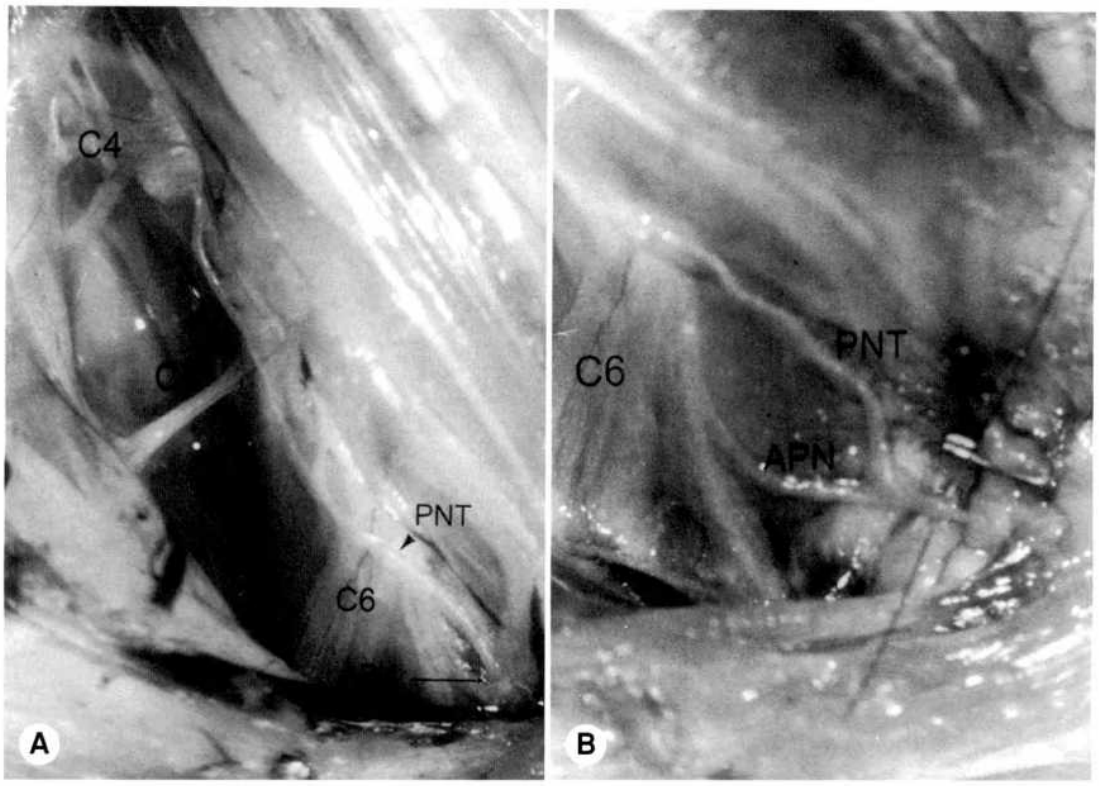

Fig 2. Dissection of right phrenic nerve of type Ia with APN. PNT — phrenic nerve trunk. A) General view. B) Detail.

root, and type IIb, with a long root, joining the phrenic nerve below the root from C6. An APN was also occasionally present.

In type III (Fig 1C), the 3 roots originating from C4, C5, and C6 had longer separate routes, eventually joined by an APN. Depending on the length of the C4 root, 2 types were described: type IIIa, with a short root, and type IIIb, with a long root, joining the phrenic nerve below the roots from C5 and C6.

The Table displays the frequencies (percentages) of the different types of root arrangements and APNs encountered in 55 cervical dissections. Type Ia (Fig 1A) was significantly encountered most frequently, in 51% of the cases on the right side and in 44% of those on the left side; there was no significant difference (NS) between right and left sides. An APN was often found, respectively in 58% and 50% of these cases (NS). Whatever the type of root arrangement encountered, according to the definition mentioned in Material and Methods, the APN was present in 16 of 37 right dissections (43%) and in 5 of 18 left dissections (28%; NS).

On the right side, the APN originated from C6 in 12 of 16 cases (75%), from C7 in 1 case, and from the nerve anastomosis between C6 and C7 (C6-C7) in 1 case. In 2 cases, the real origin was not deter-

DIFFERENT TYPES OF PHRENIC NERVE ROOT ARRANGEMENTS OBSERVED

	Right Side				*Left Side*			
	Total PN Dissections		*Total APNs Present*		*Total PN Dissections*		*Total APNs Present*	
Types of Arrangements	*No.*	*%*	*No.*	*%**	*No.*	*%*	*No.*	*%**
Type Ia	19	51†	11	58	8	44	4	50
Type Ib	4	11	3	75	3	17	0	0
Type IIa	5	14	1	20	3	17	1	33
Type IIb	4	11	0	0	2	11	0	0
Type IIIa	4	11	1	25	0	0	0	0
Type IIIb	1	3	0	0	2	11	0	0
Total	37	100	16	43	18	100	5	28

PN — phrenic nerve, APNs — accessory phrenic nerves.

*Of PN dissections.

†Significantly more frequently found than other types on same side ($p < .05$).

mined. On the left side, the APN originated from C6 in 3 of 5 cases, and from C6-C7 in 1 case. A bilateral cervical dissection was performed in 6 animals, and an identical arrangement of both roots and APNs was found in only 2 cases (33%). However, the number of rabbits was too small to conclude a significant asymmetry.

In right and left dissections, the C4 root was constant on both sides. The C5 root was also constant, either united to the C6 cervical nerve or isolated (types IIIa and IIIb).

The nerve contribution originating from C6 was sometimes absent (types Ia and Ib when the APN was absent): 9 of 37 (24%) on the right side and 7 of 18 (39%) on the left side. The C6 root was sometimes unique (types IIa and IIb; or IIIa and IIIb, when no APN was found): 12 of 37 (32%) on the right side and 6 of 18 (33%) on the left side. In types Ia and Ib, the C6 root was sometimes replaced by the APN if present (14 of 37 on the right side and 4 of 18 on the left side). The C6 contribution was thus unique in 26 of 37 cases (70%) on the right side and 10 of 18 cases on the left side (56%).

The C6 contribution was rarely double (types IIa and IIb; or types IIIa and IIIb, when an APN was present). This occurred in 2 of 37 cases (5%) on the right side and 1 of 18 cases (6%) on the left side.

DISCUSSION

In rabbits, we found that the PNRs are constantly supplied by ventral rami from cervical nerves C4 and C5, or from an anastomosis between C5 and C6; the contribution originating from C6 was not constant, but sometimes double when an APN was present. Three types of root distribution could be described: types I, II, and III. Each type could be divided into 2 groups depending on the length of the C4 root. According to the definition we have used, an APN was found in many cases, originating mostly from C6, sometimes from C6-C7, and rarely from C7; it was present in about half the cases, most frequently in the type Ia root distribution. Although the difference was not significant, an APN was encountered more frequently on the right side than on the left side. Bilateral dissections often showed a lack of symmetry in the arrangement of the PNRs.

The rabbit was chosen because other studies (denervation and reinnervation) have been performed on this common experimental animal. Precise measurements of the PNRs were not made, but we distinguished between long and short roots, and ascertained whether a common branch issued from the roots, bearing in mind the possibility of its use as a nerve transfer.[15] Thoracic dissections and denervation experiments in our laboratory have shown the rarity of thoracic roots of the phrenic nerve. Consequently, the present study was restricted to the investigation of cervical roots of the phrenic nerve.

We labeled as APNs each nerve contribution of the phrenic nerve that had a course different from that of the trunk, that originated from a branch of a cervical nerve after it had followed a common route, that had a point of junction with the phrenic nerve low in the neck or in the thorax, or that was an additional root. This concept is usually applied to a nerve in humans that contributes to the phrenic nerve and originates in the subclavian nerve. However, this point of view is controversial.

In fact, when the APN originates from C6, it could be considered as simply a root for the phrenic nerve (as in type IIa or IIb). The difference is only the length of the root and the length of the cervical nerve before it branches to form the PNR. In type Ia, this nerve branch originated externally and had a long cervical route before joining the trunk; it was termed an APN. In type IIa or IIb, this root was very short and immediately joined the trunk; it was termed the C6 root. Thus, the APN appellation was able to be reserved for an additional root from a cervical nerve. Such additional roots were present in 5% and 6%, respectively, of our right and left dissections, in types IIa and IIIa, coming from C6. Thus, "accessory root" of the phrenic nerve (in contrast to main roots from C4, C5, and C6) would be a better term, as proposed by Rajanna[16] for humans.

The C4 root, when it was long and joined the PNT below C6, could have been considered an APN, as it was called by Rikard-Bell and Bystrzycka.[17] This distribution was encountered in types IIb and IIIb, ie, in 14% on the right side and in 22% on the left side. In these cases, no double root of C6 was encountered. We did not call it an APN because of the constancy of the C4 root, because of its early origin from the C4 nerve, and by analogy with the human terminology. Under this system of classification, it would be better to term as a long root the roots of the phrenic nerve coming either primarily from C6 (right 43%; left 28%) or from C4 (right 14%; left 22%). These long roots are of great surgical interest, because they can be transposed far away in the neck (higher, if it is a long root from C4).

The root arrangement of the phrenic nerve has been poorly investigated in rabbits. Whitehouse and Grove[18] and Barone et al[19] described the phrenic nerve as originating from C4, C5, and C6, without information about the root organization or the APN.

Authors who have studied the intraspinal location of the phrenic nucleus[17,20] described the same root origins, but C4 was not constant, according to Rikard-Bell and Bystrzycka.[17] However, we did not confirm these observations.

The most precise description was carried out by Turner[21] in 1913, who performed bilateral dissection of the PNRs in 33 rabbits: "Different individuals and the two sides of a single animal may vary in the number of phrenic roots and in their place of union. There are usually three roots, one each from the fourth, fifth, and sixth cervical nerves, but there may be two or four. When only two roots were found they were from the fourth and the fifth cervical nerves. The fifth root is often though not always the largest phrenic component. The sixth phrenic root presents the greatest variation as it may be single or double, long or short. When it leaves the sixth cervical nerve a centimeter or more farther out it will be called 'long' because in these cases its course is usually a loop, laterally extended, across the seventh nerve, and its union with the other phrenic roots is far or farther back than the seventh nerve. In some cases both short and long roots were found."[21(p66)] Our findings agree with the observations of Turner. In our study, the long root of C6, when double, was labeled an APN.

In other species and humans, a similar organization can be found. In cats, most authors state that the PNT comes from C5, C6, and C4,[17,20,22] without being precise about the root distribution or APN. In 14 phrenic nerve dissections, Turner[21] found that the root originated from C5 and C6, except in 1 left-sided case with a small root from C4. The union point was not constant; the PNT could have a long route in the cervical area or be only in the thorax.

In dogs, according to most investigations, the roots come from C5, C6, and C7[21,23,24]; the APN, if present, comes from C7.

In humans, the phrenic nerve consistently originates from C4, generally from the C3 and C5 roots. An APN is found in some cases. According to Rajanna,[16] the roots issuing from C3, C4, and C5 are termed main roots, while the APN is defined as coming from the subclavian nerve (the most frequent arrangement). All other roots of the phrenic nerve are called accessory roots of the phrenic nerve. According to Rajanna, in 203 bilateral cervical dissections, the APN was found in 344 cases (85%). If the accessory roots of the phrenic nerve are called APNs, the percentage becomes 88%.[16] This description is equivalent to that of Hovelaque[25] in 1927, in his synthesis of observations of the main previous studies. Thus, in humans as in rabbits, an APN is present in a great number of cases.

Knowledge of PNR arrangements and APN frequency has 2 main applications. First, it has physiological applications: when the effect of a phrenic nerve resection has to be studied, the root arrangement and the presence of an APN must be considered in order to avoid unsuitable partial resection of the phrenic nerve.[21,26] In rabbits, because of the C6 origin of most of the APNs, resection of the C6 cervical nerve combined with that of the PNT would ensure complete denervation of the ipsilateral diaphragm. A better knowledge of the PNR distribution would permit researchers to study the effects of selective phrenic nerve resection on diaphragm innervation and function.[13,14]

Second, this knowledge has a surgical application: the long roots of the phrenic nerve can be transposed to neighboring muscles, ideally to the laryngeal (PCA) muscles, to achieve reinnervation after recurrent laryngeal nerve damage. In the same manner, a branch issuing from the union of 2 roots, if long, could be transposed to distant cervical muscles, keeping the roots (and consequently, the innervation) intact for the diaphragm. This situation was often encountered in our dissections in rabbits. Can these few roots achieve functional reinnervation? This question was addressed in further experimental studies.

ACKNOWLEDGMENTS — The authors thank Marie-France Hellot, PhD, for the statistical analysis and Donald S. Cooper, PhD, for editing the manuscript. The authors also thank Richard Medeiros for editorial advice.

REFERENCES

1. Iwamura S. Functioning remobilization of the paralyzed vocal cord in dogs. Arch Otolaryngol 1974;100:122-9.

2. Crumley RL. Experiments in laryngeal reinnervation. Laryngoscope 1982;92:1-27.

3. Crumley RL. Selective reinnervation of vocal cord adductors in unilateral vocal cord paralysis. Ann Otol Rhinol Laryngol 1984;93:351-6.

4. Baldissera F, Cantaremma G, Marini G. Abduction of the paralyzed vocal cords in the cat using selective laryngeal reinnervation by phrenic motoneurons. Laryngoscope 1986;96: 1399-404.

5. Baldissera F, Cantarella G, Marini G, Ottaviani F, Tredici G. Recovery of inspiratory abduction of the paralyzed vocal cords after bilateral reinnervation of the cricoarytenoid muscles by one single branch of the phrenic nerve. Laryngoscope 1989;99:1286-92.

6. Marie JP, Dehesdin D, Ducastelle T, Senant J. Selective reinnervation of the abductor and adductor muscles of the canine larynx after recurrent nerve paralysis. Ann Otol Rhinol Laryngol 1989;98:530-6.

7. Brondbo K, Hall C, Teig E, Dahl HA. Functional results after experimental reinnervation of the posterior cricoarytenoid

muscle in dogs. J Otolaryngol 1986;15:259-64.

8. Mahieu HF, van Lith-Bijl JT, Groenhout C, Tonnaer JAD, de Wilde P. Selective laryngeal abductor reinnervation in cats using phrenic nerve transfer and ORG 2766. Arch Otolaryngol Head Neck Surg 1993;119:772-6.

9. van Lith-Bijl JT, Stolk RJ, Tonnaer JA, Groenhout C, Konings PN, Mahieu HF. Selective laryngeal reinnervation with separate phrenic and ansa cervicalis nerve transfers. Arch Otolaryngol Head Neck Surg 1997;123:406-11.

10. Tucker HM. Human laryngeal reinnervation: long experience with neuromuscular pedicle technique. Laryngoscope 1978;88:598-604.

11. Rice DH. Laryngeal reinnervation. Laryngoscope 1982; 92:1049-59.

12. Attali JP, Traissac L, Gioux M. Réhabilitation de l'abduction cordale par anastomose nerveuse sélective chez le chien. Rev Laryngol Otol Rhinol (Bord) 1990;11:397-9.

13. Marie JP, Laquerrière A , Lerosey Y, et al. Selective resection of the phrenic nerve roots in rabbits. Part I: Cartography of the residual innervation. Respir Physiol 1997;109:127-38.

14. Marie JP, Tardif C, Lerosey Y, et al. Selective resection of the phrenic nerve roots in rabbits. Part II: Respiratory effects. Respir Physiol 1997;109:139-48.

15. Marie J-P, Lerosey Y, Dehesdin D, Jin O, Tadié M, Andrieu-Guitrancourt J. Experimental reinnervation of a strap muscle with a few roots of the phrenic nerve in rabbits. Ann Otol Rhinol Laryngol (in press).

16. Rajanna MJ. Anatomical and surgical considerations of the phrenic and accessory phrenic nerves. J Int Coll Surg 1947; 10:42-52.

17. Rikard-Bell GC, Bystrzycka EK. Localization of phrenic motor nucleus in the cat and rabbit studied with horseradish peroxidase. Brain Res 1980;194:479-83.

18. Whitehouse RH, Grove AJ. Dissection of the rabbit. London, England: University Tutorial Press, 1967.

19. Barone R, Pavaux C, Blin PC, Cuq P. Atlas of rabbit anatomy. Paris, France: Masson and Cie, 1973.

20. Ullah M. Localization of the phrenic nucleus in the spinal cord of the rabbit. J Anat 1978;125:377-86.

21. Turner AH. Remarks on the origin of the phrenic nerve in the rabbit, cat, and dog. Am J Physiol 1913;32:65-9.

22. Fournier M, Sieck GC. Somatotopy in the segmental innervation of the cat diaphragm. J Appl Physiol 1988;64:291-8.

23. De Troyer A, Kelly S. Chest wall mechanics in dogs with acute diaphragm paralysis. J Appl Physiol 1982;53:373-9.

24. Kelley WO. Phrenic nerve paralysis. Special consideration of the accessory phrenic nerve. J Thorac Surg 1950;19:923-8.

25. Hovelaque A. Anatomie des nerfs craniens et rachidiens et du système grand sympathique chez l'homme. Paris, France: Doin et al, 1927:363-85.

26. Katagiri M, Young RN, Platt R, Kieser TM, Easton P. Respiratory muscle compensation for unilateral or bilateral hemidiaphragm paralysis in awake canines. J Appl Physiol 1994;77:1972-82.

IMAGING CASE STUDY OF THE MONTH
FRONTOETHMOID OSTEOMA

RICHARD H. VOWLES, FRCS (ORL-HNS) NIGEL R. BLEACH, FRCS (OTOL)
SLOUGH, ENGLAND

CASE REPORT

A 69-year-old man was referred from the Department of Ophthalmology with a 6-month history of right-sided epiphora. He had no proptosis, diplopia, or visual disturbance. An ophthalmological examination yielded essentially normal findings, but a firm mass could just be palpated at the right inner canthus. A coronal computed tomography (CT) scan was arranged, and this demonstrated a large bony mass in the medial orbital wall (see Figure, A). The mass was not impinging on the eye, but had displaced the nasolacrimal duct laterally and was obstructing the frontal recess, leading to a secondary mucocele of the right frontal sinus (see Figure, B).The lesion was seen to extend up as far as the cribriform plate, but there was no intracranial component (see Figure, C). A provisional diagnosis was made of frontoethmoid osteoma.

After discussion, the patient decided to have the lesion removed surgically. The lesion was approached via a right-sided Lynch-Howarth incision. Careful exposure and appropriate osteotomies allowed the osteoma to be mobilized gently and removed as a complete specimen, which was subjected to histologic evaluation. The frontal sinus was opened during the procedure, releasing copious quantities of retained inspissated pus. (Microbiological examination revealed this to be sterile.) Internal examination of the frontal sinus also demonstrated it to be considerably expanded in size. After the tumor was removed, the remaining large bony defect was thought to provide adequate access to and drainage of the frontal sinus. The cavity was packed with 2.5-cm ribbon gauze impregnated with Whitehead's varnish, which was removed at 2 weeks postoperatively, revealing a healthy, well-healed frontal sinus cavity.

Histologically, the lesion was found to be a typical benign osteoma.

DISCUSSION

Osteomas are thought to be the commonest benign tumors of the facial bones, with the frontal sinus being the site most frequently affected.[1] Forty-eight percent of sinus osteomas are located here, and of these, 37% are found around the frontal sinus ostium.[2] The true incidence cannot be quoted, as many osteomas remain asymptomatic and therefore escape detection,[3,4] but it was estimated to be as high as 0.43% in a review of 3,510 sinus radiographs.[5]

Osteomas may present at any age, having been reported in patients less than 10 years old, but most are diagnosed in the fifth and sixth decades. Males appear to be affected marginally more often than females, with ratios varying from 1.3:1[2] to 3:1.[6] The cause is uncertain, and there are 3 conflicting theories: traumatic, infective, and embryonic. There may be a history of facial trauma, although no direct causal relationship has been established, and in many cases no relevant history is evident. There is also no evidence to link osteoma formation with chronic sinusitis, although some believe that chronic inflammation may stimulate osteoblastic activity; it would seem far more likely that chronic infection is secondary to an obstructed sinus ostium. The developmental theory is lent weight by the observation that many osteomas arise from the frontoethmoid suture line, an area in which membranous and cartilaginous structures abut in early life. Against this argument is the fact that many osteomas do not arise at such embryonic junctions.[7,8]

There is a known association between multiple osteomas and intestinal polyps, fibromas, lipomas, neurofibromas, epidermoid cysts, abnormal teeth, and pigmented skin lesions (Gardner's syndrome, an autosomal dominant condition with variable penetrance).[9] The presence of these sequelae should be sought in all patients with sinus osteomas.

The mode of presentation of these lesions depends largely on the site of origin. Most commonly (70%), they present with the symptoms of frontal sinusitis, with frontal headaches and mucopurulent rhinor-

From the Department of Otolaryngology–Head and Neck Surgery, Wexham Park Hospital, Slough, England.
CORRESPONDENCE — Richard H. Vowles, FRCS (ORL-HNS), 86 Cathles Rd, London SW12 9LG, England.

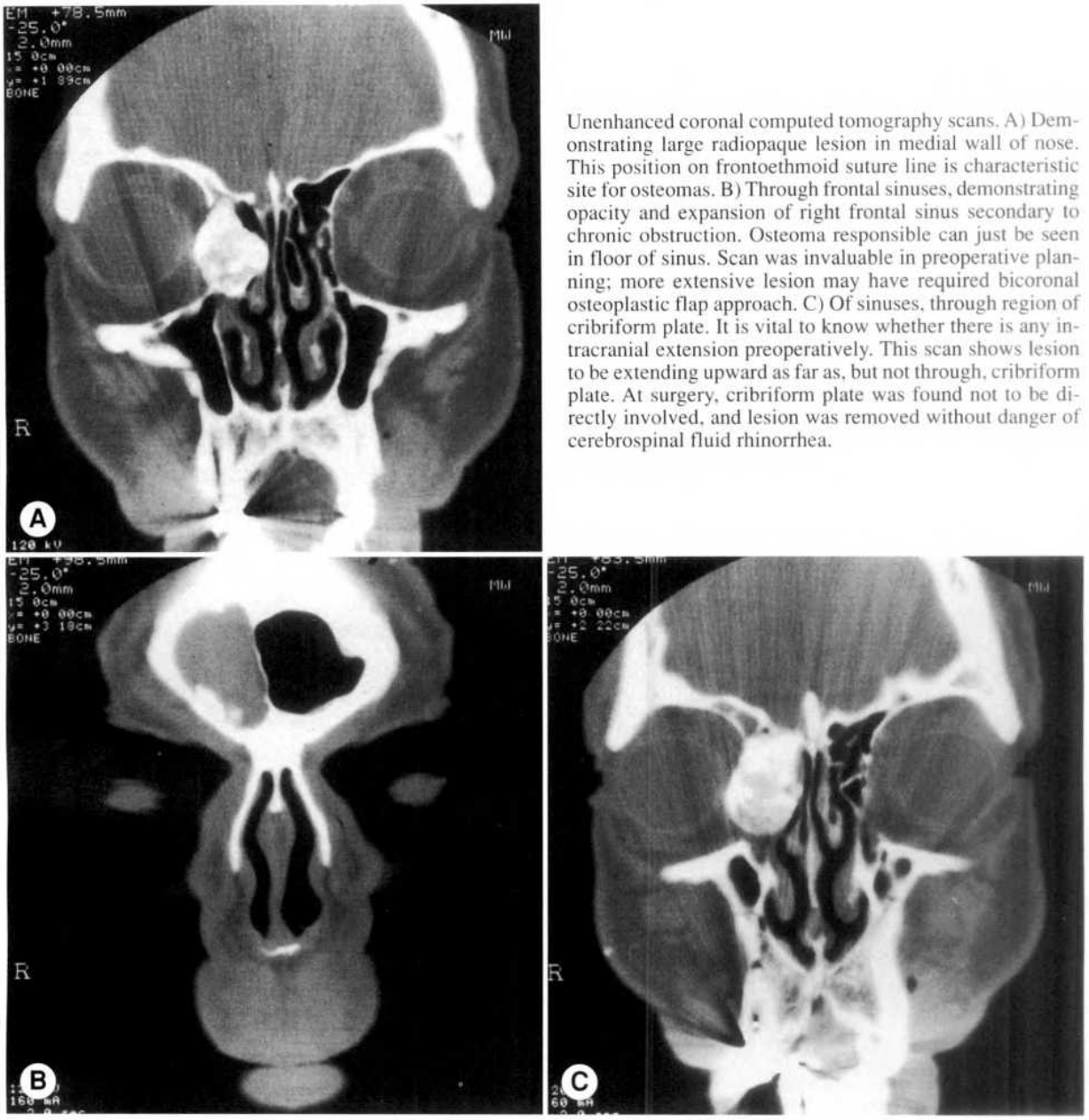

Unenhanced coronal computed tomography scans. A) Demonstrating large radiopaque lesion in medial wall of nose. This position on frontoethmoid suture line is characteristic site for osteomas. B) Through frontal sinuses, demonstrating opacity and expansion of right frontal sinus secondary to chronic obstruction. Osteoma responsible can just be seen in floor of sinus. Scan was invaluable in preoperative planning; more extensive lesion may have required bicoronal osteoplastic flap approach. C) Of sinuses, through region of cribriform plate. It is vital to know whether there is any intracranial extension preoperatively. This scan shows lesion to be extending upward as far as, but not through, cribriform plate. At surgery, cribriform plate was found not to be directly involved, and lesion was removed without danger of cerebrospinal fluid rhinorrhea.

rhea.[4] There are numerous case reports of osteomas extending beyond the confines of the sinuses and causing serious intracranial complications such as meningitis, brain abscesses, and intracranial mucoceles.[6,10-13] Ophthalmic symptoms arise only rarely, despite tumor extending into the orbit in one third of cases. Reported ophthalmic symptoms include proptosis, diplopia, and ptosis, although there are reports of visual loss and, as in our case, epiphora.[7]

The diagnosis is usually made radiologically, but the differential diagnosis includes osteosarcoma, osteoblastic metastases, Paget's disease, osteoid osteoma, ossifying fibroma, calcifying meningioma, and fibrous dysplasia.[11]

The imaging modality of choice is CT scanning. Although osteomas may be detected on some plain x-rays or tomograms, such films do not give sufficient detail for accurate assessment and confident, safe surgical intervention. Similarly, magnetic resonance scanning gives very inadequate bony delineation and may also be misleading when assessing the presence or absence of frontal mucoceles.[11,12]

Bone scanning using technetium-99 may have a minor role to play in the assessment of these lesions. Noyek et al[14] suggested that those with "hot" scans (representing bone with high metabolic activity) should be monitored more carefully. Bone scanning may therefore give useful prognostic information and may be of value in deciding whether to treat surgically or to manage conservatively with serial scan-

ning.

Radiologically, osteomas show 5 distinct appearances:

1. Uniformly sclerotic. The most common type, with bone density similar to that of cortical bone.
2. Target-like. Dense peripheral shell with a more radiolucent center.
3. Partially corticated shell with heterogeneous matrix, more common in the larger lesions.
4. Heterogeneous, without any shell.
5. Laminated, resembling calculi.

Osteomas appear to be slow-growing, exerting their effects by local pressure. There does not appear to be any danger of malignant transformation. Controversy exists regarding whether to excise the tumors surgically. It has been suggested that sinus osteomas should be monitored radiologically unless they cause unacceptable symptoms, are located near the natural ostium of the frontal sinus, occupy more than 50% of the frontal sinus, extend beyond the confines of the frontal and ethmoid sinuses, or are obviously enlarging radiologically.[15]

Surgical approaches vary according to the site and size of the tumor. If there is any intracranial extension, a full craniofacial excision with en bloc resection of the ethmoid labyrinth should be undertaken.[5,16] This carries the added advantage, in larger tumors, of allowing the harvesting of calvarial bone, which is then fixed in place with a microsystem to reconstruct any ensuing deformity.[16]

Tumors limited to the anterior wall of the sinus may be tackled endoscopically. The technique used is via an external incision, as would be adopted for an endoscopic face-lift.[17,18] There are no reports of endonasal excision of frontal osteomas.

Our case was really too large for us to contemplate endoscopic resection, despite considerable endoscopic experience on the part of the surgical team. The tumor was felt to be too close to the cribriform plate for the procedure to be carried out safely (see Figure, C).

Whether to obliterate the frontal sinus remains controversial. For larger tumors requiring a craniofacial approach, it would appear impossible not to,[5] but with smaller lesions such as ours, especially if an endoscopic approach has been employed, obliteration would seem unnecessary, although fenestration of the frontal intersinus septum would seem a sensible precaution.

REFERENCES

1. Handousa AS. Nasal osteomata. J Laryngol Otol 1940;55: 197-224.
2. Earwaker J. Paranasal sinus osteomas: a review of 46 cases. Skeletal Radiol 1993;22:417-23.
3. Harrison DFN, Lund VJ. Tumours of the upper jaw. Edinburgh, Scotland: Churchill Livingstone, 1993.
4. Atallah N, Jay MM. Osteomas of the paranasal sinuses. J Laryngol Otol 1981;95:291-304.
5. Chang SC-N, Chen PK-T, Chen Y-R, Chang C-N. Treatment of frontal sinus osteoma using a craniofacial approach. Ann Plast Surg 1997;38:455-9.
6. Rappaport JM, Attia EL. Pneumocephalus in frontal sinus osteoma: a case report. J Otolaryngol 1994;23:430-6.
7. Wilkes SR, Trautmann JC, DeSanto LW, Campbell RJ. Osteoma: an unusual cause of amaurosis fugax. Mayo Clin Proc 1979;54:258-62.
8. Ataman M, Ayas K, Gursel B. Giant osteoma of the frontal sinus. Rhinology 1993;31:185-7.
9. Gardner EJ, Plenk HG. Hereditary pattern for multiple osteomas in a family group. Am J Hum Genet 1952;4:31-5.
10. Holness RO, Attia E. Osteoma of the frontoethmoidal sinus with secondary brain abscess and intracranial mucocele: case report. Neurosurgery 1994;35:796-7.
11. Shady JA, Bland LI, Kazee AM, Pilcher WH. Osteoma of the frontoethmoidal sinus with secondary brain abscess and intracranial mucocele: case report. Neurosurgery 1994;34:920-3.
12. Brunori A, Bruni P, Delitala A, Greco R, Chiappetta F. Frontoethmoid osteoma complicated by intracranial mucocele and hypertensive pneumocephalus: case report. Neurosurgery 1995;36:1237-8.
13. Lunardi P, Missori P, Di Lorenzo N, Fortuna A. Giant intracranial mucocele secondary to osteoma of the frontal sinuses: report of two cases and review of the literature. Surg Neurol 1993;39:46-8.
14. Noyek AM, Chapnik JS, Kirsch JC. Radionuclide bone scan in frontal sinus osteoma. Aust NZ J Surg 1989;59:127-32.
15. Savic DLJ, Djeric DR. Indications for the surgical treatment of osteomas of the frontal and ethmoidal sinuses. Clin Otolaryngol 1990;15:397-404.
16. Clauser L, Meneghini F, Curri D. Osteoma of the frontoethmoidal sinuses: craniofacial resection and reconstructive strategy. J Craniofac Surg 1991;2:75-81.
17. Bracaglia R, Fortunato R, Marando A, Farallo E. Frontal exostose resection during endoscopic subperiosteal lifting: case report. Aesthetic Plast Surg 1997;21:122-4.
18. Onishi K, Maruyama Y, Sawaizumi M. Endoscopic excision of forehead osteoma. J Craniofac Surg 1995;6:516-8.

AUDITORY SCREENING IN NEONATES BY MEANS OF TRANSIENT EVOKED OTOACOUSTIC EMISSIONS: A REPORT OF 2,842 RECORDINGS

DIDIER AIDAN, MD
PARIS, FRANCE

PAUL AVAN, MD, PHD
CLERMONT-FERRAND, FRANCE

PIERRE BONFILS, MD, PHD
PARIS, FRANCE

The principal goal of an early identification program is to identify hearing impairment present at birth, in order to effect appropriate intervention as early as possible. Although recent research provides some evidence for the value of transient evoked otoacoustic emissions (TEOAEs) in neonate hearing screening, data are needed from large-scale clinical evaluations about the value of using TEOAEs for screening not only high-risk but also healthy neonates. A cohort of 1,421 neonates (2,842 ears) from the well-baby nursery was screened with TEOAEs in a 2-stage process. Neonates were referred from the first test prior to being discharged from the hospital. Those who failed were rescreened before the end of the first month. Those who did not pass the second-stage TEOAE screening were referred for diagnostic audiological evaluation for confirmation of hearing loss. Neonates transferred to a neonatal intensive care unit were not included in this study. Two neonates with bilateral sensorineural hearing loss of >40 dB hearing level were identified from this cohort. This study demonstrates the feasibility and the limitations of using TEOAEs as a universal hearing screening tool for all neonates. It confirms that the prevalence of hearing impairment in neonates has to be taken into account, even in a group of children without high-risk criteria. In France, a prevalence of 1.4 per 1,000 would represent 1,000 deaf children born every year, with reference to about 700,000 births per year. This study suggests that such universal screening programs would substantially increase the rate of early-identified infants with significant hearing impairment.

KEY WORDS — audition, cochlea, hearing screening, neonate, transient evoked otoacoustic emissions.

INTRODUCTION

The prevalence of bilateral sensorineural hearing loss (SNHL) in neonates has been estimated to be between 1 and 2 children per 1,000.[1] Moderate to profound hearing impairment is a significant health problem that occurs more frequently than other diseases such as phenylketonuria (0.07 in 1,000) or congenital hypothyroidism (0.17 in 1,000),[2] for which universal neonatal screenings have been implemented for years. The mean age for the confirmation of suspected hearing loss is around 3 years in Europe and the United States.[1] The result is that for many hearing-impaired children, much of the crucial period for language and speech learning is wasted. For all these reasons, the Joint Committee on Infant Screening issued a position recommending a universal auditory screening to be implemented for all infants within the first 3 months of life.[1] For the past 40 years, infant hearing screening has been attempted with a number of different psychoacoustic methods. In the last 15 years, auditory brain stem response (ABR) testing has been considered the most objective screening technique. Transient evoked otoacoustic emissions (TEOAEs) represent a recently developed method that could be applied to all newborns prior to hospital discharge. The Joint Committee on Infant Screening proposed that screening begin with a TEOAE test.[1] The purposes of the present study were to evaluate whether TEOAE recordings could be used accurately as a universal hearing screening tool for every newborn and to estimate the prevalence of neonatal SNHL.

MATERIALS AND METHODS

Materials. The sample was composed of 1,727 neonates born between October 1995 and March 1997 in the hospital nursery. The mean duration of hospitalization was 3 days. Recordings were made systematically for all neonates, without specially accounting for the presence of SNHL risk factors. However, 3 groups of neonates were excluded from the study because they could not be tested before being discharged from the hospital: 1) 81 neonates (4.7%) were transferred on day 1 after birth to a neonatal intensive care unit (NICU) in another hospital; 2) 173 infants (10%) born on a Friday or Saturday were discharged from the hospital on the next Monday morning, before screening could be done; and 3) 52 neonates (3%) could not be tested for various practical reasons (eg, parents' refusal, omission without

From the Auditory Research Laboratory (CNRS, UMR "Neurobiologie des Systèmes Sensorimoteurs" and Formation Associée Claude Bernard), Université René Descartes, Faculté Necker-Enfants Malades, Hôpital Boucicaut, Hôpital Europeen Georges Pompidou, Paris (Aidan, Bonfils), and the Biophysics Laboratory, Faculty of Medicine, University of Auvergne, Clermont-Ferrand (Avan), France. Support was provided by the Fondation Claude Bernard, the Subvention de Madame Laroche, and the Fondation de l'avenir.

CORRESPONDENCE — Pierre Bonfils, MD, PhD, ENT Department, Hôpital Boucicaut, 78 rue de la Convention, F-75015 Paris, France.

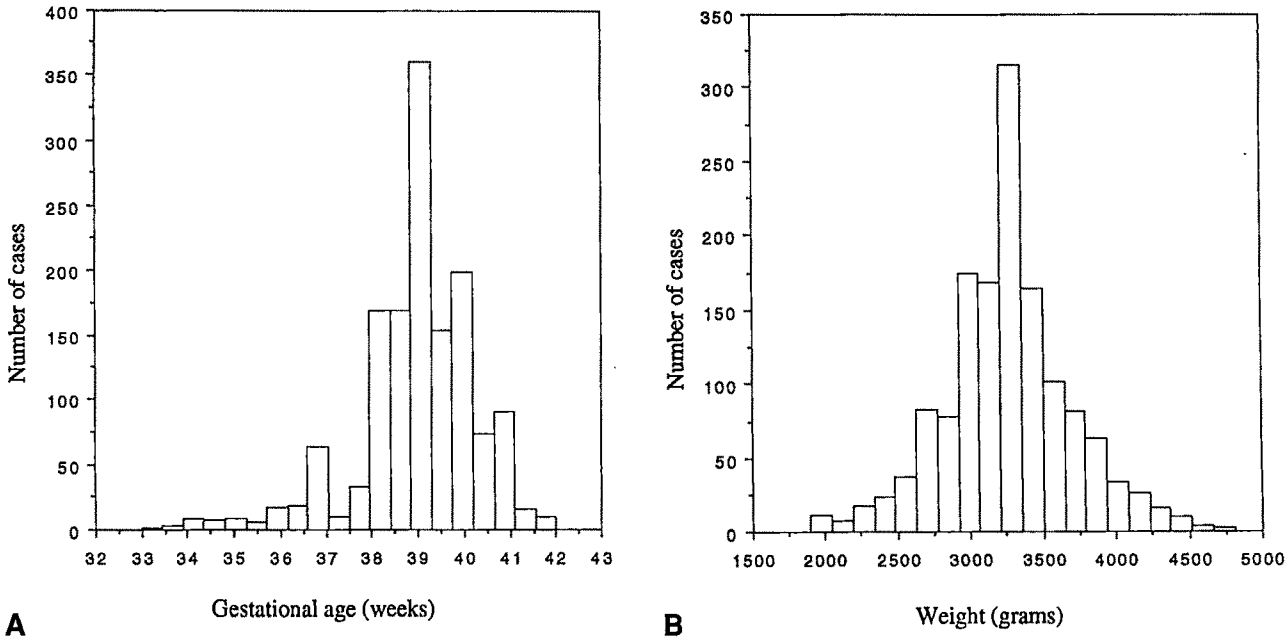

Fig 1. Distributions of A) gestational age (in weeks) and B) birth weight (in grams) in series of 1,421 tested neonates. A) Mean gestational age was 38.9 weeks (SD 1.8). B) Mean birth weight was 3,260 g (SD 482).

any reason). Thus, recordings were available for a sample of 1,421 infants (706 boys and 715 girls). The mean gestational age was 38.9 weeks (standard deviation [SD] 1.8; Fig 1A), the mean birth weight was 3,260 g (SD 482; Fig 1B), and the mean Apgar score at 3 minutes was 9.9 (SD 0.5).

Methods. Neonates were screened for TEOAEs by means of the ILO92 Otodynamic Analyzer (Otodynamics Ltd).[3] The probe design, signal processing, and technical procedures have been described elsewhere.[3] Stimuli were clicks with a flat acoustic spectrum for frequencies between 0.5 and 5 kHz. The responses were collected alternately into 2 buffers, A and B, at which point they were averaged 260 times within a time window of 17.5 milliseconds (ms), starting 2.5 ms after the stimulus onset. The stimulus gain was 0 dB (ie, default setting of the ILO92). This stimulus gain corresponds to a mean average per sound pressure level (SPL) of 78 dB (SD 4; Fig 2). The stimulus sequence was a linear pattern.

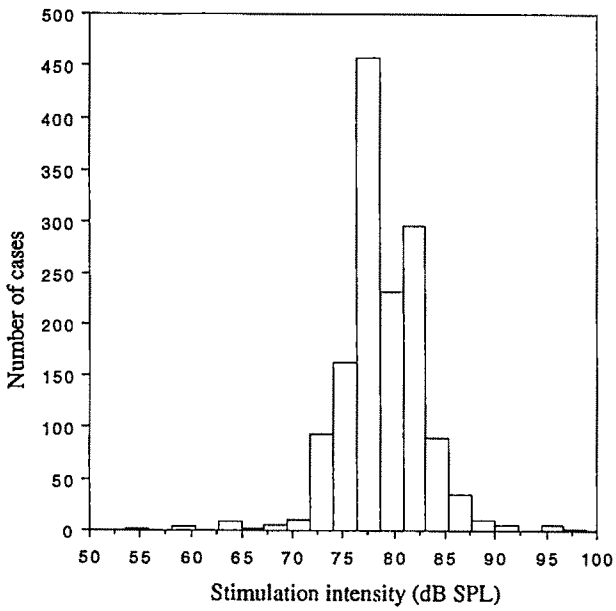

Fig 2. Distribution of stimulation intensity (in decibels sound pressure level [SPL]) of click elicited by ILO92 Otodynamic Analyzer with stimulus gain of 0 dB (ie, default setting of ILO92) in series of 1,421 neonates. Stimulus gain of 0 dB corresponds to mean average per SPL of 78 dB (SD 4).

Recordings were performed at the nursery, in a quiet but not sound-insulated area. Environmental noise levels in the testing room, measured with a Bruël and Kjaër sound level meter, were around 50 dB SPL. Neonates were tested while they were naturally asleep. An appropriate-size neonate probe was placed in the external ear canal. All screenings were done every afternoon from Monday to Friday. No test was done on Saturday or Sunday. For this reason, neonates born on a Friday or Saturday and discharged from the hospital on Monday morning could not be tested (ie, 173 neonates). Both ears were tested for every neonate. Recordings were performed 48 hours following birth, because on day 1 the middle ear residual fluid might prevent or hamper the reception of otoacoustic emissions.[3] Results were stored in a personalized file, in which was included administrative, obstetric, and perinatal information (in particular, that pertaining to SNHL risk factors).

Results of the TEOAE screening were scored as

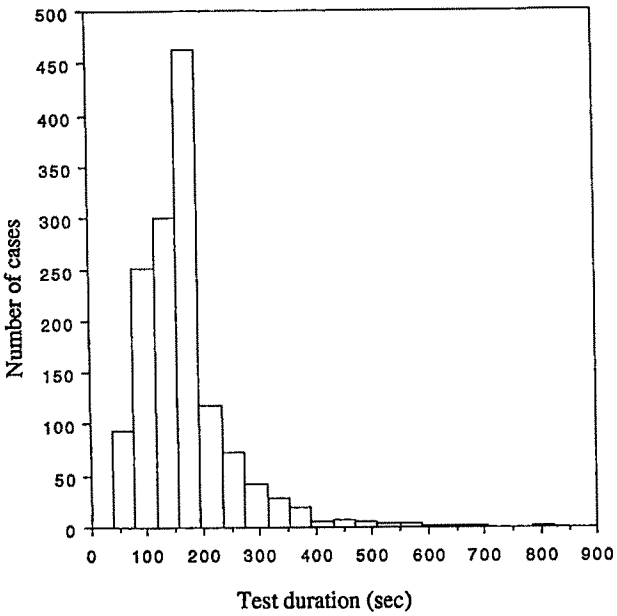

Fig 3. Distribution of time (in seconds) necessary to record TEOAEs in both ears of each neonate in clinical conditions in series of 1,421 tested neonates. Time varied from 50 to 820 seconds. Mean time was 167 seconds (SD 88).

pass or fail. A "pass" was scored (and so the test was considered negative) when 3 criteria were present: 1) an overall magnitude of TEOAE response of >8 dB SPL,[4] 2) a broad spectrum (ie, TEOAEs typically extend from 0.8 to 5 kHz with few deep notches), and 3) a high correlation between the 2 traces of alternate buffers A and B (ie, more than 60%).[3,5] A

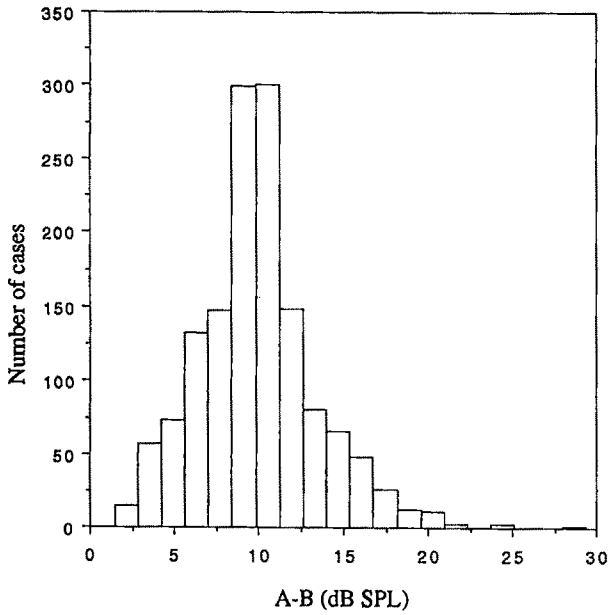

Fig 4. Distribution of A-B (see text) value (in decibels SPL) calculated by ILO92 Otodynamic Analyzer in series of 1,421 neonates tested in clinical conditions. Amplitude appreciates noise floor in external ear canal. This value varied from 2 to 29 dB SPL (mean 9.9 dB SPL; SD 3.9).

PREVALENCE OF RISK FACTORS FOR HEARING IN SERIES OF 1,421 NEONATES

Risk Factor	*Pass*	*Bilateral Fail*	*Unilateral Fail*	*Total*
Family history of deafness	16	2	0	18
Craniofacial deformity	0	0	0	0
Birth weight <1,500 g	0	0	0	0
Prenatal infection	8	0	0	8
Cytomegalovirus	2	0	0	2
Rubella	0	0	0	0
Toxoplasmosis	5	0	0	5
Syphilis	0	0	0	0
Herpes	1	0	0	1
Hypoxemia	42	2	0	44
Neonatal infection	26	2	1	29
Meningitis	0	0	0	0
Hyperbilirubinemia	36	1	0	37
Total	128	7	1	136
Admission to neonatal intensive care unit	0	0	0	81

"fail" was scored when at least 1 of those criteria was not met, and the test was considered positive. In these cases, neonates were referred for a second test before the end of the first month after birth. Those who failed the second test were referred for a diagnostic audiological evaluation in a pediatric otolaryngology center.

RESULTS

Technical Considerations. The duration of each TEOAE recording session was about 1 hour and permitted recording TEOAEs for 5 neonates. This time included 1) the time of TEOAE recordings, 2) the time necessary to bring the neonate to a testing room adjacent to the nursery, and 3) the time needed to explain the screening result to the parents. The mean time of TEOAE recording (ie, the signal averaging) for a neonate was 167 seconds (SD 88) for both ears (Fig 3).

The difference between the 2 traces of alternate buffers A and B (ie, A-B magnitude) was evaluated for each recording. This value provided an estimation of the noise floor in the external ear canal. The mean A-B magnitude was 9.9 dB SPL (SD 3.9; Fig 4). This technical characteristic was not statistically different between the 2 ears.

Neonatal SNHL Risk Factors. One hundred thirty-six neonates (9.6%) exhibited an SNHL risk factor (Joint Committee, 1990; see Table). Hypoxemia was the most common risk factor, observed in 44 neonates. These neonates were not transferred to an NICU. Other common risk factors were hyperbilirubinemia and neonatal infection. Two hundred six

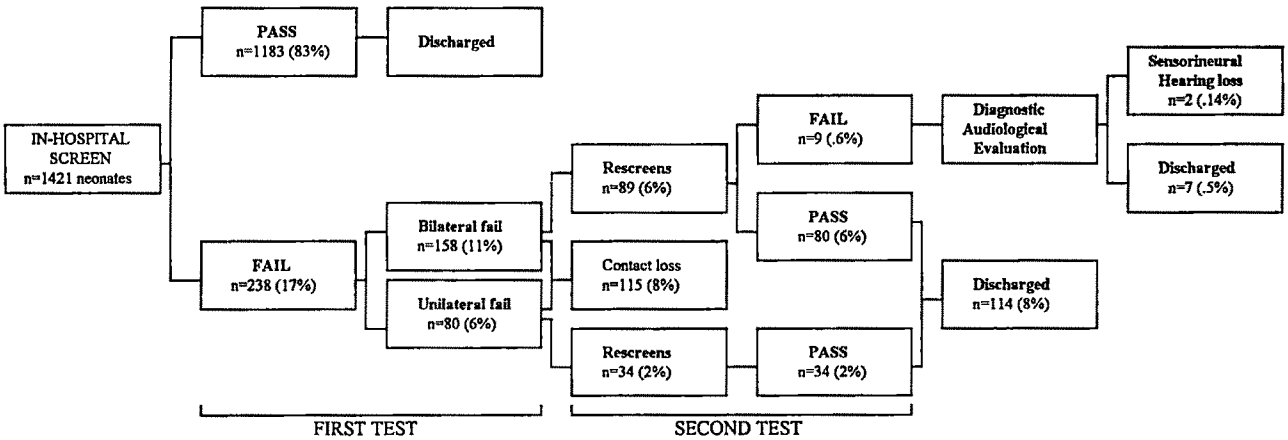

Fig 5. Results of transient evoked otoacoustic emission hearing screening in series of 1,421 tested neonates.

neonates received antibiotic therapy including netilmicin (Netromicin, Schering Plough) with a mean duration of 4.5 days (range 2 to 8 days). This antibiotic therapy was given for either the treatment (29 neonates) or the suspicion (171 neonates) of a perinatal infection. Only 18 neonates had a family history of deafness. Other risk factors were prenatal infections (cytomegalovirus, toxoplasmosis, or herpes).

Analysis of Series. This series included 1,421 neonates (2,842 ears; Fig 5). In 1,183 neonates (83.25%), the test was considered negative because neonates had bilateral TEOAEs. A "fail" was scored for 238 neonates (16.75%); the test was considered positive because TEOAEs were not normal either in only 1 ear (80 neonates, 5.63%) or in both ears (158 neonates, 11.12%). These neonates were referred for a second test before the end of the first month after birth. In most cases, the second test was scheduled during the first week after discharge.

In the group with unilateral absence of TEOAEs (80 neonates), the family contact was lost for 46 neonates (3.2%), and a second test was realized for 34 neonates (2.4%). For all tested neonates, the second test was negative. In the group with bilateral absence of TEOAEs (158 neonates), the family contact was lost for 69 neonates (4.9%), and 89 neonates (6.3%) received follow-up testing. Of the 89 retested neonates, 80 (5.6%) had satisfactory TEOAEs on the second test and 9 (0.6%) were considered to have positive tests and were referred for a diagnostic audiological evaluation in a pediatric otolaryngology center.

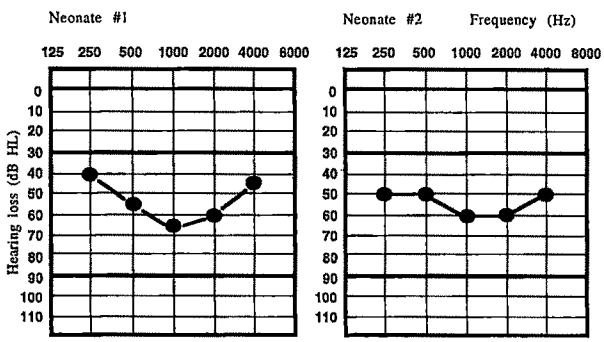

Fig 6. Conditioned orientation reflex audiograms of 2 infants at 10 months, showing bilateral hearing loss of >40 dB hearing level for all conventional audiometric frequencies.

Of the 9 neonates referred for diagnostic audiological evaluation, none exhibited an SNHL risk factor. Seven children were discharged after normal audiological test findings. Two children were recalled for distraction testing, ABR testing, and tympanometry at 6 months of age. Both were found to have a bilateral hearing impairment. The ABR wave V thresholds were 60 dB hearing level (HL) for both ears. Figure 6 shows the conditioned orientation reflex audiograms performed at 10 months (ie, hearing thresholds >40 dB for all conventional audiometric frequencies).

Family Contact Loss After Positive Test. In this series, 238 neonates had either no unilaterally or no bilaterally recordable TEOAEs. We tested 123 neonates (51.7%). The family contact was lost for 115 neonates in spite of multiple attempts at contacting them. The family contact loss represents 57.5% of neonates with a unilateral "fail," and 43.7% of neonates with a bilateral "fail." There was no statistical difference between these 2 populations.

Evaluation of False Positives. Among the 1,421 neonates tested on day 2, 238 neonates (16.75%) were considered positive after the first test. It is difficult to evaluate the number of false positives, because 115 neonates were not retested (ie, family contact loss). Two evaluations of false-positive values can be made: 1) if all non-retested neonates are considered as neonates with SNHL, the false-positive value is 49.16%, and 2) if all non-retested neonates are considered as neonates without SNHL, the false-

positive value is 99.16%.

DISCUSSION

The purposes of this study were 1) to evaluate the feasibility of systematic hearing screening of neonates by TEOAEs and 2) to evaluate neonatal SNHL prevalence with this test.

Analysis of Sample. No infants were deliberately excluded from the study. Yet, the screening was not performed on the whole group. Eighty-one neonates (4.7% of the whole population) requiring an NICU admission at birth were excluded from the study because they were transferred to another hospital. That percentage is 3 times lower than that reported in the survey of White et al,[6] in which 16% of the neonates were admitted into NICUs. It is well recognized that 1% to 4% of NICU neonates have an SNHL,[1,7] because most of them exhibit a neonatal SNHL high-risk factor.[8] So, the exclusion of such a group probably underestimates the neonatal SNHL prevalence in this study.

The population tested in this study included neonates with weights and Apgar scores in agreement with normative data in France. One hundred thirty-six neonates (9.6%) exhibited a neonatal SNHL risk factor. This percentage is consistent with previous evaluations in the literature, in which 7% to 12% of the neonates have high-risk factors.[1,6] Of these 136 neonates, 128 neonates passed the first test and 8 failed. No risk factors were found in the group of neonates who failed the second test, and consequently, none in the 2 neonates identified with an SNHL. These 2 neonates would have been missed if the screening had been performed only on neonates exhibiting neonatal SNHL risk indicators, as in most current screening programs.[9] This observation confirms the importance of the Joint Committee on Infant Screening recommendations, which suggest a universal screening for all neonates within the first 3 months of life.[1]

Analysis of Screening Method. The neonate hearing screening in this study used TEOAEs. As first proposed by Kemp et al,[3] TEOAEs are now widely used as a specific and sensitive noninvasive tool for the diagnosis of inner ear impairment, particularly for evaluation of hearing function in a pediatric population.[10,11] This test is considered the ideal model for the screening of SNHL in neonates according to the Joint Committee recommendations.[1]

So far, there has been no uniformity in the protocols used by different clinicians, and the normative data used for the analysis of TEOAEs vary among different studies. In this study, 3 main criteria were used. First, the TEOAE magnitude recorded in neonates was compared to a reference value, considered as the lower limit between a normal test and a "pathologic" one (ie, 8 dB SPL). Second, TEOAE reproducibility had to exceed 60%. Third, the spectrum, evaluated by its lower and upper limits, had to cover the frequency bands between 0.5 and 5.5 kHz.[4] The magnitude criteria vary in the literature. For example, White et al[6] and Chang et al[12] scored a "pass" when TEOAE magnitude was 3 dB above the noise floor. Our criteria were based on a previous statistical analysis of TEOAE magnitude in normal neonates.[4] The TEOAE reproducibility criteria range from 50%[13,14] to 75%[12] in the literature. The spectrum criteria were used only by Chang et al and White et al.

The stimulus intensity was not modified in this study. In some other studies, recordings were obtained at different stimulus levels to observe the growth of the TEOAE response magnitude.[15] But the growth of the stimulus intensity is judged possibly unsatisfactory by Kemp et al,[3] because of the dependence of this quantity on the instrumental noise floor and doubts about the physiological nature of the detection thresholds for an essentially physical response.[3]

Analysis of Results. Of all tested neonates, 1,183 (83.25%) passed the first test. Chang et al[12] studied a group of 41 full-term newborns, without perinatal disease, with TEOAE recordings. The authors compared the results of the test before and after cleaning the external ear canal. The pre–otoscopic examination TEOAE pass rate of 82 ears was 76%, while the pass rate improved to 91% after external canal debris removal. In the study of Zorowka et al[16] on TEOAE recordings in 2 groups of neonates — 45 healthy newborns and 59 newborns with perinatal infection — an otoscopic examination was performed before each TEOAE test. In the group of healthy newborns, the pass rate was 95.5%. In these 2 series, the small size of the studied cohort permitted a systematic otoscopic examination. On the other hand, in the present study and in that of White et al,[6] the great number of neonates prevented a systematic examination of the ear canal. Consequently, some neonates might have failed at the first stage only because of the presence of external canal debris.

In the series of White et al,[6] 1,850 neonates were screened by TEOAEs: 304 of them were from NICUs and 73% of the neonates had passed the first test. Perhaps the low pass rate was secondary to the percentage of neonates from NICUs. However, the study of Kennedy et al[15] showed pass rates that were not significantly different between normal neonates and NICU neonates.

In the cohort of neonates requiring a second test screen (ie, 238 neonates), 2 groups had to be considered, based on the results of the first test: a bilateral "fail" (n = 158) and a unilateral "fail" (n = 80). This distinction is not always found in others' series. Of the 238 infants referred for the second test, 89 neonates having bilateral failure and 34 having unilateral failure were actually retested, so that 123 neonates (51.7%) requiring a second test were effectively rescreened. The family contact was lost with others (n = 115). In the study of White et al,[6] the family contact loss rate was smaller: 497 neonates required a second test and 403 (81%) were retested. Stevens et al[17] studied 346 neonates screened with TEOAE recordings and ABRs. Neonates were referred for a second test when they failed both tests (ie, 42 neonates). In this group, 64% of the neonates (n = 27) were actually retested. The family contact loss rate in the present study could be explained by the great number of healthy neonates. In these cases, it may be more difficult to convince parents to reply to a second test notification. Further, this study was conducted in a medical hospital without a pediatric unit for the follow-up of neonates. That fact exacerbated loss of contact with the children. In any case, the large family contact loss rate reported in this study may have resulted in an underestimation of the neonatal SNHL prevalence.

A "pass" was scored for 92.7% of neonates retested (114 of 123). This result substantially exceeds the White et al[6] second-test "pass" rate (288 of 403). This high pass rate suggests that some failures on the first test were dependent on factors other than SNHL. The first-stage failure rate could have been influenced by probe fitting problems. Fitting the probe is actually the single most important part of making an acoustic emission measurement. Further, some children were not deeply asleep, and physiologic noise (eg, swallowing movements) could have influenced the TEOAE recordings. Obstructing debris in the external duct, as earlier discussed, can attenuate TEOAE responses. White et al[6] reported 37 neonates identified with a conductive hearing loss in a group of infants referred for diagnostic audiological evaluation. Middle ear dysfunction can indeed confound the interpretation of TEOAEs.[18] Middle ear evaluation by tympanometry prior to screening was not performed in this study, and even though middle ear disorders are not frequent in neonates, this factor could have influenced the results of the screening. However, tympanometry may not be accurate in this population. Gestational age may not have interfered with the first-test "pass" rate, because of the great homogeneity of the study group according to the term (average term 38.9 weeks, SD 1.8), and the small number of preterm infants. Even if some characteristics of the emissions[13] change with increasing postconceptional age (ie, shorter-latency amplitudes increase more than longer-latency amplitudes), there are no statistically significant variations of TEOAE incidence and overall amplitude.[5]

Two neonates were finally identified with bilateral SNHL; therefore, the prevalence of confirmed SNHL in neonates was 1.4 in 1,000. This result is consistent with previous findings. According to the US National Institutes of Health Consensus Statement, approximately 1 of every 1,000 children is born deaf.[1] In other studies, the prevalence is estimated at 0.9 per 1,000,[19] 1 per 1,000,[20] 1.3 per 1,000,[21] and 1.7 per 1,000.[22] In the White et al[6] survey, the prevalence of SNHL in neonates is 5.95 per 1,000. But in the White et al study, the fact that 7 neonates in the group of 11 neonates with confirmed deafness were from an NICU could explain this large difference. In our study, neonates in the NICU were excluded. It is also important to consider the fact that only 51% of the children who failed the first test were retested 1 month later. That means that the prevalence of SNHL was probably underestimated and could have been much higher if NICU neonates had been tested.

CONCLUSION

First, this study demonstrates the feasibility and limitations of using TEOAEs as a universal hearing screening tool for all neonates. Second, it confirms that the prevalence of hearing impairment in neonates has to be taken into account, even in a group of children with few high-risk criteria. In France, a prevalence of 1.4 per 1,000 would represent 1,000 deaf children every year, with reference to about 700,000 births per year. It suggests that such universal screening programs would substantially increase the rate of early-identified infants with significant hearing impairment. Both TEOAEs and ABRs show maximal promise as universal screening tools for the neonate. Each method has its unique advantages and disadvantages. Nevertheless, the use of TEOAEs in the detection of hearing impairment in well babies could be a cost-effective way of detecting early hearing impairments.[1]

REFERENCES

1. Early identification of hearing impairment in infants and young children. NIH Consensus Statement 1993;11:1-24.

2. Batshaw ML, Perret YM. Children with handicaps: a medical primer. Baltimore, Md: Brookes, 1981.

3. Kemp DT, Ryan S, Bray P. A guide to the effective use of otoacoustic emissions. Ear Hear 1990;11:148-54.

4. Aidan D, Lestang P, Avan P, Bonfils P. Characteristics of transient-evoked otoacoustic emissions (TEOEs) in neonates. Acta Otolaryngol (Stockh) 1997;117:25-30.

5. Bonfils P, Francois M, Avan P, Londero A, Trotoux J, Narcy P. Spontaneous and evoked otoacoustic emissions in preterm neonates. Laryngoscope 1992;102:182-6.

6. White KR, Vohr BR, Maxon AB, Behrens TR, McPherson MG, Mauk GW. Screening all newborns for hearing loss using transient evoked otoacoustic emissions. Int J Pediatr Otorhinolaryngol 1994;29:203-17.

7. Sanders R, Durieux-Smith A, Hyde M, Jacobson J, Kileny P, Murnane O. Incidence of hearing loss in high risk and intensive care nursery infants. J Otolaryngol 1994(suppl 14):28-33.

8. Joint Committee on Infant Hearing. Position Statement. ASHA 1991;33(suppl 5):3-6.

9. Blake PE, Hall JE. The status of state-wide policies for neonatal hearing screening. J Am Acad Audiol 1990;1:67-74.

10. Bray P, Kemp D. An advanced cochlear echo technique suitable for infant screening. Br J Audiol 1987;21:191-204.

11. Bonfils P, Dumont A, Marie P, Francois M, Narcy P. Evoked otoacoustic emissions in newborn hearing screening. Laryngoscope 1990;100:186-9.

12. Chang KW, Vohr BR, Norton SJ, Lekas MD. External and middle ear status related to evoked otoacoustic emission in neonates. Arch Otolaryngol Head Neck Surg 1993;119:276-82.

13. Chuang SW, Gerber SE, Thornton ARD. Evoked otoacoustic emissions in preterm infants. Int J Pediatr Otorhinolaryngol 1993;26:39-45.

14. Jacobson JT, Jacobson CA. The effects of noise in transient EOAE newborn hearing screening. Int J Pediatr Otorhinolaryngol 1994;29:235-48.

15. Kennedy CR, Kimm L, Cafarelli Dees D, et al. Otoacoustic emissions and auditory brainstem responses in the newborn. Arch Dis Child 1991;66:1124-9.

16. Zorowka P, Schmitt HJ, Eckel HE, Lippert KL, Schönberger W, Merz E. Serial measurements of transient evoked otoacoustic emissions (TEOAEs) in healthy newborns and in newborns with perinatal infection. Int J Pediatr Otorhinolaryngol 1993;27:245-54.

17. Stevens JC, Webb HD, Hutchinson J, Connell J, Smith MF, Buffins JT. Click evoked otoacoustic emissions compared with brain stem electric response. Arch Dis Child 1989;64:1105-11.

18. Lonsbury-Martin BL, Martin GK, McCoy MJ, Whitehead ML. Otoacoustic emissions testing in young children: middle-ear influences. Am J Otol 1994;15(suppl 1):13-20.

19. Thringer K, Kankkunen A, Linden G, Niklasson A. Perinatal risk factors in the etiology of hearing loss in preschool children. Dev Med Child Neurol 1984;26:799-807.

20. Schein JD, Delk MT. The deaf population of the United States. Washington, DC: National Association of Deaf, 1974.

21. Kankkunen A. Preschool children with impaired hearing in Göteborg. Acta Otolaryngol Suppl (Stockh) 1982(suppl 391).

22. Feinmesser M, Tell L, Levi H. Follow-up of 40,000 infants screened for hearing defect. Audiology 1982;21:197-203.

PERCUTANEOUS IMPLANTS IN THE TEMPORAL BONE FOR SECURING A BONE CONDUCTOR: SURGICAL METHODS AND RESULTS

CATHARINA T. M. VAN DER POUW, MD, PHD
EMMANUEL A. M. MYLANUS, MD, PHD
COR W. R. J. CREMERS, MD, PHD
NIJMEGEN, THE NETHERLANDS

Clinical results of an extended follow-up of percutaneous titanium implants for application of bone conductors are presented. A simplified 1-stage surgical procedure is introduced. This study entails a consecutive series of 163 implants in 155 patients 9 to 80 years old who received a bone conductor coupled to a percutaneous titanium implant since June 1988 at the University Hospital Nijmegen. The maximum follow-up is 7 years. The bone conductor can be connected to a percutaneous abutment fixed to a titanium fixture anchored in the temporal bone. Several clinical trials from different clinics have shown its efficacy in patients with a conductive or mixed hearing loss. In this study attention is paid to the following issues: the occurrence of skin reactions, the condition of the skin around the abutment, the stability of the fixture, and a simplified surgical technique.

KEY WORDS — artificial implants, bone-anchored hearing aid, bone conduction, inflammatory reaction, skin graft, skin penetration, titanium.

INTRODUCTION

The first choice in patients with hearing impairment who require a hearing aid would be an air conduction hearing aid. In some patients, recurrent otorrhea as a result of blocking the auditory canal with the ear-mold and local irritation by the ear-mold present a problem with this type of hearing aid. The external auditory canal can also be lacking. An alternative for these patients is a conventional bone conductor worn as a headband or in the frames of eyeglasses. In a number of cases this device causes problems such as skin irritation, headache due to pressure, inconsistency in the sound quality due to shifting of the transducer over the mastoid, or cosmetic objections. For these patients, the bone conductor can be fixed on a percutaneous coupling that is coupled to an osseointegrated titanium implant in the temporal bone and is an alternative to the conventional bone conductor.[1-3] The surgical procedure in which the titanium implant is fixed was introduced and described in detail by Tjellström.[4] Several studies have been published on the clinical results of percutaneous titanium implants in the temporal bone.[2,3,5-7] Also, subjective results have been obtained, and the new bone conductor is a good alternative to the conventional bone conductor, with all patients using their new bone conductor for more than 8 hours a day.[8] In most of these studies, the fixture or titanium implant and percutaneous abutment or percutaneous coupling were placed in a 2-stage surgical procedure. Promising results in Sweden with a 1-stage surgical procedure in which the fixture and abutment were placed in 1 session prompted us to follow suit. In the 2-stage and 1-stage procedures a free retroauricular skin graft is used in order to establish an area of skin free of hair follicles around the implant.

In this study, a simplified technique that does not involve the use of a skin graft is described. The aim of the study was to assess the condition of the skin around the skin-penetrating abutment and the stability of the fixture in all patients. This simplified surgical technique is here introduced, and the clinical results obtained with this surgical procedure are presented.

PATIENTS AND METHODS

Patients. Inclusion and exclusion criteria used for the selection of the patients have been reported before.[9] The first 157 patients were accepted for implantation between June 1988 and December 1995. Only patients who have had their percutaneous device for 4 months or more are included in this study. In total, 155 patients are included in this study. Two patients received bilateral implants, 4 patients have been reimplanted, and 1 patient has been reimplanted twice, resulting in a total of 163 implants. The follow-up time varies between 8 and 84 months. Two patients have been lost to follow-up, after 2 years and 4.5 years. Eighty-nine of the patients were female and 66 were male. The youngest patient was 9 years old and the oldest patient was 80 years old at the time of the surgical procedure. The mean age

From the Department of Otorhinolaryngology, University Hospital Nijmegen, Nijmegen, the Netherlands.
CORRESPONDENCE — Catharina T. M. van der Pouw, MD, PhD, Dept of Otorhinolaryngology, University Hospital Nijmegen, PO Box 9101, 6500 HB Nijmegen, the Netherlands.

TABLE 1. HISTORY OF 155 TREATED PATIENTS

History	Patients No.	Patients %
Chronic otitis media	132	85
Congenital aural atresia	13	8
Recurrent otitis externa	10	6

was 48 years. Table 1 shows the history of the 155 treated patients. In Table 2 the distribution of the types of hearing aids previously used is presented.

Surgical Technique. In June 1988 the titanium fixture implantation program was started at the Nijmegen University Department of Otorhinolaryngology. All surgical procedures were performed by the senior author (C.W.R.J.C.). After 38 titanium implants were placed in 36 patients with the 2-stage procedure, the 1-stage procedure was used, starting early in 1991. The 1-step surgical technique used in Nijmegen with the use of a free skin graft has been described in detail.[10] Eventually, this procedure was simplified. Instead of using a free skin graft in an area of 2.5 to 3.0 cm around the percutaneous titanium abutment, the subcutaneous tissue, including the hair follicles, is reduced. This surgical procedure takes about 15 to 30 minutes. The present 1-stage procedure technique distinguishes itself from the original one on 3 counts. A purely longitudinal incision of 3 cm is made instead of the circular incision, as the skin graft is no longer used. The periosteum is removed. The tamponade with the healing cap is maintained for about 7 days instead of 14 days. Figure 1A shows the 1-step surgical procedure with the use of a free skin graft. Figure 1B shows the simplified 1-step surgical procedure. Table 3 shows the distribution of surgical procedures of the 163 implants implanted in 155 patients.

TABLE 2. DISTRIBUTION OF TYPES OF PREVIOUS HEARING AID USED AMONG 155 TREATED PATIENTS

Previous Hearing Aid	Patients No.	Patients %
Air conduction	43	28
Bone conduction	111	71.6
No hearing aid	1	0.6

Follow-up. The recovery period after surgery varied between 2 and 3 weeks. Subsequently, the patients were monitored at 4-month intervals. The stability of the fixture in the temporal bone and the fixation of the abutment were checked manually. More frequent observations were made when subjects required care for problems associated with the titanium fixture. Every 4 months the condition of the skin around the implant was observed and recorded. If multiple skin reactions were observed within a follow-up period of 4 months, only the most serious skin reaction type was recorded for that specific period. The classification of soft tissue reactions according to Holgers et al[11] was used (Table 4). Any visible circumstances of the skin around the implant suspected of having a negative influence with regard to the onset of skin reactions were noted separately. These unfavorable circumstances were skin disease, movement of the abutment, and a thick skin or a combination of these 3 circumstances. The treatment of skin reactions consisted of regular cleansing and application of antibiotic ointment. Granulation tissue was excised and a systemic antibiotic was prescribed when necessary.

RESULTS

The total follow-up period of the 163 implants was 4,826 months, including the postoperative recovery

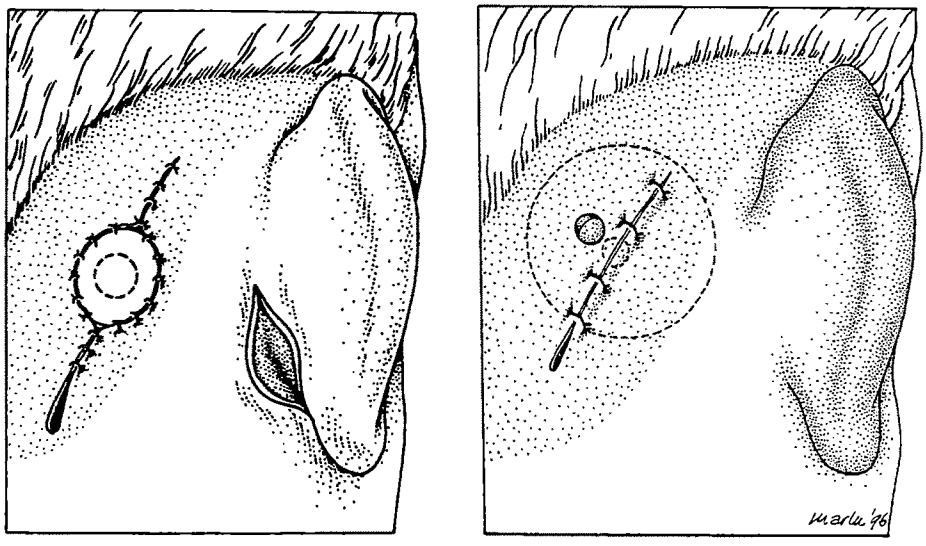

Fig 1. One-stage surgical procedures. A) With transplantation of free thinned skin graft from retroauricular fold. Longitudinal incision of 3 to 4 cm is made over intended implant site. Under free skin graft, fixture is inserted. Caudal end of longitudinal incision is left open to allow wound to drain. Punch is used to puncture graft, and abutment is placed on fixture, which penetrates through skin graft. B) Without transplantation of free thinned skin graft. In area of 2.5 to 3.0 cm around percutaneous titanium abutment, subcutaneous tissue including hair follicles is reduced. Under reduced skin, fixture is inserted. Punch is used to puncture reduced skin, and abutment is placed on fixture.

TABLE 3. DISTRIBUTION OF SURGICAL PROCEDURES OF 163 IMPLANTS IN 155 PATIENTS

	No. of Implants	*%*
Two-stage surgical procedure with skin graft	38	23.3
One-stage surgical procedure with skin graft	93	57.1
One-stage surgical procedure without skin graft	32	19.7
Total 1-stage and 2-stage surgical procedures	163	100.0

period of approximately 1 month. Nine of the 163 implanted fixtures were lost. Necrosis of the skin graft occurred in 1 patient. Table 5 shows the causes of fixture and abutment loss or removal. Of the total of 163 implants, 154 fixtures remained in the skull. This is a success rate of 94.5%. A type 4 skin reaction was observed in 3 instances in 3 implants and led to the loss of the whole implant; 1 of these 3 patients had an extended abstinence from use of the implant. A type 3 skin reaction was observed in 10 instances in 8 implants and required local treatment with an antibiotic ointment. A type 2 skin reaction was observed in 26 instances in 20 implants. In all, 132 (81%) of the 163 implants remained free of potentially dangerous skin reactions (type 2, 3, or 4). In 6 patients out of a total of 26 patients with thick skin around the abutment, a secondary skin reduction was inevitable. In 1 of the 6 patients who underwent secondary skin reduction, the implant had been installed in a 2-stage surgical procedure, and in 5 of the 6 patients, the implants had been installed in 1 session.

The life table method described by Cutler and Ederer[12] was used to calculate the cumulative proportion of implants free of adverse skin reactions (type 1, 2, 3, or 4) throughout the follow-up period. The patients were divided into 3 groups according to the surgical procedure used. The cumulative proportions of the implant groups implanted in the 2-stage surgical procedure, the 1-stage surgical procedure with

TABLE 4. DISTRIBUTION OF TYPES OF SKIN REACTIONS

	Observations	
*Types of Skin Reactions**	*No.*	*%*
0 = No irritation	1,257	91.0
1 = Slight redness	86	6.2
2 = Red and moist tissue	26	1.9
3 = Granulation tissue	10	0.7
4 = Infection leading to removal of abutment	3	0.2
Total No. of observations	1,382	100.0

*According to Holgers et al.[11]

TABLE 5. NUMBER OF REMOVED OR LOST FIXTURES IN 155 IMPLANTED EARS

Causes	*Abutment Removed or Lost*	*Fixture and Abutment Removed or Lost*
Skin reaction (type 4)	3	3
Neuralgia	4	3
Psychological reasons	1	0
Trauma	2	2
No osseointegration	1	1
No hearing improvement	2	0
Total	13	9

the use of a retroauricular skin graft, and the 1-stage surgical procedure without the use of a retroauricular skin graft are presented in Fig 2. The cumulative proportion of implants with intact skin and the number of implants followed (for a given time interval) were used to calculate the effective sample size. The number of implants and the effective sample size of the group of implants placed in 1 stage were tested against any 2 corresponding results for the group of implants placed in a 2-stage operation by comparing the best approximating 2×2 contingency table and applying a χ^2 test at the 5% level. Thus, the results of the 2-stage surgical procedure were compared to those of the 1-stage surgical procedure. Likewise, a comparison was made between the results of using or omitting a skin graft in a 1-stage surgical procedure. No statistically significant differences were found between the data for these implant groups.

Tables 6 and 7 show the distribution of the implant circumstances as noted at outpatient visits. The 163 implants are divided into 2 groups: 1 group with unfavorable circumstances like skin disease (eczema, psoriasis, lichen ruber moniliformis, and severe perspiration), a thick skin permitting movement, or a

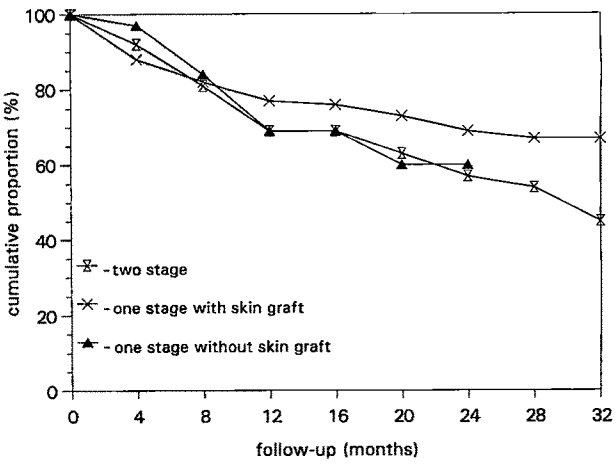

Fig 2. Cumulative proportion of implants that remained free from skin reaction versus follow-up interval.

TABLE 6. FAVORABLE AND UNFAVORABLE CIRCUMSTANCES OF SKIN IN 163 IMPLANTS

Favorable Circumstances of Skin Around Abutment	*Unfavorable Circumstances of Skin Around Abutment*
97 of 163 implants (60%)	66 of 163 implants (40%)
17 of 97 (18%) implants had skin reaction	28 of 66 (42%) implants had skin reaction

loose abutment, and 1 group without these unfavorable circumstances. In 28 of the 66 implants (42%) in the group with unfavorable circumstances, a skin reaction was observed. In the other group, in 17 of the 97 implants (18%) a skin reaction was observed. A statistical significance ($\chi^2 = 10.97$, $p < .05$) was found.

DISCUSSION

Durable fixation of the percutaneous titanium fixture with buildup for connecting a bone conductor is essential to the quality of this new generation of bone conductors. The highest fixation percentages were achieved with implants that were placed in 2 separate sessions.[7,13] However, the results of a single session were statistically similar. So, in experienced hands, it is justified to perform this operation in 1 session.[10] Table 8[5-7,10,14,15] shows that in the literature, the success percentages lie between 90% and 97.9% (loss of fixture 3% to 10%). In the Nijmegen series of patients, 9 of the 163 fixtures have been lost, in different ways (Table 5). Only 1 of the 32 fixtures that were placed in 1 session without preparation of a free skin transplant has been lost. So far, there is reason to have confidence in this simplified surgical technique.

Skin reactions were seen in 125 of the 1,382 observations, so that 91% of the total number of observations remained free from serious skin reactions (types 1, 2, 3, or 4). These findings are in agreement with those of a Swedish study on a total of 1,236 observations. In that study, in 89.1% of the total number of observations, no serious skin reactions were encountered. These implants were placed in 2 surgical sessions.[13] Table 8 shows an overview of several studies that have been performed over the past few years.

TABLE 7. SUBDIVISION OF 66 IMPLANTS WITH UNFAVORABLE SKIN CONDITIONS AND 28 IMPLANTS WITH SKIN REACTION

	No. (n = 66)	*Skin Reaction Type 2, 3, or 4 (n = 28)*
Thick skin	26	7/26 (27%)
Movement of skin around abutment	18	6/18 (33%)
Skin disease	12	8/12 (67%)
Combination of these factors	10	7/10 (70%)

Unfavorable circumstances of the skin around the abutment influence the incidence of skin reactions.[6,11] In 40% of the implants in the Nijmegen series there were unfavorable circumstances in relation to the skin and abutment. This group showed a larger proportion of cases with skin reactions than the group with normal skin conditions (42% versus 18%).

The life table method is a practical instrument that can be used to compare groups of patients or implants with different follow-ups. The cumulative proportions of implants that remained free from skin reactions after the 1-stage procedure with a free skin graft were similar to those found after the 2-stage procedure. In the group of 1-stage procedure implants in implant groups with or without a free skin graft, the cumulative proportions were also comparable. One of the major similarities between the 2 above-described surgical techniques is that an ample quantity of subcutaneous tissue is removed. In our opinion, the simplest way to achieve the greatest amount of reduction is to use a longitudinal incision and omit creating a skin flap. In the literature, various techniques have been described to achieve a hair-free area of skin at the implant site.[16,17] These include the use of a free skin flap, the transposition of skin flaps, a pedicled split skin graft, and a split skin

TABLE 8. COMPARISON OF DIFFERENT STUDIES CONCERNING CLINICAL RESULTS AND SURGICAL PROCEDURES OF BONE-ANCHORED HEARING AID IMPLANTS

Authors	*Year*	*No. of Implants*	*Follow-up (mo)**	*Two-Stage Surgery*	*One-Stage Surgery*	*With Skin Graft*	*Without Skin Graft*	*Loss of Fixture*	*No Skin Reaction†*
Tjellström and Granström[5]	1994	100	(96-192)	100	0	90	10§	10%	?
Mylanus et al[7]	1994	68	22 (8-45)	68	0	68	0	3%	86%
Mylanus and Cremers[10]	1994	33	15 (9-25)	0	33	33	0	6%	79%
Current study		163	29 (8-84)	38	125	131	32	5.5%	81%

Studies of Niparko et al,[6] Somers et al,[14] and Tjellström and Granström[15] are excluded because they also described titanium implants for attaching auricular prostheses.

*Mean; range is in parentheses.

†No skin reactions of type 2, 3, or 4.

§No subcutaneous skin reductions.

graft.[18] Although only short-term results are available, this study shows that the omission of a skin graft produces comparable clinical results. The operation is shortened by 15 to 30 minutes and the procedure is less complicated. Direct postoperative healing seems faster, and fewer outpatient checkups are necessary. Folding the pinna forward, in order to obtain a retroauricular hair-free skin graft, is no longer necessary, and omitting it may prevent an extra skin fold around the abutment. In omitting the free skin graft, there are thus 4 differences from the original 2-stage surgical procedures. (Mylanus and Cremers[10] have previously described 3 of these 4 differences.) The new surgical procedure is efficient and produces favorable results. At present, this surgical procedure takes precedence over the others.

CONCLUSIONS

In this study, the 1-stage surgical procedure without the use of a free skin graft provided good postoperative results, comparable with those from previous studies. The presented simplified implantation technique is a refinement that improves surgical management and postoperative care.

REFERENCES

1. Håkansson B, Tjellström A, Rosenhall U, Carlsson P. The bone anchored hearing aid: principle design and a psychoacoustical evaluation. Acta Otolaryngol (Stockh) 1985;100:229-39.

2. Tjellström A, Lindström J, Hallén O, Albrektsson T, Brånemark P-I. Osseointegrated titanium implants in the temporal bone. A clinical study on bone anchored hearing aids. Am J Otol 1981;2:304-10.

3. Tjellström A, Rosenhall U, Lindström J, Hallén O, Albrektsson T, Brånemark P-I. Five years of experience with skin penetrating bone anchored implants in the temporal bone. Acta Otolaryngol (Stockh) 1983;95:568-75.

4. Tjellström A. Percutaneous implants in clinical practice. CRC Crit Rev Biocompatibility 1985;1:205-28.

5. Tjellström A, Granström G. Long-term follow-up with the bone anchored hearing aid: a review of the first 100 patients between 1977 and 1985. Ear Nose Throat J 1994;73:21-3.

6. Niparko JK, Langman AW, Cutler DS, Carroll WR. Tissue-integrated prostheses in the rehabilitation of auricular defects: results with percutaneous mastoid implants. Am J Otol 1993;14:343-8.

7. Mylanus EAM, Cremers CWRJ, Snik AFM, van den Berge NW. Clinical results of percutaneous implants in the temporal bone. Arch Otolaryngol Head Neck Surg 1994;120:81-5.

8. Mylanus EAM, Snik AFM, Cremers CWRJ. The bone anchored versus the conventional hearing aid. The patients' opinion. Arch Otolaryngol Head Neck Surg 1995;121:421-5.

9. Cremers CWRJ, Snik AFM, Beynon AJ. Hearing with the bone anchored hearing aid (BAHA, HC200) compared to a conventional bone conduction hearing aid. Clin Otolaryngol 1992;17:275-9.

10. Mylanus EAM, Cremers CWRJ. A one-stage surgical procedure for placement of percutaneous implants for the bone-anchored hearing aid. J Laryngol Otol 1994;108:1031-5.

11. Holgers KM, Tjellström A, Bjursten LM, Erlandsson BE. Soft tissue reaction around percutaneous implants: a clinical study of soft tissue conditions around skin-penetrating titanium implants for bone-anchored hearing aids. Am J Otol 1988;9:56-9.

12. Cutler SJ, Ederer F. Maximum utilization of the life table method in analyzing survival. J Chronic Dis 1958;8:699-712.

13. Håkansson B, Lidén G, Tjellström A, et al. Ten years of experience with the Swedish bone-anchored hearing system. Ann Otol Rhinol Laryngol Suppl 1990;99(suppl 151).

14. Somers T, De Cubber J, Daemers K, Govaerts P, Offeciers FE. The bone anchored hearing aid and auricular prosthesis. Acta Otorhinolaryngol 1994;48:343-9.

15. Tjellström A, Granström G. One stage procedure to establish osseointegration: a zero to five years follow-up report. J Laryngol Otol 1995;109:593-8.

16. Proops DW, Wake MJC. A single stage technique for the BAHA [Abstract]. Third International Winter Seminar on Implants in Craniofacial Rehabilitation and Audiology, Selva Val Gardena, 1993:45.

17. Tjellström A. A one or two-stage procedure [Abstract]? First International Winter Seminar on Implants in Craniofacial Rehabilitation and Audiology, Lech am Arlberg, Biomaterials Club, University of Göteborg, Sweden, 1991:36.

18. Proops DW. Methods of management of the soft tissues around the bone anchored hearing aid abutment [Abstract]. 2nd International Symposium on Electronic Implants in Otology and Conventional Hearing Aids, Göteborg, Sweden, 1996:41.

ELECTRON MICROSCOPIC TEMPORAL BONE HISTOPATHOLOGY IN EXPERIMENTAL PNEUMOCOCCAL MENINGITIS

JAMIE M. RAPPAPORT, MD, FRCS(C)
MONTREAL, CANADA

SAMIR M. BHATT, MD
BOSTON, MASSACHUSETTS

ROBERT S. KIMURA, MD
BOSTON, MASSACHUSETTS

ARTHUR M. LAURETANO, MD
BOSTON, MASSACHUSETTS

ROBERT A. LEVINE, MD
BOSTON, MASSACHUSETTS

Bacterial meningitis is one of the most common causes of acquired profound sensorineural deafness in children. Measurement of hearing and examination of the cochlea is limited in patients suffering from acute meningitis. A rabbit model of pneumococcal meningitis was developed to identify the temporal bone histopathologic changes that occur in meningogenic labyrinthitis caused by *Streptococcus pneumoniae*. Light microscopy was previously performed on temporal bones from acutely meningitic rabbits with profound hearing loss as determined electrophysiologically. Extensive inflammation of the cochlea with endolymphatic hydrops was observed. The organ of Corti, however, showed preserved architecture in the majority of these animals. In order to further investigate these findings, a protocol was used to create meningitic rabbits with hearing loss ranging from early high-frequency loss to profound deafness. The temporal bones from 7 rabbits were examined by transmission electron microscopy. In cases of mild hearing loss, partial degeneration of the inner row of outer hair cells, as well as edema of efferent cochlear nerve endings and marginal cells of the stria vascularis, was seen. With increasing degrees of hearing loss, the remainder of the organ of Corti and intermediate cells of the stria showed ultrastructural abnormalities. Spiral ganglion cells and basal cells of the stria vascularis remained intact in all subjects. This study provides unique information regarding the histology and pathophysiology of meningogenic deafness. The clinical implications of these findings are discussed, with an emphasis on potentially reversible changes and therapeutic intervention.

KEY WORDS — electron microscopy, labyrinthitis, pneumococcal meningitis, rabbit, sensorineural hearing loss, temporal bone histopathology.

INTRODUCTION

Bacterial meningitis is a life-threatening infection that affects over 30,000 patients in the United States each year, most of whom are children.[1] Sensorineural hearing loss is a common complication of bacterial meningitis, affecting between 5% and 33% of patients.[1-5] The hearing loss is often severe, making meningitis one of the most common causes of acquired profound sensorineural deafness in children.[2,3] *Streptococcus pneumoniae* is the organism most likely to cause hearing loss as a sequela of meningitis.[3,4]

Current knowledge of the relationship between hearing loss and bacterial meningitis is based primarily on a number of clinical studies.[2-6] Many basic issues regarding the pathogenesis of this hearing loss, however, remain unknown. Further knowledge in this area from human clinical studies will always be difficult because of the impracticalities of frequent hearing measurements in severely ill children. An examination of temporal bone histology in acute meningitis is not possible because, with modern antibiotic regimens, most patients with meningitis survive their infection.

We developed an animal model of hearing loss in pneumococcal meningitis to overcome the weaknesses inherent in clinical studies of this subject and to better understand the pathogenesis of this disease. This model offers the opportunity to closely monitor hearing loss as it develops, and to examine the associated histopathology at any point from early, minimal hearing loss to later, profound deafness.

In previous light microscopy studies,[7,8] it was shown that inflammation began at the cochlear base

From the Department of Otolaryngology, Massachusetts Eye and Ear Infirmary (Rappaport, Bhatt, Kimura, Levine), the Department of Otology and Laryngology, Harvard Medical School (all authors), and the Department of Otolaryngology, Beth Israel Hospital (Lauretano), Boston, Massachusetts. Dr Rappaport was supported by a Killam Post-Graduate Award (Dalhousie University, Halifax, Nova Scotia, Canada), and Dr Bhatt by a grant from the Deafness Research Foundation. This study was performed in accordance with the PHS Policy on Humane Care and Use of Laboratory Animals, the NIH *Guide for the Care and Use of Laboratory Animals*, and the Animal Welfare Act (7 U.S.C. et seq.); the animal use protocol was approved by the Institutional Animal Care and Use Committee (IACUC) of Massachusetts Eye and Ear Infirmary.

Presented at the 19th Midwinter Meeting of the Association for Research in Otolaryngology, St Petersburg Beach, Florida, February 4-8, 1996.

CORRESPONDENCE — Jamie M. Rappaport, MD, FRCS(C), Dept of Otolaryngology, The Sir Mortimer B. Davis–Jewish General Hospital, 3755 Cote Ste Catherine Rd, Montreal, Quebec, Canada H3T 1E2.

HEARING LOSSES AT TIME OF SACRIFICE

Rabbit	Time of Sacrifice (Postinoculation)	Ear	Hearing Loss (dB SPL) 10 kHz	Clicks
1 (control)	2 wk	R	0	0
		L	0	0
2 (control)	2 wk	R	0	0
		L	0	0
3	18 h	R	10	0
		L	10	0
4	18 h	R	10	0
		L	10	0
5	36 h	R	30	30
		L	30	30
6	30 h	R	60	50
		L	50	40
7	60 h	R	NR	NR
		L	NR	NR

NR — no response to maximum stimulus intensity (ie, profoundly deaf).

(near the opening of the cochlear aqueduct), and spread to the apex; this spread paralleled the progression of hearing loss from high to low frequencies seen in these animals. In rabbits with profound hearing loss, acute inflammation was seen throughout the perilymphatic spaces of the labyrinth. In most specimens, the scala media contained an eosinophilic precipitate and areas of fibrin. Polymorphonuclear leukocytes (PMNs) were seen in the scala media only when inflammation in the perilymph was severe. A bulging of Reissner's membrane into the scala vestibuli (ie, endolymphatic hydrops) was seen in all specimens. The average total spiral ganglion cell count in acutely infected rabbits (19,962) was not significantly different from that in normal controls (19,728; W. Hsu, personal communication, 1996).

In most specimens, surprisingly, the organ of Corti appeared normal on light microscopy. In some cases, degenerative changes in hair cells and supporting cells consisting of cytoplasmic swelling and apical migration, pyknosis, or extrusion of nuclei were seen. These changes were always associated with leukocytic infiltration of the scala media.

The protocol described in this paper was developed to examine this phenomenon at an ultrastructural level. The temporal bones of acutely meningitic rabbits with hearing loss ranging from early high-frequency hearing loss to profound deafness were examined by transmission electron microscopy.

MATERIALS AND METHODS

Subjects. Seven female 2-kg New Zealand White rabbits were housed in individual cages in a temperature-controlled light-cycle environment with food and water provided ad libitum. Five animals were randomly selected as the test group, with the remaining 2 used as noninfected controls.

Hearing Assessment. The animals were anesthetized with ketamine hydrochloride (25 mg/kg) and xylazine hydrochloride (6 mg/kg) administered intramuscularly. The scalp was shaved and percutaneous Grass needle electrodes were placed in the midline of the rabbit occiput and snout. Baseline auditory evoked responses (AERs) were then assessed for both ears of all 7 animals as previously described.[7] Tone bursts of 10 kHz were used as narrowband stimuli, and rarefaction clicks were generated as well. The contralateral ear was masked with a broadband noise at 40 dB below the intensity of the ipsilateral stimulus. The stimuli were initially presented approximately 30 dB above the expected threshold and decreased by 10-dB steps. Evoked responses were measured for each stimulus until the largest wave present in the response was no longer visible, and the background noise of the trace was less than 100 nanovolts. Maximum stimulus intensity was 128 dB peak sound pressure level (SPL) for clicks and 82 dB SPL (ungated) for 10-kHz tone bursts. One author (S.M.B.), blinded to the subject and time of measurement, reviewed all AERs for the presence or absence of a response.

Bacterial Inoculation. Streptococcus pneumoniae type III was grown and suspended in sterile saline at a density of 1×10^6 colony-forming units per milliliter as described previously.[8] The rabbits were anesthetized as described above, and each animal's neck was prepared with iodine. The cisterna magna was entered with a 27-gauge needle, cerebrospinal fluid was withdrawn to verify position, and 500,000 colony-forming units (0.5 mL) were inoculated. Bacterial inocula were titered on *Brucella* and 5% horse blood agar. The 2 control rabbits were inoculated with an equal volume of sterile saline diluent.

Monitoring of Hearing Loss and Histopathology. Following inoculation, the rabbits were housed in separate cages and observed. The AER thresholds were tested every 6 hours, beginning 12 hours after inoculation. As hearing loss developed, the rabbits were painlessly sacrificed under deep ketamine and xylazine anesthesia and their temporal bones were harvested. This resulted in a collection of temporal bone specimens with hearing losses ranging from mild to profound (see Table). The rate of hearing loss progression was in keeping with previous studies.[7,8] Intravital cardiac perfusion was performed with saline, followed by intracardiac perfusion of fixative solution (2.5% glutaraldehyde and 2.0% paraformaldehyde in 0.1-mol/L phosphate buffer at

pH 7.3). The temporal bones were then harvested, the bullae opened, and the ossicles removed. The stapes footplate was removed with a 0.3-mm hook, and the specimens were trimmed and reimmersed overnight in fixative. The specimens were decalcified in 0.1-mol/L ethylenediaminetetraacetic acid with 2.0% glutaraldehyde in 0.1-mol/L phosphate buffer. They were then postfixed in 1.0% phosphate-buffered osmium tetroxide, dehydrated in graded alcohols, and embedded in Polybed-812. For subsequent electron microscopy, the cochleas were bisected along the longitudinal axis and the cochlear turns were separated. Ultrathin sections were cut, then stained with uranyl acetate and Sato's triple lead stain. Photographs were taken with a JEOL 100 CX transmission electron microscope at magnifications ranging from 1,000× to 33,000×.

The 2 control animals were painlessly sacrificed at 2 weeks following intrathecal inoculation with saline, and their temporal bones were processed in a manner identical to that of the infected subjects. The AERs of the control subjects were repeated at the time of sacrifice and were unchanged from baseline. The basal turns of the cochleas in both ears of all 7 rabbits were examined systematically by one author (R.S.K.), who was blinded as to the subject's hearing status. This included a review of the organ of Corti, cochlear nerve, spiral ganglion cells, and stria vascularis. The distribution of bacteria and inflammatory cells within the cochlea was also noted. The cochleas were examined at the 3.5-mm region of the basal turn, which corresponds to the region of the rabbit basilar membrane that is maximally stimulated by the high-frequency (10 kHz) stimulus[9] (also John Rosowski, personal communication, 1996).

RESULTS

Controls. Histopathologic examination of the 2 control subjects (rabbits 1 and 2) showed no significant abnormalities. Mild swelling was noted of a few outer and inner hair cell mitochondria and occasional nerve endings and was attributed to preparation artifact. One control showed some dense bodies within a few spiral ganglion cells. The remainder of the cochlear structures were normal.

Mild Hearing Loss. Rabbits 3 and 4 were sacrificed at the first sign of hearing loss, this being a 10-dB threshold elevation for the 10-kHz stimulus, with an unchanged threshold for clicks (see Table). Examination of the cochlear base in these animals revealed several abnormalities. Outer hair cells (OHCs) showed edema of mitochondria with distortion of cristae. Efferent nerve synapses contained swollen nerve endings. The OHC afferent synapses were not affected. Interestingly, both subjects had partial degeneration of the inner row of OHCs in the cochlear base of at least 1 ear (Fig 1A). Cilia were not affected. Examination of the inner hair cells (IHCs) in these animals showed mild vacuolization of cytoplasm, as well as swelling of afferent nerve endings. The cilia were normal.

The supporting cells were normal other than occasional myelin figures in the Deiters' cells. The basilar membrane was normal. Both animals had downward displacement of the tectorial membrane without disruption of cilia. Reissner's membrane in rabbit 4 showed some electron-dense cells, but was otherwise normal. Within the stria vascularis, vacuolization of the marginal cells, some of which were partially degenerated, was noted. There was swelling of intermediate cells and mild intercellular edema. Basal cells appeared normal, with intact tight junctions (Fig 1B).

Type I cochlear neurons showed occasional myelin figures, with very mild vacuolization of some spiral ganglion cells. Polymorphonuclear leukocytes were seen in Rosenthal's canal and in the scala tympani of rabbit 3. Rabbit 4 was found to have PMNs within the scala vestibuli, and bacteria were identified below the basilar membrane in the scala tympani of this animal (Fig 1C).

Moderate Hearing Loss. Rabbit 5 was sacrificed when the hearing loss was 30 dB above baseline threshold for both clicks and 10 kHz in each ear. The OHCs in this subject's cochlear base had increased ground substance within their cytoplasm, and a slightly increased proportion of lysosomal granules. The mitochondria were more swollen than in previous subjects, but other organelles such as Golgi bodies and subsurface cisternae were intact. In this animal, all 3 rows of OHCs had efferent nerve endings that were swollen and contained myelin figures. The afferent nerve endings appeared normal. The OHC cilia displayed mild distortion with rare blebs. The IHCs appeared intact, although some of their afferent nerve endings were edematous.

Increased cytoplasmic density and vacuolization of Deiters' cells was apparent. Hensen's cells were electron-dense as well. The marginal cells of the stria vascularis were vacuolated, and further swelling of the intermediate cells was noted. The basal cells remained normal. We saw PMNs in the spiral ligament, scala tympani, and scala vestibuli. One bacterium was identified within the scala media near the cilia of an IHC (Fig 2).

Severe Hearing Loss. Rabbit 6 was sacrificed

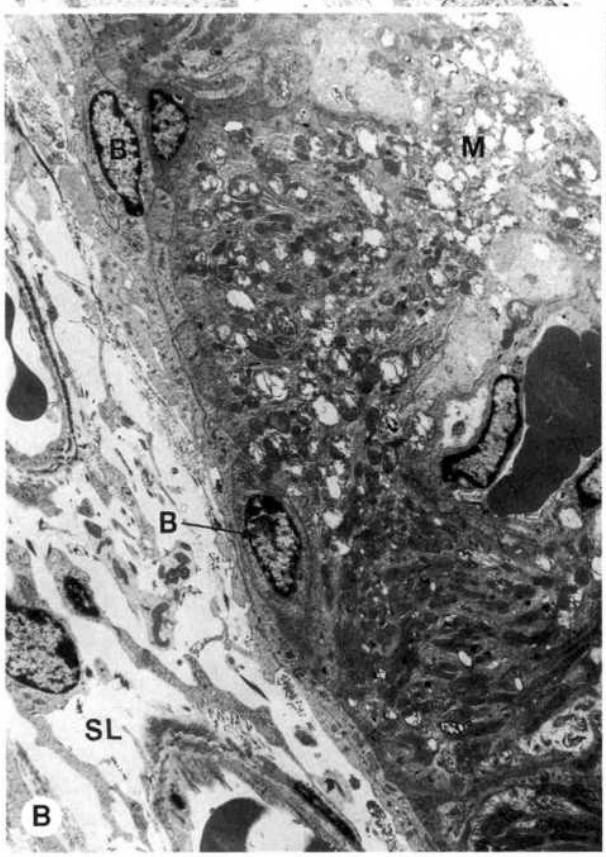

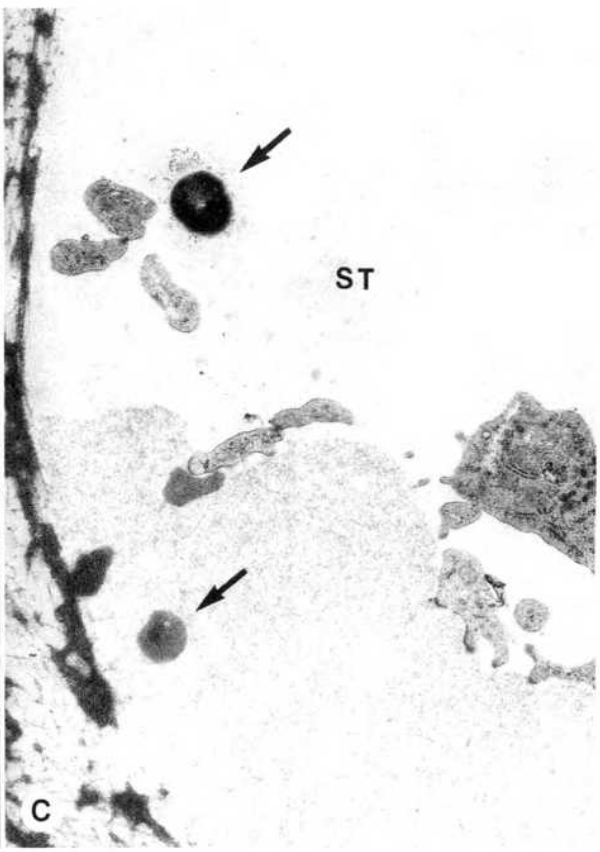

Fig 1. Mild hearing loss. A) (Rabbit 3) Outer hair cells (original ×2,000). Note degeneration of first row of OHCs (arrowhead), with intact stereocilia (arrows) and tectorial membrane (T). B) (Rabbit 4) Stria vascularis (original ×2,000). Note vacuolization of marginal cell (M) and mild intercellular edema. Basal cells (B) are normal. SL — spiral ligament. C) (Rabbit 4) Bacteria (arrows) within scala tympani (ST), below basilar membrane (original ×8,300).

when the hearing loss was 50 dB for clicks and 60 dB for 10 kHz in the right ear, and 40 dB for clicks and 50 dB for 10 kHz in the left ear. The inner row of OHCs at the cochlear base in each ear showed

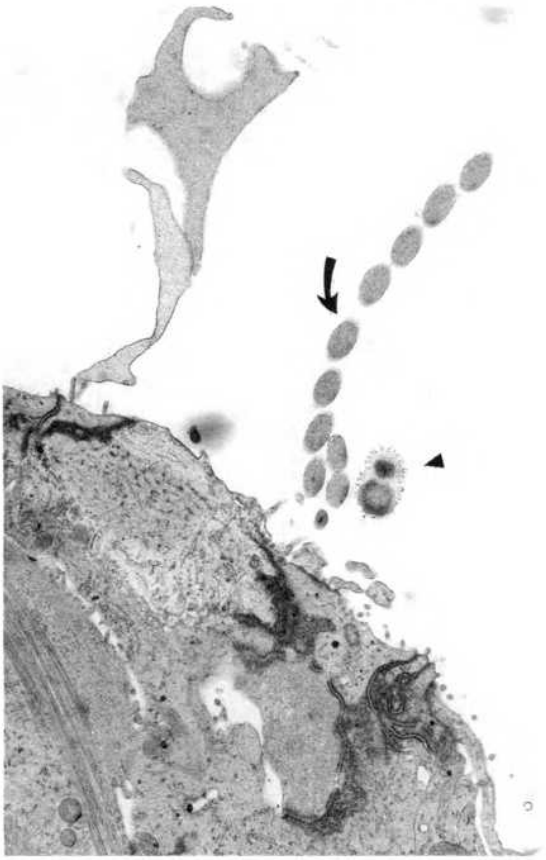

Fig 2. (Rabbit 5) Moderate hearing loss (original ×5,000). Bacterium (arrowhead) near apical portion of inner hair cell, which has slightly dense cytoplasm but intact stereocilia (arrow).

severe degeneration, with pyknotic nuclei, glycogen granules, vacuolization, and absent subsurface cisternae and Golgi bodies. The mitochondria contained multiple myelin figures. Swelling of the second and third rows of OHCs with irregular nuclear membranes was noted. The cilia of OHCs were blunted and bent; some showed fusion (Fig 3A). The efferent nerve endings were swollen, while the afferent synapses remained intact. The IHCs showed degenerated nuclei and disrupted cell membranes, with fused and/or missing cilia. Their afferent nerve endings were cystic (Fig 3B).

Deiters' and Hensen's cells contained myelin figures, and the cytoplasm of the inner phalangeal cells was electron-dense. The basilar and tectorial membranes remained intact, but Reissner's membrane consisted of cells with vacuolization and occasional myelin figures. There was vacuolization of some spiral ganglion cells and occasional myelin figures in both type I and type II neurons. The strial marginal cells had degenerating nuclei with clefting, and the intermediate cells showed vacuolization and shrinkage. The basal cells appeared normal. We saw PMNs in the scala vestibuli, in Corti's tunnel, and within the capillaries of the stria. Macrophages were seen in the tunnel of Corti, adjacent to the OHCs. Pneumococci were present in the scala tympani and in the region of the third row of OHCs near Hensen's cells.

Profound Hearing Loss. Rabbit 7 was sacrificed immediately after being determined to have bilateral, profound deafness (no response to maximal stimulus intensity of clicks and 10-kHz tone bursts). In this animal, all 3 rows of OHCs were severely degenerated (Fig 4A), with disrupted nuclear reticular lamina, absence of Golgi bodies and subsurface cisternae, and markedly decreased numbers of mitochondria. Both efferent and afferent nerve synapses were swollen. The IHCs were degenerating, with edematous afferent nerve endings.

The supporting cells were almost all abnormal, with vacuolization of the inner phalangeal cells and dense pillar cells and outer sulcus cells. Macrophages were seen penetrating the basilar membrane. There were PMNs interspersed along the tectorial membrane, and interdental cells in the limbus were degenerating. The cells of Reissner's membrane were degenerating, with breaks noted in the basement membrane (Fig 4B). Some spiral ganglion cells contained myelin figures, but overall, they appeared intact, with mildly increased cytoplasmic density (Fig 4C). The marginal cells of the stria vascularis showed severe vacuolization and large cystic spaces, with widened intercellular spaces. The intermediate cells were edematous, but the basal cells remained intact (Fig 4D). There were PMNs and macrophages within the spiral ligament, and electron-dense, vacuolated epithelial cells in the spiral prominence. Numerous PMNs, and associated proteinaceous debris, were located below the basilar membrane in the scala tympani, as well as in the scala media. Bacteria were identified in chains within the scala vestibuli, including 1 phagocytized bacterium.

DISCUSSION

This ultrastructural study of meningogenic labyrinthitis revealed that there are indeed major abnormalities evident at the electron microscopy level that were not identifiable by light microscopy alone, demonstrating the need for both techniques for a complete assessment of this process. The mildest hearing loss seen, only 10 dB threshold elevation at 10 kHz, was accompanied by abnormalities of the corresponding region of the cochlea. This included partial degeneration of the inner row of OHCs, edema of the efferent cochlear nerve endings, and vacuolization of the marginal cells of the stria vascularis. Inflammatory cells (PMNs) and bacteria were already

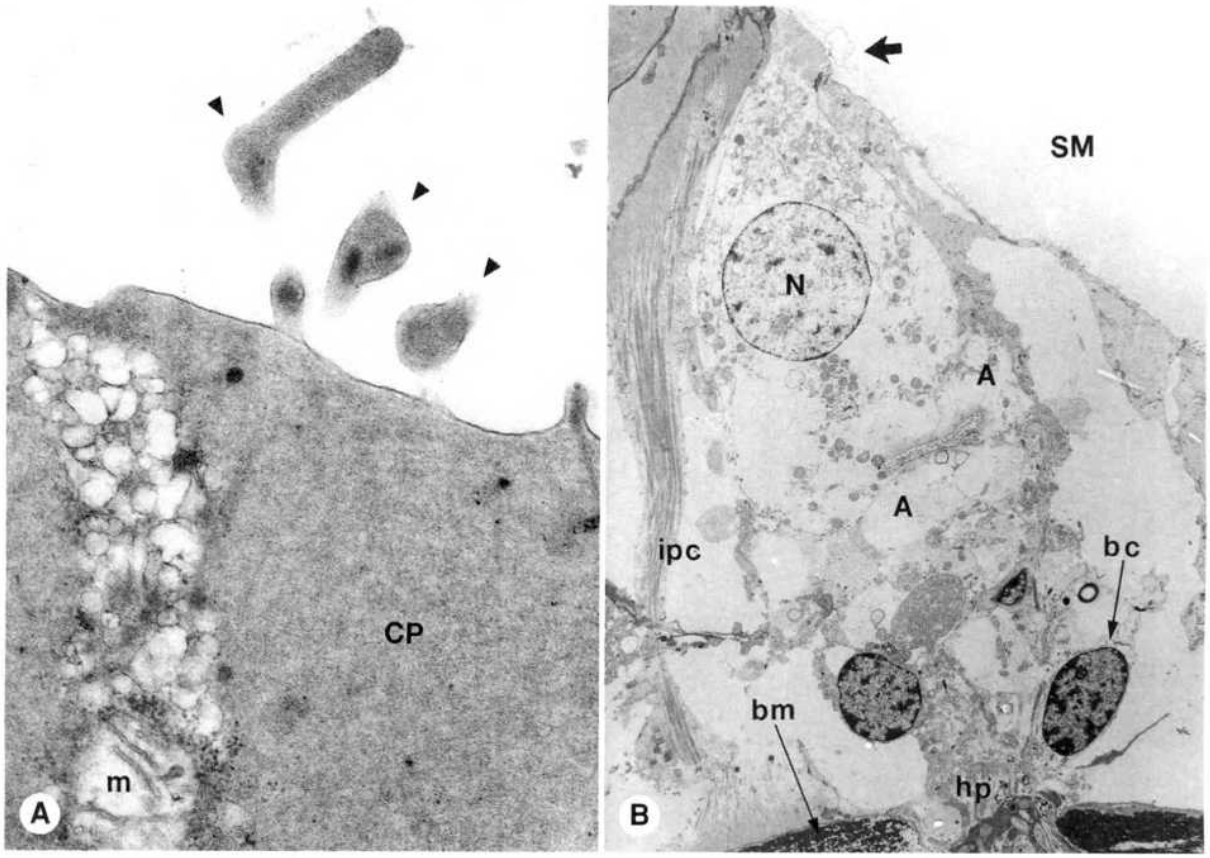

Fig 3. (Rabbit 6) Severe hearing loss. A) First row of outer hair cells (left ear), showing vacuoles and swollen mitochondrion (m; original ×26,000). Stereocilia (arrowheads) are bent, swollen, and/or fused. CP — cuticular plate. B) Inner hair cell (right ear; original ×2,000). Note absence of stereocilia (arrow) and vacuolization of cytoplasm. Nucleus (N) of IHC is pale, showing chromatolysis. Afferent nerve endings (A) are swollen and cystic. SM — scala media, bc — border cell, bm — basement membrane, hp — habenula perforata, ipc — inner pillar cell.

present in both the scala tympani and scala vestibuli.

The progression to moderate hearing loss was accompanied by more widespread structural changes. The second and third rows of OHCs showed increased cytoplasmic density, and swollen efferent nerve endings were seen. The IHCs remained relatively intact. The strial intermediate cells were more edematous. The PMNs remained confined to the perilymphatic fluid spaces, but pneumococci had entered the scala media.

Severe hearing loss was associated with considerably more damage to the cochlear structures, including the supporting cells, IHCs and OHCs, and their afferent and efferent synapses. The strial marginal cells and intermediate cells showed vacuolization, and the intercellular spaces were widened by edema. With profound hearing loss, inflammatory cells (PMNs and macrophages) and bacteria were seen throughout the perilymphatic and endolymphatic fluid compartments. Interestingly, the spiral ganglion cells and basal cells of the stria vascularis remained intact in this subject with acute, profound meningitic deafness.

To our knowledge, this represents the only study of the changes in cochlear ultrastructure seen for specific levels of meningitis-induced hearing loss. Other animal studies of labyrinthitis have illustrated findings both similar to and contrasting with ours.[10-23] Tarlow et al[10] measured an early, mild hearing loss (mean 15 dB hearing level) in cochlear microphonics and compound action potentials approximately 1 hour following the injection of *Escherichia coli* endotoxin into guinea pig cochleas. Using scanning electron microscopy, they found generalized swelling of the tectorial membrane and kinking or bending of IHC and OHC stereocilia, and they attributed their functional electrophysiologic deficits to this effect. Our findings do not support these ciliary changes as necessary for hearing loss, as rabbits with similar or greater degrees of hearing loss showed intact OHC and IHC stereocilia.

Comis et al[11] perfused guinea pig cochleas with pneumolysin, the cytolytic exotoxin of *S pneumoniae*, and found a dose-dependent effect on cochlear microphonics and compound action potentials. Scanning electron microscopy revealed severe and wide-

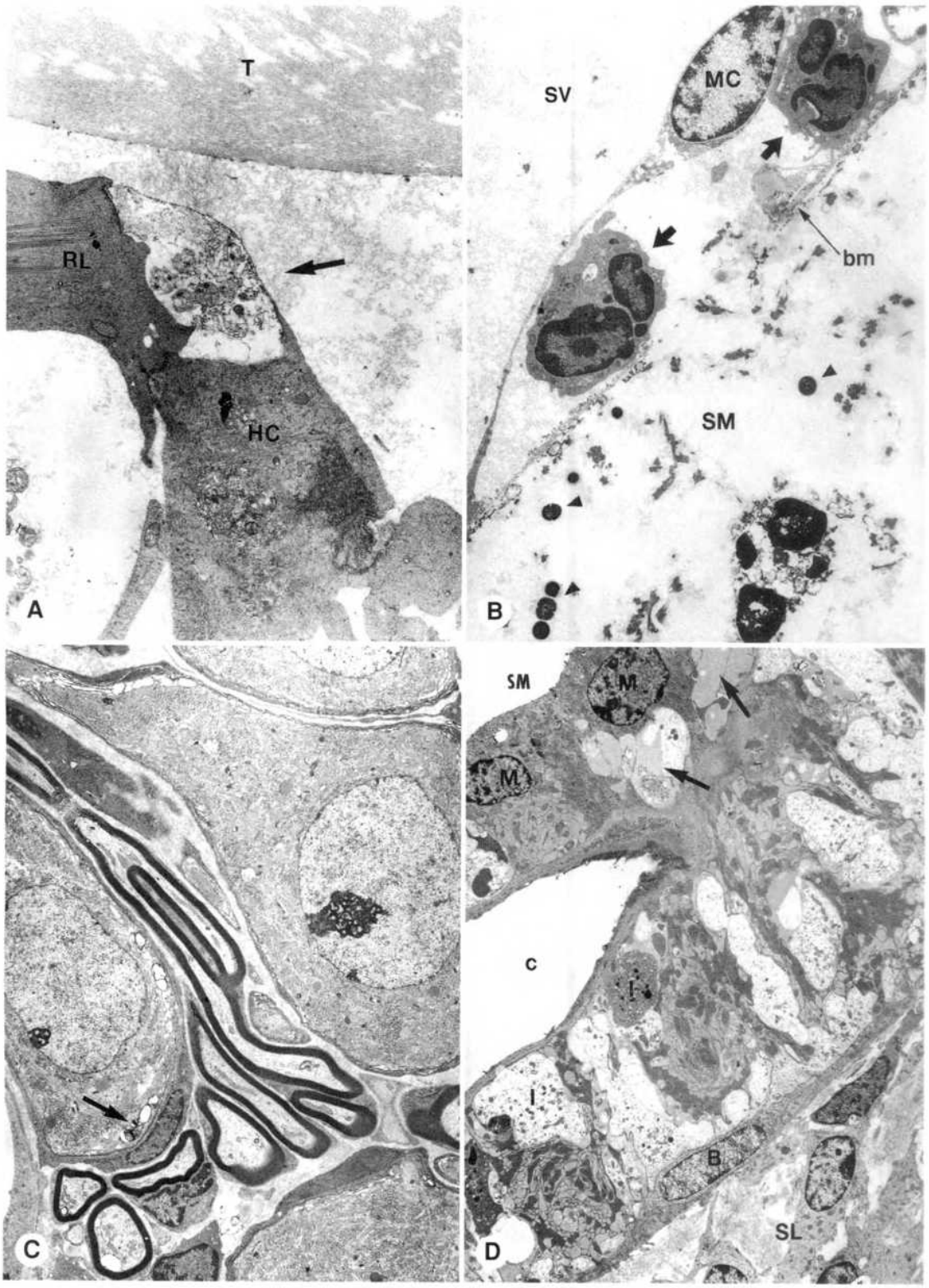

Fig 4. (Rabbit 7) Profound deafness. A) Degenerated remnant of third row of outer hair cells (arrow; original ×6,600). Note proteinaceous precipitate below tectorial membrane (T). HC — Hensen's cell, RL — reticular lamina. B) Reissner's membrane (original ×3,300). Macrophages (arrows) and degenerating mesothelial cells (MC), with breaks in basement membrane (bm), are seen. Note bacteria (arrowheads) within scala media (SM). SV — scala vestibuli. C) Spiral ganglion cells (original ×2,600). Note normal appearance of these cells, including 1 that contains small myelin figure (arrow). D) Stria vascularis (original ×2,000). Note vacuolization of marginal cells (M) with cystic spaces (arrows). Intermediate cells (I) are partially degenerate. Basal cells (B) and their junctions remain intact. c — capillary, SL — spiral ligament, SM — scala media.

spread damage throughout all turns of the organ of Corti. Although all the rows of OHC cilia were disrupted, the severity of the damage increased progressively from row 1 (inner row) to row 3 (outer row). Damage sustained by the IHCs was comparable to that of OHC rows 2 and 3. Similar changes were noted by Ross et al,[12] who induced autoimmune labyrinthitis by injecting foreign protein into the scala tympani of guinea pigs. Our findings are consistent with this pattern of change, but differ in that the earliest damage to hair cells was limited to the inner row of OHCs in the rabbit model. This may be due to toxin-related effects. For example, Friedland et al[13] concluded that pneumolysin does not have a major role in the pathogenesis of meningeal inflammation in natural pneumococcal meningitis. Another explanation may be that the above studies involved direct perfusion of the scala spaces with inherent potential for artifact induction.

The finding of earliest and most severe damage to the inner row of OHCs has been reported in studies of nonmeningitic cochlear damage, including high doses of aminoglycoside in rats[14] and intravenous injection of carboplatin in chinchillas.[15] Conversely, several studies have shown a reverse order of OHC susceptibility, with the second and third rows of OHCs being most damaged, and the first (inner) row of OHCs least affected. These studies have included waltzing guinea pigs,[16] toluene exposure by inhalation in rats,[17] and guinea pigs with fast neutron irradiation to their cochleas.[18]

Kaplan et al[19] found suppurative labyrinthitis 48 hours after inducing *Haemophilus influenzae* meningitis in rats, but hearing was not assessed. Blank et al[20] induced pneumococcal meningitis in guinea pigs and described a pattern of inflammation within the perilymphatic spaces, progressing from cochlear base to apex, similar to our findings. In their study, no inflammation was apparent in the scala media or spiral ganglion on light microscopy. Electron microscopy was not performed. Cochlear cytoarchitecture was not described, and the animals' hearing integrity was tested only grossly, by Preyer's reflexes.

Schachern et al[21] inoculated *S pneumoniae* into the middle ears of chinchillas and studied their temporal bones with light and transmission electron microscopy. The scala tympani and vestibuli, in all cochlear turns, were found to contain bacteria, fibrin, and PMNs. Bacteria were identified entering the area of the myelinated nerves through Schuknecht's canals, with spread into the organ of Corti via the habenula perforata. The nerves were often degenerated, and OHCs and IHCs were missing or atrophied in all turns. In all symptomatic animals, the striae vasculares were edematous, hemorrhagic, and in some cases atrophic; Reissner's membranes were hydropic in all cochlear turns. Infection in these cases was the result of direct extension through the round window membranes, and hearing was not assessed. The more extensive degree of damage seen in their study in comparison with ours is likely attributable to the fact that their animals were sacrificed when they demonstrated vestibular signs of labyrinthitis (head tilt or staggering). In our model, vestibular signs occur 12 to 24 hours following profound deafness and represent a later stage of infection and inflammation.

Animal studies of viral labyrinthitis[22,23] have shown preferential involvement of the stria vascularis. As was the case in our bacterial model, the basal cells were extremely resistant to the viral infection, maintaining cytologic integrity despite the severe degeneration of marginal and intermediate cells in the contiguous area.

Light microscopy of human temporal bone changes in meningitis shows suppurative labyrinthitis, most severe in the perilymphatic spaces.[6,24,25] Merchant and Gopen[6] reviewed 41 human temporal bones of patients with acute bacterial meningitis. Suppurative labyrinthitis was seen in 49% of these bones, yet sensory and neural structures of the inner ear were intact in the majority of specimens at the light microscopy level. These investigators compared their human temporal bone findings to those of our rabbit meningitis model, and found many similarities in both groups' inner ear histopathology. This study was limited by the lack of audiological documentation of hearing loss in their human temporal bone subjects, thus underscoring the need for a controlled animal model to understand the pathogenesis and progression of meningitic hearing loss. Moreover, electron microscopy of temporal bone changes was not available. Their findings questioned the traditional assumption that suppurative labyrinthitis (defined as the presence of inflammatory cells in the fluid spaces and/or tissues of the inner ear) results in permanent and irreversible hearing loss.[25]

Our study has revealed that meningogenic labyrinthitis is associated with inflammatory changes of the cochlea at an early time point. For example, the temporal bone of rabbit 4 contained PMNs within the perilymphatic spaces of the scala vestibuli, and bacteria within the scala tympani, despite near-normal hearing status in this subject. The finding of "suppurative" labyrinthitis at a stage of mild hearing loss reinforces the need to reevaluate the notion that serous labyrinthitis is associated with reversible hearing loss, while suppurative labyrinthitis results

in irreversible deafness. Previous studies (Rappaport et al, unpublished data) have shown this mild to moderate degree of hearing loss to be potentially reversible, and the lack of widespread ultrastructural cochlear damage supports this concept. We propose that the designation of suppurative labyrinthitis remain a descriptive term only, without a connotation of functional (ie, irreversible) hearing loss. In fact, our model suggests that it is suppuration of the endolymphatic fluid compartment that more specifically is associated with severe and permanent deafness.

Our findings do not necessarily imply or prove that these ultrastructural abnormalities are directly causing the observed hearing loss; one can hypothesize, however, as to the pathoetiologic mechanisms of this hearing loss on the basis of the parallel changes seen on electron microscopy. In the earliest stages of meningitic infection, bacteria and inflammatory cells were already present within the animals' cochleas. One can postulate that their initial auditory dysfunction may be due to altered homeostasis of inner ear fluid composition, including changes in viscosity or, more likely, endocochlear potential. Derangement of the electrochemical gradient is particularly likely at the point that strial intermediate cells become affected and widened intercellular spaces are evident, as seen at stages of moderate sensorineural deafness in this study. In fact, ototoxic effects without obvious histologic destruction of sensory epithelia have previously been reported with the diuretics furosemide and ethacrynic acid,[26] salicylates,[27] and indomethacin.[28] The ototoxic effects of these compounds are known to be reversible. Schwarz et al[29] studied chloroform-induced ototoxicity in guinea pigs and rats and found that these animals developed acute deafness despite normal inner ear histologic appearance on light microscopy. A secondary labyrinthitis, resulting in endolymphatic hydrops, was noted in these animals at a later time period and was associated with a permanent threshold shift.

Endolymphatic hydrops was seen in all deaf rabbits on light microscopy. Electrophysiologic and electrochemical changes have been observed in the inner ear with experimental hydrops, including a decrease in endocochlear potential[30] and a decrease in immunoreactivity for a variety of enzymes, calcium binding proteins, structural proteins, and integral membrane proteins of gap junctions, particularly among type I and type II fibrocytes of the lateral cochlear wall,[31] Mizuta et al[32] localized the sodium-potassium-chloride cotransporter as present in both the marginal and intermediate cells of the stria vascularis in rabbits. One may hypothesize, then, that mild to moderate hearing loss can occur secondary to alterations in protein function (eg, sodium-potassium adenosine triphosphatase), with subsequent gross alterations in enzyme and/or ionic milieus (eg, changes in pH or in calcium, sodium, or potassium levels).

In experimentally induced endolymphatic hydrops, a variable pattern of threshold elevations has been described. In these animal models, degeneration of hair cells and neurons is often rapid and severe. In addition to degeneration and loss of both OHCs and IHCs, abnormalities of the stereocilia among the remaining hair cells are seen. It has been suggested that this submicroscopic histopathology of stereocilia may be the cause of sensorineural hearing loss in these experimental animals.[31,33] In a study of hydropic rabbits, Lonsbury-Martin et al[34] suggested that dysfunction of the primary cochlear neuron may be more important than hair cell dysfunction in the pathogenesis of hearing loss.

The current study thus identifies early stages in the progression of meningitic deafness in which structural damage is mild (nonlethal to cells), and during which the hearing loss may be potentially reversible. Studies have suggested that the host immune response to the infecting organisms is responsible for much of the morbidity produced by bacterial meningitis.[1] The advent of effective antimicrobial therapy and improved medical management have resulted in more patients' surviving meningitis with residual deafness. By measuring hearing loss very early in meningitis, some clinical studies in humans have shown that the hearing loss may indeed be reversible.[35-37] Therefore, the elucidation of the mechanisms for this hearing loss as a potential route for therapeutic intervention is crucial.

Prophylactic therapy to prevent meningitic hearing loss may take advantage of the potentially reversible changes seen in this study. This therapy may be directed at prolonging the reversible state to allow time for antibiotics to be effective, or may blunt the host inflammatory response and enhance repair of the sequelae of acute bacterial meningitis and its treatment. Early intervention with anti-inflammatory agents might prevent hearing loss from progressing to its more severe stages. In fact, our findings and hypotheses are in keeping with clinical studies that have shown a beneficial effect on hearing of dexamethasone in addition to antibiotic treatment for meningitis. These studies have shown that corticosteroids do appear to be successful in preventing the progression to moderate or greater bilateral hearing impairment in pediatric bacterial meningitis.[38-41] Further, studies have revealed a beneficial therapeutic

effect of corticosteroids[42] and nonsteroidal agents[43] in preventing or minimizing acquired meningitic deafness in the rabbit pneumococcal model. These studies found that treatment instituted by 18 hours postinfection could result in a reversal of as much as 60 dB of acute sensorineural hearing loss, including a return to baseline thresholds in some animals.

Certain structural insults that occur in pneumococcal meningitis likely represent irreversible damage to the auditory system. For example, the light microscopy finding of inflammatory cells within the endolymphatic fluid (ie, scala media) was associated with derangement of hair cells within the cochleas of profoundly deaf animals. This suggests that once the endolymphatic fluid compartment is breached by inflammatory cells, permanent hearing loss is the likely sequela.

ACKNOWLEDGMENTS — The authors thank Jessica Hutta and Jennifer Trehey for their assistance with temporal bone preparation and electron microscopy. We are grateful to Dr Saumil N. Merchant and Dr Joseph B. Nadol, Jr, for their valuable comments during the preparation of the manuscript.

REFERENCES

1. Lipton JD, Schafermeyer RW. Evolving concepts in pediatric bacterial meningitis. Part I: Pathophysiology and diagnosis. Ann Emerg Med 1993;22:1602-15.

2. Nadol JB Jr. Hearing loss as a sequela of meningitis. Laryngoscope 1978;88:739-55.

3. Ozdamar O, Kraus N, Stein L. Auditory brainstem responses in infants recovering from bacterial meningitis: audiologic evaluation. Arch Otolaryngol 1983;109:13-8.

4. Dodge PR, Davis H, Feigin RD, et al. Prospective evaluation of hearing impairment as a sequela of acute bacterial meningitis. N Engl J Med 1984;311:869-74.

5. Kaplan SL, Smith EO, Wills C, Feigen RD. Association between preadmission oral antibiotic therapy and cerebrospinal fluid findings and sequelae caused by *Haemophilus influenzae* type b meningitis. Pediatr Infect Dis 1986;5:626-32.

6. Merchant SN, Gopen Q. A human temporal bone study of acute bacterial meningogenic labyrinthitis. Am J Otol 1996; 17:375-85.

7. Bhatt S, Halpin C, Hsu W, et al. Hearing loss and pneumococcal meningitis: an animal model. Laryngoscope 1991; 101:1285-92.

8. Bhatt S, Lauretano A, Cabellos C, et al. Progression of hearing loss in experimental pneumococcal meningitis: correlation with cerebrospinal fluid cytochemistry. J Infect Dis 1993; 167:675-83.

9. West CD. The relationship of the spiral turns of the cochlea and the length of the basilar membrane to the range of audible frequencies in ground dwelling mammals. J Acoust Soc Am 1985;77:1091-101.

10. Tarlow MJ, Comis SD, Osborne MP. Endotoxin induced damage to the cochlea in guinea pigs. Arch Dis Child 1991;66: 181-4.

11. Comis SD, Osborne MP, Stephen J, et al. Cytotoxic effects on hair cells of guinea pig cochlea produced by pneumolysin, the thiol activated toxin of *Streptococcus pneumoniae*. Acta Otolaryngol (Stockh) 1993;113:152-9.

12. Ross UH, Rogowski M, Reiss G, Gloddek B. Detection of cochlear dysfunction by the measurement of transiently evoked otoacoustic emissions in guinea pigs with autoimmune-induced labyrinthitis. Eur Arch Otorhinolaryngol 1994;251:80-3.

13. Friedland IR, Paris MM, Hickey S, et al. The limited role of pneumolysin in the pathogenesis of pneumococcal meningitis. J Infect Dis 1995;172:805-9.

14. Lenoir M, Puel JL. Dose-dependent changes in the rat cochlea following aminoglycoside intoxication. II. Histological study. Hear Res 1987;26:199-209.

15. Wake M, Takeno S, Ibrahim D, Harrison R. Selective inner hair cell ototoxicity induced by carboplatin. Laryngoscope 1994;104:488-93.

16. Canlon B, Marklund K, Borg E. Measures of auditory brain-stem responses, distortion product otoacoustic emissions, hair cell loss, and forward masking tuning curves in the waltzing guinea pig. J Acoust Soc Am 1993;94:3232-43.

17. Johnson AC, Canlon B. Progressive hair cell loss induced by toluene exposure. Hear Res 1994;75:201-8.

18. Kim CS, Shin SO. Ultrastructural changes in the cochlea of the guinea pig after fast neutron irradiation. Otolaryngol Head Neck Surg 1994;110:419-27.

19. Kaplan SL, Hawkins EP, Kline MW, Patrick GS, Mason EO Jr. Invasion of the inner ear by *Haemophilus influenzae* type b in experimental meningitis. J Infect Dis 1989;159:923-30.

20. Blank AL, Davis GL, VanDeWater TR, Ruben RJ. Acute *Streptococcus pneumoniae* meningogenic labyrinthitis. An experimental guinea pig model and literature review. Arch Otolaryngol Head Neck Surg 1994;120:1342-6.

21. Schachern PA, Paparella MM, Hybertson R, Sano S, Duvall AJ 3d. Bacterial tympanogenic labyrinthitis, meningitis, and sensorineural damage. Arch Otolaryngol Head Neck Surg 1992;118:53-7.

22. Tanaka K, Hirai T, Suenaga T, Terayama Y, Fukuda S, Matsumiya H. Experimental Sendai virus–induced labyrinthitis in guinea pigs. An ultrastructural study of cochlear lesions. Ann Otol Rhinol Laryngol 1984;93:240-6.

23. Davis GL. In vitro models of viral-induced congenital deafness. Am J Otol 1981;3:156-60.

24. Igarashi M, Schuknecht HF. Pneumococcic otitis media, meningitis, and labyrinthitis: a human temporal bone report. Arch Otolaryngol 1962;76:126-30.

25. Paparella MM, Sugiura S. The pathology of suppurative labyrinthitis. Ann Otol Rhinol Laryngol 1967;76:554-86.

26. Brown RD, Feldman AM. Pharmacology of hearing and ototoxicity. Annu Rev Pharmacol Toxicol 1978;18:233-52.

27. Deer BC, Hunter-Duvar I. Salicylate ototoxicity in the chinchilla: a behavioral and electron microscope study. J Otolaryngol 1982;11:260-4.

28. Morrison MD, Blakley BW. The effects of indomethacin on inner ear fluids and morphology. J Otolaryngol 1978;7: 149-57.

29. Schwarz DWF, Schwarz IE, Hu K. Histopathology of chloroform-induced inner ear damage. J Otolaryngol 1988;17:

32-7.

30. Cohen J, Morizono T. Changes in EP and inner ear ionic concentrations in experimental hydrops. Acta Otolaryngol (Stockh) 1984;98:398-402.

31. Nadol JB Jr, Adams JC, Kim JR. Degenerative changes in the organ of Corti and lateral cochlear wall in experimental endolymphatic hydrops and human Meniere's disease. Acta Otolaryngol Suppl (Stockh) 1995(suppl 519):47-59.

32. Mizuta K, Adachi M, Iwasa KH. Ultrastructural localization of the Na-K-Cl cotransporter in the lateral wall of the rabbit cochlear duct. ARO Meeting Abstracts 1996:134.

33. Kimura RS. Experimental blockage of the endolymphatic duct and sac and its effect on the inner ear of the guinea pig. A study on endolymphatic hydrops. Ann Otol Rhinol Laryngol 1967;76:664-87.

34. Lonsbury-Martin BL, Martin GK, Coats AC, Probst R. Alterations in acoustic-distortion products and cochlear nerve fiber activity in hydropic rabbits. In: JB Nadol Jr, ed. Second International Symposium on Meniere's Disease. Amsterdam, the Netherlands: Kugler and Ghedini, 1988:337-50.

35. Liebman EP, Lovrinic JH, Ronis ML, Katinsky SE. Hearing improvement following meningitis deafness. Arch Otolaryngol 1969;90:470-3.

36. Roeser RJ, Campbell JC, Daly DD. Recovery of auditory function following meningitic deafness. J Speech Hear Disord 1975;40:405-11.

37. Vienny H, Despland PA, Lutschg J, Deonna T, Dutoit-Marco ML, Gander C. Early diagnosis and evolution of deafness in childhood bacterial meningitis: a study using brainstem auditory evoked potentials. Pediatrics 1984;73:579-86.

38. Lebel MH, Freij BJ, Syrogiarmopoulos GA, et al. Dexamethasone therapy for bacterial meningitis: results of two double-blind, placebo-controlled trials. N Engl J Med 1988;319: 964-71.

39. Girgis NI, Faris Z, Mikhail IA, Farrag I, Sultan Y, Kilpatrick ME. Dexamethasone treatment for bacterial meningitis in children and adults. Pediatr Infect Dis J 1989;8:848-51.

40. Odio CM, Faingezicht I, Paris M, et al. The beneficial effects of early dexamethasone administration in infants and children with bacterial meningitis. N Engl J Med 1991;324: 1525-31.

41. Yurkowski PJ, Plaisance KI. Prevention of auditory sequelae in pediatric bacterial meningitis: a meta-analysis. Pharmacotherapy 1993;13:494-9.

42. Bhatt SM, Cabellos C, Nadol JB Jr, et al. The impact of dexamethasone on hearing loss in experimental pneumococcal meningitis. Pediatr Infect Dis J 1995;14:93-6.

43. Rappaport JH, Bhatt SM, Burkard RF, Merchant SN, Nadol JB Jr. Prevention of hearing loss in experimental pneumococcal meningitis by administration of dexamethasone and ketorolac. J Infect Dis 1999;179:264-8.

≈

MIDDLE EAR MECHANICS

The Second International Symposium on Middle Ear Mechanics in Research and Otosurgery will be held October 21-24, 1999, in Boston, Massachusetts. For information, contact Harvard MED-CME, PO Box 825, Boston, MA 02117; telephone (617) 432-1525; web site http://www.med.harvard.edu/conted/.

RELATIONSHIP OF THE UTRICULUS AND SACCULUS TO THE STAPES FOOTPLATE: ANATOMIC IMPLICATIONS FOR SOUND- AND/OR PRESSURE-INDUCED OTOLITH ACTIVATION

DOUGLAS D. BACKOUS, MD
SEATTLE, WASHINGTON
EDWARD S. ABOUJAOUDE, MD
BALTIMORE, MARYLAND
LLOYD B. MINOR, MD
BALTIMORE, MARYLAND
GEORGE T. NAGER, MD
BALTIMORE, MARYLAND

One hundred thirty human temporal bones that were sectioned in the vertical plane were examined to evaluate the relationship between the stapes footplate and the otolith organs. The shortest distance between the footplate and the utriculus was 0.58 ± 0.10 mm in the posterior third of the oval window, 1.04 ± 0.20 mm in the middle third, and 1.51 ± 0.20 mm in the anterior third. The distance from the sacculus to the footplate was 1.33 ± 0.20 mm in the middle third of the oval window and 1.31 ± 0.18 mm in the anterior third. Membranous connections extending between the utriculus and the footplate were found in 26% of temporal bones. These membranous connections in coexistence with additional anatomic factors such as stapes hypermobility and/or dehiscence of bone within labyrinthine structures may predispose patients to sound- and/or pressure-induced otolith activation. The findings may have implications for different causes of the Tullio phenomenon.

KEY WORDS — otolith, sacculus, stapes footplate, superior canal dehiscence, temporal bone histology, Tullio's phenomenon, utriculus.

INTRODUCTION

Tullio[1] described sound-induced eye and head movements in pigeons after surgical semicircular canal fenestration. Vestibular signs and symptoms caused in humans by sounds have been attributed to semicircular canal and otolith mechanisms. The Tullio phenomenon resulting from semicircular canal stimulation, with rotatory vertigo and nystagmus in the plane of the affected canal, has classically been identified as a complication of congenital temporal bone anomalies, syphilis, or cholesteatoma with erosion of bone overlying a semicircular canal, and as a finding after fenestration surgery for otosclerosis. Minor et al[2] recently described a syndrome of sound- and/or pressure-evoked vertigo and nystagmus in patients with a dehiscence of bone overlying the superior semicircular canal. This opening in the bone overlying the superior canal creates a third mobile window into the inner ear that allows the canal to respond to sound and to changes in pressure in the membranous labyrinth. The evoked eye movements are in the plane of the superior canal.

Patients with symptoms and signs thought to be attributable to sound-induced otolith activation have also been identified.[3,4] In an extensively studied case, Dieterich et al[5] reported a 35-year-old professional horn player who developed vertigo and postural imbalance evoked by tones of 480 ± 20 Hz at 95 dB in the left ear after he had practiced a new technique that involved high pressure in the nasopharynx and eustachian tube. The patient developed an "excitatory" ocular tilt reaction to these tones, ie, vertical skew deviation of the eyes with hypertropia (ipsilateral eye higher than contralateral, contralateral torsional deviation of the superior poles of the eyes, and contralateral head tilt). A hyperactive acoustic reflex in the affected ear, indicative of large-amplitude movements of the stapes footplate, was noted with impedance testing. Subluxation of the stapes footplate and hypertrophy of the stapedius muscle were found on middle ear exploration. The cause of the sound-induced symptoms and signs was thought to be activation of the utriculus by motion of the stapes. Cartilage and, later, compressed silicone foam were interposed between the stapes crurae to intentionally fix the footplate. The sound-induced paroxysms of the ocular tilt reaction and postural imbalance subsequently resolved.

An "inhibitory" ocular tilt reaction, with eye and head movements in the direction opposite to those described above, has also been identified.[6] Such findings can occur in cases of presumed injury to the

From the Department of Otolaryngology–Head and Neck Surgery, The Johns Hopkins University School of Medicine, Baltimore, Maryland. Dr Backous is currently at the Department of Otolaryngology–Head and Neck Surgery, Virginia Mason Medical Center, Seattle, Washington.
This work was supported by a grant from the Research Fund of the American Otological Society, Inc, by a grant from the American Laryngological, Rhinological and Otological Society, Inc, and by grants DC 00979 and DC 02390 from the National Institutes of Health/National Institute on Deafness and Other Communication Disorders.
CORRESPONDENCE — Lloyd B. Minor, MD, PO Box 41402, Baltimore, MD 21203-6402.

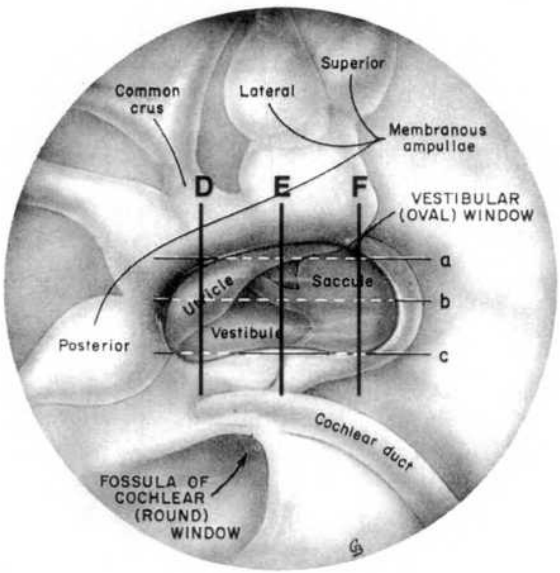

Fig 1. Right oval window according to Anson et al[12] (modified with permission), illustrating superior (a), point of maximal width (b), and inferior (c) levels. Vertical lines are added to represent sites of measurement along oval window in current study (D — posterior, E — middle, F — anterior).

utriculus such as following stapedectomy with migration of the prosthesis into the vestibule. Paroxysms of the ocular tilt reaction, oscillopsia, and postural imbalance have been termed the otolith Tullio phenomenon.[3,5]

Experimental studies have identified eye movements evoked by stimulation of specific regions of the utriculus and sacculus. Fluur and Mellström[7,8] observed eye movements evoked by microstimulation of discrete regions of the utricular and saccular maculae of cats. Coordinated upward, downward, or horizontal movements of both eyes were produced according to the relationship of the area of stimulation to the striola. Curthoys,[9] however, noted upward eye movements in response to microstimulation of all regions of the utricular and saccular maculae of guinea pigs. Differences in surgical approaches to the vestibule and/or microstimulation techniques may account for the discrepancy between findings in these studies.

Electrical stimulation of the utricular nerve in alert cats produces predominantly torsional eye movements with the superior pole of the eyes deviating away from the side of stimulation.[10,11] Two other components of the eye movements evoked by utricular nerve stimulation were also noted: small vertical movements upward in the ipsilateral eye and downward in the contralateral eye, and small contralateral horizontal movements in both eyes. These findings correspond to those noted in the patient with presumed utricular stimulation by sound described by Dieterich et al.[5]

We examined vertically sectioned, archival human temporal bones to determine anatomic factors that may predispose to otolith activation by sound or pressure stimuli to the ear. Connective tissue structures joining the utriculus to the stapes footplate were identified in 26% of the specimens. Such connections may have a role in eliciting otolith activation by these stimuli. A dehiscence in the labyrinth such as those identified in the superior canal or another anatomic abnormality such as hypermobility of the stapes footplate may be required in order for these types of activation to occur.

MATERIALS AND METHODS

The temporal bones examined in this study were from the Johns Hopkins University temporal bone registry. In accordance with standard methodology, each bone had been decalcified, embedded in celloidin, and cut in the vertical plane in 24-μm sections, and every 10th section was mounted and stained for histologic examination. Specimens were included in this study only if there was no evidence on microscopic examination of labyrinthine hydrops, inflammation, infection, osteitis, hemorrhage, congenital middle or inner ear malformation, stapes subluxation, or bony fistulization of the otic capsule. Death records were used to obtain demographic information and to exclude specimens from patients with documented otologic disease.

Sections were digitized (Hamamatsu CCD camera/Macintosh 840w), displayed on a video monitor (72 dots per inch), and saved as TIFF (tagged-image file format) files to preserve anatomic relationships. Distance calibration was done with a scale bar for each data collection session. On-line image analysis (NIH 1.58 software) was used to determine the shortest distance from the undersurface of the footplate to the utriculus and sacculus. Measurements were taken at the posterior, middle, and anterior regions of the oval window (Fig 1[12]). Three measurements were taken at each location. The presence or absence of membranous connections and the relationships of these connections between the footplate and the otoliths were documented. Findings required verification by 3 examiners to be included in the study.

RESULTS

One hundred thirty temporal bones met the criteria for inclusion in the study. Eighty-eight specimens were from males and 42 from females. The shortest distance between the footplate and the utriculus was 0.58 ± 0.10 mm (mean ± SD) in the posterior third

SHORTEST DISTANCE MEASURED BETWEEN OTOLITH ORGANS AND STAPES FOOTPLATE IN VERTICALLY SECTIONED HUMAN TEMPORAL BONES (N = 130)

	Posterior Third		*Middle Third*		*Anterior Third*	
	Utriculus	*Sacculus*	*Utriculus*	*Sacculus*	*Utriculus*	*Sacculus*
Mean	0.58	N/A	1.04	1.33	1.51	1.31
Median	0.59	N/A	1.00	1.30	1.47	1.28
SD	0.10	N/A	0.20	0.20	0.20	0.18

Data are in millimeters.
N/A — not applicable.

of the oval window, 1.04 ± 0.20 mm in the middle third, and 1.51 ± 0.20 mm in the anterior third. The shortest distance from the sacculus to the footplate was 1.33 ± 0.20 mm in the middle third of the oval window and 1.31 ± 0.18 mm in the anterior third (see Table). The sacculus was not present in any of the posterior sections. In no specimen was either the utriculus or the sacculus in direct contact with the stapes footplate.

Membranous connections between the utriculus and the footplate were found in 34 of the 130 bones (26%; Fig 2). Patients in this group ranged in age from 8 to 74 years. Twenty specimens were from males and 14 from females. These areas of connective tissue were found bilaterally in 7 patients. The remaining 20 specimens had unilateral membranous connections only. The cause of death of the patients found to have membranous connections varied. Seven patients died of complications of pulmonary tuberculosis, 6 of intracranial tumors unrelated to the inner ear or posterior fossa, 4 of cancer other than brain, 3 of atherosclerosis, 2 of aortic rupture, 1 each of bronchitis, rheumatic fever, cirrhosis, and meningitis, and 1 of an unknown cause.

The membranous connections were not distributed evenly along the 3 regions of the footplate. The posterior footplate was the only site of involvement in 18 specimens (Fig 3). The middle portion of the footplate was the sole site in 1 bone, and the connections spanned from the posterior to the middle sections in 15 samples. Membranous connections to the utriculus in immediate proximity to the macula were present in 33 of 34 specimens. Membranous connections did not contact the anterior footplate or the sacculus.

DISCUSSION

Stapes hypermobility resulting in direct mechanical activation of the macula of the utriculus has been suggested as one mechanism for the otolith Tullio phenomenon.[5] Our study examined relative distances between structures in the otic capsule and the stapes footplate in archival human temporal bone sections. Measurements of the shortest distance from the stapes base to the utriculus, sacculus, and foramen of the spherical recess in horizontal human temporal bone sections were first reported by Anson et al.[12] They measured a representative specimen and then documented the shortest distance from a group of 25 additional bones. Their findings can be summa-

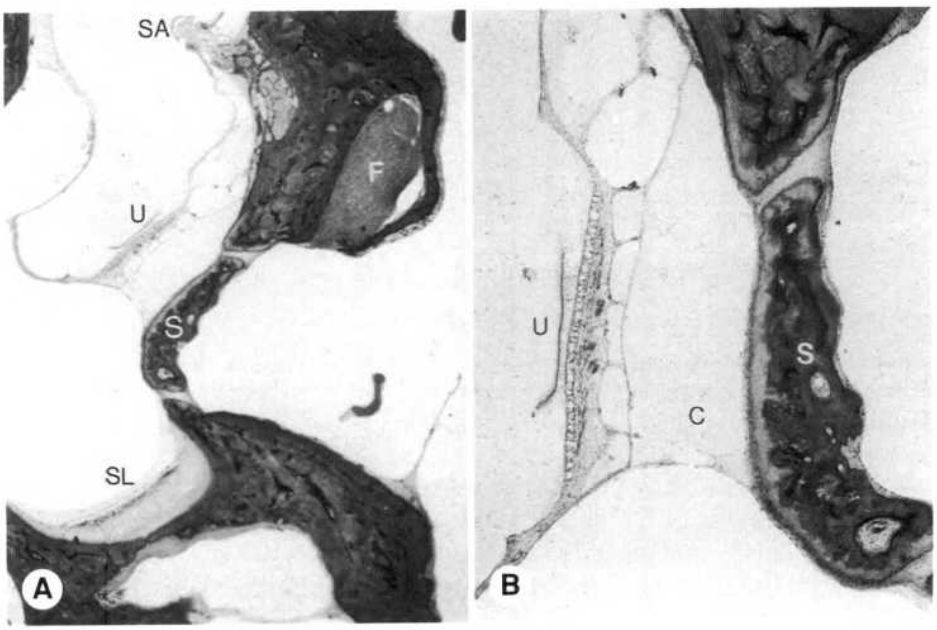

Fig 2. A) Left temporal bone with connective tissue meshwork joining utriculus (U) to posterior aspect of stapes footplate (S) and labyrinthine bone superior to footplate (×13). Macula of utriculus and portion of otoconial membrane are visualized. Also seen on this section are facial nerve (F), ampulla of superior canal (SA), and spiral ligament of cochlea (SL). B) Higher-power image from same section of trabecular network (C) that joins footplate (S) to utriculus (×33).

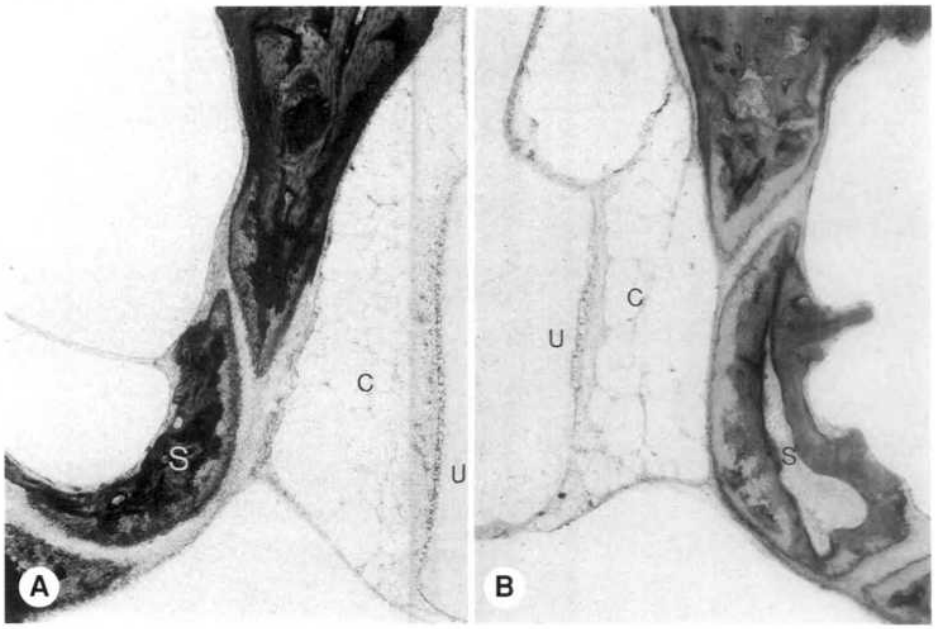

Fig 3. Two additional temporal bones from different patients displaying membranous connections (C) extending from posterior aspect of stapes footplate (S) to utriculus (U; ×33). A) Right. B) Left.

rized as follows. At a transverse level near the superior margin of the oval window, the distance from the footplate to the sacculus varied between 1.0 and 1.4 mm in the representative specimen, with the shortest distance from the additional 25 bones being 0.82 mm. The distance to the utriculus was between 0.7 and 1.4 mm, and the shortest distance was 0.38 mm. At the level of maximum horizontal width of the oval window, the sacculus and the utriculus were both 1.4 mm from the footplate, with the shortest distance from the footplate to the sacculus being 0.8 mm, and to the utriculus, 0.2 mm. At the most inferior measurement in the oval window, the distance from the footplate to the sacculus was 2.0 mm (shortest distance 0.38 mm), and to the utriculus, 1.5 mm (shortest distance 0.65 mm).

Since, within its dynamic operating range, the stapes moves in the oval window in a "piston-like" manner,[13] a significant amount of footplate movement would be required to make direct physical contact with the utriculus or sacculus sufficient to cause mechanical stimulation of the macula. The single measurement reported by Anson et al[12] of a distance from the footplate to the utriculus of 0.2 mm was much less than the 1.4 mm reported in their representative bone and was less than any measurement in our series. This narrow distance may represent an unusual finding in a selected specimen or some form of artifact of preparation in that particular section. The existence of some other anatomic factors linking the footplate to the otoliths and/or providing an additional mobile window into the labyrinth may be required for macular stimulation.

Membranous connections between the utriculus and the footplate were identified in 26% of the bones in this study. These connections appear to be extensions of the trabecular meshwork that supports otolith organs within the vestibule. There was no evidence of infectious or inflammatory processes in the bones examined in this study. The membranous connections extended through consecutive sections for a total length of 480 to 960 μm in 15 specimens. In the 19 bones with membranous connections present in only 1 section, the connections may have extended up to 480 μm, but not into the field of the successive cut. This argues that these connections are indeed membranes and not simply single strands of connective tissue.

Because of the principally horizontal orientation of the utricular macula, examination of vertically sectioned temporal bones allows for serial description of the relationship of this structure to the footplate of the stapes. Such direct measurements cannot be made from axial sections. When our data are considered with those of Anson et al,[12] the shortest distance from the footplate to the utriculus is in the posterior-superior region of the oval window. In an effort to minimize injury to the utriculus, avoidance of posterior footplate manipulation during stapes surgery is advised. The susceptibility of the utriculus to injury in this region is suggested by the report of utricular injury (an ocular tilt reaction based upon inhibition of the affected utriculus) in a patient following stapedectomy with prosthesis placement in the posterior aspect of the footplate.[6]

The membranous connections between the utriculus and the footplate identified in this study could perhaps tether the macula and thereby predispose af-

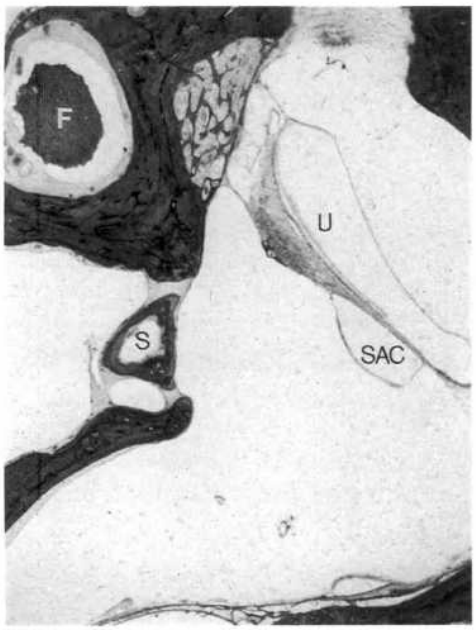

Fig 4. Right temporal bone showing relationship of posterior aspect of sacculus (SAC) to utriculus (U; ×13). Also seen on this section are facial nerve (F) and stapes footplate (S).

fected individuals to sound- and/or pressure-induced eye movements and postural imbalance. Nadol[14] reported vertigo and eye movements induced by motion of the tympanic membrane with pressure in the external canal in patients with "vestibular fibrosis" typically resulting from long-standing Meniere's disease. Temporal bone studies showed contracted membranous spaces within the labyrinth and dense fibrous adhesions between the footplate and the otoliths. It is unlikely that such connections, independent of other anatomic or physiological factors, could lead to such mechanical activation of the otoliths. If the connections alone were sufficient to induce otolith activation by these stimuli, then these signs and symptoms would probably be more commonly identified.

Erlich and Lawson[15] studied the incidence of sound-induced horizontal nystagmus in 40 patients with auditory and vestibular complaints and compared them to 10 asymptomatic subjects using electro-oculography. Pure tone stimuli from 500 to 6,000 Hz at 110 dB were delivered for 90 seconds. Thirty-six (90%) of the patients with otologic complaints and all 10 (100%) of the asymptomatic subjects had nystagmus, with slow phase eye velocity of 1°/s or greater as measured by electro-oculography, that began at an average latency of 60 to 90 seconds from the onset of the stimulus. It is difficult to infer a mechanism of sound-induced eye movements occurring at these long latencies.

Using a force platform, Ishizaki et al[16] studied the effect of low-frequency sound (25, 50, and 63 Hz at 130 to 132 dB for 30 seconds) on postural stability in 55 healthy volunteers and 152 patients with vertigo due to varied inner ear disorders. Eye movements were not recorded. In contrast to the study of Erlich and Lawson,[15] these normal subjects had normal sway with enhanced performance attributed to increased alertness from this exceedingly intense auditory stimulus. Twenty-six percent of patients with Meniere's disease, 40% of subjects with chronic otitis media and vertigo, and 26% of patients with vertigo of peripheral origin had significant sway for at least 2 of 3 frequencies tested. Ishizaki et al postulated a possible role for vestibulospinal reflexes, which could have been evoked from sound-induced otolith activation, in the origin of these responses.

Vestibular nerve afferents have been shown to respond to sound at frequencies of 200 to 400 Hz (120 to 130 dB sound pressure level).[17] Lower thresholds (90 to 100 dB) for activation of saccular afferents by sounds over the frequency range of 100 to 3,000 Hz have been reported by McCue and Guinan.[18,19] Some units were excited by condensation, and others by rarefaction clicks. Responses were identified in most units at a latency of <1.0 millisecond following onset of the tone.

Colebatch et al[20] found that patients with the Tullio phenomenon had lower thresholds for activation of vestibulocollic reflexes with clicks ipsilateral to the sensitive ear. These click-evoked responses from the sternocleidomastoid muscle appear to arise from stimulation of the sacculus. Murofushi et al[21] demonstrated in extracellular recording experiments that vestibular nerve afferents thought to innervate the sacculus responded at lower sound intensity levels than did those afferents innervating other end organs. Click-evoked myogenic potentials in the sternocleidomastoid muscle have also been reported in patients after vestibular neuritis who later manifested posterior canal benign paroxysmal positional vertigo (BPPV) on the affected side.[22] Patients who did not have posterior canal BPPV after vestibular neuritis did not have click-evoked myogenic potentials when tested. This finding implies that the sacculus is the site of origin for vestibular-evoked myogenic potentials and supports the notion that sound can result in otolith activation. It is unclear whether eye movements typically accompany these click-evoked responses.

The utriculus and sacculus are adjacent and at right angles to one another in the membranous labyrinth (Fig 4). Could the membranous connections identified between the utriculus and footplate be contributing to the diminished click-evoked vestibulocollic

reflexes seen in patients with the Tullio phenomenon? Recent experimental and modeling studies of fluid and pressure dynamics in the labyrinth indicate that such connections are likely to have only a subtle effect on pressure transmission through the system in the absence of abnormalities such as hypermobility of the stapes footplate or dehiscence of bone overlying one of the semicircular canals.[23,24]

REFERENCES

1. Tullio P. Das Ohr und die Entstehung der Sprache und Schrift. Vienna: Urban und Schwarzenberg, 1929.

2. Minor LB, Solomon D, Zinreich J, Zee DS. Sound- and/or pressure-evoked vertigo due to bone dehiscence of the superior semicircular canal. Arch Otolaryngol Head Neck Surg 1998; 124:249-58.

3. Deecke L, Mergner T, Plester D. Tullio phenomenon with torsion of the eyes and subjective tilt of the visual surround. Ann N Y Acad Sci 1981;374:650-5.

4. Vogel P, Tackmann W, Schmidt F-J. Observations on the Tullio phenomenon. J Neurol 1986;233:136-9.

5. Dieterich M, Brandt TH, Fries W. Otolith function in man. Brain 1989;112:1377-92.

6. Halmagyi GM, Gresty MA, Gibson WPR. Ocular tilt reaction with peripheral vestibular lesion. Ann Neurol 1979;6:80-3.

7. Fluur E, Mellström A. Utricular stimulation and oculomotor reactions. Laryngoscope 1970;80:1701-12.

8. Fluur E, Mellström A. Saccular stimulation and oculomotor reactions. Laryngoscope 1970;80:1713-21.

9. Curthoys IS. Eye movements produced by utricular and saccular stimulation. Aviat Space Environ Med 1987;58:A192-A197.

10. Suzuki JI, Tokumasu K, Goto K. Eye movements from single utricular nerve stimulation in the cat. Acta Otolaryngol (Stockh) 1969;68:350-62.

11. Tokumasu K, Suzuki JI, Goto K. A study of the current spread on electrical stimulation of the individual utricular and ampullary nerves. Acta Otolaryngol (Stockh) 1971;71:313-8.

12. Anson BJ, Donaldson JA, Warpeha RL, Winch TR. Symposium: Management of Meniere's Disease. II. Anatomic considerations. Laryngoscope 1965;75:1497-517.

13. Guinan JJ, Peake WT. Middle-ear characteristics of anesthetized cats. J Acoust Soc Am 1966;41:1237-61.

14. Nadol JB. Positive "fistula sign" with an intact tympanic membrane. Arch Otolaryngol 1974;100:273-8.

15. Erlich MA, Lawson W. The incidence and significance of the Tullio phenomenon in man. Otolaryngol Head Neck Surg 1980;88:630-5.

16. Ishizaki H, Pyykkö I, Aalto H, Starck J. Tullio phenomenon and postural stability: experimental study in normal subjects and patients with vertigo. Ann Otol Rhinol Laryngol 1991; 100:976-83.

17. Young ED, Fernandez C, Goldberg JM. Responses of squirrel monkey vestibular neurons to audio-frequency sound and head vibration. Acta Otolaryngol (Stockh) 1977;84:352-60.

18. McCue MP, Guinan JJ. Acoustically responsive fibers in the vestibular nerve of the cat. J Neurosci 1994;14:6058-70.

19. McCue MP, Guinan JJ. Sound evoked activity in primary afferent neurons of a mammalian vestibular system. Am J Otol 1997;18:355-60.

20. Colebatch JG, Rothwell JC, Bronstein A, Ludman H. Click-evoked vestibular activation in the Tullio phenomenon. J Neurol Neurosurg Psychiatry 1994;57:1538-40.

21. Murofushi T, Curthoys IS, Topple AN, Colebatch JG, Halmagyi GM. Responses of guinea pig primary vestibular neurons to clicks. Exp Brain Res 1995;103:174-8.

22. Murofushi T, Halmagyi GM, Yavor RA, Colebatch JG. Absent vestibular evoked myogenic potentials in vestibular neurolabyrinthitis; an indicator of inferior vestibular nerve involvement? Arch Otolaryngol 1996;122:845-8.

23. Damiano ER, Rabbitt RD. A singular perturbation model of fluid dynamics in the vestibular semicircular canal and ampulla. J Fluid Mech 1996;307:333-72.

24. Rabbitt RD, Highstein SM, Boyle R. Determinants of semicircular canal afferent response dynamics in fish. Ann N Y Acad Sci 1996;781:213-43.

EFFICACY OF AN ANTIALLERGIC DRUG ON OTITIS MEDIA WITH EFFUSION IN ASSOCIATION WITH ALLERGIC RHINITIS

AN EXPERIMENTAL STUDY

MASASHI SUZUKI, MD
OITA, JAPAN
HIDEYUKI KAWAUCHI, MD
IZUMO, JAPAN
HIDEOMI KERAKAWAUCHI, MD
OITA, JAPAN
GORO MOGI, MD
OITA, JAPAN

The effect of an antiallergic drug on the evacuation of middle ear effusion (MEE) from the tubotympanum was investigated by means of an animal model with both otitis media with effusion (OME) and allergic rhinitis. Azelastine hydrochloride (AZ), an oral antiallergic drug, was administered and the presence of MEE was investigated. Serous MEE was seen in 12 of the 13 untreated control animals on the 11th day after the experimental OME was induced, whereas MEE was detected in 9 of the 13 animals administered 1 mg/kg of AZ, but only in 4 of the 13 animals administered 2 mg/kg of AZ. In addition, the effect of AZ on MEE production was also examined in an experimental OME animal model without allergic rhinitis. Middle ear effusion was observed in all OME animals that received 2 mg/kg AZ for 5 consecutive days, before and 3 days after the experimental OME was induced. Results of the present study indicate that AZ promotes the evacuation of MEE from the tubotympanum in the OME animal model associated with nasal allergy. These data suggest that an antiallergic drug may contribute to the therapy of OME patients in association with nasal allergy indirectly, by promoting evacuation of MEE due to inhibition of type I allergic reactions in the nasopharynx.

KEY WORDS — allergic rhinitis, antiallergic drugs, azelastine, experimental studies, nasal allergy, otitis media with effusion.

INTRODUCTION

Otitis media with effusion (OME) is one of the most common causes of hearing loss in children. It is generally accepted that nasal allergic reactions cause eustachian tube obstruction, resulting in tubal dysfunction, although an allergic cause for the development of OME is still controversial. Friedman et al[1] showed that a provocative intranasal pollen challenge to allergic individuals induced eustachian tube obstruction. Walker et al[2] reported that a single histamine intranasal provocative challenge in atopic adult individuals resulted in eustachian tube obstruction. In a previous study,[3] it was clearly demonstrated that nasal IgE-mediated allergic reactions interfered with the clearance of middle ear effusion (MEE). The importance of treating allergy has been, therefore, emphasized in patients having both nasal allergy and OME. However, it is not clear whether antiallergic drugs enhance the clearance of MEE in patients with both nasal allergy and OME.

In the present study, we examined whether azelastine hydrochloride (AZ), an oral antiallergic agent,[4] actually promotes evacuation of MEE from the tubotympanum, using an experimental OME animal model with allergic rhinitis. In addition, we also investigated whether the antiallergic drug inhibits production of MEE directly or not in an OME animal model.

MATERIALS AND METHODS

Animals. Sixty-five healthy male guinea pigs (weighing 280 to 410 g) were examined. Prior to introducing each animal to the study population, microscopic observation of the eardrum and tympanometry were performed in order to confirm that the middle ear was normal. The animals were anesthetized by intraperitoneal injection of pentobarbital sodium (30 mg/kg) prior to induction of OME.

Agent. Azelastine hydrochloride in powder form was supplied by EIZAI Co Ltd, Tokyo, Japan. Pure AZ was dissolved in boiling distilled water at a concentration of 1.0 mg/mL and then cooled. A weight-dependent dose of the solution was administered to the animals.

Induction of Otitis Media With Effusion. We induced OME in the guinea pigs by instilling an immune complex (IC) into the middle ear, as described in a previous paper.[5] Briefly, the IC was prepared by mixing a high-titer guinea pig antiserum against keyhole limpet hemocyanin (KLH) with KLH at the optimal ratio. Freeze-dried IC was suspended in phosphate-buffered saline (PBS). The tympanic cavity of

From the Department of Otolaryngology, Oita Medical University, Oita (Suzuki, Kerakawauchi, Mogi), and the Department of Otolaryngology, Shimane Medical University, Izumo (Kawauchi). Japan. This research was supported by a Grant-in-Aid for Scientific Research (C) (No. 08671973) from the Ministry of Education, Japan.

CORRESPONDENCE — Goro Mogi, MD, Dept of Otolaryngology, Oita Medical University, 1-1 Idaigaoka, Hasama-cho, Oita 879-55, Japan.

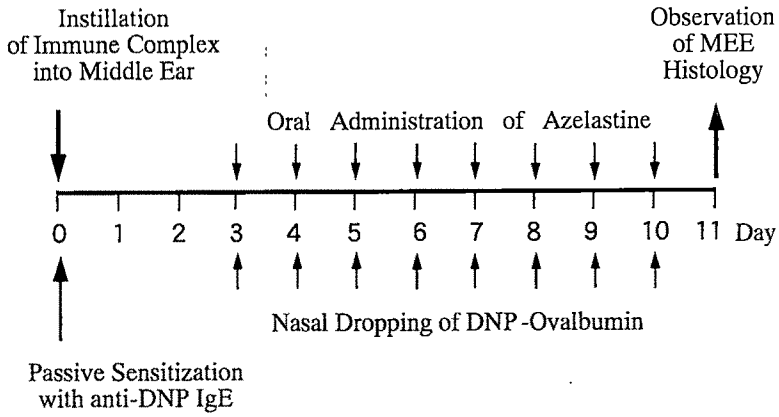

Fig 1. Schedule of experiment 1 for induction of otitis media with effusion and nasal allergy, and treatment with azelastine hydrochloride. MEE — middle ear effusion, DNP — dinitrophenyl.

1 ear was inoculated with 0.2 mg of IC in 0.1 mL sterile PBS through the tympanic bulla.

Induction of Nasal Allergic Reaction. An IgE-mediated nasal allergic reaction was induced by administration of drops of 0.5 mL dinitrophenyl-ovalbumin (DNP-OVA) in saline at a concentration of 5 mg/mL 3 times daily into both nasal cavities of the guinea pigs 3 days after IC middle ear instillation. Prior to administration of the nasal drops, the animals were injected intravenously with anti-DNP IgE serum for passive sensitization. Preparation of the antiserum has been described previously.[6]

Design of Experiment 1. To examine the effect of AZ on MEE clearance, 51 guinea pigs were divided into the following 4 groups (Fig 1 and Table 1). Thirteen animals received no treatment (group A), 13 guinea pigs were administered 1 mg/kg AZ (group B), and 13 animals were administered 2 mg/kg AZ (group C) by gastric intubation from the 3rd day to the 10th day after IC injection into the tympanic cavity. The other 12 animals were administered saline drops instead of DNP-OVA and did not receive AZ (group D). All the animals were painlessly sacrificed and the degree of MEE stagnation was determined on the 11th day after IC middle ear instillation.

Design of Experiment 2. In order to establish whether an experimental dose of AZ (2 mg/kg per day) would inhibit MEE production, 14 animals were divided into 2 groups of 7 (groups E and F; Fig 2 and Table 2). Group E received 2 mg/kg AZ for 5 consecutive days before IC middle ear inoculation. Following inoculation, the animals received treatment for 3 more days, and then were painlessly sacrificed on the 4th day after IC instillation, because the degree of MEE stagnation reaches its peak on that day. The other 7 animals served as nontreatment controls (group F).

TABLE 1. SCHEDULE FOR NASAL DROPPING OF ANTIGEN AND ORAL ADMINISTRATION OF AZELASTINE IN EXPERIMENT 1

Group	*Nasal Dropping*	*Dose of Azelastine*	*No. of Animals*
A	DNP-ovalbumin	No medicine	13
B	DNP-ovalbumin	1 mg/kg	13
C	DNP-ovalbumin	2 mg/kg	13
D	PBS	No medicine	12

DNP — dinitrophenyl, PBS — phosphate-buffered saline.

Monitoring of Otitis Media With Effusion. Each animal was monitored daily after IC middle ear instillation until the time of sacrifice by observing the eardrum and middle ear with a surgical microscope to determine the presence of MEE.

Histologic Examination. The skulls of the guinea pigs were dissected at midline as soon as the animals were sacrificed by intracardiac perfusion with periodate-lysine-paraformaldehyde (PLP) fixative. Middle ear and eustachian tube mucosae were dissected and transferred to PLP fixative for storage at 4°C overnight. The specimens were immersed in buffered disodium ethylenediamine tetra-acetate (pH 6.8) to be decalcified and then embedded in paraffin. Sections 8 μm thick were cut and stained with toluidine blue (pH 7).

Statistical Analysis. Statistical analyses were carried out by means of a nonparametric test. Fisher's exact probability test was used to examine the difference between the variables. Significant differences in the efficacy comparison of the treatment groups were established at the $p < .05$ level.

RESULTS

Incidence of Middle Ear Effusion. In a previous study,[3] the effect of nasal allergic reactions on the clearance of MEE in the OME animal model was

TABLE 2. SCHEDULE FOR ORAL ADMINISTRATION OF AZELASTINE IN EXPERIMENT 2

Group	*Medication*	*No. of Animals*
E	Azelastine 2 mg/kg	7
F	Control (no medicine)	7

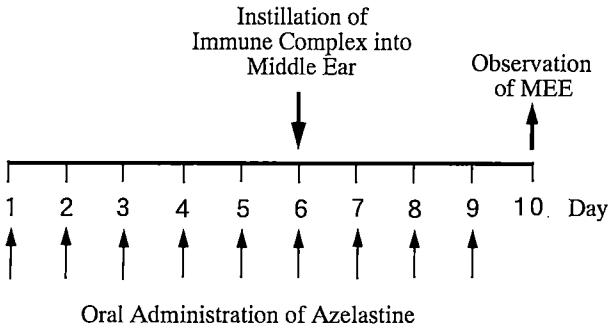

Fig 2. Schedule of experiment 2 for induction of otitis media with effusion and treatment with azelastine hydrochloride.

examined in the same manner as in the present experiment 1. The result showed that the biggest difference in positive rate of MEE between animals with an induced nasal allergic reaction (group A) and nonsensitized animals (group D) was seen on the 11th day after IC inoculation. That is the reason why the tympanic cavities were examined to determine the presence of MEE on day 11 after intratympanic inoculation of IC. Table 3 shows the results seen in groups A, B, C, and D. Twelve of the 13 animals in group A developed OME showing serous MEE, whereas in group D, MEE was seen in 3 of the 12 guinea pigs. Eleven days after IC injection, the incidence of MEE was significantly lower in group D (OME without nasal allergy) than in group A (OME with allergic rhinitis). This result indicates again that nasal allergic reactions interfere with the clearance of MEE. Middle ear effusion was detected in 9 of the 13 animals in group B and 4 of the 13 animals in group C. The number of ears having MEE was less in these 2 groups compared with that in group A, and the number in group C was close to that in group D. The incidence of MEE was also significantly lower in group C (OME with nasal allergy, 2 mg/kg AZ administered) than in group A (OME with allergic rhinitis). This outcome was thought to result from the effect of AZ on IgE-mediated reactions in the nose.

However, the possibility of a direct effect of AZ on IC-mediated OME was undeniable, because chemical mediators such as histamine and leukotrienes are released in any inflammation.[7,8] Therefore, experiment 2 was performed. Usually, MEE can be seen on day 4 after the inoculation of IC. That is why the presence of MEE was examined on the 4th day after IC injection in this experiment. As shown in Table 4, in groups E (2 mg/kg AZ) and F (no treatment), MEE was observed in all the animals on day 4 after IC inoculation into the middle ear. The result of this experiment indicates that 2 mg/kg of AZ could not inhibit production of MEE by IC-mediated OME in animals.

TABLE 3. INCIDENCE OF MIDDLE EAR EFFUSION IN EXPERIMENT 1

Group A	12/13	92%[a]
Group B	9/13	69%[b]
Group C	4/13	31%[c]
Group D	3/12	25%[d]

For a versus c and a versus d, $p < .002$.

Histology. Light microscopic findings revealed that the number of infiltrative cells and mast cells in the mucosa at the pharyngeal orifice of the eustachian tube was lower in animals without MEE than in those with MEE, regardless of the group.

DISCUSSION

The cause of OME remains controversial. Infection of the middle ear, eustachian tube dysfunction, and allergy have been considered to be major causative factors. In a previous study,[9] a high incidence of nasal allergy in OME patients was noted, suggesting a relationship between the 2 entities. Since then, allergy has been implicated as a major causative factor of OME, on the basis of an increasing number of OME patients who have developed allergic rhinitis or the presence of humoral and cellular immune response components in the effusion.[10-14] Development of MEE considered to be due to a type I allergic reaction has been demonstrated in animals.[15] In addition, recent studies[16,17] showed an elevated level of eosinophil cationic protein in the effusion and an increase of eosinophils in middle ear mucosa of patients with allergies. The studies suggested that type I allergy might play a causative role in the production of MEE in OME patients. However, a number of investigators have denied that MEE is an allergic fluid or that type I allergy is an etiologic factor in OME on the basis of laboratory findings and experimental data.[3,6,18-25] Lim and Birck,[18] Bernstein and Reisman,[14] and Sipila and Karma[19] found an insignificant number of eosinophils in MEE or middle ear mucosa from patients with OME. Many studies[14,20-24] have found that MEE does not contain a total or antigen-specific IgE antibody concentration in excess of that in matched serum. In addition, Doyle et al[25] and Tomonaga et al[26] failed to discover any MEE, even though they found allergic changes in the mucosa of animals passively sensitized and undergoing direct antigen injection into the tympanic cavity. Even if it is still unknown whether type I allergy is involved in the cause and pathogenesis of

TABLE 4. INCIDENCE OF MIDDLE EAR EFFUSION IN EXPERIMENT 2

Group E	7/7	100%
Group F	7/7	100%

OME, eustachian tube dysfunction has been implicated in type I allergic reactions of the nose. Skoner et al[27] demonstrated that intranasal challenge with house dust mites can provoke immune-mediated nasal obstruction and eustachian tube dysfunction in sensitized subjects. Ackerman et al[28] showed that intranasal insufflation of pollen caused eustachian tube obstruction in patients with pollinosis. Osur et al[29] evaluated eustachian tube function in children with ragweed allergy using the 9-step pressure-swallowing test, and they demonstrated that the development of eustachian tube obstruction was found to correlate with ragweed skin test outcome, wheal size, and daily patient symptom scores. These findings suggest that inflammation in the area of the nasopharynx and tubal orifice is important in the expression of eustachian tube dysfunction. The inflammation continuously interferes with MEE clearance, and an IgE-mediated allergic reaction of mucous membranes lining the nose, nasopharynx, and eustachian tube constitutes one of the factors that are indicative of a chronic state of disease.[3]

The present animal experiment demonstrated that AZ administration facilitated the elimination of MEE from the middle ear of guinea pigs in which OME and allergic rhinitis were induced simultaneously. Middle ear effusion developed within 4 days and disappeared spontaneously 10 to 14 days after IC injection in group D animals. However, MEE persisted in animals with allergic rhinitis, as shown in group A. In a previous study,[3] the biggest difference in the incidence of MEE between animals representative of groups A and D of the present study was seen on day 11 after IC inoculation. Therefore, MEE was investigated on day 11 in the present study. The incidence of MEE in the middle ear was less in group B and group C animals, which were administered the antiallergic drug, than in control group A. Especially, the number of ears having MEE was significantly less in group C than in group A.

In an experimental study,[26] the eustachian tube of guinea pigs in which type I allergic reactions of the nose were induced was examined histologically and functionally. The opening pressure of the eustachian tube was increased in the sensitized animals. Histologic examination showed numerous infiltrative cells and mast cells in the mucous membrane of the nasopharynx around the pharyngeal orifice. In the present study, histologic findings showed a lower number of inflammatory cells and mast cells in the mucosa at the pharyngeal orifice of the eustachian tube in animals without MEE than in those with MEE, in all groups except group D. Previous studies have demonstrated that AZ effectively inhibits allergic eosinophil infiltration and neutrophil infiltration in animals.[30,31] Therefore, the results of the present study support the theory that AZ suppresses the allergic reaction in the nasopharynx around the eustachian tube. Thus, AZ administration appeared to lead to improvement in eustachian tube function and result in clearance of MEE.

On the other hand, MEE was seen in the ears of all animals without allergic reactions that were administered 2 mg/kg of AZ for 4 consecutive days before intratympanic IC inoculation and that subsequently received the drug until the time of sacrifice. Azelastine hydrochloride inhibits not only allergic hypersensitivity reactions but also nonallergic reactions, such as release of histamine from mast cells and leukocytes, and the release of leukotrienes.[7,8] Experimental OME in the present study was thought to have been induced by a type III allergic reaction.[5] However, 2 mg/kg per day AZ, which is a high dose compared to the common dose in humans, could not suppress production of MEE. This finding indicates that the experimental dose of AZ did not alleviate the experimental OME.

The present study confirmed that an antiallergic drug could actually promote evacuation of MEE from the tubotympanum in an experimental OME animal model with allergic rhinitis. This finding might result from improvement of eustachian tube dysfunction induced by the allergic reaction. Therefore, this study suggests that antiallergic therapy might improve ear symptoms indirectly in OME patients with allergic rhinitis.

REFERENCES

1. Friedman RA, Doyle WJ, Casselbrant ML, Bluestone CD, Fireman P. Immunologic-mediated eustachian tube obstruction: a double-blind crossover study. J Allergy Clin Immunol 1983;71:442-7.

2. Walker SB, Shapiro GG, Bierman CW, et al. Induction of eustachian tube dysfunction with histamine nasal provocation. J Allergy Clin Immunol 1985;76:551-6.

3. Mogi G, Chaen T, Tomonaga K. Influence of nasal allergic reactions on the clearance of middle ear effusion. Arch Otolaryngol Head Neck Surg 1990;116:331-4.

4. McTavish D, Sorkin EM. Azelastine: a review of its pharmacodynamic and pharmacokinetic properties, and therapeutic potential. In: Sorkin EM, ed. Drugs. Auckland, New Zealand: ADIS Press Limited, 1989:1-24.

5. Suzuki M, Kawauchi H, Mogi G. Immune-mediated otitis media with effusion. Am J Otolaryngol 1988;9:199-209.

6. Tomonaga K, Kurono Y, Mogi G. Type I allergic reaction in the middle ear and eustachian tube mucosae: an experimental study. In: Lim DJ, Bluestone CD, Klein JO, Nelson JD, eds. Recent advances in otitis media. Philadelphia, Pa: BC Decker, 1988:71-5.

7. Chand N, Diamantis W, Sofia RD. Antagonism of leu-

kotrienes, calcium and histamine by azelastine. Pharmacologist 1984;26:152.

8. Diamantis W, Chand N, Harrison JE, Pillar J, Perhach JL, Sofia RD. Inhibition of release of SRS-A and its antagonism by azelastine(A), an H1 antagonist–antiallergic agent. Pharmacologist 1982;24:200.

9. Jordan R. Chronic secretory otitis media. Laryngoscope 1949;59:1002-15.

10. Tomonaga K, Kurono Y, Mogi G. The role of nasal allergy in otitis media with effusion: a clinical study. Acta Otolaryngol Suppl (Stockh) 1988(suppl 458):41-7.

11. Draper WL. Secretory otitis media in children: a study of 540 children. Laryngoscope 1967;77:636-53.

12. Phillips MJ, Knight NJ, Manning H. IgE and secretory otitis media. Lancet 1974;2:1176-8.

13. Sloyer JL Jr, Ploussard JH, Karr LJ. Otitis media in the young infant: an IgE-mediated disease? Ann Otol Rhinol Laryngol Suppl 1980;89(suppl 68):133-7.

14. Bernstein JM, Reisman ER. The role of acute hypersensitivity in secretory otitis media. Trans Am Acad Ophthalmol Otolaryngol 1973;78:120-7.

15. Miglets A. The experimental production of allergic middle ear effusion. Laryngoscope 1973;83:1355-84.

16. Hurst DS, Venge P. Levels of eosinophil cationic protein and myeloperoxidase from chronic middle ear effusion in patients with allergy and/or acute infection. Otolaryngol Head Neck Surg 1996;114:531-44.

17. Hurst DS. Association of otitis media with effusion and allergy as demonstrated by intradermal skin testing and eosinophil cationic protein levels in both middle ear effusions and mucosal biopsies. Laryngoscope 1996;106:1128-37.

18. Lim DJ, Birck H. Ultrastructural pathology of the middle ear mucosa in serous otitis media. Ann Otol Rhinol Laryngol 1971;80:838-53.

19. Sipila P, Karma P. Inflammatory cells in mucoid effusion of secretory otitis media. Acta Otolaryngol (Stockh) 1982; 94:467-72.

20. Mogi G, Maeda S, Yoshida T, Watanabe N. Role of atopic allergy in otitis media with effusion. JCEORL Allergy 1979; 41:43-9.

21. Bernstein JM, Lee J, Conboy K, Ellis E, Li P. Further observations on the role of IgE-mediated hypersensitivity in recurrent otitis media with effusion. Otolaryngol Head Neck Surg 1985;93:611-5.

22. Boedts D, Groote DG, Vuchelen JV. Atopic allergy and otitis media with effusion. Acta Otolaryngol Suppl (Stockh) 1984(suppl 414):108-14.

23. Lewis DM, Schram JL, Lim DJ, Birck HG, Gleich G. Immunoglobulin E in chronic middle ear effusions. Comparison of RIST, PRIST, and RIA techniques. Ann Otol Rhinol Laryngol 1978;87:197-201.

24. Palva T, Lehtinen T, Halmepuro L. Immunoglobulin E in mucoid secretory otitis media. ORL J Otorhinolaryngol Relat Spec 1985;47:220-3.

25. Doyle WE, Takahara T, Fireman P. The role of allergy in the pathogenesis of otitis media with effusion. Arch Otolaryngol 1985;111:502-6.

26. Tomonaga K, Chaen T, Kurono Y, Mogi G. Type I allergic reactions of the middle ear and eustachian tube: an experimental study. Auris Nasus Larynx 1990;17:121-31.

27. Skoner DP, Doyle WJ, Chamovitz AH, Fireman P. Eustachian tube obstruction after intranasal challenge with house dust mite. Arch Otolaryngol Head Neck Surg 1986;112:840-2.

28. Ackerman MN, Friedman RA, Doyle WJ, Bluestone CD, Fireman P. Antigen-induced eustachian tube obstruction: an intranasal provocative challenge test. J Allergy Clin Immunol 1984;73:604-9.

29. Osur SL, Volovitz B, Dickson S. Eustachian tube dysfunction in children with ragweed hayfever during natural pollen exposure. Allergy Proc 1989;10:133-9.

30. Chand N, Nolan K, Diamantis W, Sofia RD. Inhibition of aeroallergen-induced bronchial eosinophilia by azelastine in guinea pigs. Int Arch Allergy Immunol 1992;97:229-32.

31. Werner U, Szelenyi I. Measurement of MPO activity as a model for detection of granulocyte infiltration in different tissues. Agents Actions 1992;35:101-3.

COURSE OF IL-1β, IL-6, IL-8, AND TNF-α IN THE MIDDLE EAR FLUID OF THE GUINEA PIG OTITIS MEDIA MODEL INDUCED BY NONVIABLE *HAEMOPHILUS INFLUENZAE*

KATSURO SATO, MD
NAOBUMI NONOMURA, MD
MASAHIRO KAWANA, MD
YUICHI NAKANO, MD
NIIGATA, JAPAN

To characterize the local response in acute otitis media, courses of interleukin (IL)–1ß, IL-6, IL-8, and tumor necrosis factor (TNF) α in middle ear fluid (MEF) of the guinea pig otitis media model induced by nonviable *Haemophilus influenzae* were investigated with enzyme-linked immunosorbent assay (ELISA) kits. The IL-1ß concentration in *H influenzae*–inoculated ears peaked 24 hours after inoculation. The IL-8 concentration was significantly higher in *H influenzae*–inoculated ears than in controls 48 and 96 hours after inoculation. The TNF-α concentration in *H influenzae*–inoculated ears had an initial peak 6 hours after inoculation and had significant late increases 48 and 96 hours after inoculation. The results suggest that IL-1ß and TNF-α were produced by middle ear mucosa in the early stage of the experiment by stimulation of bacterial inoculation, which caused subsequent inflammatory cell accumulation, and that IL-8 and TNF-α were produced in the late stage by accumulating inflammatory cells.

KEY WORDS — animal model, cytokine, enzyme-linked immunosorbent assay, *Haemophilus influenzae*, middle ear fluid.

INTRODUCTION

In a large series of clinical investigations performed in the 1980s, *Haemophilus influenzae* was cultured from 20% to 23% of middle ear fluid (MEF) samples of acute otitis media (AOM) patients[1,2] and was recognized as one of the three most important pathogens (ie, *H influenzae*, *Streptococcus pneumoniae*, and *Moraxella catarrhalis*) of AOM. In addition, *H influenzae* was the most frequently cultured bacteria (15%) from children with otitis media with effusion (OME).[2] Nonviable *H influenzae* and its endotoxin caused middle ear inflammation experimentally.[3-5]

The course of local inflammatory responses in experimental otitis media has been carefully investigated with the chinchilla otitis media model induced by *S pneumoniae*[6-10] and the guinea pig model induced by *H influenzae*.[4,5] From those studies, inflammatory cells, lysozyme, and oxidative metabolic products were recognized as important inflammatory mediators in experimental AOM.

In middle ear infectious diseases, the contribution of cytokines to clinically isolated MEF has been investigated by several institutes,[11-18] and recently, similar observations on experimentally created MEF were reported.[19,20] Cytokine studies using murine otitis media models by the methodologies of immunohistochemistry[21] or in situ hybridization[22] have shown several roles of cytokines in the middle ear. Murine models are useful because murine cytokine antibodies are easily available, but the murine models are not sufficient for investigating MEF biochemically because of their limited volume of MEF obtained from an ear. We recently observed that interleukin (IL)–1ß, IL-6, IL-8, and tumor necrosis factor (TNF) α were detected in MEF of type 3 *S pneumoniae*–induced experimental otitis media in the chinchilla model with commercially available human enzyme-linked immunosorbent assay (ELISA) kits.[10]

We have been investigating the pathophysiology in the middle ear after inoculation of *H influenzae*[23] and *M catarrhalis*[24] with a similar procedure, which has been recognized as a significant animal otitis media model. We therefore sought to investigate the course of cytokines of experimentally created MEF using commercially available human ELISA kits in the guinea pig model of otitis media induced by nonviable *H influenzae*.

MATERIALS AND METHODS

A total of 24 healthy adult guinea pigs weighing 400 to 600 g with normal middle ears, ascertained by otoscopy, were used in this study. All procedures were performed on ketamine hydrochloride–anesthetized animals.

From the Department of Otolaryngology, Niigata University School of Medicine, Niigata, Japan.

Part of this study was presented at the Third Extraordinary International Symposium on Recent Advances in Otitis Media, Copenhagen, Denmark, June 1-5, 1997.

CORRESPONDENCE — Katsuro Sato, MD, Dept of Otolaryngology, Niigata University School of Medicine, 1-757 Asahi-machi, Niigata, 951-8510 Japan.

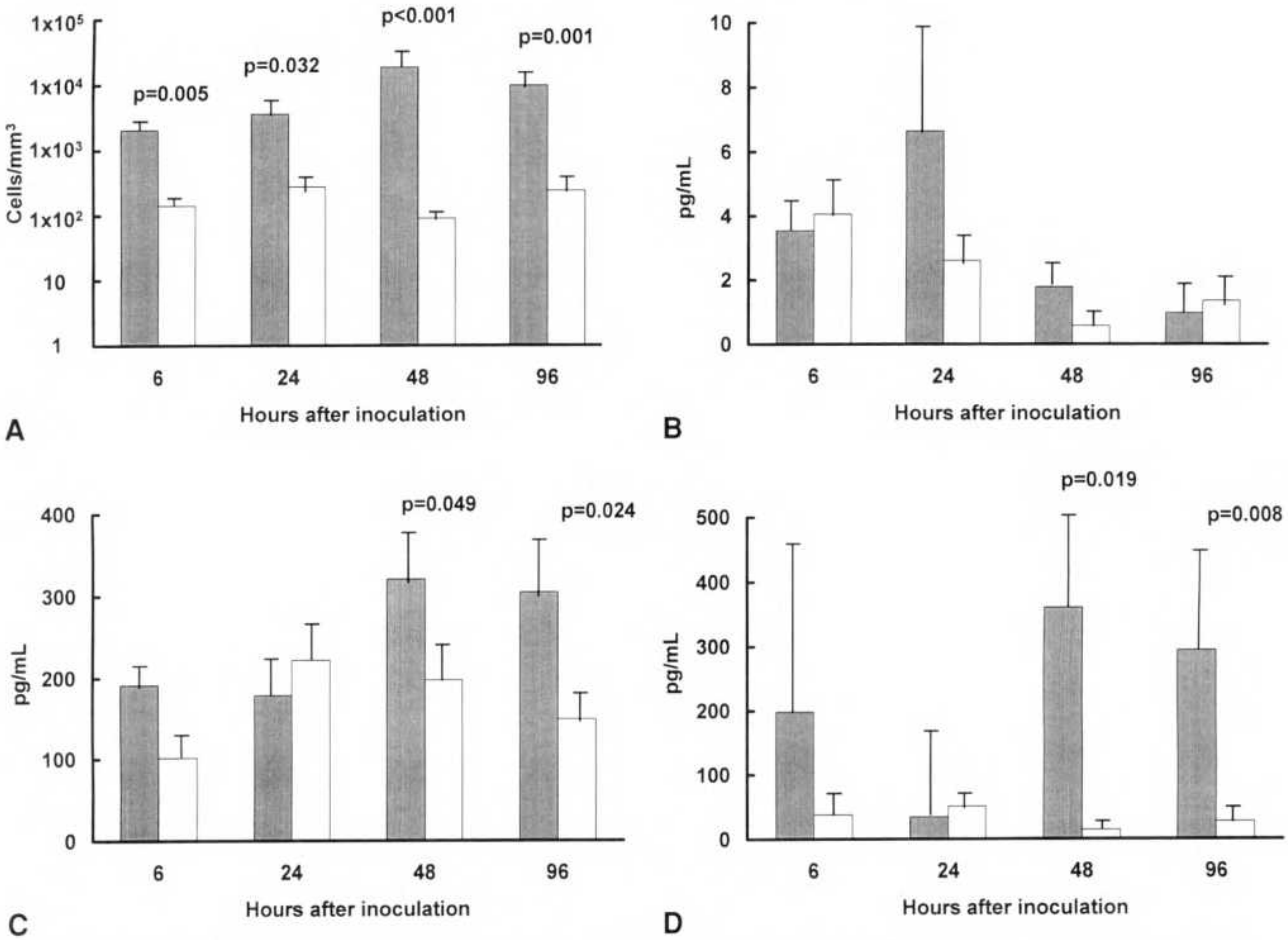

Fig 1. Results (mean ± SE) obtained from middle ear fluid specimens from 6 to 96 hours after inoculation of nonviable *Haemophilus influenzae*. Dark bars — *H influenzae*–inoculated specimens; white bars — controls inoculated with phosphate-buffered saline. A) Inflammatory cells. B) Interleukin-1β. C) Interleukin-8. D) Tumor necrosis factor α.

Nontypeable *H influenzae* biovar 2 (NCTC 8143) was preincubated on chocolate agar plates (Eiken Chemicals, Tokyo, Japan), and cultured in a liquid culture medium containing 1% triptone (Difco Laboratories, Detroit, Mich), 0.5% yeast extract (Difco), 0.15% sodium chloride (Wako Pure Chemical Industries, Osaka, Japan), 0.1% glucose (Kanto Chemical, Tokyo), 100 μg/mL ß-nicotinamide-adenine dinucleotide (ß-NAD, Wako), and 100 μg/mL hemin (Wako) for 48 hours in a shaker. Grown bacteria were collected, washed in sterile phosphate-buffered saline (PBS), pH 7.4, and killed by shaking in 0.3% formalin for 24 hours. Killed *H influenzae* were washed in sterile 0.01 mol/L PBS 3 times to remove the formalin from the bacterial cells. The killed bacteria were suspended in 0.01 mol/L PBS and adjusted to a concentration of 10^{10} cells per milliliter.

The test animals were divided into 4 groups. The right middle ear bullae of all the animals were inoculated with a volume of 0.1 mL of the bacterial suspension (10^9 cells per ear), and the left middle ear bullae were inoculated with sterile 0.01 mol/L PBS for the controls. Six animals of each group were painlessly sacrificed 6, 24, 48, and 96 hours after bacterial inoculation. A 2- to 3-mm-diameter hole was made on each harvested bulla, and the bullae were washed 3 times with 100 μL of 0.01 mol/L PBS. The washing PBS (total 300 μL) including MEF was adjusted to the same volume (500 μL) and used for cytologic and biochemical analyses. The sampled MEF was cultured on chocolate agar plates for 48 hours to confirm sterility of the fluid. Culture-positive ears were excluded from the study.

Inflammatory cell numbers in MEF (in cells per cubic millimeter) were measured with a hemocytometer. Concentrations of IL-1ß, IL-6, IL-8, and TNF-α were measured with human ELISA kits (IL-1ß, IL-6, and TNF-α, Immunotech, Marseille, France; IL-8, Dianova, Munster, Germany). Cytokine concentrations below the lowest standard concentration of the ELISA kits were described as undetectable, and the values were substituted with one half of the lowest standard concentration of the respective ELISA kits. The concentrations of IL-1ß and IL-6 of the same MEF samples were also measured with murine ELISA kits (Endogen Inc, Cambridge, Mass)

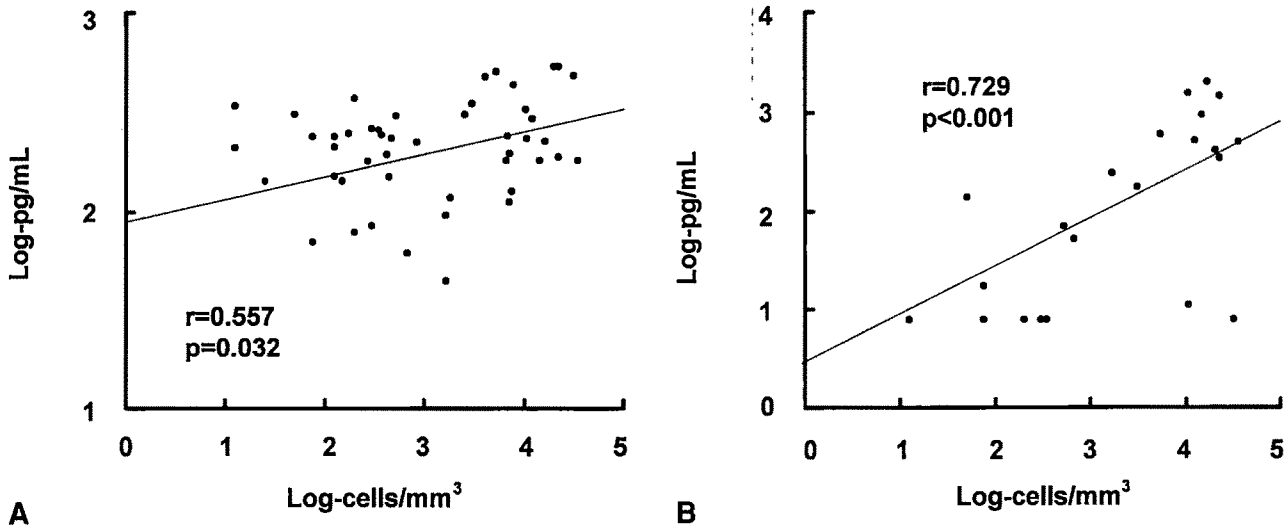

Fig 2. Correlations. A) Between inflammatory cell number and interleukin-8 concentration in middle ear fluid (MEF) (all MEF specimens in experiment). x-axis — $\log_{10}$ inflammatory cells per cubic millimeter; y-axis — $\log_{10}$ interleukin-8 in picograms per milliliter. B) Between inflammatory cell number and tumor necrosis factor α concentration in MEF (all MEF specimens in experiment). x-axis — $\log_{10}$ inflammatory cells per cubic millimeter; y-axis — $\log_{10}$ tumor necrosis factor α in picograms per milliliter.

to evaluate the cross-reactivity of the guinea pig cytokines between human and murine cytokine antibodies.

Inflammatory cell number (in cells per cubic millimeter) and cytokine concentrations (in picograms per milliliter) in MEF were log-transformed and analyzed for statistical significance by Student's paired *t*-test. The detection rates of the 4 cytokines with human (IL-1ß, IL-6, IL-8, and TNF-α) and murine (IL-1ß and IL-6) ELISA kits were compared. Correlation coefficients were calculated for evaluating the relationship of inflammatory cell numbers to cytokine concentrations in MEF. The correlations between the cytokine titers with human and murine ELISA kits of IL-1ß and IL-6 were also evaluated.

RESULTS

Inflammatory cells in MEF of *H influenzae*–inoculated ears increased as early as 6 hours after inoculation, and the concentration was significantly higher than in controls throughout the experiment (from 6 to 96 hours; 6 hours, $p = .005$; 24 hours, $p = .032$; 48 hours, $p < .001$; 96 hours, $p = .001$; Fig 1A).

We detected IL-1ß, IL-6, IL-8, and TNF-α in 79.2%, 18.8%, 97.9%, and 62.5% of total MEF samples, respectively. The IL-6 concentration was excluded from subsequent statistical analysis because of the low detection rate.

The IL-1ß concentration in *H influenzae*–inoculated ears peaked 24 hours after inoculation, although the difference between inoculated and control ears was not significant ($p = .198$; Fig 1B). The IL-8 concentration in *H influenzae*–inoculated ears peaked at 48 hours, and the concentrations in inoculated ears were significantly higher than those in control ears 48 and 96 hours after inoculation (48 hours, $p = .049$; 96 hours, $p = .024$; Fig 1C). The TNF-α level had an initial peak at 6 hours, though not significant ($p = .161$), and a later increase at 48 hours after inoculation of nonviable *H influenzae*. The differences between inoculated and control ears were statistically significant 48 and 96 hours after inoculation (48 hours, $p = .019$; 96 hours, $p = .008$; Fig 1D).

The IL-8 concentrations and inflammatory cell numbers were significantly correlated in all ears of the experiment combined ($r = .557$, $p = .032$; Fig 2A). The TNF-α concentrations of all the test ears combined were also significantly correlated with inflammatory cell numbers ($r = .729$, $p < .001$; Fig 2B). The IL-1ß concentrations and inflammatory cell numbers in MEF were not significantly correlated ($r = .489$, $p = .101$).

The detection rates of IL-1ß and IL-6 with murine ELISA kits were 85.4% and 81.3%, respectively. The titers of cytokines obtained with the human and murine ELISA kits were significantly correlated for IL-1ß ($r = .732$, $p < .001$), but not for IL-6 ($r = .466$, $p = .137$). The differences between inoculated and control ears with murine ELISA kits were not significant for either IL-1ß or IL-6 concentrations.

DISCUSSION

Investigations aiming to study the local defense response in animal otitis media models have shown that bacterial components stimulate inflammatory

mediators in MEF such as inflammatory cells, lysozyme, oxidative metabolic products, and some inflammatory cytokines that cause subsequent middle ear tissue injury.[4-7,10,23,24] To prevent acceleration of acute inflammation after bacterial infection in the course of AOM, and sequelae of AOM such as chronic OME, treatment strategies designed to reduce or neutralize the inflammatory mediators in the early stage of AOM will be required.

The contribution of cytokines to middle ear inflammation has been studied with MEF obtained from patients with otitis media.[11-16] The IL-1ß[11] and IL-6[12] MEF concentrations were higher in younger children with OME, and IL-1ß was higher in purulent MEF than in serous or mucoid MEF.[13,14] Interleukin-8 transcripts were detected in 75% of MEFs from both pediatric and adult chronic OME patients.[15] The TNF-α MEF concentration was correlated with age in children with OME.[12] Cytokines generally work in relation with other cytokines, and in middle ear diseases, both IL-1ß and TNF-α concentrations in MEF were correlated with the concentration of IL-8 in MEF obtained from children with OME.[16] In another clinical study, IL-1ß, IL-6, and TNF-α in MEF were highly correlated, and TNF-α reflected the chronicity of otitis media.[17] The IL-8 level in MEF was associated with recurrence of AOM.[18] These findings indicate that IL-1ß and IL-6 mainly act in acute stages of otitis media, whereas IL-8 and TNF-α act in chronic stages of OME, but the relationship between the cytokines in acute and chronic stages of otitis media seems not to be consistent. Cytokine concentrations in experimentally created MEF in animal otitis media models have recently been investigated with human cytokine ELISA kits, and IL-1ß was related to the presence of MEF in the chinchilla pneumococcal otitis media model.[19] We also reported that IL-1ß and IL-6, but not IL-8 or TNF-α, had a similar response to penicillin treatment of inflammatory cell influx in chinchilla MEF induced by viable *S pneumoniae*.[10] Therefore, knowledge of cytokine kinetics (ie, when, how, and which cytokines work) in AOM will lead to improved treatment strategies for preventing sequelae of AOM, such as administering cytokine antibodies or cytokine receptors in addition to antimicrobial treatment.

In the present study, the inflammatory cell numbers in MEF of *H influenzae*–inoculated ears were significantly higher than those in control ears throughout the experiment, confirming that significant acute inflammation was induced during this otitis media model. The MEF analysis up to 96 hours after inoculation in this study, to observe the acute local response, was based on a report of a nonviable *H influenzae*–induced chinchilla AOM model in which predominance of polymorphonuclear leukocytes in MEF continued until 4 to 5 days after bacterial inoculation.[3] The detection rates of IL-1ß and IL-6 in this experiment were higher with murine ELISA kits than with human ELISA kits. The high correlation between human and murine kit IL-1ß results suggests that human ELISA kits are usable for MEF obtained from guinea pigs. The IL-6 titers obtained with human and murine kits were not significantly correlated, presumably because the detection rate with the human ELISA kit was very low; hence, for IL-6, murine ELISA kits would be better for analyzing MEF obtained from guinea pigs. In this experiment, cytokine titers in MEF were analyzed directly, as previously done with MEF samples of chinchilla otitis media models,[10,19,20] but correction or normalization of the diluted MEF with albumin or total protein, as done with human MEF samples,[11-14,16,17] might reduce the variability of the samples.

The IL-8 and TNF-α concentrations in MEF were significantly higher in *H influenzae*–inoculated ears than in controls 48 and 96 hours after inoculation. The IL-1ß level in *H influenzae*–inoculated ears peaked at 24 hours after inoculation, but the difference between inoculated and control ears was not significant. These results parallel clinical findings that IL-1ß acts earlier and TNF-α acts later in the course of otitis media.[13] Interleukin-8 was supposed to play a role in the late half of this AOM model (eg, after 48 hours) in the present experiment, as clinically reported.[15,18] The IL-8 concentration and inflammatory cell concentration in MEF of this experiment showed a significant correlation that supports the theory that IL-8 is a strong chemoattractant of neutrophils. The highly significant correlation between the TNF-α concentration and the inflammatory cell concentration of all the test ears added together suggests that TNF-α acts in cooperation with inflammatory cells during the whole course of the experiment. We also observed an initial peak of TNF-α 6 hours after inoculation, suggesting that TNF-α had 2 points of action, in the early and late halves of this AOM model. The differences between bacterial-inoculated and control ears for IL-1ß at 24 hours and TNF-α at 6 hours were not significant, probably because the exact peak times of IL-1ß and TNF-α were missed.

In our unpublished data, IL-1ß and TNF-α peaked earlier than IL-6 and IL-8 in the chinchilla otitis media model induced by viable *S pneumoniae*, and the continuing increase of IL-6 in MEF 7 days after bacterial inoculation in the same experiment suggests the importance of IL-6 kinetics after 96 hours. Re-

cently, TNF-α was reported to be detected in MEF but not in serum in lipopolysaccharide-induced otitis media in the chinchilla model — a finding suggesting that TNF-α was produced locally in the middle ear by the stimulation of endotoxin.[20]

The findings reported above suggest that the early peaks of IL-1ß and TNF-α in MEF were produced locally in the middle ear mucosa by the stimulation of bacterial inoculation, which caused subsequent inflammatory cell accumulation into the middle ear. Higher levels of IL-6, IL-8, and TNF-α observed in the late half of the experiment might be produced by accumulated inflammatory cells, and the cytokines might act for more accumulation of inflammatory cells, and for stimulation of phagocytic cells to eliminate bacterial cells from the middle ear. Treatment strategies to neutralize inflammatory cytokines should be administered in the very early stages of AOM for IL-1ß and TNF-α, and in the late stages of AOM for IL-6, IL-8, and TNF-α. Further investigations using a viable bacteria–inoculated animal AOM model to study the influence of bacterial clearance on the course of inflammation will be needed to correlate the results in this experiment to the clinical course of AOM, and further studies that elucidate the correlation between cytokines in MEF and middle ear tissue injury by histologic observation in addition to biochemical analysis will be required for management of patients with chronic OME.

REFERENCES

1. Giebink GS. The microbiology of otitis media. Pediatr Infect Dis J 1989;8:S18-S20.

2. Bluestone CD, Stephenson JS, Martin LM. Ten-year review of otitis media. Pediatr Infect Dis J 1992;11:S7-S11.

3. DeMaria TF, Briggs BR, Lim DJ, Okazaki N. Experimental otitis media with effusion following middle ear inoculation of nonviable *H influenzae*. Ann Otol Rhinol Laryngol 1984;93:52-6.

4. Nonomura N, Nakano Y, Satoh Y, Fujioka O, Niijima H, Fujita M. Otitis media with effusion following inoculation of *Haemophilus influenzae* type b endotoxin. Arch Otorhinolaryngol 1986;243:31-5.

5. Nonomura N, Nakano Y, Fujioka O, Niijima H, Kawana M, Fujita M. Experimentally induced otitis media with effusion following inoculation with the outer cell wall of nontypable *Haemophilus influenzae*. Arch Otorhinolaryngol 1987;244:253-7.

6. Nonomura N, Giebink GS, Juhn SK, Harada T, Aeppli D. Pathophysiology of *Streptococcus pneumoniae* otitis media: kinetics of the middle ear biochemical and cytologic host responses. Ann Otol Rhinol Laryngol 1991;100:236-43.

7. Kawana M, Kawana C, Yokoo T, Quie PG, Giebink GS. Oxidative metabolic products released from polymorphonuclear leukocytes in middle ear during experimental otitis media. Infect Immun 1991;59:4084-8.

8. Kawana M, Kawana C, Giebink GS. Penicillin treatment accelerates middle ear inflammation in experimental pneumococcal otitis media. Infect Immun 1992;60:1908-12.

9. Sato K, Quartey MK, Liebeler CL, Giebink GS. Timing of penicillin treatment influences the course of *Streptococcus pneumoniae*–induced middle ear inflammation. Antimicrob Agents Chemother 1995;39:1896-8.

10. Sato K, Quartey MK, Liebeler CL, Le CT, Giebink GS. Roles of autolysin and pneumolysin in middle ear inflammation caused by a type 3 *Streptococcus pneumoniae* in the chinchilla otitis media model. Infect Immun 1996;64:1140-5.

11. Yellon RF, Leonard G, Marucha PT, et al. Characterization of cytokines present in middle ear effusions. Laryngoscope 1991;101:165-9.

12. Yellon RF, Leonard G, Marucha P, et al. Demonstration of interleukin 6 in middle ear effusions. Arch Otolaryngol Head Neck Surg 1992;118:745-8.

13. Himi T, Suzuki T, Kodama H, Takezawa H, Kataura A. Immunologic characteristics of cytokines in otitis media with effusion. Ann Otol Rhinol Laryngol Suppl 1992;101(suppl 157): 21-5.

14. Juhn SK, Garvis WJ, Lees CJ, Le CT, Kim CS. Determining otitis media severity from middle ear fluid analysis. Ann Otol Rhinol Laryngol Suppl 1994;103(suppl 163):43-5.

15. Takeuchi K, Maesako K, Yuta A, Sakakura Y. Interleukin-8 gene expression in middle ear effusions. Ann Otol Rhinol Laryngol 1994;103:404-7.

16. Maxwell KS, Fitzgerald JE, Burleson JA, Leonard G, Carpenter R, Kreutzer DL. Interleukin-8 expression in otitis media. Laryngoscope 1994;104:989-95.

17. Yellon RF, Doyle WJ, Whiteside TL, Diven WF, March AR, Fireman P. Cytokines, immunoglobulins, and bacterial pathogens in middle ear effusions. Arch Otolaryngol Head Neck Surg 1995;121:865-9.

18. Chonmaitree T, Patel JA, Garofalo R, et al. Role of leukotriene B4 and interleukin-8 in acute bacterial and viral otitis media. Ann Otol Rhinol Laryngol 1996;105:968-74.

19. Johnson MD, Fitzgerald JE, Leonard G, Burleson JA, Kreutzer DL. Cytokines in experimental otitis media with effusion. Laryngoscope 1994;104:191-6.

20. DeMaria TF, Murwin DM. Tumor necrosis factor during experimental lipopolysaccharide-induced otitis media. Laryngoscope 1997;107:369-72.

21. Johnson MD, Contrio A, Contrio J, Maxwell K, Leonard G, Kreutzer D. Murine model of otitis media with effusion: immunohistochemical demonstration of IL-1α antigen expression. Laryngoscope 1994;104:1143-9.

22. Bikhazi P, Ryan AF. Expression of immunoregulatory cytokines during acute and chronic middle ear immune response. Laryngoscope 1995;105:629-34.

23. Kawana M. Early inflammatory changes of the *Haemophilus influenzae*–induced experimental otitis media. Auris Nasus Larynx 1995;22:80-5.

24. Sato K. Experimental otitis media induced by nonviable *Moraxella catarrhalis* in the guinea pig model. Auris Nasus Larynx 1997;24:233-8.

LIPID PEROXIDES IN MIDDLE EAR FLUID AFTER ACUTE OTITIS MEDIA IN GUINEA PIGS

THOMAS G. TAKOUDES, MD JOSEPH HADDAD JR, MD

NEW YORK, NEW YORK

Oxygen free radical damage has been demonstrated in the middle ear mucosa of a guinea pig model of acute otitis media (AOM). Potential sources of free radicals include both neutrophils responding to infection and *Streptococcus pneumoniae*, a common AOM pathogen. This project was conducted to examine the middle ear fluid in a guinea pig model of AOM for evidence of elevated lipid peroxide (LPO) as a marker of free radical damage. Twenty-one guinea pigs were injected transtympanically with bacteria into the left (infected) middle ear cavity and sterile saline into the right (control) middle ear. Middle ear fluid was recovered on postoperative day 5. The fluid was weighed and analyzed for quantity of LPO. Results indicated an increased absolute level of LPO, as well as an increased level of LPO divided by the weight of the fluid recovered. Histologic examination confirmed leukocyte infiltration and mucosal edema that were consistent with mucosal damage. While free radical damage to the middle ear mucosa in a guinea pig model of AOM is well documented, this is the first study to demonstrate evidence of free radical damage in middle ear fluid. These results are relevant because they correlate mucosal damage with lipoperoxidation in fluid. Additionally, this serves as an important precursor to human studies, since middle ear fluid is readily available in patients with otitis media.

KEY WORDS — free radicals, lipoperoxidation, middle ear fluid, otitis media, *Streptococcus pneumoniae*.

INTRODUCTION

Free radical–mediated damage has been implicated in the pathogenesis of several disease processes, including cataract formation,[1] stroke,[2] atherosclerosis,[3] arthritis,[4] and reperfusion injury.[5] Tissue injury and subsequent disease occur when free radicals, such as the superoxide radical (O_2^-) and the hydroxyl radical (OH•), damage lipids, proteins, carbohydrate, and nucleotides.[6]

Free radicals are theorized to cause tissue damage in acute otitis media (AOM) because 2 sources of free radical production, leukocytes and bacteria, are involved in the pathogenesis of AOM. Specifically, neutrophils produce free radicals during the respiratory burst phase of contact with pathogens.[7] *Streptococcus pneumoniae* is the most common pathogen in AOM[8] and produces hydrogen peroxide, which is an important free radical mediator, as it grows.[9]

Recent investigations have demonstrated that free radical damage occurs in AOM. One study[10] conducted in this laboratory examined the mucosa that lines the middle ear cavity of a guinea pig model for free radical damage in AOM. In this experiment, *S pneumoniae* was injected into 1 middle ear cavity to cause AOM, while sterile saline was injected into the other middle ear cavity as a control. Five days later, lipid peroxide (LPO), a marker of free radical damage to cellular lipids, was noted to be elevated in the middle ear mucosa of infected ears compared to noninfected ears.[10] While that study demonstrated that pneumococcal AOM causes free radical damage to the mucosa, it did not address the possibility that free radical damage could be evidenced in the middle ear fluid that bathes the middle ear cavity.

Analysis of middle ear fluid in otitis media is important for 2 reasons. First, the fluid bathes the middle ear cavity, and thus the presence of markers of free radical damage within the fluid is likely to reflect free radical damage to the middle ear mucosa. Second, middle ear fluid is more readily available than middle ear mucosa in human studies. An understanding of the pathogenesis of middle ear fluid in an animal model is important as a precursor to human studies. Accordingly, the present study was conducted with a guinea pig model of AOM to examine middle ear fluid for evidence of LPO, which is a marker of free radical damage.

METHODS

Animal Model. Twenty-one 400- to 500-g Hartley guinea pigs (King Star, Kingston, NH) were examined and assessed otoscopically for evidence of ear disease. The animals were anesthetized with 87 mg/

From the Division of Pediatric Otolaryngology–Head and Neck Surgery, Columbia-Presbyterian Medical Center, Babies and Children's Hospital, New York, New York. This study was performed in accordance with the PHS Policy on Humane Care and Use of Laboratory Animals, the NIH *Guide for the Care and Use of Laboratory Animals*, and the Animal Welfare Act (7 U.S.C. et seq.); the animal use protocol was approved by the Institutional Animal Care and Use Committee (IACUC) of Columbia University.

CORRESPONDENCE — Joseph Haddad Jr, MD, Division of Pediatric Otolaryngology–Head and Neck Surgery, Columbia-Presbyterian Medical Center, Babies and Children's Hospital, 3959 Broadway, Babies Hospital North-5-501, New York, NY 10032.

kg of ketamine hydrochloride and 13 mg/kg of xylazine hydrochloride by intraperitoneal injection. Each ear canal was cleaned and washed with a 70% ethyl alcohol solution. With sterile technique, an operating microscope (Carl Zeiss, Germany) and a speculum were used to guide a 22-gauge lacrimal probe across the tympanic membrane (TM) and into the middle ear cavity. The right (control) middle ear cavity was injected with 100 μL of sterile phosphate buffered saline (PBS), and the left (infected) middle ear cavity was injected with 100 μL of a 10^8/mL suspension of type 3 *S pneumoniae* (American Type Culture Collection, Rockville, Md).

On postoperative day 5, animals were assessed otoscopically for the presence or absence of middle ear fluid and signs of AOM, including a bulging, red TM and purulent discharge in the ear canal. All animals were subsequently painlessly sacrificed with a 100-mg/kg intraperitoneal injection of pentobarbital. With scissors, the skin was dissected off the skull to just below the ear canal. A 26-gauge needle attached to a 1-mL syringe was then inserted through the TM, and suction was applied to remove fluid from the cavity. The fluid was rapidly weighed in a preweighed centrifuge tube, and 300 μL of cold PBS was added. Only fluid specimens that weighed more than 2.0 mg were included in the study. The sample was then homogenized in a glass grinder, sonicated, and centrifuged at 3,000*g* for 5 minutes. The supernatant was recovered and stored for subsequent biochemical analysis.

Lipid Peroxide Assay. Quantitative analysis of LPO in each specimen was performed with the Determiner LPO-CC kit (Kamiya Biomedical, Thousand Oaks, Calif). The kit uses the hemoglobin-catalyzed stoichiometric reaction of hydroperoxides with 10-N-methylcarbamoyl-3,7-dimethylamino-10 H-phenothiazine (MCDP) to form methylene blue, which is measured colorimetrically. Our samples were analyzed with the following protocol. One part of the sample was mixed with 1 part of the kit's reagent 1 and incubated for 10 minutes at 37°C. Two parts of the kit's reagent 2 were added to the sample, which was incubated for an additional 15 minutes at 37°C. The specimens were subsequently measured at the colorimetric end point of 650 nm and compared with the kit's standard (cumene hydroperoxide) that is run simultaneously. All samples were run in triplicate, and an average value for each specimen was determined. Values were expressed as nanomoles of LPO. These LPO values were then divided by the weights of the samples and multiplied by 1,000 to determine LPO per weight in nanomoles per microgram.

Histologic Study. Temporal bones from 2 control and 2 infected middle ears were fixed in 10% formalin, decalcified in 10% formic acid, dehydrated in alcohol, and embedded in paraffin with the tympanic bulla oriented toward the sectioned end of the paraffin block. The specimen was sectioned to a 5-μm thickness with a microtome. Tissue sections were then stained with hematoxylin and eosin and examined microscopically (qualitatively) for mucosal thickness and the presence of white and red blood cells in both the mucosa and fluid as indicators of inflammation.

Statistical Analysis. An unpaired Student's *t*-test was used to compare control saline-injected middle ear fluid to pneumococcus-injected middle ear fluid in the following categories: fluid weight, total LPO in each middle ear, and LPO divided by fluid weight. A p value of .05 or less was considered statistically significant.

RESULTS

Animal Model. Otoscopic evaluation of TMs at postoperative day 5 demonstrated that 21 of the 21 pneumococcus-injected ears developed clinical signs of otitis media, including a bulging, red TM. One of the 21 saline-injected control ears demonstrated purulent discharge in the middle ear and external ear canal and was excluded from the study. There were no animal deaths. Greater than 2.0 mg of purulent fluid was recovered from 18 of the 21 infected ears. Clear fluid was recovered from 12 of 20 control ears. The average amount of fluid recovered was 19.05 ± 3.17 mg in the infected group and 14.73 ± 3.62 mg in the control group ($p = .38$).

Lipid Peroxide Levels. As shown in Fig 1, total LPO levels were significantly elevated in the fluid from infected (8.77 ± 1.94 nmol) versus control (1.12 ± 0.55 nmol) middle ears ($p = .004$). Similarly, Fig 2 shows that the LPO concentration in the middle ear fluid, defined as total LPO divided by the weight of the fluid collected, was significantly elevated ($p = .001$) in infected specimens (503 ± 97 nmol of LPO per microgram of fluid) compared to control specimens (55 ± 15).

Histology. Representative sections of the tympanic bulla portion of temporal bones were analyzed for both control and infected middle ears. As is shown in Fig 3, there were significant inflammatory changes in the mucosa of the infected specimens compared to the control specimens. In particular, infected specimens showed a marked increase in submucosal edema, as well as inflammatory cell infiltration and hyperemia of the mucosa.

DISCUSSION

Free radicals are highly reactive molecular spe-

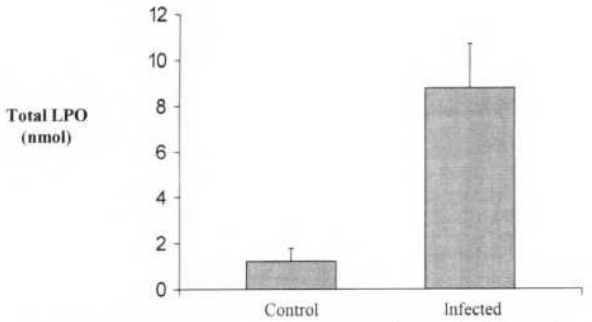

Fig 1. Lipid peroxide (LPO) level, as determined by colorimetric assay, was significantly elevated in middle ear fluid from pneumococcus-infected specimens (8.77 ± 1.94 nmol) compared to saline-injected controls (1.12 ± 0.55; p = .004). Results were measured 5 days after inoculation.

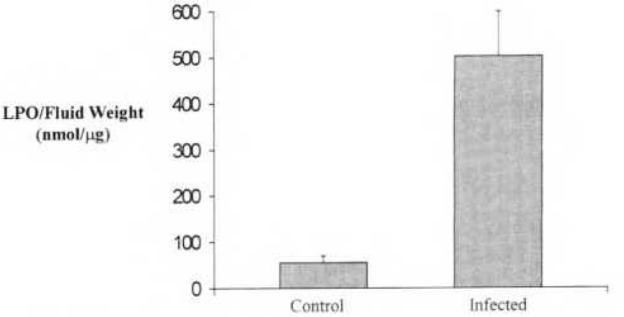

Fig 2. Lipid peroxide concentration, defined as total LPO collected divided by weight of fluid recovered from middle ear cavity, was measured on postoperative day 5. Concentration of LPO was significantly elevated in fluid from pneumococcus-infected middle ears (503 ± 97 nmol of LPO per microgram of fluid) compared to saline-injected control middle ears (55 ± 15; p = .001).

cies with unpaired outer orbital electrons that cause tissue damage by chemically modifying cellular lipids, proteins, carbohydrates, and nucleotides. Free radical damage is primarily caused by the superoxide radical (O_2) and the hydroxyl radical ($OH\bullet$). These species act upon polyunsaturated fatty acids of cellular membranes to remove a hydrogen atom from the methylene carbon of an unsaturated fatty acid. The resulting carbon-centered radical reacts with molecular oxygen to form a peroxy radical. The peroxy radical may then abstract a hydrogen atom from another unsaturated fatty acid. The result is another carbon-centered peroxy radical and an LPO. The peroxy radical may then propagate a chain reaction effect. Termination of the reaction occurs when the peroxy radical combines with a free radical scavenger. The formation of LPOs is significant because these molecules have multiple pathological effects on the cell membranes. In particular, lipid peroxidation decreases membrane fluidity and membrane barrier function and thus can lead to cell structural disorganization and possibly cell death.

Recently, there has been a keen interest in investigating the role of free radicals in the pathogenesis of AOM. A theoretic reason for this interest is the fact that there are at least 2 potential sources of free radical production in this disease. First, neutrophils produce free radicals during the respiratory burst phase of their response to infection. Second, *S pneumoniae*, which is the most common pathogen in AOM, produces hydrogen peroxide as it grows; hydrogen peroxide is a by-product of oxidative metabolism and a significant mediator of free radical damage.[11] It therefore seems likely that free radical damage would be a relevant factor in the pathogenesis of AOM.

Guinea pigs have been used in this laboratory to study free radical damage in AOM. In 1 model, *S*

Fig 3. Hematoxylin and eosin–stained sections of A) saline-injected control and B) pneumococcus-infected guinea pig temporal bones at postoperative day 5 (original ×400). Infected specimen is notable for marked submucosal edema, inflammatory cell infiltration, and hyperemia, which are absent in control specimen.

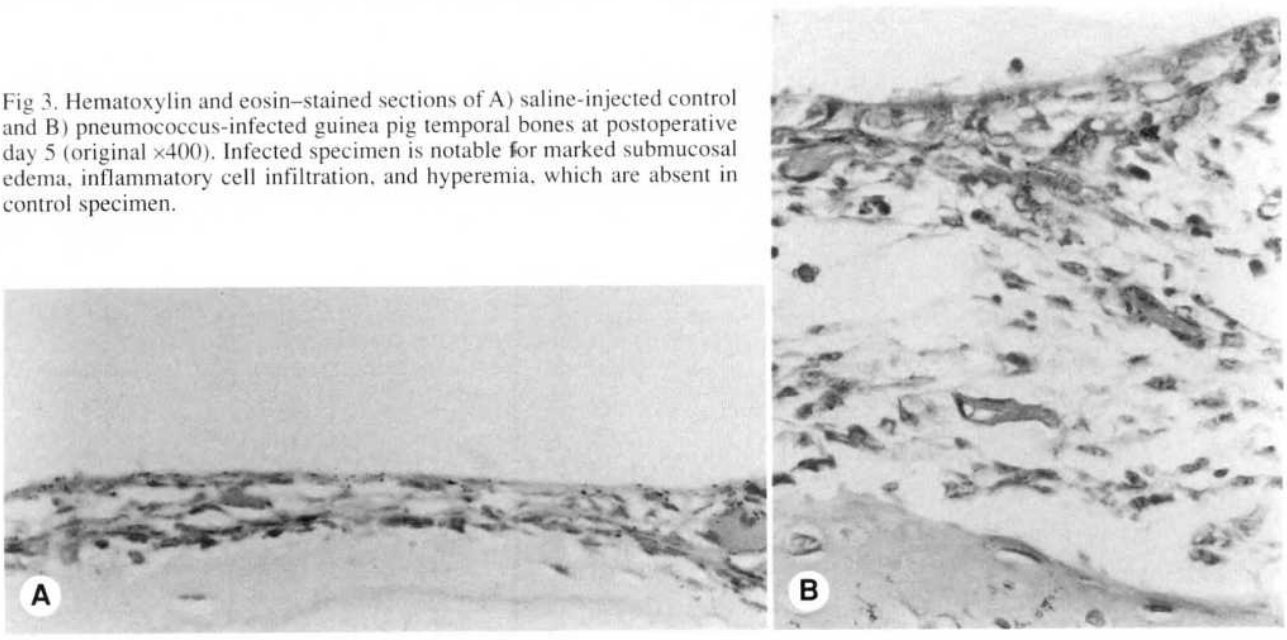

pneumoniae is injected through the TM and into the middle ear cavity to cause AOM, with saline injected into the other middle ear as a control. Previous work with this model has demonstrated elevated LPO levels, and thus free radical–mediated damage, in the mucosa of infected middle ears. Additionally, it was noted on histologic examination that the infected middle ear mucosa was 10 to 20 times thicker than the control mucosa and contained an inflammatory cell infiltrate.[10] The histologic and biochemical data from that study demonstrated that pneumococcal AOM caused significant free radical–mediated damage to the middle ear mucosa. However, that study did not address the status of free radicals within the middle ear fluid.

Middle ear fluid, which is composed of fluid and inflammatory cells that leak from capillaries at the inflammatory site, bathes the middle ear mucosa during infection. It is important to understand the role of free radicals in middle ear fluid in the pathogenesis of otitis media for 2 reasons. First, middle ear fluid bathes the mucosa, and thus, free radical activity within the fluid may reflect free radical damage to the mucosa. Second, middle ear fluid is readily available in human studies, while middle ear mucosa is not. Thus, future studies of free radical activity in human otitis media are likely to involve analysis of fluid. Accordingly, the current study was conducted to assess LPO levels in middle ear fluid in pneumococcus-infected ears compared to control ears.

The results of the current investigation demonstrate a significant elevation of LPO in the fluid recovered from pneumococcus-injected middle ears compared to saline-injected middle ears at postoperative day 5 (Figs 1 and 2). Hematoxylin and eosin–stained sections of the middle ear cavities demonstrated marked submucosal edema, inflammatory cell infiltration, and hyperemia in infected specimens compared to controls (Fig 3). Thus, the histologic examination confirmed mucosal trauma in the infected specimens. This is the first study to document evidence of free radical damage in middle ear fluid in otitis media.

There are several issues to consider when analyzing these results. First, pneumococcal otitis media, which had previously been shown to cause free radical damage to the middle ear mucosa,[10] has now been shown to cause increased LPO in middle ear fluid. Therefore, elevated LPO levels in middle ear fluid may be an indication of elevated LPO (and thus free radical damage) in the mucosa. Second, the pathogenesis of free radical damage in otitis media should be considered. Free radicals, which are likely to arise from both *Streptococcus* and neutrophils during infection, appear to attack mucosal cell membranes. The resulting thickened and dysfunctional mucosa may affect the ability of middle ear fluid to be cleared and thus increase the susceptibility of the middle ear to reinfection. Finally, these results need to be considered with respect to human disease. Although the relevance of the current study to human pathology is uncertain, it is possible that in children, the combination of *Streptococcus* infection and responding neutrophils can generate mucosa-damaging free radicals. Investigation of this hypothesis would require analysis of human middle ear fluid, since obtaining human middle ear mucosa for analysis is impractical. Therefore, the current experiment is relevant as a precursor to investigations of the role of free radicals in the pathogenesis of human otitis media.

Further research on the pathogenesis of free radicals in otitis media needs to be conducted. Specifically, animal research should be directed at decreasing the oxidative stress in AOM. While antibiotics kill bacteria that cause the disease, middle ear fluid containing damaging free radicals may remain after the infection is eradicated. The use of free radical scavengers (enzymes such as superoxide dismutase, catalase, and glutathione peroxidase), antioxidant vitamins (C, E, and beta-carotene), and other anti-inflammatory agents may decrease damage in the middle ear during infection. Their role as therapeutic options in AOM needs to be investigated. Additionally, human studies should be conducted that investigate the role of free radicals in human otitis media. The current animal study, which attempts to link analysis of middle ear fluid to previous experiments that have documented free radical damage to the mucosa, serves as an important precursor to human investigations.

REFERENCES

1. Rao NA, Thaete LG, Delmagge JM, Sevanian A. Superoxide dismutase in ocular structures. Invest Ophthalmol Vis Sci 1985;26:1778-81.

2. Krause GS, DeGracia DJ, Skjaerlund JM, Dormandy TL. Assessment of free radical induced damage in brain proteins after ischemia and reperfusion. Resuscitation 1992;23:59-69.

3. Sharma RC, Crawford DW, Kramsch DM, Sevanian A, Jiao Q. Immunolocalization of native antioxidant scavenger enzymes in early hypertensive and atherosclerotic arteries. Arterioscler Thromb 1992;12:403-15.

4. Lunec J, Halloran SP, White AG, Dormandy TL. Free radical oxidation (peroxidation) products in serum and synovial fluid in rheumatoid arthritis. J Rheumatol 1981;8:233-45.

5. Ruuge EK, Ledenev AN, Lakomkin VL, Konstantinov AA, Ksenzenko MY. Free radical metabolism in myocardium during ischemia and reperfusion. Am J Physiol 1991;261:81-6.

6. Halliwell B, Gutteridge JMC. Free radicals in biology and medicine. Oxford, England: Oxford University Press, 1989: 366-415.

7. Baggiolini M, Thelen M. The phagocytes and the respiratory burst. In: Seis H, ed. Oxidative stress: oxidants and antioxidants. London, England: Academic Press, 1991:399-420.

8. Bluestone CD, Stephenson JS, Martin LM. Ten-year review of otitis media pathogens. Pediatr Infect Dis J 1992;11 (suppl):S7-S11.

9. Joklik WK, Willet HP, Amos DB, Wilfert CM. Zinsser's microbiology. 20th ed. Norwalk, Conn: Appleton and Lange, 1992:432-3.

10. Parks RR, Huang CC, Haddad J Jr. Evidence of oxygen radical injury in experimental otitis media. Laryngoscope 1994; 104:1389-92.

11. Feher J, Cosmos G, Vereckei A. Free radical reactions in medicine. Berlin, Germany: Springer-Verlag, 1987:1-10.

EUROPEAN SOCIETY OF PEDIATRIC ORL

The Vth International Conference of the European Society of Pediatric ORL will be held July 9-13, 2000, in Graz, Austria. For more information, contact Claire Zwerina, Secretary to Prof Stammberger, ENT-Department, University Hospital, Auenbruggerplatz 20, A-8036 Graz, Austria; fax ++43/316/385/3425.

TREATMENT OF HYPERTROPHY OF THE INFERIOR TURBINATE: LONG-TERM RESULTS IN 382 PATIENTS RANDOMLY ASSIGNED TO THERAPY

DESIDERIO PASSÀLI, MD
SIENA, ITALY
MARCO ANSELMI, MD
SIENA, ITALY
MARIA LAURIELLO, MD
L'AQUILA, ITALY
LUISA BELLUSSI, MD
SIENA, ITALY

A number of surgical techniques are commonly performed to control the symptoms of inferior turbinate hypertrophy unresponsive to medical treatment. We report long-term results in 382 patients randomly assigned to receive electrocautery (62), cryotherapy (58), laser cautery (54), submucosal resection without lateral displacement (69), submucosal resection with lateral displacement (94), and turbinectomy (45). Outcomes of objective test results from rhinomanometry, acoustic rhinometry, mucociliary transport time, and secretory immunoglobulin A levels were compared to the symptom scores before and yearly after surgical treatment. These data indicate that submucosal resection with lateral displacement of the inferior turbinate results in the greatest increases in airflow and nasal respiratory function with the lowest risk of long-term complications.

KEY WORDS — inferior turbinate hypertrophy, inferior turbinate surgery.

INTRODUCTION

Although it is not a life-threatening condition, nasal obstruction can interfere with the quality of life. If septal defects are excluded, the main structures contributing to this problem are the nasal turbinates, especially the inferior turbinates. Perennial allergic rhinitis and nonallergic rhinitis are the most common noninfectious causes of mucosal swelling of the inferior turbinates and reduced nasal airflow. Untreated, these conditions may result in chronic nasal obstruction secondary to dilation of the venous sinuses or fibrosis.

Surgical procedures on the enlarged inferior, and sometimes middle, turbinates are the only effective therapy in these cases. However, selection of the procedure of choice among the several available techniques appears to be based more on personal attitudes than on a critical assessment of the treatment outcomes. In fact, since the first experiences in turbinal surgery performed by Hartmann in the 1890s,[1] the large number of surgical procedures with reported benefits suggests a lack of consensus about the most effective technique.

The principal procedures in current use are cauterization, cryosurgery, submucosal resection with or without outfracture, and resection of the turbinate. Each procedure has recognized advantages and disadvantages. We review our experience with each of these procedures in patients with inferior turbinate hypertrophy unresponsive to medical therapy. Outcomes were based on objective studies and a structured questionnaire over 4 years of follow-up.

PATIENTS AND DIAGNOSIS

Four hundred fifty-seven patients, 256 males and 201 females (age range 8 to 70 years, median age 38 years) with intractable nasal obstruction due to chronic allergic or vasomotor rhinitis and operated on at the otolaryngology clinic of the University of Siena, were included in the present study.

Patients with infectious rhinitis or marked septal deviation were excluded from the trial. Other exclusion criteria were previous nasal surgery, nasal polyps or sinusitis contributing to the nasal obstruction, significant improvement after medical treatment with steroid nasal sprays, and other major nasal diseases.

Each patient underwent the following diagnostic protocol.

1. Clinical history.
2. Clinical examination.
3. Skin tests by prick testing for grass pollen, *Parietaria*, and *Dermatophagoides* to identify hypersensitive subjects.
4. Dosage of specific immunoglobulin E (IgE) by radioallergosorbent test (RAST).

From the Department of Otorhinolaryngology, University of Siena Medical School, Siena (Passàli, Anselmi, Bellussi), and the Department of Experimental Medicine, University of L'Aquila Medical School, L'Aquila (Lauriello), Italy.

CORRESPONDENCE — Desiderio Passàli, MD, ENT Dept, University of Siena, Policlinico Le Scotte, Viale Bracci, 53100 Siena, Italy.

TABLE 1. QUESTIONNAIRE ON SYMPTOMS COLLECTED EVERY YEAR AT CONTROL

Please express your evaluation on	
Nasal obstruction during the day:	1 2 3 4 5 6
Nasal obstruction during the night:	1 2 3 4 5 6
Please express your evaluation on	
Nasal discharge during the day:	1 2 3 4 5 6
Nasal discharge during the night:	1 2 3 4 5 6
Please express your evaluation on sensation of ear fullness:	1 2 3 4 5 6

Symptoms must be graded according to a 1-6 scale where 1 is the absence of symptoms and 6 is maximum severity of symptoms.

5. Nasal decongestion test (NDT) carried out by baseline recording of nasal resistance by anterior active rhinomanometry (Rynosystem Amplifon) according to a committee report on the standardization of rhinomanometry[2]; insufflation of a local vasoconstrictor (tramazoline hydrochloride) into each nasal cavity; and repeat recording of nasal resistance after 10 minutes. If the nasal resistance normalized or improved, the test was considered positive. If the nasal resistance remained unchanged, the finding was judged to be abnormal.[2] All the patients in the present study had abnormal NDT results.

6. Acoustic rhinometry performed by a Rhinoklack RK 1000 to assess the morphologic and geometric situation of the nasal cavity.

7. Measurement of nasal mucociliary transport time (MCTT) using charcoal powder placed on the inferior turbinate. The normal time to appearance of the charcoal indicator in the oropharynx is 13 ± 2 minutes.[3] When the MCTT exceeds 30 minutes, we consider the transport to be blocked and interrupt the observation.

8. Measurement of nasal secretory immunoglobulin A (IgA). Specimens were obtained by inserting 2 small cotton swabs into each nasal fossa, between the septum and the middle and inferior turbinates, under anterior rhinoscopy. Twenty minutes later, the swabs were removed by a bayonet forceps and inserted into an insulin syringe to squeeze out the secretion into a test tube. Specimens were analyzed immediately or frozen for later analysis.[4]

9. A questionnaire on symptoms, administered every year during the controls. The patients graded the following symptoms: nasal obstruction during the day and night, nasal discharge during the day and night, and sensation of ear fullness according to a scale of 1 to 6 (Table 1).

SURGICAL TECHNIQUES

The following procedures were performed: 1) electrocautery in 62 patients (group 1); 2) cryotherapy in 58 patients (group 2); 3) laser cautery in 54 patients (group 3); 4) submucosal resection without lateral displacement in 69 patients (group 4); 5) submucosal resection with lateral displacement in 94 patients (group 5); and 6) turbinectomy in 45 patients (group 6). Patients were assigned randomly to 1 of the 6 groups. Each of the 10 surgeons involved performed a balanced percentage of each type of operation, using the same technique. Residents were not involved. All the surgical procedures were carried out under local anesthesia.

Electrocautery. Inferior turbinate cauterization was done by applying a high-frequency coagulation current via a round point electrode at constant power. The electrode was introduced as far as the posterior end of the nasal cavity. The coagulation was carried out on the medial surface from behind forward, 2 to 4 times, 10 seconds each time. At the end of the intervention, Merocel packs were placed for 3 days to avoid the formation of synechiae between the turbinate and septum.[5]

Cryotherapy. The nasal probe of a standard cryogenic unit using nitrogen protoxide was applied along the free edge and then on the medial face at 2 overlapping levels for 2 minutes, at a temperature of –80°C. Merocel nasal packing was left in each side for 3 days.[6-8]

Laser Cautery. Coagulation of the inferior turbinates was done with a carbon dioxide laser (Coherent MP20 laser) delivering 300 impulses per second at 10 to 15 W. The laser spot was the same size as the point of the electrocautery needle. A 2.5-millisecond interval was left between consecutive applications to avoid excessive carbonization. Packing was not necessary.[9,10]

Submucosal Resection Without Lateral Displacement. Through a 3- to 4-mm incision on the head of the inferior turbinate, the submucosal tissue was dissected from the medial surface and inferior edge of the bone by an elevator. Excess cavernous tissue was removed with Hartmann forceps with resection of the posterior end of the turbinate. Merocel packing was used[1,11,12] (Fig 1).

Submucosal Resection With Lateral Displacement. This procedure was identical to the above plus outfracture and lateral displacement of the turbinal bone by a Goldman displacer[13,14] (Fig 2).

Turbinectomy. After medial and upward fracture, the inferior turbinate was resected by angled scissors along the insertion close to the lateral nasal wall. Merocel nasal packing was used for 3 days to control bleeding.[15-17]

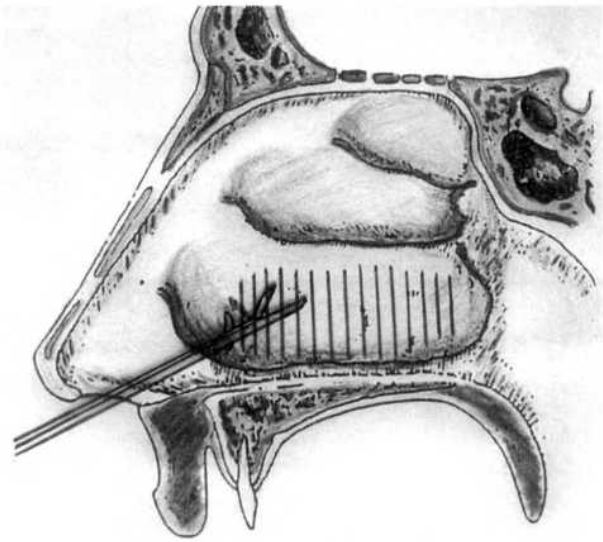

Fig 1. Submucosal resection.

In all cases, nasal packing was used without a topical antibiotic. All patients received a third-generation cephalosporin for 6 days.

RESULTS

Of the 457 patients entered into the trial, 382 were available for follow-up. The follow-up was 4 years in 100 patients, 3 years in 91 patients, 2 years in 107 patients, and 1 year in 84 patients.

Forty percent (182) of the patients admitted to the study proved to be allergic. Nasal hyperactivity was triggered by *Dermatophagoides* in 30% (54) of cases, by grass pollen in 10% (18), and by both allergens in 60% (110).

Results were assessed by measures of 1) patency as indicated by nasal resistance and acoustic rhinometry, 2) MCTT, 3) secretory IgA, 4) symptom score, and 5) complications.

Patency. Nasal resistance values are presented in Table 2. Although the average resistance values were improved in all groups from the preoperative level, the duration of improvement varied by treatment group. The least improvement occurred in the electrocautery group, and these values worsened yearly to become abnormal by the third postoperative year. Normal nasal patency was restored in the other groups and remained normal for the remainder of the study period. The greatest improvement was seen in the turbinectomy group.

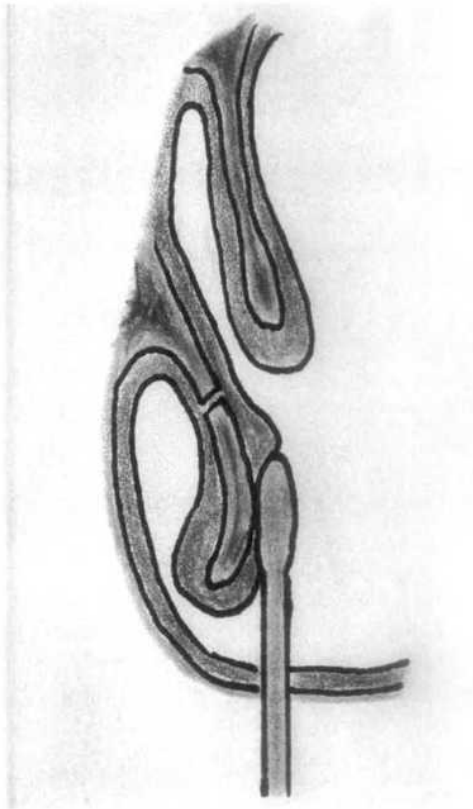

Fig 2. Lateral displacement after submucosal resection.

Table 3 shows the morphologic status of the nasal cavities as documented by acoustic rhinometric measurements. All groups had increased volume during the first year, with worsening in the electrocautery, laser, and cryotherapy groups in the later years. It is

TABLE 2. NASAL RESISTANCE VALUES MEASURED BY RHINOMANOMETRY

Time of Enrollment	*Group 1*	*Group 2*	*Group 3*	*Group 4*	*Group 5*	*Group 6*
1st y (n = 100)	0.80 ± 0.13 (n = 15)	0.6 ± 0.11 (n = 16)	0.5 ± 0.09 (n = 14)	0.45 ± 0.09 (n = 20)	0.45 ± 0.09 (n = 24)	0.3 ± 0.09 (n = 11)
2nd y (n = 91)	0.85 ± 0.14 (n = 29)	0.6 ± 0.12 (n = 30)	0.55 ± 0.10 (n = 27)	0.45 ± 0.09 (n = 39)	0.45 ± 0.09 (n = 45)	0.3 ± 0.09 (n = 21)
3rd y (n = 107)	1.2 ± 0.33 (n = 47)	0.9 ± 0.26 (n = 45)	0.5 ± 0.10 (n = 43)	0.5 ± 0.11 (n = 53)	0.45 ± 0.10 (n = 75)	0.45 ± 0.10 (n = 35)
4th y (n = 84)	1.5 ± 0.41 (n = 62)	1.0 ± 0.29 (n = 58)	0.6 ± 0.14 (n = 54)	0.5 ± 0.12 (n = 69)	0.45 ± 0.12 (n = 94)	0.45 ± 0.09 (n = 45)

Data are in pascals per cubic centimeter per second (mean ± SD). Before surgery, mean value of resistance was 1.2 Pa/cm^3 per second.

n — number of subjects (total = 382); group 1 — electrocautery; group 2 — cryotherapy; group 3 — laser cautery; group 4 — submucosal resection; group 5 — submucosal resection with displacement; group 6 — turbinectomy.

TABLE 3. NASAL VOLUMES MEASURED BY ACOUSTIC RHINOMETRY

Time of Enrollment	*Group 1*	*Group 2*	*Group 3*	*Group 4*	*Group 5*	*Group 6*
1st y (n = 100)	8.5 ± 1.35 (n = 15)	9.3 ± 1.31 (n = 16)	10.4 ± 2.52 (n = 14)	12.4 ± 2.96 (n = 20)	11.5 ± 2.34 (n = 24)	12.5 ± 1.95 (n = 11)
2nd y (n = 91)	7.3 ± 1.28 (n = 29)	7.6 ± 1.14 (n = 30)	9.5 ± 2.37 (n = 27)	10.2 ± 2.05 (n = 39)	10.2 ± 2.15 (n = 45)	11.8 ± 2.15 (n = 21)
3rd y (n = 107)	5.5 ± 1.12 (n = 47)	5.7 ± 1.03 (n = 45)	8.1 ± 2.12 (n = 43)	11.3 ± 2.14 (n = 53)	11.1 ± 2.47 (n = 75)	11.7 ± 2.03 (n = 35)
4th y (n = 84)	4.5 ± 1.13 (n = 62)	4.9 ± 0.98 (n = 58)	7.4 ± 1.93 (n = 54)	11.4 ± 2.41 (n = 69)	11.7 ± 2.39 (n = 94)	11.8 ± 2.01 (n = 45)

Data are in cubic centimeters (mean ± SD). Mean value before surgery was 4.8 cm^3.

n — number of subjects (total = 382); group 1 — electrocautery; group 2 — cryotherapy; group 3 — laser cautery; group 4 — submucosal resection; group 5 — submucosal resection with displacement; group 6 — turbinectomy.

well known that acoustic rhinometry measures the volume of the nasal cavity. So, acoustic rhinometry will register an increase of the volume of the nasal cavity after surgery, as the size of the turbinates is decreased. Unfortunately, so far, rhinometry is not well standardized, and the normal values are not established. However, we believe that the absolute values are not very important, and it is interesting to evaluate the trend during the follow-up years.

Mucociliary Transport Time. The mucociliary clearance test results are shown in Table 4. The average MCTTs remained abnormal, except in the 2 groups undergoing submucosal resection.

Secretory IgA. A similar trend occurred with secretory IgA production (Table 5). Normal average values (80 to 100 mg/100 mL) were reached only in patients receiving submucosal resection, and the combination with lateral displacement ensured the best results.

Symptom Severity Score. The trend of the symptom score in each group is recorded in Table 6 and shows the best results to be in patients treated by submucosal resection. Symptoms worsened in groups 1 and 2 in parallel to the decrease in nasal patency.

Complications. Surgical complications are presented in Fig 3 and Table 7. The patients in groups 1 to 3 had the greatest problem with chronic crusting, due to the nasal physiology impairment, and synechia formation. Bleeding was noted only in groups 4 to 6, reaching clinically troublesome levels only in group 6, with true hemorrhages in 25 patients in the total turbinectomy group.

Composite Analysis. To compare the effectiveness of the procedures, analysis of variance was performed year by year. With rhinomanometric results, a statistically significant difference ($p > .05$) was found in favor of submucosal resection with lateral displacement (group 5) in comparison with groups 1 to 3.

A statistically significant difference between group 5 and groups 1, 2, 3, and 6 was noted when the dependent variable was 1) acoustic rhinometry results ($p > .01$), 2) MCTT, or 3) symptom score ($p > .01$).

DISCUSSION

Cauterization, cryotherapy, and laser cautery are associated with only short-term benefit to airway patency and with troublesome complications of crusting. The decreased bleeding, lack of postoperative pain, and faster healing after laser cauterization do

TABLE 4. MUCOCILIARY TRANSPORT TIME

Time of Enrollment	*Group 1*	*Group 2*	*Group 3*	*Group 4*	*Group 5*	*Group 6*
1st y (n = 100)	26 ± 1.64 (n = 15)	25 ± 1.92 (n = 16)	27 ± 1.78 (n = 14)	20 ± 2.45 (n = 20)	21 ± 2.15 (n = 24)	29 ± 0.92 (n = 11)
2nd y (n = 91)	25 ± 1.57 (n = 29)	26 ± 2.15 (n = 30)	27 ± 1.67 (n = 27)	20 ± 2.36 (n = 39)	18 ± 1.83 (n = 45)	28 ± 0.73 (n = 21)
3rd y (n = 107)	26 ± 1.49 (n = 47)	26 ± 2.05 (n = 45)	26 ± 1.83 (n = 43)	18 ± 2.15 (n = 53)	15 ± 1.75 (n = 75)	29 ± 0.85 (n = 35)
4th y (n = 84)	25 ± 1.93 (n = 62)	25 ± 1.93 (n = 58)	27 ± 1.90 (n = 54)	20 ± 2.41 (n = 69)	15 ± 1.68 (n = 94)	29 ± 0.95 (n = 45)

Data are in minutes (mean ± SD). Normal value (for charcoal powder) is 13 ± 2 minutes. When time exceeds 30 minutes, we consider blockage to be present and interrupt observation.

n — number of subjects (total = 382); group 1 — electrocautery; group 2 — cryotherapy; group 3 — laser cautery; group 4 — submucosal resection; group 5 — submucosal resection with displacement; group 6 — turbinectomy.

TABLE 5. IMMUNOGLOBULIN A CONCENTRATION IN NASAL SECRETIONS

Time of Enrollment	*Group 1*	*Group 2*	*Group 3*	*Group 4*	*Group 5*	*Group 6*
1st y (n = 100)	10 ± 2.5 (n = 15)	08 ± 2.2 (n = 16)	10 ± 2.4 (n = 14)	40 ± 8.3 (n = 20)	38 ± 8.1 (n = 24)	20 ± 5.3 (n = 11)
2nd y (n = 91)	10 ± 2.6 (n = 29)	12 ± 2.8 (n = 30)	11 ± 2.2 (n = 27)	35 ± 7.8 (n = 39)	40 ± 8.6 (n = 45)	15 ± 4.6 (n = 21)
3rd y (n = 107)	12 ± 2.9 (n = 47)	10 ± 2.7 (n = 45)	15 ± 2.9 (n = 43)	40 ± 8.4 (n = 53)	52 ± 9.5 (n = 75)	18 ± 4.8 (n = 35)
4th y (n = 84)	18 ± 3.1 (n = 62)	15 ± 2.8 (n = 58)	10 ± 2.5 (n = 54)	53 ± 9.2 (n = 69)	70 ± 12.8 (n = 94)	20 ± 5.5 (n = 45)

Data are in milligrams per 100 milliliters (mean ± SD). Normal value is 80 to 100 mg/100 mL.

n — number of subjects (total = 382); group 1 — electrocautery; group 2 — cryotherapy; group 3 — laser cautery; group 4 — submucosal resection; group 5 — submucosal resection with displacement; group 6 — turbinectomy.

not justify the disadvantages such as the expensive instrumentation and risk of synechia formation. Thus, the laser offers no advantage over simpler surgical instruments.

Submucosal resection of the vascular tissue within the turbinate had the least complications (bleeding, crusting) and the greatest improvement in mucociliary clearance and local secretory IgA production. The longer hospital stay is counterbalanced by the absence of bleeding and the minimal crusting. This conservative technique gives good results in the majority of cases and is well tolerated. In Italy we also have to consider hospital stay, because, unlike in other countries, we hospitalize patients submitted to turbinate surgery.

The 94 patients who underwent submucosal resection (groups 4 and 5) obtained the best results. Adding lateral displacement (group 5) to the procedure incurred no additional risk and resulted in marginally better results. In fact, the long-lasting increase of nasal patency that returned to normal values was accompanied by the normalization of MCTT and local secretory IgA production. Therefore, we recommend the additional step of turbinate outfracture when performing submucosal resection of the turbinate tissue.

Outfracture of the inferior turbinate (without submucosal resection) does not significantly affect the nasal airway, even when combined with amputating the posterior end of the turbinate. In fact, anterior rhinomanometry showed that any eventual improvement is not predictable in any specific patient and that it is short-lasting. Therefore, outfracture, of which the advantages are the absence of risk of postoperative nasal adhesions and the minimal possibility of developing atrophic rhinitis, either produces a modest increase in nasal patency[14] or is unable to correct the nasal obstruction.

In contrast, lateral displacement of the inferior turbinate improves the results obtained with submucosal resection, because hypertrophy reduction and lateralization are both obtained. Although a statistically significant difference was not observed in the present study comparing submucosal resection with and without lateral displacement, the additional surgical step appears to improve outcome without any additional risk.

Turbinectomy had the greatest effect on nasal obstruction, but its adverse effect on the other nasal functions, as shown by poor results of MCTT and secretory IgA testing and by secondary hemorrhage, limits the usefulness of this technique. Increased air-

TABLE 6. TOTAL SYMPTOM SCORE

Time of Enrollment	*Group 1*	*Group 2*	*Group 3*	*Group 4*	*Group 5*	*Group 6*
1st y (n = 100)	20 ± 2.25 (n = 15)	21 ± 3.11 (n = 16)	21 ± 2.45 (n = 14)	10 ± 1.59 (n = 20)	10 ± 1.43 (n = 24)	21 ± 2.43 (n = 11)
2nd y (n = 91)	22 ± 2.78 (n = 29)	22 ± 3.34 (n = 30)	24 ± 3.10 (n = 27)	12 ± 1.79 (n = 39)	10 ± 1.67 (n = 45)	20 ± 2.35 (n = 21)
3rd y (n = 107)	26 ± 3.76 (n = 47)	27 ± 3.85 (n = 45)	18 ± 2.11 (n = 43)	12 ± 1.81 (n = 53)	10 ± 1.85 (n = 75)	22 ± 2.72 (n = 35)
4th y (n = 84)	26 ± 3.82 (n = 62)	25 ± 3.78 (n = 58)	20 ± 2.23 (n = 54)	12 ± 1.89 (n = 69)	10 ± 1.72 (n = 94)	20 ± 2.11 (n = 45)

Data are in points (mean ± SD). Questionnaire on symptoms was administered every year at control visit. Patients graded following symptoms: nasal obstruction and nasal discharge during day and night, and sensation of ear fullness, according to 1-6 scale.

n — number of subjects (total = 382); group 1 — electrocautery; group 2 — cryotherapy; group 3 — laser cautery; group 4 — submucosal resection; group 5 — submucosal resection with displacement; group 6 — turbinectomy.

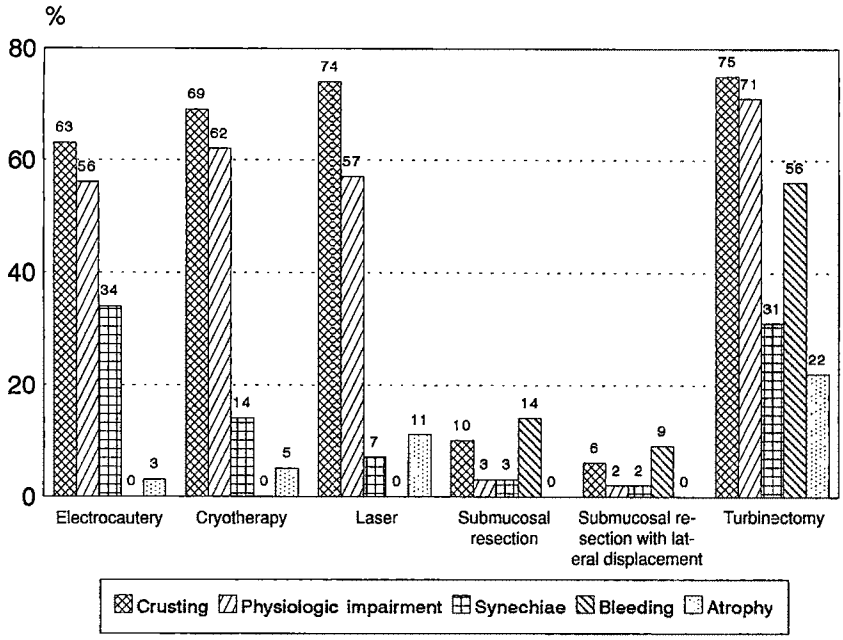

Fig 3. Percentage of patients having complications. Bleeding was absent in electrocautery, cryotherapy, and laser groups. Atrophy was absent in both submucosal resection groups.

flow and the macroturbulence produced by the modified nasal anatomy are responsible for excessive drying of nasal secretions and crusting.

Epiphora due to the damage of opening the nasolacrimal duct is uncommon, except for cases of unusual duct opening up to 10 mm below the attachment of the inferior turbinate. Dawes[18] and Cook et al[19] noted a significant risk of primary hemorrhage following turbinectomy (8.9% to 10% of patients). Salam and Wengraf[20] noted that increase of nasal airflow corresponded to a decrease in the humidifying activity of the nasal mucosa.

Although atrophic rhinitis is a rare complication of total inferior turbinectomy, more frequent in patients with poor hygiene and nutrition, many authors recommend removal of only the portion of the turbinate necessary to treat the airway obstruction, avoiding radical resection of the inferior turbinate.

CONCLUSIONS

Each procedure for surgical management of chronic nasal obstruction has been noted to have distinct advantages and drawbacks, leading to the general teaching that no one operation is "right" for every case and that surgery should be individualized. However, the results of this study permit us to draw specific conclusions. It is clear that the more conservative techniques must be preferred, because they provide effective control of the vasomotor disturbances without interfering with the anatomy and physiology of the turbinates.

These results indicate that the dramatic improvement in nasal airflow following complete resection of the inferior turbinates is accompanied by a clinically significant loss of humidification and warming of the inspired air, decreased efficiency of mucociliary transport, and reduced secretory IgA defense activities. Thus, even if turbinectomy has excellent results in relieving nasal obstruction, it is associated with more pain and crusting, long-term dryness, and an increased infection rate.

A follow-up of 4 years is long enough to evidence the normalization of physiological parameters when submucosal resection with or without lateral displacement is performed. During the same period of time, no significant improvements are observed for

TABLE 7. COMPLICATIONS

Complications	*Group 1 (n = 62)*	*Group 2 (n = 58)*	*Group 3 (n = 54)*	*Group 4 (n = 69)*	*Group 5 (n = 94)*	*Group 6 (n = 45)*
Crusting	39	40	40	7	6	34
Physiologic impairment	35	36	31	2	2	32
Synechiae	21	8	4	2	2	14
Bleeding	0	0	0	10	8	25
Atrophy	2	3	6	0	0	10

Data are numbers of subjects.

n — number of subjects; group 1 — electrocautery; group 2 — cryotherapy; group 3 — laser cautery; group 4 — submucosal resection; group 5 — submucosal resection with displacement; group 6 — turbinectomy.

nonconservative surgical procedures such as turbinectomy.

In our opinion, a longer follow-up could only confirm our results. In fact, the increased airflow and macroturbulence throughout the nasal cavities following turbinectomy represent the pathophysiological basis of nasal drying and crusting.

As a consequence, the nasal physiological impairment must be considered permanent, having as its substratum irreversible anatomic alterations.[21,22]

Without doubt, elevation of a mucoperiosteal flap is technically more difficult than full thickness excision. This may be one of the reasons many surgeons prefer total or partial turbinectomy to submucosal resection, in spite of the better nasal physiology with the latter procedure.

We recommend submucosal resection combined with lateral displacement as a first-choice operation in cases of nasal obstruction due to hypertrophy of the inferior turbinates.

ACKNOWLEDGMENT — The authors thank George A. Gates, MD, for editorial recommendations.

REFERENCES

1. Mabry RL. Inferior turbinoplasty: patient selection technique and long-term consequences. Otolaryngol Head Neck Surg 1988;98:60-6.

2. Clement PAR. Committee report on standardization of rhinomanometry. Rhinology 1984;22:151-5.

3. Passali D, Bellussi L, Bianchini-Ciampoli M, De Seta E. Our experiences in nasal mucociliary transport time determination. Acta Otolaryngol (Stockh) 1984;97:319-23.

4. Passali D. L'unità rino-faringo-tubarica. Milano, Italy: Ed. CRS Amplifon, 1985.

5. Peynegre R, Bossard B, Koskas G, Borsik M, Bovaziz A, Gilain L. La chirurgie endoscopique des cornets: etude préliminaire. Ann Otolaryngol (Paris) 1989;106:537-40.

6. Principato J. Chronic vasomotor rhinitis: cryogenic and other modes of treatment. Laryngoscope 1979;89:619-38.

7. Moore GF, Bicknell PG. A comparison of cryotherapy and submucous diathermy in vasomotor rhinitis. J Laryngol Otol 1980;94:1411-31.

8. Motta G, Pucci V, Villari G, Motta G Jr, Salzano FA. Cryosurgery in the treatment of hypertrophic chronic rhinitis. In: Passàli D, ed. Around the nose. Firenze, Italy: Conti Tipocolor, 1988.

9. Lenz H. Acht Jahre Laserchirurgie an den unteren Nasenmuscheln bei Rhinopathia vasomotoria in Form der Laserstrichkarbonisation. HNO 1985;33:422-5.

10. Fukutake T, Yamashita T, Tomoda K, Kumazawa T. Laser surgery for allergic rhinitis. Arch Otolaryngol Head Neck Surg 1986;112:1280-2.

11. House HP. Submucous resection of the inferior turbinate. Laryngoscope 1951;61:637-48.

12. Lizarraga VM, Arellano AM. Reseccion submucosa del cornete inferior oseo. Acta Otorrinolaringol Esp 1989;40:363-4.

13. Galetti G, Dallari S, Galetti R. Turbinoplasty: personal technique and long-term results. ORL 1991;53:111-5.

14. O'Flynn PE, Milford CA, MacKay IS. Multiple submucosal out-fractures of inferior turbinates. J Laryngol Otol 1990; 104:239-40.

15. Elwany S, Harrison R. Inferior turbinectomy: comparison of four techniques. J Laryngol Otol 1990;104:206-9.

16. Goode RL. Surgery of the turbinates. J Otolaryngol 1978; 7:262-8.

17. Ophir D, Schindel D, Halperin D, Marhak G. Long term follow-up of the effectiveness and safety of inferior turbinectomy. Plast Reconstr Surg 1992;90:980-4.

18. Dawes PJD. Inferior turbinectomy: is the risk of haemorrhage overstressed? J Laryngol Otol 1988;102:590-1.

19. Cook JA, McCombe AW, Jones AS. Laser treatment of rhinitis: 1 year follow-up. Clin Otolaryngol 1993;18:209-11.

20. Salam MA, Wengraf C. Concho-antropexy or total inferior turbinotomy for hypertrophy of the inferior turbinates? A prospective randomized study. J Laryngol Otol 1993;107: 1125-8.

21. Martinez SA, Nissen AJ, Stock CR, Tesmer T. Nasal turbinate resection for relief of nasal obstruction. Laryngoscope 1983;93:871-5.

22. Moore GF, Freeman TJ, Orgren JP, Yonkers AJ. Extended follow-up of total inferior turbinate resection for relief of chronic nasal obstruction. Laryngoscope 1985;95:1095-9.

ABNORMAL EXPRESSION OF THE CYSTIC FIBROSIS TRANSMEMBRANE REGULATOR IN CHRONIC SINUSITIS IN CYSTIC FIBROSIS AND NON–CYSTIC FIBROSIS PATIENTS

MARC D. COLTRERA, MD
TRACY A. GOODPASTER
SUSAN M. MATHISON, MD
ALLEN M. GOWN, MD
SEATTLE, WASHINGTON

Cystic fibrosis (CF) patients commonly suffer from chronic sinusitis. Mutations of a single gene, the cystic fibrosis transmembrane conductance regulator (CFTR) gene, have been associated with CF. Functional CFTR protein is localized to the apical cell membrane, while dysfunctional CFTR is commonly found in the cytoplasm. We undertook a preliminary immunocytochemical study of CFTR subcellular localization in CF and non-CF pediatric and adult patients using a newly developed murine monoclonal antibody, TAM. Immunostaining was evaluated for subcellular localization (cytoplasmic versus membranous) and for epithelial layer (basal versus luminal). Analysis of the predominant CFTR distribution patterns demonstrated significant differences in adult versus pediatric groups independent of whether the latter were CF or non-CF ($p < .0001$ and $p < .008$, respectively), and no significant difference between the 2 pediatric groups ($p = .70$). This suggests that the pathophysiology of pediatric sinusitis differs from that of adult sinusitis at the level of secretion production.

KEY WORDS — cystic fibrosis, cystic fibrosis transmembrane regulator, immunocytochemistry, sinusitis.

INTRODUCTION

Cystic fibrosis (CF) is the most common lethal autosomal recessive disease among Caucasians.[1] It affects up to 1:2,000, with an estimated heterozygous carrier rate of 1:25. The most common clinical abnormalities associated with CF include an abnormally high concentration of chloride in the sweat, chronic respiratory disease affecting both the upper and lower respiratory tracts, and pancreatic exocrine insufficiency. However, wide variations in CF phenotypes exist. In 1989, a single gene was found to be associated with CF, the cystic fibrosis transmembrane conductance regulator (CFTR) gene.[2-4] The CFTR gene codes for a protein that functions as a cyclic AMP–regulated chloride channel. In normal individuals, the CFTR gene product can be localized to the apical membrane of pancreatic acinar cells and duct structures underlying respiratory mucosa.[5-8] The most common CFTR mutation, ΔF508, results in a protein product that is not trafficked to the apical membrane; it remains in the cytoplasm, where it is essentially nonfunctional.[8,9] Disruption of the secretion of chloride and other codependent ions results in an increase in the viscosity of the secretory products of the affected cells. In respiratory epithelium this leads to the inspissated mucous secretions characteristic of CF patients.

Given that the carrier rate for CFTR abnormalities is so high and that other factors may also result in abnormal CFTR expression, CFTR abnormalities may be involved in the development of chronic sinusitis. Since adequate data on CFTR genotypic abnormalities in the non-CF sinus disease population do not exist, we undertook this immunocytochemical study of CFTR localization to investigate CFTR dysfunction in CF and non-CF pediatric and adult populations with chronic sinusitis requiring sinus surgery.

MATERIALS AND METHODS

Generation and Screening of Anti-CFTR Antibodies (TAM). We immunized BALB/c mice with a synthetic peptide corresponding to the C-terminus of the CFTR protein (amino acid residues 1468 to 1480) in accordance with a standard immunization protocol approved by the Animal Care Committee at the University of Washington. Briefly, 3 injections containing 100 μg of peptide were administered over a 4-week period. The spleens were removed and a fusion procedure was performed with Ag8 cells as previously described.[10] Supernatants were screened initially by an enzyme-linked immunosorbent assay using the parent C-terminus peptide, followed by immunocytochemistry on deparaffinized, formalin-fixed blocks of T84 colonic carcinoma cells, known to express high levels of CFTR.[2] Antibodies yielding a cell surface immunostaining pattern were selected for further analysis on control tissue sections.

Western Analysis. Western blots were performed

From the Departments of Otolaryngology–Head and Neck Surgery (Coltrera, Mathison) and Pathology (Goodpaster, Gown), University of Washington, Seattle, Washington. Supported by grant DK 47754 from the National Institutes of Health. This study was performed in accordance with the PHS Policy on Humane Care and Use of Laboratory Animals, the NIH *Guide for the Care and Use of Laboratory Animals*, and the Animal Welfare Act (7 U.S.C. et seq.); the animal use protocol was approved by the Institutional Animal Care and Use Committee (IACUC) of the University of Washington.

CORRESPONDENCE — Marc D. Coltrera, MD, Dept of Otolaryngology, Box 356515, University of Washington, Seattle, WA 98195.

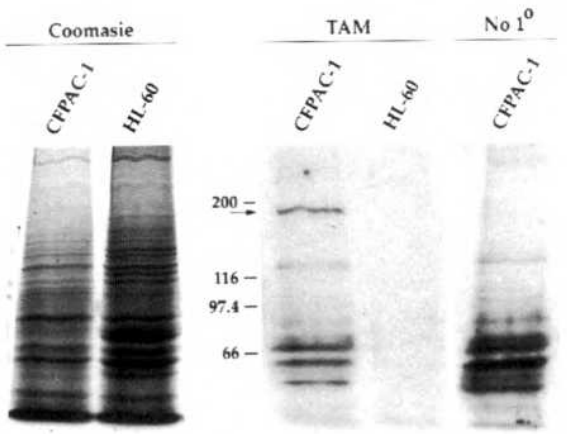

Fig 1. Western blot of TAM ascites on CFPAC-1 (positive control) and HL-60 (negative control) cell lines. Arrow points to single TAM-specific band in TAM immunostaining lanes. "No 1°" blot (no primary TAM antibody) demonstrates nonspecific secondary antibody bands on CFPAC-1 cells. Coomassie blue stain demonstrates protein from both cell types in gel.

according to standard methodology on CFPAC-1 and HL-60 cell lines.[11] The CFPAC-1 (ATCC), a metastatic human adenocarcinoma pancreatic cell line with the ΔF508 mutation, served as the positive control cell type, while HL-60 (ATCC), a leukemia cell line with no detectable levels of CFTR messenger RNA, served as the negative control cell type.[12,13] Briefly, cell lysates containing 20 μg of total protein were loaded on 7% sodium dodecyl sulfate–polyacrylamide gel electrophoresis gels, run at 32 mA for 2 hours, and transferred overnight at 4°C onto a nitrocellulose membrane. After transfer, the membrane was blocked for 2 hours in 1% casein/0.1% Tween/phosphate buffered saline (PBS) at room temperature and probed with TAM ascites (1:1,000). Secondary anti-mouse IgM–horseradish peroxidase conjugated antibody (1:3,000; Boehringer Mannheim, Indianapolis, Ind) was applied for 1 hour, and a chemiluminescent detection system was then employed according to the manufacturer's instructions (Pierce, Rockford, Ill). Controls for secondary antibody binding omitted primary TAM antibody.

Immunocytochemistry. Standard immunocytochemistry techniques were utilized as previously described.[14] Formalin-fixed tissue sections were deparaffinized, rehydrated in graded alcohols, and washed in PBS prior to incubation with TAM ascites (1:1,000) overnight at room temperature. The sections were then rinsed in PBS and incubated for 30 minutes at room temperature in biotinylated goat anti-mouse IgM (1:400; Vector Laboratories, Burlingame, Calif). Rinsed sections were then covered with Vector Elite ABC detection reagents, according to the manufacturer's instructions, at room temperature for 30 minutes. The slides were then developed in 3,3'-diaminobenzidine (DAB) with nickel chloride and counterstained with methyl green.

Selection of Sinonasal Specimens. Sixty-seven formalin-fixed, paraffin-embedded specimens of sinonasal mucosa were obtained from the archives of the University of Washington Medical Center and the Children's Hospital and Medical Center in Seattle, Washington. The 67 specimens consisted of 25 pediatric sinusitis cases (ages 8 to 15; 17 children with a diagnosis of CF on the basis of positive sweat chloride tests and history, and 8 children with negative sweat chloride tests and no known multisystem involvement) and 42 adults with no known history of CF (ages 26 to 47) who had undergone nasal polypectomies and/or formal sinus procedures.

Relationship of CFTR Expression to Histologic Features. To avoid differentiation-related changes in CFTR immunolocalization, immunostaining analysis was confined to areas of histologically normal-appearing pseudostratified columnar epithelium. All immunostained preparations were evaluated by at least 2 observers, and all tissues were scored with respect to 1) intracellular localization of the anti-CFTR immunostaining (cytoplasmic versus membranous) and 2) the location of the anti-CFTR immunostaining within the epithelium (basal versus luminal cell layers). The level of intensity of the anti-CFTR immunostaining varied significantly within specimens and could not be quantitated in a concise manner for analysis. For the purposes of statistical analysis, the "predominant" intracellular immunostaining pattern (cytoplasmic versus membranous) was defined as the immunostaining pattern found in more than 75% of the immunostained respiratory epithelial tissue, while "mixed" immunostaining scores were assigned to specimens in which neither pattern clearly predominated in this manner. Immunostaining of cells in the basal epithelial layer was scored as either present or absent.

Statistical Analysis. Statistical analysis of immunostaining pattern data included χ^2 analysis. All statistical tests were run with the Statview software package (Abacus Concepts, Berkeley, Calif).

RESULTS

TAM Antibody Western Analysis and Control Tissue Immunostaining. Following initial screening, 2 IgM antibody subclones (TAM antibody, subclones 16 and 18) were chosen for further study. Analysis by Western blot detected a single TAM-specific immunostained band around 180 to 185 kd in the CFPAC-1–positive control cells that was absent in the HL-60–negative control cells (Fig 1). The sequence-predicted size of CFTR is 170 to 175 kd, but

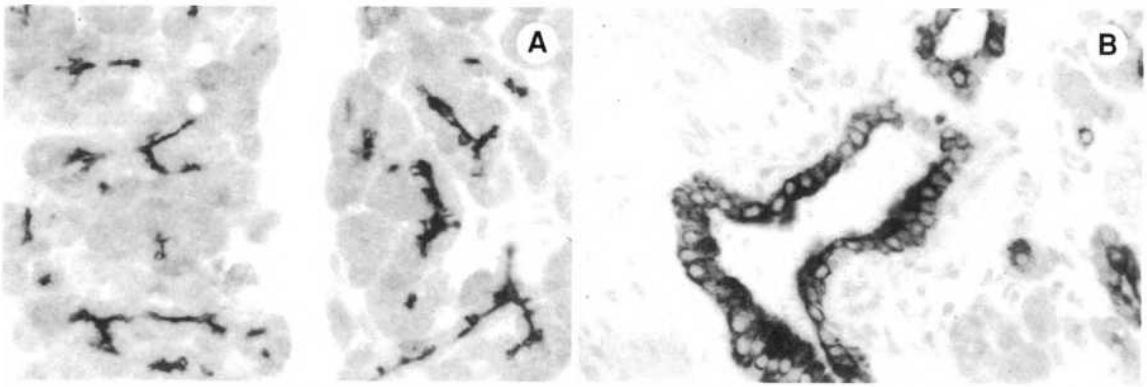

Fig 2. Normal pancreatic control tissue (original ×400). A) TAM immunostaining on pancreatic acini demonstrating apical membranous immunostaining pattern. B) TAM immunostaining on pancreatic interlobular duct demonstrating apical and basolateral immunostaining.

CFTR-specific antibodies have detected protein bands between 130 and 200 kd.[2,5,9,15,16] Both TAM antibody subclones demonstrated identical immunostaining patterns on control tissues consistent with previous studies on the intracellular distribution of CFTR.[8,17-19] Apical membranous immunostaining was found in pancreatic acinar cells, while apical and basolateral cell membrane immunostaining was noted in pancreatic ducts and respiratory ducts (Fig 2).

Sinonasal Tissue TAM Immunocytochemistry Analysis. Of the 67 sinonasal specimens, 4 of the adult specimens were excluded for lack of adequate immunostaining. Strict interpretation of all immunostaining in the specimens demonstrated frequent findings of focal cytoplasmic anti-CFTR immunostaining with or without membranous immunostaining (Fig 3). Additionally, there were areas within the specimens that demonstrated no CFTR expression immediately adjacent to areas with expression. Table 1 lists the predominant intracellular TAM immunostaining patterns. The χ^2 analyses demonstrated a statistically significant difference between the adult

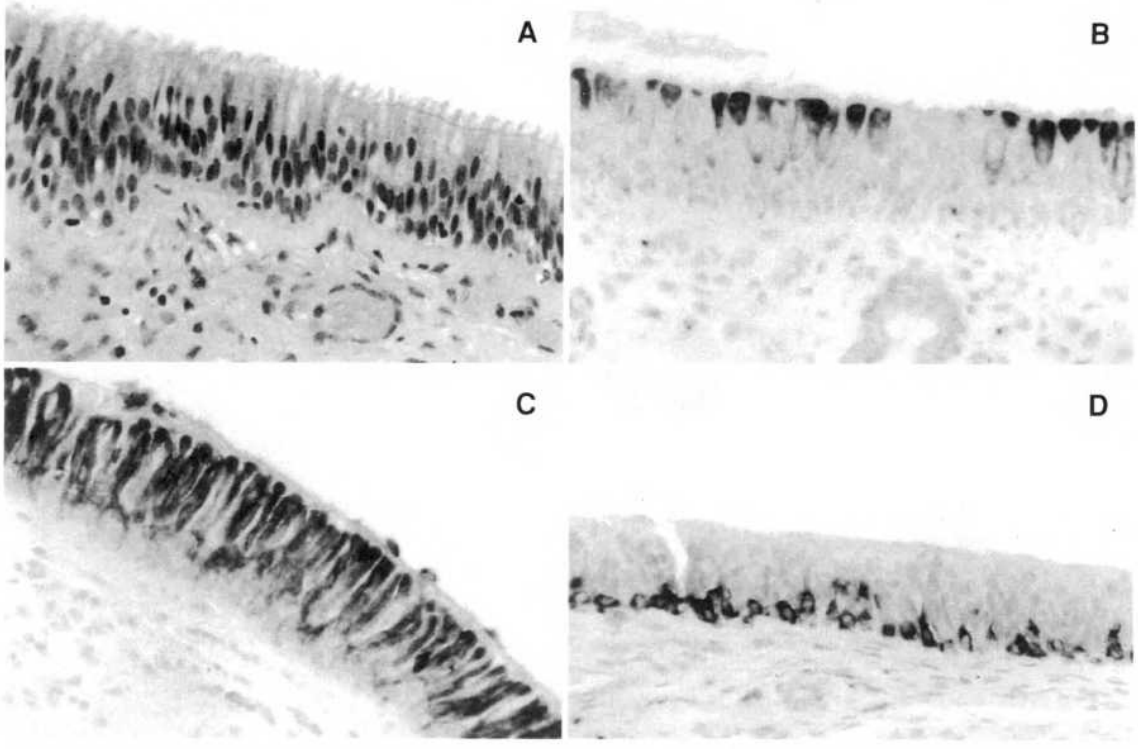

Fig 3. Sinonasal tissue (original ×400). A) Hematoxylin and eosin staining of pseudostratified ciliated columnar epithelium from maxillary sinus. B) TAM immunostaining demonstrating restricted apical membranous immunostaining pattern. C) TAM immunostaining demonstrating diffuse cytoplasmic immunostaining pattern. Note sparing of basal layer cells. D) TAM immunostaining demonstrating immunostaining pattern restricted to basal layer cells.

TABLE 1. PREDOMINANT CFTR INTRACELLULAR IMMUNOSTAINING PATTERN RESULTS

	Apical Membranous	*Mixed*	*Cytoplasmic*
Adult	28	8	2
Non-CF child	2	3	3
CF child	2	7	8

CFTR — cystic fibrosis transmembrane conductance regulator, CF — cystic fibrosis.

group and both pediatric groups (adult versus non-CF child, $p < .008$; adult versus CF child, $p < .0001$), while there was no statistically significant difference between the 2 pediatric groups (non-CF child versus CF child, $p = .70$). Scoring specimens for the presence or absence of basal epithelial cell layer immunostaining again demonstrated a difference between the adult group and the pediatric groups (adult versus non-CF child, $p < .0006$; adult versus CF child, $p < .0002$), but not between the 2 pediatric groups (non-CF child versus CF child, $p = .89$; Fig 3 and Table 2).

DISCUSSION

Normal mucus production is important for the maintenance of nasal cavity and paranasal sinus homeostasis. This fact is apparent in patients with CF, many of whom have significant sinus abnormalities and chronic sinonasal bacterial colonization that can exacerbate their lower airway problems.[20-22] The CFTR has been recognized as a major regulator of mucous fluid content.[1] The maintenance of the high CF carrier rate (1:25 in Caucasian populations of northern European descent) has led to speculations that the heterozygous state might have some selective advantage.[23] Conversely, the heterozygous state might also have deleterious effects such as recurrent sinusitis. No wide-scale genotyping of non-CF patients with chronic sinusitis has been performed, and thus, possible links between the CF heterozygous state and chronic sinusitis remain unexplored.

The CFTR is a large gene found on chromosome 7q31.[2-4] It codes for a 1480 amino acid protein that functions as a cyclic AMP–regulated chloride channel.[6] The CFTR also plays a role in cellular sodium flux, though the mechanism remains to be clarified, and is normally expressed in secretory cell types found in a wide variety of organs, including the respiratory tract, the digestive tract, and the exocrine pancreas. Subcellular localization of wild-type CFTR activity is normally restricted to the apical cellular membrane in respiratory ciliated epithelium.[8,17] Conflicting data, possibly due to the different CFTR antibodies employed, have been published on the immunocytochemical localization of CFTR, but the consensus of opinion is that in normal individuals the CFTR gene product can be immunolocalized to

TABLE 2. PRESENCE OR ABSENCE OF BASAL EPITHELIAL CELL LAYER CFTR IMMUNOSTAINING

	Positive	*Negative*
Adult	36	2
Non-CF child	4	4
CF child	8	9

the apical membrane in pancreatic acini and to the apical and basolateral membranes of glandular duct cells in a variety of tissues.[17-19] These findings are consistent with the secretory function of CFTR. Malfunction of an ion channel like CFTR can be caused by several different mechanisms, including 1) genetic abnormalities leading to a dysfunctional gene product, 2) endogenous or exogenous factors affecting protein expression, and 3) factors affecting the intracellular targeting of the gene product. Each of these mechanisms may relate to the development of chronic sinusitis in CF as well as non-CF patients.

Over 230 different alleles of CFTR have been described.[1] Genetic mutations affecting transcription, translation, transport, and protein structure have all been demonstrated to alter CFTR function. The most common mutation, ΔF508, accounts for 70% of CF cases.[2,3] The ΔF508 CFTR gene differs from the wild-type gene by a 3 base pair deletion that results in a protein product lacking a phenylalanine residue. Unlike the wild-type protein, the ΔF508 CFTR protein is not trafficked to the apical membrane, instead remaining in the cytoplasm, where it is nonfunctional. A similarly mistrafficked CF mutation, G480C (cysteine for glycine at residue 480) has been demonstrated to have normal function when the protein is redirected to the cell surface.[24] Relative CFTR dysfunction due to subcellular mislocation could potentially affect CFTR heterozygotes. Even though a single gene appears to cause CF, other genetic elements probably contribute to the variable CF phenotypes seen in patients with similar CFTR mutations.[1] These same cofactors might also affect CFTR intracellular localization and function in patients without CFTR mutations.

Exogenous factors such as cytokines can affect CFTR function. Studies have demonstrated similar cytokine profiles in both CF and non-CF patients. Cytokines described include interleukin-1 (IL-1), IL-6, IL-8, tumor necrosis factor α (TNF-α), and interferon-γ (IFN-γ).[25-31] The main source of these cytokines is the leukocytic inflammatory cells, but IL-8 and IFN-γ are also produced by the nasal mucosa in chronic sinusitis.[28,29] Studies have demonstrated the effect of cytokines on CFTR expression. Besancon et al[32] demonstrated that IFN-γ down-regulates CFTR expression in gut epithelial cell lines. In another study, IL-4 and IL-13 were found to differen-

tially regulate Cl^- secretion in gut cell lines.[33] The IL-4 Cl^- effect was related to a decrease in CFTR protein expression. These data suggest a direct causal link between cytokine expression and a maladaptive thickening in nasal secretions that could worsen the sinusitis. However, these studies did not address the issue of changes in cellular and subcellular localization of the CFTR gene product. While predominant patterns emerged in the analysis of our specimens, all specimens demonstrated mixtures of apical membranous and cytoplasmic staining. It is possible that these patterns are influenced by local populations of inflammatory cells. The specimens used in this study were inadequate for further analyses along these lines; in vitro explant cultures of sinus mucosa might be useful in addressing cytokine-CFTR issues more directly. Such studies might suggest novel treatments aimed at restoring normal sinonasal homeostasis.

Chronic sinusitis can lead to morphological changes in respiratory mucosa such as basal cell hyperplasia and squamous metaplasia. Alterations in epithelial differentiation can also affect intracellular CFTR localization. Immunofluorescence studies have demonstrated a loss of CFTR apical localization as the morphology shifts from ciliated pseudostratified epithelium to more squamoid patterns.[17,34] Analysis of our specimens concentrated solely on areas of histologically normal-appearing pseudostratified ciliated columnar epithelium in order to try to avoid differentiation-related variations. However, it is possible that subtle early changes had actually occurred in the histologically normal epithelium, resulting in a loss of the apical membrane polarity within the respiratory epithelial cells. In such a situation, CFTR mistrafficking might simply be a sensitive marker for changes in cell polarization.

In our study, the predominant subcellular staining pattern in the adult specimens was found to be apical, with a subset of specimens demonstrating nonpredominant mixed patterns. Of note, 2 adult cases demonstrated predominant cytoplasmic staining. In contrast, the predominant patterns among the CF children were mixed and cytoplasmic. While we do not have genotypic information on these CF cases, these findings are consistent with the expectation that the majority of pediatric CF cases would have ΔF508 or other mutations leading to increased cytoplasmic distribution of the CFTR protein. Interestingly, the non-CF pediatric cases demonstrated patterns similar to those of the CF pediatric group. This suggests that the pathophysiology of pediatric sinus infections, at least those severe enough to require surgery, differs from that of adult cases at the level of secretion production. It must be recognized that a child with a negative sweat chloride test might have an undiagnosed, limited form of CF and that formal analysis of the CFTR gene would be necessary to exclude this possibility. This analysis is beyond the scope of our current study.

The more frequent presence of basal epithelial anti-CFTR immunostaining in the adult specimens is an intriguing finding, but its significance is unclear. The basal layer epithelial cells are less differentiated compared with the ciliated columnar epithelial cells in the luminal cell layer. Since the basal cells are not presumed to have a secretory role in respiratory epithelium, no function for CFTR is presently recognized in these cells, and the sporadic presence of basal layer anti-CFTR immunostaining may indicate that it is not a normal condition. Additional, nonsecretory roles have been proposed for CFTR in intracellular protein trafficking and in acidification of intracellular organelles.[35,36] Up-regulation of CFTR in basal cells may reflect changes in cell homeostasis or may be an early marker of differentiation.

In conclusion, this study suggests that changes in subcellular localization of CFTR are a common finding in CF and non-CF sinusitis patients. The specimens available for analysis were submitted to pathology as "representative" tissue obtained during sinus surgeries and lack detailed anatomic information that might be important, since CFTR expression may vary depending on location in the sinonasal tract. For an in-depth understanding of the possible role of CFTR dysfunction in sinusitis, future studies should include more detailed clinical information such as disease severity (eg, limited recurrent infections versus massive polypoid sinusitis), treatment history (eg, steroid use), and clinical status at the time of surgery (eg, adequacy and recency of any presurgical drug treatment). Genetic analysis of the CFTR locus in patients with chronic sinusitis may also prove to be informative. The increasing availability of genetic testing methods may make mutational analysis of the CFTR gene in chronic sinusitis patients more feasible in the future.

ACKNOWLEDGMENT — The authors acknowledge Marilyn Skelly for valuable technical assistance.

REFERENCES

1. Aitken ML, Fiel SB. Cystic fibrosis. Dis Mon 1993;39: 1-52.

2. Riordan JR, Rommens JM, Kerem B, et al. Identification of the cystic fibrosis gene: cloning and characterization of complementary DNA. Science 1989;245:1066-73.

3. Kerem B, Rommens JM, Buchanan JA, et al. Identification of the cystic fibrosis gene: genetic analysis. Science 1989; 245:1073-80.

4. Rommens JM, Iannuzzi MC, Kerem B, et al. Identification of the cystic fibrosis gene: chromosome walking and jumping. Science 1989;245:1059-65.

5. Crawford I, Maloney PC, Zeitlin PL, et al. Immunocytochemical localization of the cystic fibrosis gene product CFTR. Proc Natl Acad Sci U S A 1991;88:9262-6.

6. Denning GM, Ostedgaard LS, Cheng SH, Smith AE, Welsh MJ. Localization of cystic fibrosis transmembrane conductance regulator in chloride secretory epithelia. J Clin Invest 1992;89:339-49.

7. Engelhardt JF, Yankaskas JR, Ernst SA, et al. Submucosal glands are the predominant site of CFTR expression in the human bronchus. Nat Genet 1992;2:240-8.

8. Puchelle E, Gaillard D, Ploton D, et al. Differential localization of the cystic fibrosis transmembrane conductance regulator in normal and cystic fibrosis airway epithelium. Am J Respir Cell Mol Biol 1992;7:485-91.

9. Cheng SH, Gregory RJ, Marshall J, et al. Defective intracellular transport and processing of CFTR is the molecular basis of most cystic fibrosis. Cell 1990;63:827-34.

10. Gown AM, Vogel AM. Monoclonal antibodies to intermediate filament proteins of human cells: unique and cross-reacting antibodies. J Cell Biol 1982;95:414-24.

11. Sarkadi B, Bauzon D, Huckle WR, et al. Biochemical characterization of the cystic fibrosis transmembrane conductance regulator in normal and cystic fibrosis epithelial cells. J Biol Chem 1992;267:2087-95.

12. Tran-Paterson R, Davin D, Krauss RD, Rado TA, Miller DM. Expression and regulation of the cystic fibrosis gene during rat liver regeneration. Am J Physiol 1992;263:C55-C60.

13. Schoumacher RA, Ram J, Iannuzzi MC, et al. A cystic fibrosis pancreatic adenocarcinoma cell line. Proc Natl Acad Sci U S A 1990;87:4012-6.

14. Coltrera MD, Wang J, Porter PL, Gown AM. Expression of platelet-derived growth factor B-chain and the platelet-derived growth factor receptor beta subunit in human breast tissue and breast carcinoma. Cancer Res 1995;55:2703-8.

15. Marino CR, Matovcik LM, Gorelick FS, Cohn JA. Localization of the cystic fibrosis transmembrane conductance regulator in pancreas. J Clin Invest 1991;88:712-6.

16. Walker J, Watson J, Holmes C, Edelman A, Banting G. Production and characterisation of monoclonal and polyclonal antibodies to different regions of the cystic fibrosis transmembrane conductance regulator (CFTR): detection of immunologically related proteins. J Cell Sci 1995;108:2433-44.

17. Brezillon S, Dupuit F, Hinnrasky J, et al. Decreased expression of the CFTR protein in remodeled human nasal epithelium from non-cystic fibrosis patients. Lab Invest 1995;72:191-200.

18. Cohn JA, Melhus O, Page LJ, Dittrich KL, Vigna SR. CFTR: development of high-affinity antibodies and localization in sweat gland. Biochem Biophys Res Commun 1991;181:36-43.

19. Kartner N, Augustinas O, Jensen TJ, Naismith AL, Riordan JR. Mislocalization of delta F508 CFTR in cystic fibrosis sweat gland. Nat Genet 1992;1:321-7.

20. Ramsey B, Richardson MA. Impact of sinusitis in cystic fibrosis. J Allergy Clin Immunol 1992;90:547-52.

21. Nishioka GJ, Cook PR. Paranasal sinus disease in patients with cystic fibrosis. Otolaryngol Clin North Am 1996;29:193-205.

22. Batsakis JG, El-Naggar AK. Cystic fibrosis and the sinonasal tract. Ann Otol Rhinol Laryngol 1996;105:329-30.

23. Quinton PM. Abnormalities in electrolyte secretion in cystic fibrosis sweat glands due to decreased anion permeability. In: Quinton PM, Martinez RJ, Hopfer U, eds. Fluid and electrolyte abnormalities in exocrine glands in cystic fibrosis. San Francisco, Calif: San Francisco Press, 1982:53-76.

24. Smit LS, Strong TV, Wilkinson DJ, et al. Missense mutation (G480C) in the CFTR gene associated with protein mislocalization but normal chloride channel activity. Hum Mol Genet 1995;4:269-73.

25. Salva PS, Doyle NA, Graham L, Eigen H, Doerschuk CM. TNF-alpha, IL-8, soluble ICAM-1, and neutrophils in sputum of cystic fibrosis patients. Pediatr Pulmonol 1996;21:11-9.

26. Davidsson A, Danielsen A, Viale G, et al. Positive identification in situ of mRNA expression of IL-6, and IL-12, and the chemotactic cytokine RANTES in patients with chronic sinusitis and polypoid disease. Clinical relevance and relation to allergy. Acta Otolaryngol (Stockh) 1996;116:604-10.

27. Pfeffer KD, Hueckstead TP, Hoidal JR. Expression and regulation of tumor necrosis factor in macrophages from cystic fibrosis patients. Am J Respir Cell Mol Biol 1993;9:511-9.

28. Takeuchi K, Yuta A, Sakakura Y. Interleukin-8 gene expression in chronic sinusitis. Am J Otolaryngol 1995;16:98-102.

29. Hamilos DL, Leung DY, Wood R, et al. Eosinophil infiltration in nonallergic chronic hyperplastic sinusitis with nasal polyposis (CHS/NP) is associated with endothelial VCAM-1 upregulation and expression of TNF-alpha. Am J Respir Cell Mol Biol 1996;15:443-50.

30. Lund VJ, Henderson B, Song Y. Involvement of cytokines and vascular adhesion receptors in the pathology of fronto-ethmoidal mucocoeles. Acta Otolaryngol (Stockh) 1993;113:540-6.

31. Richman E-J. Cytokine soup: making sense of inflammation in cystic fibrosis. Pediatr Pulmonol 1996;21:3-5.

32. Besancon F, Przewlocki G, Baró I, Hongre AS, Escande D, Edelman A. Interferon-gamma downregulates CFTR gene expression in epithelial cells. Am J Physiol 1994;267:C1398-C1404.

33. Zund G, Madara JL, Dzus AL, Awtrey CS, Colgan SP. Interleukin-4 and interleukin-13 differentially regulate epithelial chloride secretion. J Biol Chem 1996;271:7460-4.

34. Dupuit F, Kalin N, Brézillon S, Hinnrasky J, Tummler B, Puchelle E. CFTR and differentiation markers expression in non-CF and delta F 508 homozygous CF nasal epithelium. J Clin Invest 1995;96:1601-11.

35. Barasch J, Kiss B, Prince A, Saiman L, Gruenert D, Al-Awqati Q. Defective acidification of intracellular organelles in cystic fibrosis. Nature 1991;352:70-3.

36. Jacquot J, Puchelle E, Hinnrasky J, et al. Localization of the cystic fibrosis transmembrane conductance regulator in airway secretory glands. Eur Respir J 1993;6:169-76.

EFFECT OF DIESEL EXHAUST ON GUINEA PIG NASAL MUCOSA

KIYOSHI HIRUMA, MD
CHIBA, JAPAN

NOBUHISA TERADA, MD
CHIBA, JAPAN

TOYOYUKI HANAZAWA, MD
CHIBA, JAPAN

MINORU NOMOTO, MD
CHIBA, JAPAN

KEN-ICHI MAESAKO, PHD
CHIBA, JAPAN

AKIYOSHI KONNO, MD
CHIBA, JAPAN

TAKAHIRO KOBAYASHI, PHD
TSUKUBA, JAPAN

In this study using guinea pigs, we investigated the effects of diesel exhaust (DE) containing diesel exhaust particulate (DEP) on 1) vascular permeability induced by histamine, 2) nasal mucosal permeability to horseradish peroxidase (HRP), and 3) eosinophilic epithelial infiltration. The vascular permeability induced by histamine was enhanced significantly and dose-dependently in DE-exposed guinea pigs. The HRP reaction products in epithelial cells and intercellular spaces were significantly and dose-dependently increased in those guinea pigs. Eosinophil infiltration into the epithelial layer was significantly increased in guinea pigs exposed to DE containing 3.2 mg/m^3 DEP, and the reactivity of the nasal mucosa to histamine solution applied on the nasal mucosa was significantly enhanced in those guinea pigs. These findings suggest that DE may play an important role not only in promoting nasal hyperreactivity induced by the enhancement of absorption of antigen through the nasal epithelium, but also in inducing eosinophil infiltration in nasal mucosa and enhancing nasal mucosal reactivity.

KEY WORDS — diesel exhaust, diesel exhaust particulate, eosinophil infiltration, epithelial permeability, horseradish peroxidase.

INTRODUCTION

It is reported that the frequency of histamine-induced sneezing is significantly increased in diesel exhaust (DE)–exposed guinea pigs (Kobayashi, unpublished observations). This finding suggests that DE exposure increases the histamine sensitivity of nasal mucosa. So, we examined the vascular permeability of nasal mucosa caused by histamine stimulation as an index of histamine sensitivity. The vascular permeability was measured by using Evans blue. Evans blue was extracted from the tissues of guinea pigs by formamide, and the tissue content was quantified fluorimetrically. Nasal mucosal epithelium serves as a protective barrier to the passage of exogenous materials across the airway mucosa. Studies using horseradish peroxidase (HRP) have shown that changes in the mucosal barrier with an increase in transepithelial transport of HRP occur following exposure to cigarette smoke,[1] ether,[2] histamine,[3] surgical trauma,[4] or osmotic pressure.[5,6] Exposure to ubiquitous environmental agents such as diesel exhaust particulate (DEP) may also have a profound effect on the absorptive properties of the mucosal epithelium. Enhanced permeability of the nasal mucosa has been observed after administration of DEP into the nasal cavity,[7] and an increase in IgE production has been induced by inoculation of antigen with DEP.[8] To our knowledge, no published data are available on the effect of exposure to DE on nasal mucosal permeability. Eosinophil infiltration into nasal epithelium or subepithelium causes nasal mucosal hyperreactivity. Therefore, in the present study, we examined the effects of DE exposure on nasal mucosal permeability and eosinophil infiltration in nasal epithelium and subepithelium.

MATERIALS AND METHODS

Procedure. Hartley strain white male guinea pigs purchased from Japan SLC, Inc were used. They weighed 500 to 700 g at the start of the study. They were divided into 3 groups. Eight guinea pigs of each group were exposed to filtered air or to a low or high concentration of DE for 28 days in 1 of 3 identical chambers. Only filtered room air flowed through 1 chamber; and for the other 2 chambers, filtered room air was mixed with DE to achieve 1.0-mg/m^3 and 3.2-mg/m^3 concentrations of particulates (DEP) before it was passed through the chambers. The DE used in this study was generated by a light-duty (2,740 cm^3) 4-cylinder diesel engine (4jB1 type, Isuzu Automobile Co,Tokyo, Japan) using standard diesel fuel. The engine was operated at 2,000 rpm under a load of 6 torque (kilograms per meter) generated by an EDYC dynamometer (Meiden-Sya, To-

From the Department of Otorhinolaryngology, Chiba University School of Medicine, Chiba (Hiruma, Terada, Hanazawa, Nomoto, Maesako, Konno), and the Department of Basic Medical Sciences, National Institute for Environmental Studies, Tsukuba (Kobayashi), Japan.

CORRESPONDENCE — Kiyoshi Hiruma, MD, Dept of Otorhinolaryngology, Chiba University School of Medicine, 1-8-1, Inohana, Chiba City, Chiba, 260 Japan.

SUMMARY OF CHARACTERISTICS OF EXPOSURE ATMOSPHERES

		Diesel Exhaust Particulate	
	Control	*1.0 mg/m³*	*3.2 mg/m³*
Particulate (cpm)	17.7 ± 5.9	588.8 ± 81.6	2,414.2 ± 351.7
Nitrogen oxides (ppm)	0.019 ± 0.029	10.48 ± 3.02	26.07 ± 8.04
Nitric oxide (ppm)	0 ± 0.026	9.32 ± 1.88	22.55 ± 5.18
Nitrogen dioxide (ppm)	0 ± 0.003	1.39 ± 0.53	4.15 ± 1.41
Carbon dioxide (ppm)	512.3 ± 99.85	1,500.8 ± 174.6	3,033.9 ± 595.4
Sulfur dioxide (ppm)	0.063 ± 0.068	0.869 ± 0.212	1.900 ± 0.458

Data are mean ± SD.

kyo). Specifications for the engine and the dilution system have been reported elsewhere.[9] A summary of the characteristics of the exposure atmospheres is shown in the Table. The exposures to DE were performed for 12 hours (from 10:00 PM to 10:00 AM) per day, in the National Institute for Environmental Studies, Tsukuba, Japan.

Vascular Permeability Induced by Histamine. After a 28-day exposure, animals were anesthetized intraperitoneally with pentobarbital sodium. After 20 minutes, Evans blue was injected into an extrajugular vein. Immediately, 50 μL of 15-mmol/L histamine was administered into each nostril. After 10 minutes, the thorax was opened and animals were rinsed with 150 mL saline via the aorta for 2 minutes. The nostrils were opened and the septum and maxilloturbinal conchae of both sides were excised.

Extraction and Quantification of Evans Blue. The excised tissue was pressed against a filter paper to remove excess fluid and immediately weighed, placed in 2.0 mL formamide, and incubated for 24 hours in a water bath at 50°C. Colorimetric measurements were performed in a spectrophotometer at the absorption maximum for Evans blue (620 nm). For fluorescence measurements, a spectrofluorometer was used at an excitation wavelength of 620 nm. Calculations were based on external standards in formamide.

Nasal Mucosal Permeability to HRP. After a 28-day exposure, animals were anesthetized intraperitoneally with pentobarbital sodium and tracheotomy was performed. Catheter tubes were connected to disposable syringes, filled with HRP solution (50 mg HRP [type II, Sigma, St Louis, Mo] dissolved in 1 mL phosphate buffered saline [PBS]). The animals had their heads down with catheter tubes in both nostrils, so that injected HRP would not flow into the inferior airways and lungs. Eighty microliters of HRP was instilled into both nasal cavities and left for 30 minutes. At 30 minutes after HRP instillation, HRP was eliminated and blood samples were obtained by cardiac puncture. The samples were centrifuged and plasma was stored at −80°C in order to quantify the serum HRP by enzyme-linked immunosorbent assay. Animals were sacrificed painlessly, and the septal mucosa was removed for morphological evaluation of HRP uptake and transport of HRP across the nasal epithelium.

Enzyme Immunoassay. Microwell plates (96 flat-bottom wells, Nunc Inter Med) were coated with 100 μL of anti-HRP antibody (Cappel, Organon Teknika Co, Durham, NC) diluted 1,000 times with carbonate-bicarbonate buffer (pH 9.6). After incubation at 4°C overnight, the plates were washed twice with 300 μL of washing buffer (0.05% Tween 20 in 0.1-mol/L PBS). For after-coating, the plates were coated with 100 μL of 5% fetal calf serum in PBS and incubated at 37°C for 2 hours. After washing, the wells were incubated with 100 μL of standard or serum samples. As a standard, HRP was diluted 10 times with normal guinea pig serum. Serum samples were diluted 10 times with PBS. After incubation at 37°C for 2 hours and additional washing, 100 μL of 1.5 mg *o*-phenylenediamine (OPD, Wako, Japan) reagent dissolved in 1 mL phosphate citrate buffer was added as a reactive substrate and incubated for 10 minutes at room temperature in the dark. The reaction was stopped by adding 50 μL of 6N sulfuric acid. The absorbance measurements were read spectrophotometrically at 490 nm in each well (model 450 Microplate Reader, Bio-Rad).

Histologic Studies. Immediately after the animals were killed, respiratory nasal mucosa of the septum was removed and placed in 2% glutaraldehyde overnight. These specimens were washed in PBS and sliced into finer segments with a Vibratome (Series 1000, Technical Products International, Inc, St Louis, Mo). These were reacted for localization of peroxidase activity by the method of Graham and Karnovsky.[10] The tissues were then placed in a 2% solution of osmium tetroxide for 1 hour, dehydrated with a series of ethanol buffers, and embedded in Spur (Nissin EM, Tokyo). Sections were cut with an ultramicrotome; 1-μm-thick sections were prepared from each block and stained with toluidine blue for light microscopy. Thin sections from such blocks were cut, stained with uranyl acetate, and examined with

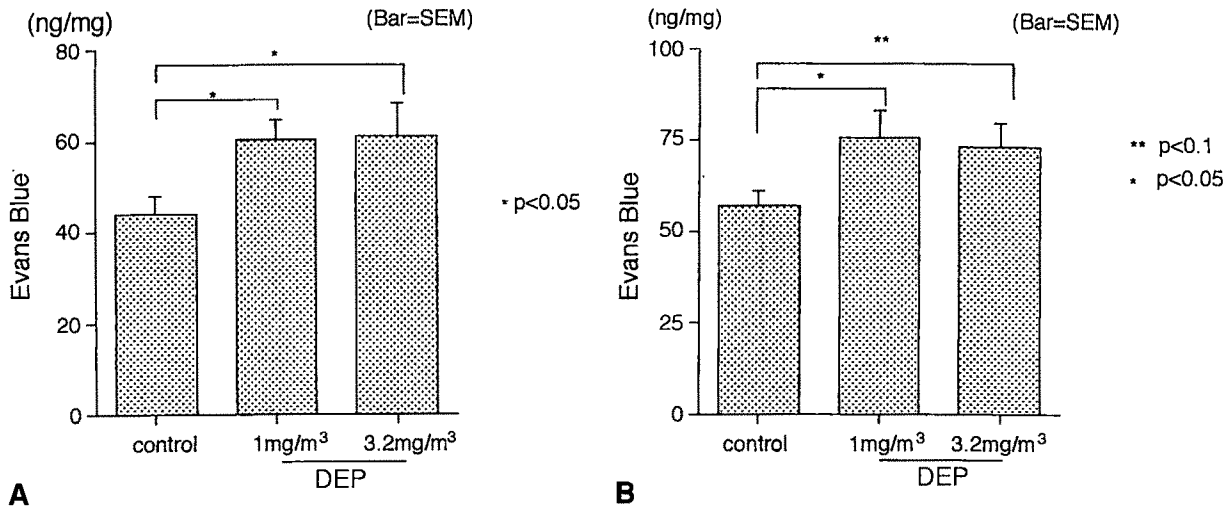

Fig 1. Histogram showing Evans blue extravasation (vascular permeability by histamine) in A) septal mucosa and B) mucosa of maxilloturbinal concha. DEP — diesel exhaust particulate.

an electron microscope. In similar fashion, the nasal septa were removed and embedded in paraffin. Sections 4 μm thick were cut and Giemsa-stained. Tissue was examined by light microscopy and filmed. Eosinophils in epithelium and subepithelium were counted, and the surface areas of the epithelial and subepithelial layers were measured with area-measuring software (Mitablet-II, Graphtec KD4030). In this fashion, the number of eosinophils per single layer (square millimeters) was determined. Additionally, tissues were embedded in Epon (Nissin EM) and examined by ultramicroscopy.

Statistical Analysis. Comparisons of Evans blue extravasation (vascular permeability), the number of eosinophils in the epithelial layer, and the ratio of eosinophilic epithelial infiltration were done by Mann-Whitney U-test. Comparisons of the percentages of dark cells among all epithelial cells were done by unpaired *t*-test. For both analyses, a p value of .05 was considered the limit of significance. Comparisons of the percentages of intercellular spaces with positive reaction to HRP were done by χ^2 test. For these analyses, a p value of .01 was considered the limit of significance.

RESULTS

Vascular Permeability Induced by Histamine. The vascular permeability of nasal mucosa by histamine was significantly and dose-dependently increased in DE-exposed guinea pigs. Figure 1A shows Evans blue extravasation in septal mucosa; the differences between the control group (N = 8) and the group exposed to 1.0 mg/m^3 DEP (N = 8) and between the control group (N = 8) and the group exposed to 3.2 mg/m^3 DEP (N = 7) were statistically significant ($p < .05$). Figure 1B shows Evans blue extravasation in the mucosa of maxilloturbinal concha; the differences between the control group (N = 8) and the group exposed to 1.0 mg/m^3 DEP (N = 8) were statistically significant ($p < .05$). The differences between the control group (N = 8) and the group exposed to 3.2 mg/m^3 DEP (N = 7) show a tendency to significance ($p < .1$) statistically.

Nasal Mucosal Permeability to HRP. In the control group, HRP reaction products were observed in the periciliary spaces, but in very few intercellular spaces. On the other hand, in the groups exposed to 1.0 mg/m^3 and 3.2 mg/m^3 DEP, there was much diffuse cytoplasmic uptake of HRP in dark ciliated cells, which appeared to be undergoing degeneration, and HRP in the intercellular spaces (Fig 2). Figure 3 shows the percentages of dark cells among all epithelial cells; the differences between the control group and the group exposed to 1.0 mg/m^3 DEP and between the control group and the group exposed 3.2 mg/m^3 DEP were statistically significant ($p < .05$). Figure 4 shows the percentages of intercellular spaces with a positive reaction to HRP. The difference between the control group and the groups exposed to DEP were statistically significant ($p < .01$). However, serum levels of HRP did not differ significantly among the 3 groups: control (N = 6), 52.4 ± 37.7 ng/mL; 1.0 mg/m^3 DEP (N = 7), 22.8 ± 5.52 ng/mL; and 3.2 mg/m^3 DEP (N = 7), 38.6 ± 68.1 ng/mL.

Eosinophil Infiltration. The number of eosinophils in the subepithelial layer did not differ significantly among the 3 groups: control (N = 4), 230.82 ± 163.55 cells/mm^2; 1.0 mg/m^3 DEP (N = 4), 97.4 ± 47.07 cells/mm^2; and 3.2 mg/m^3 DEP (N = 4), 468.86 ± 216.21 cells/mm^2. On the other hand, the number of eosinophils in the epithelial layer increased significantly in the the group exposed to 3.2 mg/m^3 DEP ($p < .05$; Fig 5A). Nasal epithelium exposed to 3.2

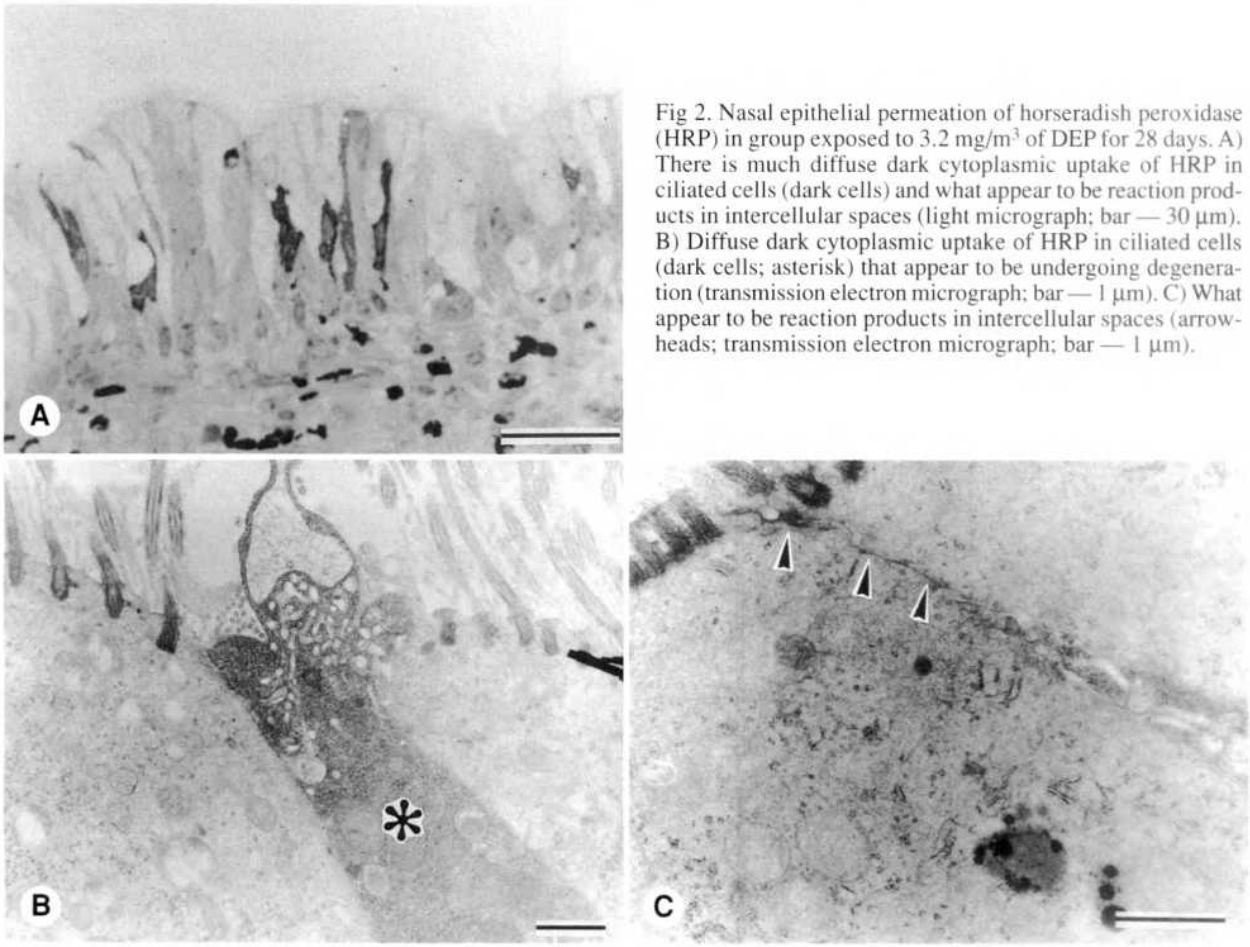

Fig 2. Nasal epithelial permeation of horseradish peroxidase (HRP) in group exposed to 3.2 mg/m^3 of DEP for 28 days. A) There is much diffuse dark cytoplasmic uptake of HRP in ciliated cells (dark cells) and what appear to be reaction products in intercellular spaces (light micrograph; bar — 30 μm). B) Diffuse dark cytoplasmic uptake of HRP in ciliated cells (dark cells; asterisk) that appear to be undergoing degeneration (transmission electron micrograph; bar — 1 μm). C) What appear to be reaction products in intercellular spaces (arrowheads; transmission electron micrograph; bar — 1 μm).

mg/m^3 DEP for 28 days (Fig 6B) had more eosinophil infiltration than did control nasal epithelium (Fig 6A). Figure 7 shows eosinophil infiltration into the epithelial layer in an animal exposed to 3.2 mg/m^3 of DEP.

DISCUSSION

In this study, we showed that the vascular permeability induced by histamine was significantly increased by DE exposure in a dose-dependent manner. Recently, we observed that the expressions of histamine H1 receptor (H1R) mRNA in human mucosal microvascular endothelial cells and nasal epithelial cells are significantly enhanced by DEP extract (extract of polyaromatic hydrocarbons; Terada et al, unpublished observations). Although we have to confirm that the protein level of H1R is actually

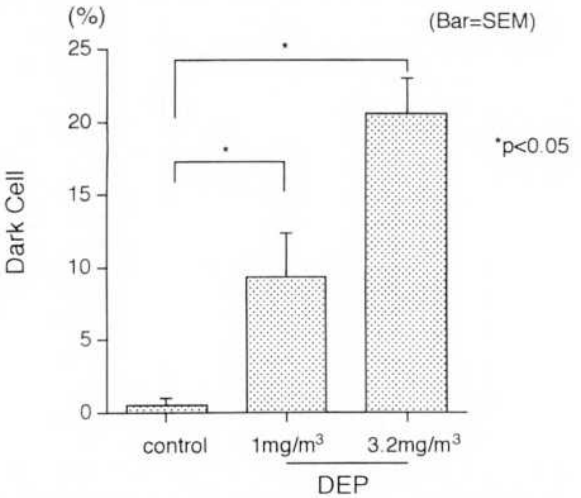

Fig 3. Histogram showing percentages of "dark cells."

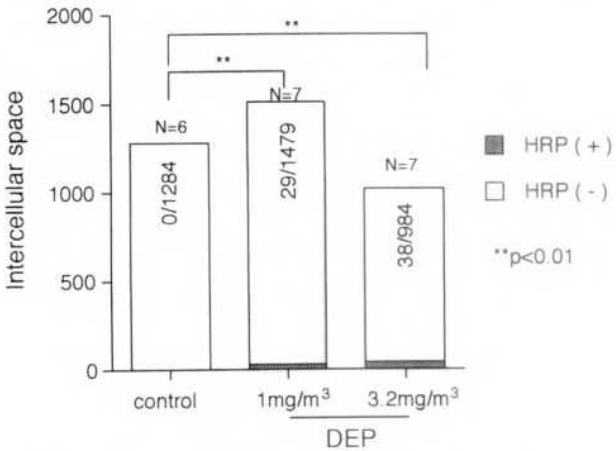

Fig 4. Histogram showing percentages of intercellular spaces in which HRP reaction products appear to be present.

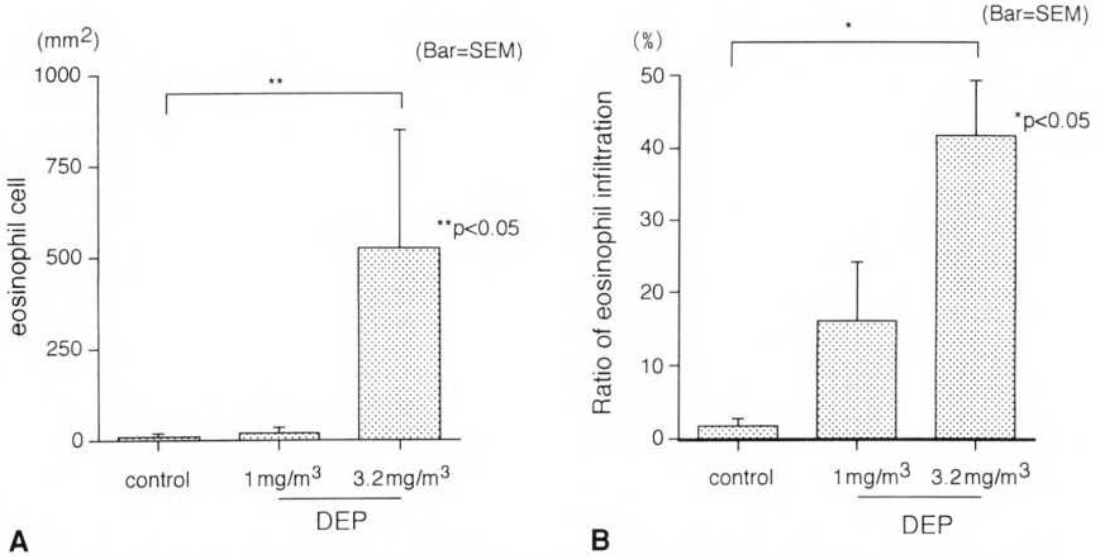

Fig 5. Eosinophil infiltration of nasal epithelium exposed to DEP for 28 days. A) Comparison of numbers of eosinophils in nasal epithelium. B) Comparison of ratio of eosinophil infiltration.

up-regulated by DEP extract, there is a possibility that DE exposure may up-regulate the expression of H1R in nasal mucosa.

We also showed that nasal epithelial permeability to HRP is increased by exposure to DE. Ranga et al[11] found that in guinea pigs exposed to nitrogen dioxide, the morphological correlates of increased permeability to HRP appear to be of 2 different kinds. One is an increase in pinocytotic activity within the hyperplastic goblet cells. The other is transjunctional transport by leaky tight junctions. Boucher et al[3] found that histamine and methacholine increase tracheobronchial mucosa permeability, and that this effect is most likely mediated by functional change in epithelial tight junctions. However, Sakagami et al[12] reported that otitis media increased the uptake of HRP in the middle ear mucosa by pinocytosis and that epithelial tight junctions remained intact in the presence of inflammation of the middle ear cavity. How, then, did HRP permeate the epithelium in DE-exposed animals? There are 2 possible explanations for this. One is that HRP is taken up by pinocytosis and transported to the lateral cell wall, where it is released into the intercellular space, while the other is that HRP permeates directly into the intercellular space via tight junctions. The former requires about 30 minutes, so at 10 minutes after HRP instillation, HRP reaction products in intercellular spaces are considered to have entered directly via tight junction (Inagaki[13]). In our study, HRP was instilled for 30 minutes, and therefore it is impossible to determine in which way the HRP reaction products entered the intercellular space. In addition, Walker et al[14] reported that tight junction morphology did not change following exposure to cigarette smoke, which increased penetration of HRP from the lumen of the trachea into the bloodstream.

In our previous study, following nasal application of HRP prior to nasal DEP solution treatment for 3 weeks, the HRP content in serum was significantly higher than in control specimens (PBS-treated group). Further, the density of HRP reaction products in epithelial cells and intercellular spaces was significantly increased in the DEP-treated guinea pigs on electron microscopic observation (Konno, unpublished observations). In the present study, however, serum

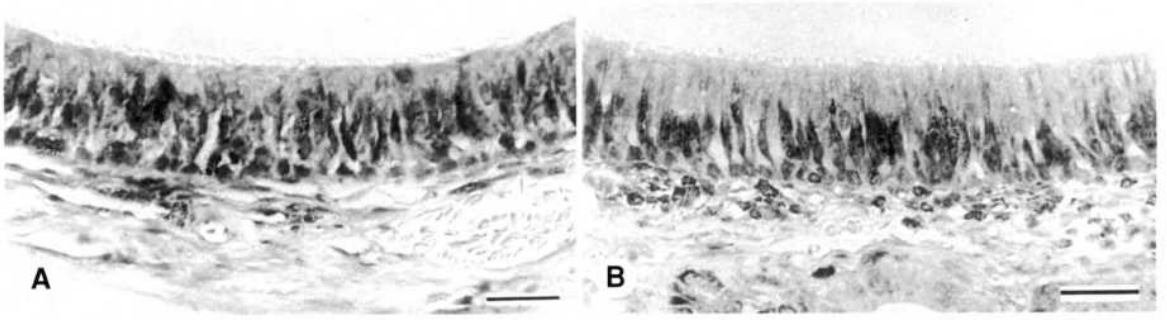

Fig 6. Eosinophil infiltration in nasal epithelium (light micrograph; bar — 30 μm). A) Control nasal epithelium. B) Nasal epithelium exposed to 3.2 mg/m^3 DEP for 28 days.

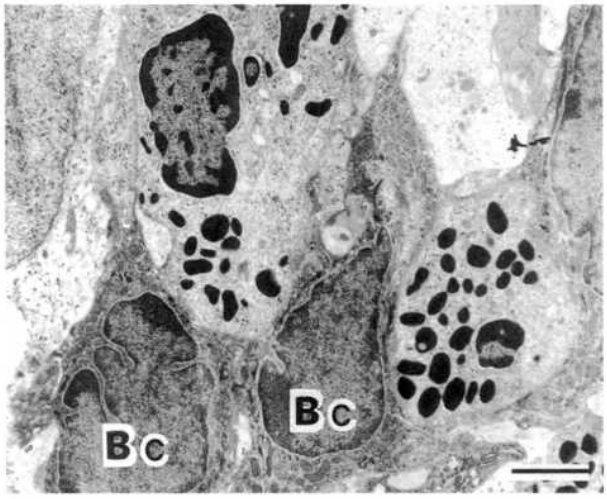

Fig 7. Eosinophil infiltration in nasal epithelium (transmission electron micrograph; bar — 1 μm; Bc — basal cell).

levels of HRP did not differ significantly among the 3 groups. This discrepancy in findings is thought to be due to the difference between intranasal DEP solution instillation (strong stimulation) and DE exposure (mild stimulation). In fact, electron microscopic observations showed that in inoculated animals, cell damage spread from the epithelial layer to the subepithelial layer, and HRP reaction products were commonly detected in the subepithelial layer (Konno, unpublished observations).

The molecular weight of HRP is 40,000 d, and HRP appears to be almost the same weight as some antigens, for example, certain pollens. It is certainly possible that the mucosal permeability to antigen across the epithelial layer is increased. Finally, increases in epithelial permeability, even minor ones, may have a marked effect on allergic inflammation.

The finding that eosinophil infiltration into the epithelial layer was increased in the groups exposed to DE suggests that DEP may have some significant effects on the eosinophils, which are thought to be mainly responsible for nasal mucosal hyperreactivity. This finding can be attributed to enhanced adhesion between eosinophils and epithelial cells promoted by potentiation of cell-to-cell adhesion molecules and/or epithelial function. Terada et al[15] reported that dose-dependent eosinophil-epithelium adhesion was promoted by stimulating eosinophils for 18 hours with DEP extract. On the other hand, epithelial adhesion to eosinophils was not affected by either DEP or DEP extract when human nasal epithelial cells were stimulated with them. This suggested that DEP extract changes the expression of eosinophil surface adhesion molecules, such as leukocyte function associated antigen–1 (LFA-1) and macrophage antigen–1 (MAC-1), which are counter-receptors of intracellular adhesion molecule–1 (ICAM-1). However, in an immunofluorescence and flow cytometric study performed after eosinophil stimulation with DEP extract, no change in mean fluorescence intensity was observed for any adhesion molecule studied.[15] It therefore appears likely that DEP extract increases eosinophil adhesiveness to human nasal epithelial cells by changing the affinity of all adhesion molecules.

One effect of DEP is promotion of cytokine production, especially that of granulocyte-macrophage colony stimulating factor (GM-CSF) and interleukin-8 (IL-8), by epithelial cells. When cultured nasal epithelial cells are exposed to DEP, production of GM-CSF and IL-8 is increased (Terada, unpublished observations). While GM-CSF facilitates cell differentiation, migration, and activation and increases eosinophil survival rate,[16] IL-8 facilitates the migration of activated eosinophils.[17,18] Therefore, DEP may promote eosinophil infiltration by facilitating the production of cytokine-releasing eosinophils by epithelial cells.

These findings suggest that DEP has a variety of roles in the induction of allergy. Enhanced IgE production in lymphocytes and mast cells has been found in some previous studies.[8,19,20] Additionally, the above considerations strongly suggest that DEP plays an important role in promoting nasal hyperreactivity through H1R, induced by facilitation of epithelial antigen passage effects and enhanced eosinophil infiltration of epithelium.

ACKNOWLEDGMENTS — The authors thank Dr T. Kanda for his valuable advice throughout this study, and Y. Hirashima for her excellent technical assistance.

REFERENCES

1. Boucher RC, Johnson J, Inoue S. The effect of cigarette smoke on the permeability of guinea pig airways. Lab Invest 1980;43:94-100.

2. Richardson J, Bouchard T, Ferguson CC. Uptake and transport of exogenous proteins by respiratory epithelium. Lab Invest 1976;35:307-14.

3. Boucher RC, Ranga V, Pare PD, Inoue S, Moroz LA, Hogg JC. Effect of histamine and methacholine on guinea pig tracheal permeability to HRP. J Appl Physiol 1978;45:939-48.

4. Rhodes PS, Karnovsky MJ. Loss of macromolecular barrier function associated with surgical trauma to the intestine. Lab Invest 1971;25:220-9.

5. Wade JB, Karnovsky MJ. Fracture faces of osmotically disrupted zonulae occludentes. J Cell Biol 1974;62:344-50.

6. Humbert F, Grandchamp A, Pricam C, Perrelet A, Orci L. Morphological changes in tight junctions of *Necturus maculosus* proximal tubules undergoing saline diuresis. J Cell Biol 1976;69:90-6.

7. Kobayashi T, Ito T. Diesel exhaust particulates induce nasal mucosal hyperresponsiveness to inhaled histamine aerosol. Fundam Appl Toxicol 1995;27:195-202.

8. Muranaka M, Suzuki S, Koizumi K, et al. Adjuvant activity of diesel exhaust particulates for the production of IgE antibody in mice. J Allergy Clin Immunol 1986;77:616-23.

9. Sagai M, Saito H, Ichinose T, Kodama M, Mori Y. Biological effects of diesel exhaust particles. I. *In vitro* production of superoxide and *in vivo* toxicity in mouse. Free Radic Biol Med 1993;14:37-47.

10. Graham RC, Karnovsky MJ. The early stage of absorption of injected horseradish peroxidase in the proximal tubule of the mouse kidney: ultrastractural cytochemistry by a new technique. J Histochem Cytochem 1966;14:291-302.

11. Ranga V, Kleinerman J, Ip MPC, Collins AM. The effect of nitrogen dioxide on tracheal uptake and transport of horseradish peroxidase in the guinea pig. Am Rev Respir Dis 1980;122:483-90.

12. Sakagami M, Harada T, Juhn SK, Duvall AJ III, Matsunaga T. Uptake of horseradish peroxidase by the middle ear mucosa in experimentally induced otitis media. Eur Arch Otorhinolaryngol 1990;148:113-8.

13. Inagaki M. Electron microscopic studies on the tight junctional permeability of the human nasal mucosa. Mie Med J 1984;33:407-17.

14. Walker DC, MacKenzie A, Wiggs BR, Hulbert WC, Hogg JC. The structure of tight junctions in the tracheal epithelium may not correlate with permeability. Cell Tissue Res 1984;235: 607-13.

15. Terada N, Maesako K, Hiruma K, et al. Diesel exhaust particulates enhance eosinophil adhesion to nasal epithelial cells and cause degranulation. Int Arch Allergy Immunol 1997;114: 167-74.

16. Cox G, Ohtoshi T, Gauldie J, et al. Promotion of eosinophil survival by human bronchial cells and its modulation by steroids. Am J Respir Cell Mol Biol 1991;4:255-63.

17. Sehmi R, Cromwell O, Waldlaw A, Moqbel R, Kay AB. Interleukin-8 is a chemoattractant for eosinophils purified from subjects with a blood eosinophilia but not from normal healthy subjects. Clin Exp Allergy 1993;23:1027-36.

18. Villar MTA, Douglass J, Shute J, Church MK, Holgate ST. Interleukin-8 is a chemoattractant for eosinophils primed with interleukin-4 [Abstract]. Am Rev Respir Dis 1993;147 (suppl):A242.

19. Takafuji S, Suzuki S, Koizumi K, et al. Enhancing effect of suspended particulate matter on the IgE antibody production in mice. Int Arch Allergy Appl Immunol 1989;90:1-7.

20. Takenaka H, Zhang K, Sanchez DD, Tsien A, Saxon A. Enhanced human IgE production from exposure to the aromatic hydrocarbons from diesel exhaust: direct effects on B-cell IgE production. J Allergy Clin Immunol 1995;95:103-15.

FUNCTIONAL ENDOSCOPIC SINUS SURGERY

Functional Endoscopic Sinus Surgery — Basic and Advanced Techniques will be held in Graz, Austria, in English (July 1-3, 1999) and in German (September 2-4, 1999). For more information, contact Claire Zwerina, Secretary to Prof Stammberger, ENT-Department, University Hospital, Auenbruggerplatz 20, A-8036 Graz, Austria; fax ++43/316/385/3425.

CONGENITAL NASAL HEMANGIOPERICYTOMA: INTRAUTERINE, INTRAOPERATIVE, AND HISTOLOGIC FINDINGS

KARL GÖTTE, MD
KARL HÖRMANN, MD
JÜRGEN SCHMOLL, MD
WOLF-DIETER HILTMANN, MD
MANNHEIM, GERMANY

Hemangiopericytoma is a rare tumor of mesenchymal origin. To date, 91 cases of nasal or paranasal hemangiopericytoma and 59 congenital hemangiopericytomas have been reported in the literature. A congenital hemangiopericytoma arising from the nasal cavity and skull base has not yet been described. We report a case of a male newborn with a highly vascular nasal tumor diagnosed by in utero sonography with three-dimensional surface reconstruction. The tumor extended to the right anterior skull base, the right nasal cavity, and the right side of the nasal pyramid. A complete resection by neodymium:yttrium-aluminum-garnet–potassium titanyl phosphate ("Nd:YAG-KTP") laser was performed on the day of cesarean section at 33 weeks' gestation. The tumor was diagnosed as hemangiopericytoma by histologic and immunohistochemical findings. Postoperative nasal flow, feeding, and sight were unimpaired. At the 9-month follow-up, the infant remained free of disease.

KEY WORDS — congenital tumor, hemangiopericytoma, laser surgery, nose, three-dimensional surface reconstruction.

INTRODUCTION

Hemangiopericytoma is a rare tumor of vascular origin, comprising 3% of all soft tissue sarcomas.[1] While the tumor may arise from any vascular site, a literature review found only 91 reported cases of hemangiopericytomas of the nasal cavity and the paranasal sinuses, most often involving the ethmoid cells.[1] Patients mainly present with epistaxis and nasal obstruction; rarely, anosmia and proptosis may be seen. Compagno and Hyams[2] and Compagno[3] introduced the term "hemangiopericytoma-like tumors" for nasal forms in order to distinguish these forms from hemangiopericytomas of other locations. Nasal forms are likely to take a benign course; however, recurrence is seen frequently. There are only 2 documented cases of distant metastases.[4,5]

Congenital forms comprise only 3.3% to 7% of all hemangiopericytomas[6]; 59 cases of congenital hemangiopericytomas have been reported, including 2 congenital hemangiopericytomas of the nasopharynx.[7] To our knowledge, a congenital hemangiopericytoma of the nasal cavity and anterior skull base has not yet been described.

The appearance of a congenital hemangiopericytoma is that of a soft, mostly homogeneous mass, partially encapsulated and often multilobular. A synchronous appearance of congenital forms at multiple sites is an extremely rare event.[7] There is no possibility of gross differentiation from other vascular tumors. Spontaneous hemorrhage from congenital hemangiopericytomas can be life-threatening.[8]

Common to all forms of hemangiopericytomas is their derivation from contractile cells of the capillary wall, called the pericytes of Zimmermann.[9] Histology shows a uniform pattern of elongated cells in a highly vascular surrounding. By silver reticulin staining, single cells surrounded by a layer of reticulin are typically seen in hemangiopericytomas, while in hemangiomas the reticulin fibers are commonly found exterior to the endothelial cells.

Immunohistochemistry is a helpful tool in the diagnosis of hemangiopericytoma. An exclusive vimentin expression is a typical finding in adult as well as congenital forms of hemangiopericytoma, allowing differentiation from infantile myofibromatosis, which is positive for vimentin as well as α–smooth muscle protein.[5] Electron microscopy shows spindle cells outside the basal lamina of vessels and bundles of microfilaments, thus supporting the contractile function of the pericytes.[5] Little data exist on the cytogenetic findings in hemangiopericytomas; however, several chromosomal abnormalities have been noted. A subtype of hemangiopericytoma seems to be characterized by an aberration of chromosome segment 12q13-15.[10] Flow cytometric DNA studies by El-Naggar et al[11] have used diploid DNA content to confirm the low proliferative activity of these tumors.

The differential diagnosis depends entirely on histologic features. Diagnostic difficulties can be found

From the Departments of Otolaryngology–Head and Neck Surgery (Götte, Hörmann), Pathology (Schmoll), and Obstetrics and Gynecology (Hiltmann), University Hospital Mannheim, Mannheim, Germany.

CORRESPONDENCE — Karl Götte, MD, Dept of Otolaryngology–Head and Neck Surgery, University Hospital, D-68135 Mannheim, Germany.

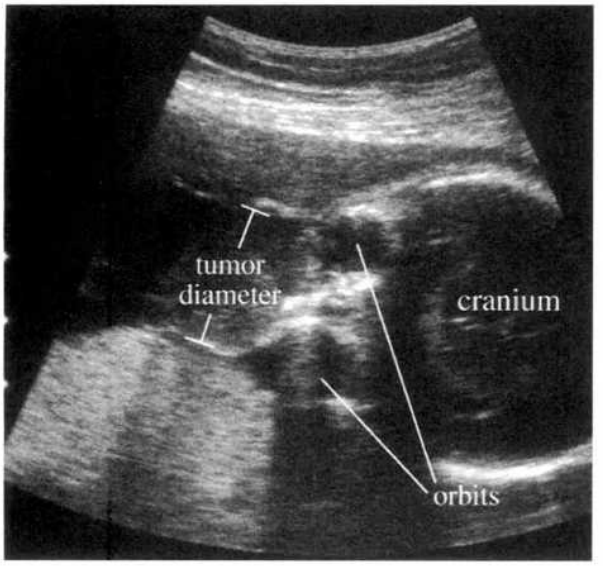

Fig 1. Intrauterine sonographic findings during 28th week of gestation, horizontal section. Encapsulated midfacial tumor on left side, as well as both orbital walls and cranium, is clearly visible.

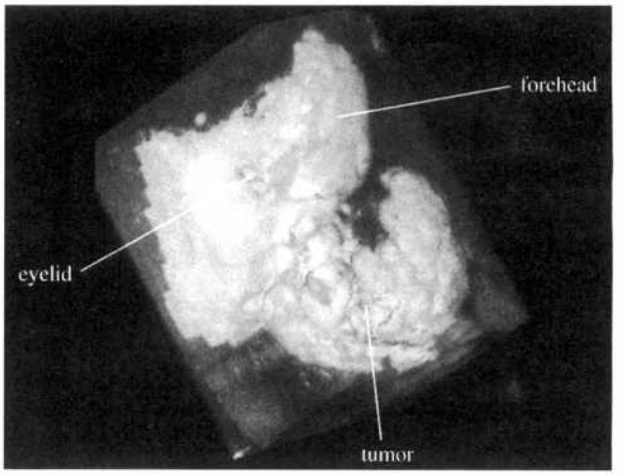

Fig 2. Three-dimensional surface reconstruction based on sonographic data, showing encapsulated tumor and its relation to facial structures such as forehead, right eye, and right angle of mouth in lateral view from right side (computer program INVIVO, Fraunhofer Institute for Cognitive Computing and Medical Imaging, Darmstadt, Germany).

in the differentiation of hemangiopericytomas from juvenile hemangioendothelioma, vascular leioma, glomus tumors, and congenital myofibromatosis.[12]

Enzinger and Smith[13] defined the histologic features of benign and malignant forms of hemangiopericytoma. Hemorrhage, necrosis, calcification, and large numbers of mitotic figures (>3 per high-power field) would be suggestive of malignancy, but the prognostic value of these histologic findings, especially in congenital and juvenile hemangiopericytomas, is very limited.[13]

A prediction of the clinical course of nasal hemangiopericytomas is difficult. In adults, nasal hemangiopericytomas are known to have a high rate of local recurrence. The risk of local recurrence is at least 50%. Distant metastases may arise from hematogenous and lymphatic spread.[14] As congenital hemangiopericytomas mostly take a benign course and have a different histopathology, they can be regarded as a separate pathological entity.[6] In congenital forms, local recurrence and distant metastases are extremely rare.[15,16] The clinical course of a hemangiopericytoma is difficult to predict, as local recurrence may occur many years after initial treatment.[17]

CASE REPORT

A 35-year-old gravida 6, para 2 woman presented during the 28th week of gestation for routine sonographic examination. The woman was noted to have a dysmelia of the right hand. Sonographic examination at this time and during follow-up revealed a constantly enlarging vascular tumor of the midface. The sonographic data were acquired by a volume scan (machine 530, Kretz, Austria; Fig 1). A three-dimensional (3-D) reconstruction of the facial surface was performed off-line (Fig 2). For 3-D reconstruction, the program INVIVO, developed by the Fraunhofer Institute for Cognitive Computing and Medical Imaging, Darmstadt, Germany, together with the local Department of Obstetrics and Gynecology, was used.

This latter diagnostic tool, together with an interdisciplinary approach involving the Department of Otolaryngology prior to delivery, led to the following conclusions.

1. Spontaneous delivery would be life-threatening for the mother and lethal for the child.
2. The tumor, although of giant size regarding the dimensions of the fetus, was potentially resectable without a major functional deficit or mutilation, as was shown by 3-D surface reconstruction.
3. Respiratory distress of the newborn immediately after delivery had to be considered.
4. As the tumor was noted to be highly vascular, a major challenge for the surgeon would be to control blood loss.

A primary cesarean section was performed during the 33rd week of pregnancy, with preparation for rigid tracheoscopy and tracheotomy. Apgar scores were 7 at 1 minute, 8 at 5 minutes, and 8 at 10 minutes. The birth-weight of the fully developed male patient was 2,190 g. At clinical examination, a solid, nonbleeding tumor with a diameter of 8 cm, covering almost the entire face, was noted (Fig 3). The

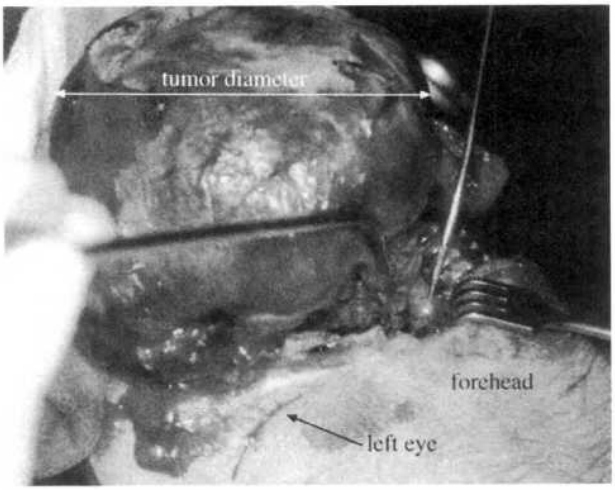

Fig 3. Intraoperative findings after cesarean primary section during 33rd week of pregnancy, from cranial view showing enormous, highly vascular tumor, as well as closed left eye (lower left).

tumor was broadly connected with the right lateral nasal wall, with its base in the region of the right ethmoid sinuses and right frontal skull base. The nasal pyramid, including its bony and cartilaginous parts, was developed, although the nose and the anterior wall of the right maxillary sinus were compressed.

After an initially stable cardiorespiratory situation, the child developed rapidly increasing dyspnea and had to be intubated orally. The tumor was resected on the first day of life. Surgery was performed with a combined neodymium:yttrium-aluminum-garnet (Nd:YAG)–potassium titanyl phosphate (KTP) laser after a bipolar cauterization of several major vessels at the base of the tumor. The frequency-doubled KTP laser mode was mainly used as a cutting instrument, with good hemostatic properties. The Nd:YAG laser mode was only used for selected deep coagulation. By this technique, blood loss was minimized. A single blood transfusion of 20 mL was necessary. The cartilaginous part of the right lateral nasal wall had to be resected due to tumor involvement. All other parts of the nasal pyramid could be preserved. The orbital wall and the skull base were left intact. The resulting wound on the external part of the nose was partially covered by a skin rotation. The nasal cavity healed by granulation.

IMMUNOHISTOCHEMICAL FINDINGS

Vimentin	+
Desmin	–
CD34	–
Smooth muscle actin	–
Epithelial membrane antigen	–
S-100 protein	–
Factor VIII–related antigen	–
Pan-cytokeratin	–

The histologic diagnosis after hematoxylin-eosin, periodic acid–Schiff (PAS), and Gomori staining, in addition to immunohistochemistry staining, was hemangiopericytoma. Immunohistochemistry was negative for expression of CD34 and positive for vimentin. The Table gives an overview of the immunohistochemical findings. A histologic section of the tumor with PAS staining is shown in Fig 4.

The postoperative course was uneventful. The young patient developed well and showed no signs of retardation or disability. Further examination showed a coloboma of the right iris, as well as multiple lipomalike structures of the subcutaneous tissue, though serum cholesterol and triglyceride levels were normal. There were no other deformities. Nasal airflow, feeding, and sight were not impaired.

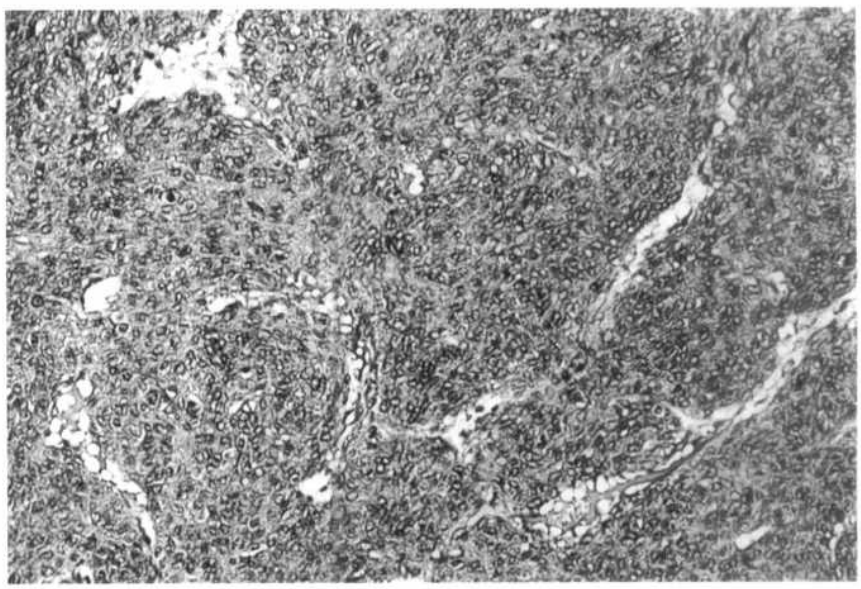

Fig 4. At microscopic investigation, hemangiopericytoma shows tightly packed tumor cells around ramifying thin-walled, endothelium-lined vascular channels (periodic acid–Schiff, original ×200).

Fig 5. Postoperative result 3 months after surgery.

The patient was well healed at 3 months after surgery (Fig 5). During a follow-up period of 9 months, there was no evidence of recurrence. Rhinoplasty is planned after childhood.

DISCUSSION

Of the 59 reported cases of congenital hemangiopericytomas, we could not find a case in which the existence of the tumor was detected in utero.[6-8,12,15,16] Whereas, for most locations, this lack of detection may be of no major consequence for therapy and prognosis, a high risk of mortality exists for vascular tumors in the head and neck. While high-resolution sonography enables the obstetrician to define already-present structures, information about the exact location of the tumor and its relationship to surrounding structures requires 3-D surface reconstruction. Although still a quite new and laborious technique, it gives the otolaryngologist important additional information about the potential for resection and the choice of adequate surgical procedure. The possibilities of 3-D reconstruction of sonographic data for broader applications in otolaryngology require further investigation.

Congenital hemangiopericytomas mostly take a benign course and may also spontaneously remit. Congenital tumors are nonetheless dangerous: recurrence can occur after several years, and a malignant course with distant metastases cannot be excluded with certainty. Also, there is a risk of massive and life-threatening bleeding, especially when the tumor is exposed.[15-17] In this specific case there was an additional major risk of asphyxia due to the location of the tumor.

Complete surgical resection remains the treatment of choice. For hemangiopericytomas of the nose and the paranasal sinuses, lateral rhinotomy and midfacial degloving are possible means of access, if complete resection by endoscopic surgery is not possible.[14,18] Preoperative angiography with simultaneous embolization might be helpful in adult cases, but is not practical in newborns. The use of the combined Nd:YAG-KTP laser for resection has several advantages. In our case, the passage of the laser energy by a flexible fiber allowed good access to the hidden base of the tumor. The KTP laser, with a wavelength of 532 nm and an absorption length in soft tissue of 2 to 3 mm, has good cutting properties with acceptable hemostatic properties. The Nd:YAG laser, with a wavelength of 1,064 nm and an absorption length of 3 to 4 mm in soft tissue, has only been used in cases of required deep coagulation.[19] The possible dangers, especially of uncontrolled heat conduction, in the use of a KTP or an Nd:YAG laser in this region of highly delicate structures must be balanced against the underlying life-threatening disorder.

Attempts to treat hemangiopericytomas by chemotherapy, especially Adriamycin, have been reported.[20] Cure by chemotherapy is uncertain, however, and chemotherapy in newborns is not the treatment of choice. Radiotherapy in the treatment of hemangiopericytomas has also been reported, but the results of radiotherapy and chemotherapy are less promising than those of surgical treatment. Steroid therapy, useful in many kinds of vascular diseases, seems to be ineffective in hemangiopericytomas.[12]

CONCLUSION

Survival of mother and child in this specific case could only be ensured by accurate intrauterine sonographic diagnosis of the nasal tumor and coordinated interdisciplinary action. Three-dimensional surface reconstruction of sonographic data permits the otorhinolaryngologist to offer prenatal recommendations for treatment of congenital vascular malformations.

The application of an Nd:YAG-KTP laser for resection of nasal hemangiopericytomas has not yet been described. In our experience, this type of laser, combining cutting properties with good hemostatic properties, proved to be an excellent means of treating a congenital nasal vascular tumor.

Because nasal and congenital hemangiopericytomas are subtypes of a rare mesenchymal tumor, data regarding the outcome of affected patients are rare and inconsistent in the literature. We emphasize the need to report diagnosed cases and the need to carefully preserve the resected material, as future molecular analyses may offer the promise of defining subtypes with variable clinical behavior.

REFERENCES

1. Abdel-Fattah HM, Adams GL, Wick MR. Hemangiopericytoma of the maxillary sinus and skull base. Head Neck 1990; 12:77-83.

2. Compagno J, Hyams VJ. Hemangiopericytoma-like intranasal tumors: a clinico-pathological study of 23 cases. Am J Clin Pathol 1976;66:672-83.

3. Compagno J. Hemangiopericytoma-like tumors of the nasal cavity: a comparison with hemangiopericytoma of soft tissue. Laryngoscope 1978;88:460-9.

4. De Campore E, Calabrese V, Bianchi PM, Camaioni A, Corrandini C. Malignant hemangiopericytoma of nasal cavity. J Laryngol Otol 1983;97:963-8.

5. Eichhorn JH, Dickersin GR, Bhan AK, Goodman ML. Sinonasal hemangiopericytoma: a reassessment with electron microscopy, immunohistochemistry and long-term follow-up. Am J Surg Pathol 1990;14:856-66.

6. Kauffman SL, Stout AP. Hemangiopericytoma in children. Cancer 1960;13:695-710.

7. Seibert JJ, Seibert RW, Weisenburger DS, Allsbrook W. Multiple congenital hemangiopericytomas of the head and neck. Laryngoscope 1978;88:1006-12.

8. Resnick SD, Stuart L, Jones G. Hemorrhagic complications in a rapidly growing, congenital hemangiopericytoma. Pediatr Dermatol 1993;10:267-70.

9. Stout AP, Murray MR. Hemangiopericytoma; vascular tumor featuring Zimmermann's pericytes. Ann Surg 1942;116: 26-33.

10. Mandahl N, Orndal C, Heim S, et al. Aberrations of chromosome segment 12q13-15 characterize a subgroup of hemangiopericytomas. Cancer 1993;71:3009-13.

11. El-Naggar AK, Batsakis JG, Garcia GM, Luna ML, Goepfert H. Sinonasal hemangiopericytomas; a clinicopathologic and DNA content study. Arch Otolaryngol Head Neck Surg 1992;118:134-7.

12. Bailey PV, Weber TR, Tracy TF, O'Connor DM, Sotelo-Avila C. Congenital hemangiopericytoma: an unusual vascular neoplasm of infancy. Surgery 1993;114:936-41.

13. Enzinger FM, Smith BH. Hemangiopericytoma, an analysis of 106 cases. Hum Pathol 1976;7:61-82.

14. Chawla OP, Oswal VH. Hemangiopericytoma of the nose and paranasal sinuses. J Laryngol Otol 1987;101:729-37.

15. Morgan A, Evbuomwan I. Congenital hemangiopericytoma of the face with early distant metastasis. J R Coll Surg Edinb 1983;28:123-5.

16. Jenkins JJ. Congenital malignant hemangiopericytoma. Pediatr Pathol 1987;7:119-22.

17. Schirger A, Uihlein A, Parker HL, Kernchan JW. Hemangiopericytoma recurring after 26 years. Proc Mayo Clin 1958; 33:347-52.

18. Maniglia AJ, Phillips DA. Midfacial degloving for the management of nasal, sinus, and skull-base neoplasms. Otolaryngol Clin North Am 1995;28:1127-43.

19. Levine HL. Endoscopy and the KTP/532 laser for nasal sinus disease. Ann Otol Rhinol Laryngol 1989;98:46-51.

20. Wong PP, Yagoda A. Chemotherapy of malignant hemangiopericytoma. Cancer 1978;41:1256-60.

DISTRIBUTION OF RANTES AND INTERLEUKIN-5 IN ALLERGIC NASAL MUCOSA AND NASAL POLYPS

CHUL HEE LEE, MD

KANG SOO LEE, MD
SUNG OK LEE, MSc
CHAE-SEO RHEE, MD
YANG-GI MIN, MD

SEOUL, KOREA

Eosinophil-chemoattracting cytokines are thought to be important in the pathogenesis of allergic inflammation. However, little is known about the presence and significance of RANTES in nasal allergy and nasal polyps, two well-known rhinologic disorders characterized by eosinophil infiltration in the tissue. In order to evaluate the role of RANTES in eosinophil infiltration in vivo, the tissue distributions of RANTES and interleukin-5 (IL-5) and their correlation with eosinophil infiltration were investigated. Nasal mucosa specimens were obtained from 9 allergic and 12 control subjects, and nasal polyps from 6 allergic and 9 nonallergic subjects. All the subjects were divided into 4 groups: normal mucosa, allergic mucosa, nonallergic polyps, and allergic polyps. To identify the cellular localizations of RANTES and IL-5, we used specific immunohistochemical staining. We also investigated the differences in cytokine expression among the 4 groups, and the correlation between cytokine expression and eosinophil infiltration in the tissue. RANTES was expressed in the epithelium, endothelium, and some submucosal cells, while IL-5 was confined to the cells in the submucosa. Expression of both RANTES and IL-5 significantly increased in allergic mucosa and nasal polyps compared to normal mucosa; however, there was no significant difference in their expression between allergic and nonallergic polyps. Both cytokines had a significant correlation between their expression and either total or activated eosinophil numbers. The results of this study suggest that RANTES, as well as IL-5, plays a role in eosinophil recruitment in allergic nasal mucosa and nasal polyps in vivo.

KEY WORDS — eosinophil, interleukin-5, nasal mucosa, nasal polyps, RANTES.

INTRODUCTION

Eosinophil recruitment is well known to be important in the pathogenesis of allergic inflammation such as bronchial asthma and allergic rhinitis.[1] It is also believed that the mechanisms by which eosinophils are attracted to the tissues require chemoattractant signals such as cytokines.[2,3] Several in vitro studies have shown that RANTES (Regulated And Normal T cells Expressed and Secreted) is a potent chemoattractant for eosinophils,[2-4] while interleukin-5 (IL-5) is well known to recruit and activate eosinophils in vivo and in vitro.[1,2,5,6] However, little is known about the significance of RANTES in nasal mucosal allergy and nasal polyps in vivo. Recently, there have been conflicting reports on the role of RANTES as an eosinophil chemoattractant in vivo. In a study using bronchoalveolar lavage fluid (BALF), Venge et al[2] concluded that both RANTES and IL-5 are important chemoattractants in asthmatics. On the other hand, the results of another study using BALF have shown that eosinophil recruitment is associated with IL-5, but not with RANTES, 24 hours after allergen challenge.[1]

In order to better understand the role of RANTES and compare it to that of IL-5 in vivo, we investigated 1) the expression patterns of RANTES and IL-5 in nasal allergy and nasal polyposis and 2) the correlation between cytokines and eosinophil recruitment at the tissue level.

MATERIALS AND METHODS

Subjects. Nine patients with perennial allergic rhinitis and 12 healthy, nonatopic, nonrhinitic subjects with nasal septal deviation were enrolled. All the subjects were divided into 4 groups: normal mucosa, allergic mucosa, nonallergic polyps, and allergic polyps. None of the subjects had experienced symptoms of upper respiratory tract infection within the preceding month. The rhinitic patients were symptomatic and were not receiving any medication, including topical steroids, for at least 4 weeks before the study. The presence of allergy was determined by the presence of the main symptoms of allergic rhinitis, including nasal itching, sneezing, and watery rhinorrhea and a positive skin prick test and/or radioallergosorbent test (RAST). All 9 rhinitic patients were sensitive to the house dust mite (*Dermatophagoides pteronyssinus* and/or *Dermatopha-*

From the Department of Otorhinolaryngology, College of Medicine, Seoul National University, Seoul, Korea. This research was supported by grant 95-08-2081 from the Seoul National University Research Fund.

CORRESPONDENCE — Chul Hee Lee, MD, Dept of Otorhinolaryngology, Seoul National University Hospital, 28, Yongon-Dong Chongno-Gu, Seoul, 110-744, Korea.

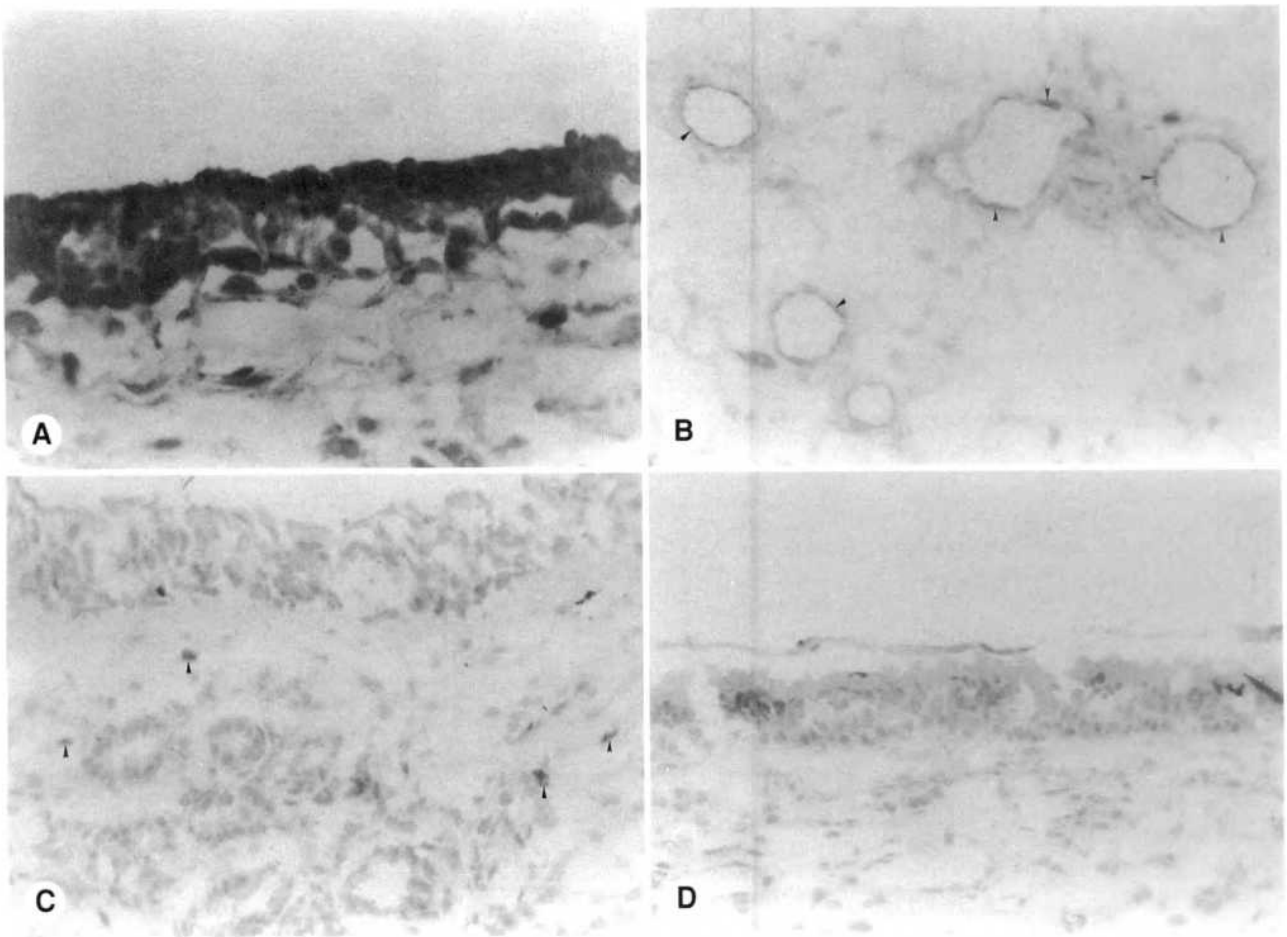

Fig 1. Sections of nasal mucosa and nasal polyp tissues. A) Representative section of allergic nasal mucosa with positive staining for RANTES in epithelium (original ×400). B) Vascular endothelium staining with anti-RANTES in normal nasal mucosa tissue (arrowheads; original ×250). C) Photomicrograph of anti–IL-5–stained nasal polyp tissue demonstrating several positive immunoreactive cells in submucosa (arrowheads; original ×400). D) Nasal polyp with demonstration of specific activity of anti-RANTES, with negative RANTES expression after incubation of anti-RANTES with rhRANTES (original ×250).

goides farinae), which is the most common allergen in Korea. This study was approved by the Seoul National University Ethics Committee. All the subjects gave written informed consent to participation in this study.

Nasal Biopsy and Tissue Processing. Nasal mucosa specimens were obtained from the inferior turbinates during septoplasty, and nasal polyps during endoscopic sinus surgery. The tissues were then immediately frozen and stored in a –70°C refrigerator. The frozen tissue specimens were processed into Tissue-Tek OCT compound (Miles Inc, Elkhart, Ind) and serially sectioned at 4-μm thickness.

Immunohistochemistry. The sections were fixed in acetone and stained with a streptavidin-biotin peroxidase system. Primary monoclonal antibodies used in this study were as follows: goat anti-human RANTES (R&D, Minneapolis, Minn), rat anti-human IL-5 (Pharmingen, San Diego, Calif), mouse anti-human major basic protein (MBP; Monosan, Uden, the Netherlands), and mouse anti-human EG2 (secreted form of eosinophil cationic protein; Pharmacia, Uppsala, Sweden). Biotin-labeled goat anti-mouse, rabbit anti-goat, and rabbit anti-rat immunoglobulins (Dako Ltd, Glostrup, Denmark) were used as the secondary antibodies for MBP or EG2, RANTES, and IL-5, respectively. After preincubation with blocking antibody in a Dako labeled streptavidin-biotin kit for 30 minutes at room temperature, the sections were incubated — respectively, with goat anti-human RANTES, diluted 1:100; rat anti-human IL-5, diluted 1:50; mouse anti-human MBP, diluted 1:40; and mouse anti-human EG2, diluted 1:50 — in a moist chamber for 2 hours. After washing in phosphate-buffered saline, the sections were incubated with biotin-labeled goat anti-mouse IgG (1:200) for 30 minutes at room temperature, washed again in the same buffer, and subsequently conjugated by avidin horseradish peroxidase for 45 minutes at room temperature. They were then washed and stained for peroxidase activity with 3,3-diami-

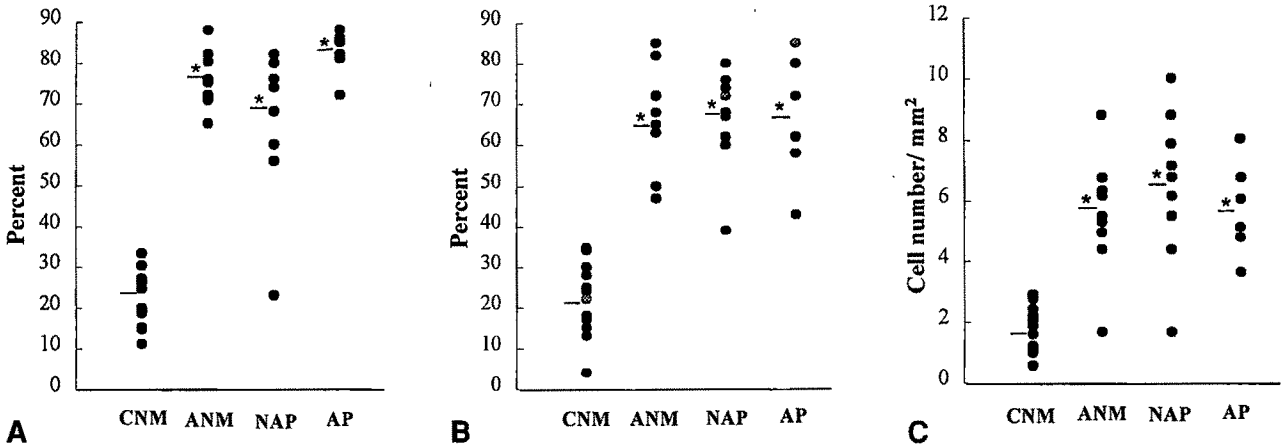

Fig 2. RANTES expression in A) epithelium, B) vessels, and C) submucosa of subjects with control nasal mucosa (CNM), allergic nasal mucosa (ANM), nonallergic nasal polyps (NAP), and allergic nasal polyps (AP). Data are shown as percentage of total length of epithelium, RANTES-positive submucosal cells in 1 mm^2 of tissue, and percentage of RANTES-positive vessels against total vessels, respectively. Solid bars — mean values; asterisks — $p < .05$ (statistically significant).

no-benzidine-tetrahydrochloride (DAB; Sigma, St Louis, Mo). The specific inhibitory activity of anti-RANTES and anti–IL-5 was checked by the preincubation of the respective antibodies with recombinant human (rh)–RANTES (R&D) and rhIL-5 (R&D).

Assessment and Quantitation of Immunoreactivity. The length of positively stained epithelium was expressed as a percentage of the total length of the epithelium in order to quantitate the immunoreactivity of the epithelium. With an eye reticule, 1 mm^2 of the lamina propria was examined in 5 fields under 100× magnification for RANTES-positive and IL-5–positive submucosal cells, and under 400× magnification for MBP (total eosinophils) and EG2 (activated eosinophils). The mean value of the immunoreactivity in the 5 fields was taken as the result. Percent expression of vascular endothelial RANTES was calculated as follows: (Number of vessels stained by RANTES-specific monoclonal antibody/Number of vessels stained by antibody for factor VIII) × 100. The numbers of vessels stained with RANTES and with factor VIII were analyzed from sequential sections.

We assessed the differences among the 4 different groups (normal nasal mucosa, allergic nasal mucosa, nonallergic polyps, and allergic nasal polyps). Correlation between either RANTES or IL-5 expression and eosinophil infiltration in the tissue was also investigated. The expression of RANTES and IL-5 was analyzed by 2 pathologists blinded to the source of the tissues. The counts of the 2 observers were closely correlated, and the average counts were used to report the results.

Statistical Analysis. A Mann-Whitney U test was used to compare the positive immunoreactivity between the 2 groups. Correlation was explored with Spearman's rank correlation test. The level of significance was accepted as $p < .05$.

RESULTS

Immunolocalization of RANTES and IL-5. RANTES was expressed in the epithelial cells (Fig 1A), vascular endothelial cells (Fig 1B), and some submucosal cells, while immunoreactivity for IL-5 was confined to the cells in the submucosa (Fig 1C) both in the nasal mucosa and in nasal polyps. The distribution of immunoreactivity for either cytokine was basically identical in the nasal mucosa and nasal polyps. The immunoreactivity against anti-RANTES or anti–IL-5 was completely blocked by preincubation with rhRANTES (Fig 1D) or rhIL-5.

Comparison of Expression of RANTES and IL-5 Among Four Groups. The expression of RANTES

TABLE 1. MEAN ± SD OF RANTES IMMUNOREACTIVITY

					p Value			
	CNM	*ANM*	*NAP*	*AP*	*CNM vs ANM*	*CNM vs NAP*	*CNM vs AP*	*NAP vs AP*
Epithelium	23.95 ± 7.2	77.64 ± 7.5	70.28 ± 19.2	84.05 ± 10.0	.0001	.0006	.0011	.068
Vessels	21.07 ± 7.4	66.74 ± 8.9	68.55 ± 10.4	67.24 ± 13.5	.0002	.0004	.0010	.100
Submucosa	1.62 ± 0.7	5.96 ± 2.5	6.67 ± 3.1	5.72 ± 1.3	.0002	.0004	.0009	.537

Data are percentages for epithelium and vessels, and numbers of cells for submucosa.

CNM — control nasal mucosa, ANM — allergic nasal mucosa, NAP — nonallergic nasal polyps, AP — allergic nasal polyps.

TABLE 2. MEAN ± SD OF INTERLEUKIN-5 IMMUNOREACTIVITY

	CNM	ANM	NAP	AP	p Value: CNM vs ANM	CNM vs NAP	CNM vs AP	NAP vs AP
Submucosa	0.53 ± 0.4	3.77 ± 0.9	2.97 ± 0.9	4.65 ± 1.2	.0029	.0015	.0033	.082

Data are numbers of cells.

CNM — control nasal mucosa, ANM — allergic nasal mucosa, NAP — nonallergic nasal polyps, AP — allergic nasal polyps.

in the epithelium was significantly increased in allergic mucosa (77.64% ± 7.5%, p = .0001), nonallergic nasal polyps (70.28% ± 19.2%, p = .0006), and allergic nasal polyps (84.05% ± 10.0%, p = .0011) compared to normal mucosa (23.95% ± 7.2%; Fig 2A). RANTES expression in the vessels was also significantly increased in allergic mucosa (66.74% ± 8.9%, p = .0002), nonallergic polyps (68.55% ± 10.4%, p = .0004), and allergic polyps (67.24% ± 13.5%, p = .0010) compared to normal mucosa (21.07% ± 7.4%; Fig 2B). This finding was also observed in the expression of submucosal cells (1.62 ± 0.7 cells in normal mucosa, 5.96 ± 2.5 in allergic mucosa, 6.67 ± 3.1 in nonallergic polyps, and 5.72 ± 1.3 in allergic polyps; Fig 2B and Table 1). Likewise, IL-5 expression of submucosal cells was increased in allergic mucosa (3.77 ± 0.9, p = .0015), nonallergic polyps (2.97 ± 0.9, p = .0033), and allergic polyps (4.65 ± 1.2, p = .0033) compared to normal mucosa (0.53 ± 0.4; Table 2). However, there was no significant difference in the expression of either RANTES (p > .05) or IL-5 (p = .082) between the nonallergic and allergic groups in patients with nasal polyps (Tables 1 and 2).

There was a significant correlation of RANTES with total (MBP-positive) and activated (EG2-positive) eosinophil numbers in the epithelium (MBP, r = .727, p = .0001; EG2, r = .742, p = .0001) and in the vessels (MBP, r = .867, p = .0001; EG2, r = .854, p = .0001) and submucosal cells (MBP, r = .864, p = .0001; EG2, r = .857, p = .0001; Fig 3A and Table 3). Similar correlations were noted when the mean IL-5–positive cell numbers in the submucosa were analyzed with total and activated eosinophil numbers. A correlation performed between the mean IL-5–positive cell numbers and the total eosinophil numbers yielded r = .812, p = .0001. Further, a correlation performed between IL-5–positive cell numbers and the activated eosinophil numbers yielded r = .723, p = .0004 (Fig 3B and Table 3).

DISCUSSION

In vitro investigations have revealed that RANTES induces eosinophil chemoattraction and release of eosinophil cationic protein.[4,7] However, very little information is available on the in vivo role of RANTES in allergic airway inflammation, which is characterized by eosinophil infiltration in the tissue. Further, there has been a controversy regarding the in vivo role of RANTES in 2 recent studies using BALF in asthmatics.[1,2] The results of these studies using BALF may not fully explain the role of RANTES and IL-5 at the tissue level. Moreover, the importance of RANTES may be more related to its eosinophil chemoattractive ability in a tissue-bound form, rather than a secreted form within the airway lumen, since it has been proposed that intercellular matrix-bound RANTES acts as a major chemotactic mediator of inflammatory cell infiltration.[8,9] In this study, the expression of RANTES and IL-5 increased in the allergic nasal mucosa, and the degree of expression of either cytokine showed a significant correlation with infiltration of eosinophils in the tissue. These results

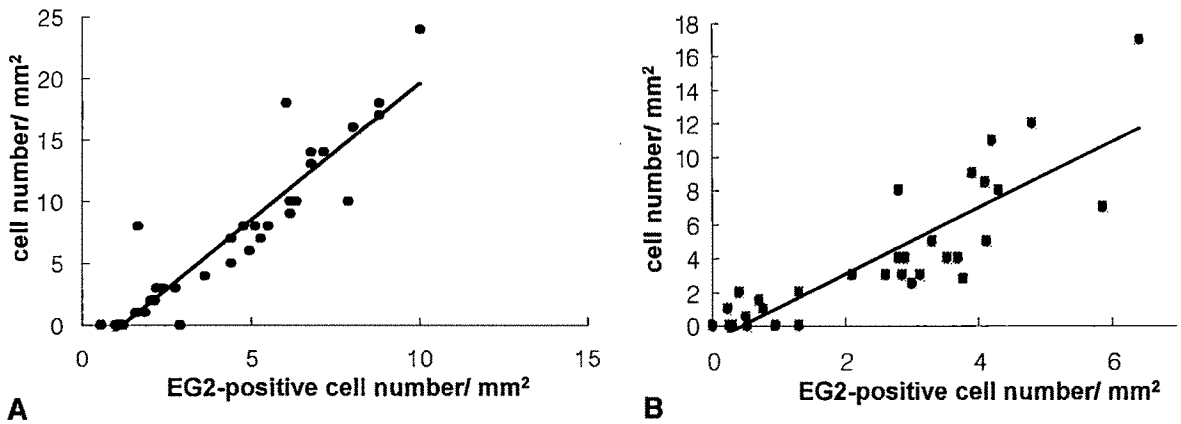

Fig 3. Correlation of A) RANTES and B) IL-5 expression with EG2-positive (activated) eosinophil numbers in submucosa. RANTES and IL-5 show good correlation with activated eosinophil numbers.

TABLE 3. CORRELATION BETWEEN CYTOKINE EXPRESSION AND EOSINOPHIL INFILTRATION

Cytokine	*Monoclonal Antibody*	*Epithelium*	*Submucosa*	*Vessels*
RANTES	MBP	r = .727, p = .0001	r = .864, p = .0001	r = .867, p = .0001
	EG2	r = .742, p = .0001	r = .857, p = .0001	r = .854, p = .0001
Interleukin-5	MBP		r = .812, p = .0001	
	EG2		r = .723, p = .0004	

MBP — major basic protein; EG2 — secreted form of eosinophil cationic protein.

suggest that RANTES and IL-5 may play important roles in eosinophil recruitment in allergic nasal mucosa.

RANTES has been known to be expressed by various cells such as fibroblasts, monocytes and macrophages, T-lymphocytes, and epithelial and endothelial cells.[10-12] In this study, immunoreactivity for RANTES could be localized in the epithelial cells, vascular endothelial cells, and some submucosal cells. In this study, we also demonstrated that the expression of RANTES and IL-5 increased significantly in allergic nasal mucosa and nasal polyps with both allergic and infectious rhinitis, as compared to normal mucosa. It is suggested that both RANTES and IL-5 are responsible for eosinophil infiltration in nasal polyps with and without nasal allergy, as well as in allergic nasal mucosa. Mast cells and eosinophils were reported to be major sources of IL-5 in human allergic mucosal inflammation.[13] The immunoreactivity for IL-5 was confined to several submucosal cells in this study. Bachert et al[14] identified 69.5% of IL-5–positive cells as eosinophils. However, our study does not rule out the possibility that T-lymphocytes are another source of IL-5, because these cells do not store protein and therefore are not expected to be positive in an immunohistochemical study, as Bachert et al suggested. Further, because the inflammation found in the polyps may be due to chronic superinfection of the polyps, further studies including a control with chronic sinusitis only are needed.

REFERENCES

1. Sur S, Kita H, Gleich GJ, Chenier TC, Hunt LW. Eosinophil recruitment is associated with IL-5, but not with RANTES, twenty-four hours after allergen challenge. J Allergy Clin Immunol 1996;97:1272-8.

2. Venge J, Lampinen M, Hakansson L, Rak S, Venge P. Identification of IL-5 and RANTES as the major eosinophil chemoattractants in asthmatic lung. J Allergy Clin Immunol 1996;97:1110-5.

3. Rot A, Krieger M, Brunner T, Bischoff SC, Schall TJ, Dahinden CA. RANTES and macrophage protein 1α induce the migration and activation of normal human eosinophil granulocytes. J Exp Med 1992;176:1489-95.

4. Alam R, Stafford S, Forsythe P, et al. RANTES is a chemotactic and activating factor for human eosinophils. J Immunol 1993;150:3442-8.

5. Sedgwick JB, Calhoun WJ, Gleich GJ, et al. Immediate and late airway response of allergic rhinitis patients to segmental antigen challenge. Characterization of eosinophil and mast cell mediators. Am Rev Respir Dis 1991;144:1274-81.

6. Ohnishi T, Kita H, Weiler D, et al. IL-5 is the predominant eosinophil-active cytokine in the antigen-induced pulmonary late-phase reaction. Am Rev Respir Dis 1993;147:901-7.

7. Ebisawa M, Yamada T, Bickel C, Klunk D, Schleimer RP. Eosinophil transendothelial migration induced by cytokines. III. Effect of the chemokine RANTES. J Immunol 1994;153:2153-60.

8. Gilat D, Hershkoviz R, Mekori YA, Vlodavsky I, Lider O. Regulation of adhesion of CD4+ T lymphocytes to intact or heparinase-treated subendothelial extracellular matrix by diffusible or anchored RANTES and MIP-1 beta. J Immunol 1994;153:4899-906.

9. Tanaka Y, Adams D, Hubscher S, Hirano H, Siebenlist U, Shaw S. T-cell adhesion induced by proteoglycan-immobilized cytokine MIP-1 beta. Nature 1993;361:79-82.

10. Kwon OJ, Jose PJ, Robbins RA, Schall TJ, Williams TJ, Barnes PJ. Glucocorticoid inhibition of RANTES expression in human lung epithelial cells. Am J Respir Cell Mol Biol 1995;12:488-96.

11. Stellato C, Beck LA, Gorgone GA, et al. Expression of the chemokine RANTES by a human bronchial epithelial cell line. Modulation by cytokines and glucocorticoids. J Immunol 1995;155:410-8.

12. Teran LM, Davies DE. The chemokines: their potential role in allergic inflammation. Clin Exp Allergy 1996;26:1005-19.

13. Bradding P, Feather IH, Wilson S, et al. Immunolocalization of cytokines in the nasal mucosa of normal and perennial rhinitic subjects. J Immunol 1993;151:3853-65.

14. Bachert C, Wagenmann M, Hauser U, Rudack C. IL-5 synthesis is upregulated in human nasal polyp tissue. J Allergy Clin Immunol 1997;99:837-42.

GRAFT HEALING IN LARYNGOTRACHEAL RECONSTRUCTION: AN EXPERIMENTAL RABBIT MODEL

IAN N. JACOBS, MD
PHILADELPHIA, PENNSYLVANIA
SCOTT D. BODEN, MD
ATLANTA, GEORGIA
PIERRE PODREBARAC, MD
ATLANTA, GEORGIA
MICHAEL CHEN, MD
ATLANTA, GEORGIA

The actual sequence of events in graft healing in laryngotracheal reconstruction (LTR) is not well understood. To investigate sequential changes in graft healing, we submitted 21 rabbits to LTR with an anterior auricular cartilage graft. They were immediately extubated after surgery, and no stent was used. Rabbits were painlessly sacrificed at 7 different time periods (0, 1, 2, 3, 4, 6, and 10 weeks after surgery). Cross sections of the larynx and graft were cut and stained with hematoxylin-eosin and trichrome. Epithelialization progressed very rapidly and was complete by 21 days. During the 10 weeks, there was a progressive necrosis and resorption of the original graft cartilage. However, neochondrification progressed very rapidly and resulted in excellent structural support of the graft in the airway. Problems, such as infection and granulation tissue formation, were relatively minor and infrequent.

KEY WORDS — epithelialization, laryngotracheal reconstruction, neochondrification, subglottic stenosis.

INTRODUCTION

The management of subglottic stenosis depends on several factors, including the age and size of the patient, as well as the location and severity of the stenosis. The mainstay for repair of severe subglottic stenosis is laryngotracheal reconstruction (LTR) with autologous cartilage grafts.[1-5] This technique involves the expansion of the diameter of the subglottic airway with the insertion of elliptically shaped cartilage grafts (Fig 1). Costal or auricular cartilage may serve as graft material. Grafts may be placed in the anterior position, the posterior position, or both. The placement site depends on the location and severity of the stenosis.

The ideal laryngotracheal graft should conform to the shape of the airway lumen and maintain structural support of the airway. The graft should have enough structural rigidity to prevent collapse of the lumen. The survival of the original graft cartilage is important to maintaining the structural integrity of the graft in the airway.

Both clinical and animal studies have established that autologous cartilage grafts survive in both positions.[5-9] Zalzal et al[7] performed LTR with an autologous costal cartilage graft in the anterior position of the larynx in 50 New Zealand White rabbits. They maintained perichondrium on the luminal surface of the airway in 32 of the 50 rabbits and performed his-

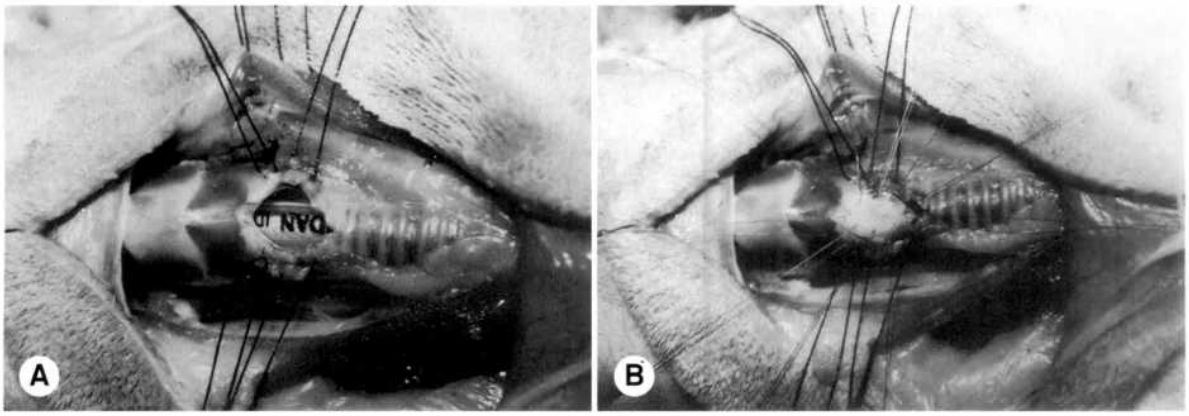

Fig 1. Techniques. A) Laryngofissure in rabbit airway. B) Auricular cartilage graft sutured into anterior position.

From the Division of Otolaryngology (Jacobs, Podrebarac) and the Department of Orthopedics (Boden, Chen), Emory University School of Medicine, Atlanta, Georgia. This study was supported by the Emory University Committee Grant. It was performed in accordance with the PHS Policy on Humane Care and Use of Laboratory Animals, the NIH *Guide for the Care and Use of Laboratory Animals*, and the Animal Welfare Act (7 U.S.C. et seq.); the animal use protocol was approved by the Institutional Animal Care and Use Committee (IACUC) of Emory University.

CORRESPONDENCE — Ian N. Jacobs, MD, The Children's Hospital of Philadelphia, Division of Otolaryngology, 34th St and Civic Center Blvd, First Floor, Wood Center, Philadelphia, PA 19104.

tologic examination of the specimens at 2 and 4 months. They found histologic evidence of complete epithelialization and qualitative survival of the original costal cartilage in 29 of the 32 specimens. However, 4 of the 14 rabbits without perichondrium on the luminal surface developed cartilage infection and necrosis and died. An additional 3 cases had partial infection with qualitative evidence of graft cartilage survival.[7]

Further, Cotton[5] performed quantitative histologic analysis of auricular cartilage grafts in the airway of 32 New Zealand White rabbits. The study compared the survival and fate of autologous auricular cartilage grafts in both the anterior and posterior positions of the larynx at 1 point in time (2 months). Nine rabbits were excluded from analysis because of infection of the grafts and premature death. Most of the graft cartilage of the remaining specimens survived in both positions. However, both anteriorly and posteriorly placed grafts developed substantial necrosis and resorption of the original cartilage, as well as a significant degree of neochondrification. The posteriorly placed grafts developed less necrosis and resorption and more neochondrification than the anteriorly placed grafts. In fact, in Cotton's study, a mean of 43.4% of the original anterior cartilage necrosed and resorbed, compared to 16% of the original posterior graft cartilage.[5]

Graft healing in LTR is a dynamic and progressive process with potential complications. Therefore, it is important to analyze the chronological changes in the cartilage graft over time, including the development of potential problems such as excessive cartilage necrosis, graft infection, and the formation of granulation tissue. Further, no previous investigator has analyzed the crucial dynamic changes in graft healing in a sequential fashion. The main purpose of this investigation was to determine the sequence of events in graft healing in a rabbit model of LTR. It is not known how quickly cartilage grafts epithelialize and become securely incorporated into the graft insertion site. In addition, the basic histologic model of graft healing in LTR will serve as a basis for future experimental studies of graft healing.

MATERIALS AND METHODS

Laryngotracheal reconstruction was performed on 21 female New Zealand White rabbits. The rabbits, which weighed 4.0 to 4.5 kg, were administered an intramuscular injection of xylazine hydrochloride (6 mg/kg) and ketamine hydrochloride (30 mg/kg). They were intubated and maintained on isoflurane (1%) throughout the surgery. The neck and left ear were shaved and prepared with Betadine solution. A transverse incision was made over the dorsal surface of the left ear. The perichondrial surface of the auricular cartilage was isolated, and a 20 × 15-mm section of cartilage was excised with the perichondrium intact on the dorsal surface. The cartilage graft was kept moist in a saline-soaked gauze. The ear skin incision was closed with a running 4-0 Vicryl suture.

The rabbit was then positioned in a supine, hyperextended position on a shoulder roll. A 3-cm transverse incision was made at the level of the subglottic region. The sternohyoid and sternothyroid muscles were separated to expose the larynx in the midline. An anterior laryngofissure was made through the cricoid cartilage and upper 2 tracheal rings (Fig 1A). A 20 × 15-mm section of translucent radiographic film was used as a template to shape an elliptical anterior cartilage graft. The graft was secured to the cut edges of the divided cricoid and tracheal cartilage by means of 10 or 11 interrupted 6-0 Prolene sutures (Fig 1B). At the end of the procedure, the rabbit was given positive pressure ventilation to check for air leaks. The wound was then copiously irrigated with saline solution. The muscle and skin were closed in layers with interrupted 4-0 Vicryl sutures. The rabbits were immediately extubated after surgery. No antibiotics were employed.

Three rabbits were painlessly sacrificed immediately after surgery and at each of the later time periods (1, 2, 3, 4, 6, and 10 weeks after surgery). The larynx and trachea were harvested and placed in 10% formalin solution for fixation. The larynx was transversely divided at the center of the cartilage graft. A 2-mm-thick horizontal section from the midportion of the graft was removed and embedded in paraffin. Five-micron-thick cross sections were cut on a microtome. They were placed on glass slides and stained with hematoxylin-eosin and trichrome.

All the stained specimens underwent quantitative histologic analysis with a semiautomated Optomax V Image Analyzer (Optomax, Hollis, NH). After a cursor was used to outline the images of interest on a magnified monitor screen, computed measurements of area, length, and circumference were made with the VIDS V program (Optomax). The following measurements were made for each specimen: 1) percentage of the graft surface covered with epithelium (Fig 2); 2) length of the graft surface that was epithelialized (millimeters), 3) area of the tracheal lumen (square millimeters), 4) area of the entire cartilage graft (square millimeters), and 5) areas of neochondrification (square millimeters). Then, on the trichrome stains, the areas of viable and necrotic cartilage within the graft were determined and calculated



Fig 2. Results. Partial surface epithelialization at 1 week after surgery (original ×40). Arrow shows direction of epithelial migration over original cartilage graft (A). Note that most of newly formed epithelial cells (leading edge) are flattened and cuboidal.

as a percentage of the entire cartilage graft (Fig 3). The results of the 3 specimens at each time period were averaged, and the standard error was calculated for each time period. The time zero controls, which were painlessly sacrificed immediately after surgery, were used as an example of viable cartilage.

RESULTS

Twenty of the 21 rabbits survived the entire postoperative period. There were no major wound infections. None of the rabbits had signs of upper airway obstruction. However, 1 rabbit died suddenly of airway obstruction from a mucous plug. This was on the seventh day after surgery, following an uncomplicated postoperative course. The graft was completely intact and underwent histologic analysis as a 1-week specimen. In addition, 2 rabbits developed small areas of granulation tissue on the intraluminal surface at 2 and 4 weeks. These were small and did not compromise the airway (Fig 4). However, there was a higher degree of infection and necrosis of the original cartilage graft in these 2 specimens relative to other specimens at the same time period (8.4% at 2 weeks and 30.7% at 4 weeks). Epithelialization was rapid and reached 100% coverage within 3 weeks (Table 1). The initial epithelial cells were small and cuboidal (Fig 2), but by 6 weeks had transformed into ciliated columnar respiratory epithelium (Fig 5). The area of the laryngotracheal lumen remained relatively constant over time (Table 1).

The original cartilage graft changed dramatically in a short period of time. At 1 week, the original graft started to undergo necrosis (1.5%). This progressed to 39% at 10 weeks after surgery (Table 2).

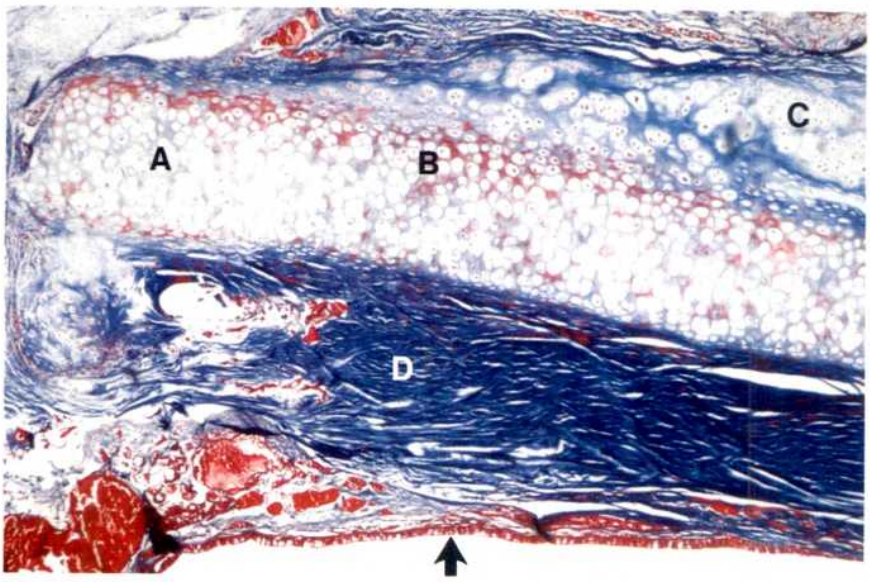

Fig 3. Results. Cartilage graft 6 weeks after surgery (original ×100). Note original cartilage graft with cartilage necrosis (A) and viable cartilage (B). Neochondrification (C) occurs on extraluminal surface of graft. This also shows complete epithelial layer of cells (arrow) and thick layer of fibrous tissue (D) between epithelium and graft.

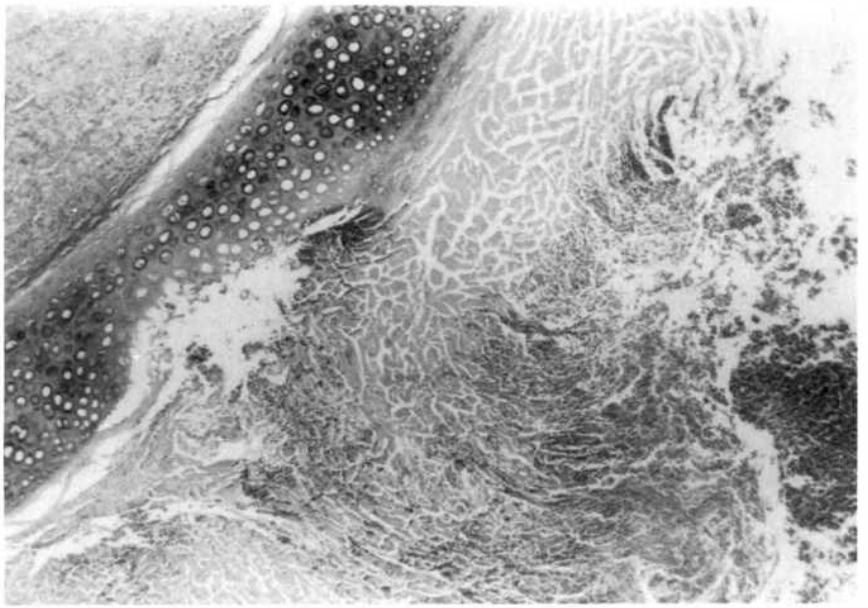

Fig 4. Graft with inflammatory granulation tissue (original ×100). Note infiltration of chronic inflammatory cells and necrosis of cartilage.

However, as the original cartilage graft necrosed and resorbed, there was a simultaneous and progressive increase in the formation of new cartilage. This occurred on the extraluminal surface of the graft and both cut ends of the tracheal cartilage (Table 2 and Fig 3). The area of neochondrification reached a maximum of 1.85 mm at 10 weeks. In some cases, the neochondrification process did alter the shape of the cartilage graft (Fig 6).

DISCUSSION

This study clearly demonstrated the sequential histologic changes in an autologous laryngotracheal cartilage graft as a function of time. The free laryngotracheal cartilage graft undergoes multiple dramatic changes that may impact on the structural integrity of the graft. First, the luminal surface of the graft is rapidly epithelialized. The complete epithelial lining will protect the cartilage graft from infection by the respiratory tract. From the beginning, the epithelium grows from the lateral free edge toward the midline. This growth results in complete epithelial coverage of the graft by 21 days.

Surface epithelialization is a rapid process in most regions of the human body. On the epidermal surface, small linear wounds require 3 to 5 days for complete epithelialization to occur. The process begins 12 hours after formation of the wound with epithelial migration. Subsequent events include the formation of the basement lamina, differentiation of the epidermis, and keratinization.[10] Larger open surfaces may require longer periods of time for epithelialization to occur. In the experimental rabbit model, the cartilage grafts were completely epithelialized by 21 days after surgery, although the process starts immediately after surgery. The initial epithelial layer at 3 weeks was composed of flattened cuboidal cells, which gradually differentiated into a mature respiratory epithelium at the later time periods. Since stents were not used in this experiment, epithelialization occurred rapidly over an unimpeded free surface. Wiatrak et al[11] previously demonstrated that stents may retard the epithelialization process.

TABLE 1. HISTOLOGIC ANALYSIS

Time (wk)	*Surface Epithelialization (%)*	*Tracheal Lumen Area (mm^2)*
0	0 ± 0.0	20.5 ± 1.2
1	52 ± 1.11	22.5 ± 2.09
2	53 ± 13.0	24.6 ± 0.95
3	100 ± 0.0	23.4 ± 0.42
4	100 ± 0.0	19.8 ± 4.10
6	100 ± 0.0	23.6 ± 0.66
10	100 ± 0.0	22.1 ± 0.91

Data are mean ± SE.

While epithelialization is occurring, the original cartilage graft undergoes dramatic changes over time, including cartilage necrosis, resorption, and neochondrification. Assessment of these changes in cartilage viability can be done in several ways. Histologic analysis, which is a reliable method to assess cartilage viability, was used in this experiment. On histologic examination, cartilage death is manifested by large, empty cartilage cells with loss of nuclei and massive inflammatory cellular infiltration (Fig 4). In contrast, viable cartilage cells contain both nuclei and chromatin. Cartilage necrosis can also be assessed biochemically (ie, hydroxyproline) or by use of radioactive tracers.[6,7] In this study, the time zero control specimens demonstrated the histologic appearance of viable auricular cartilage cells and matrix with our staining techniques.

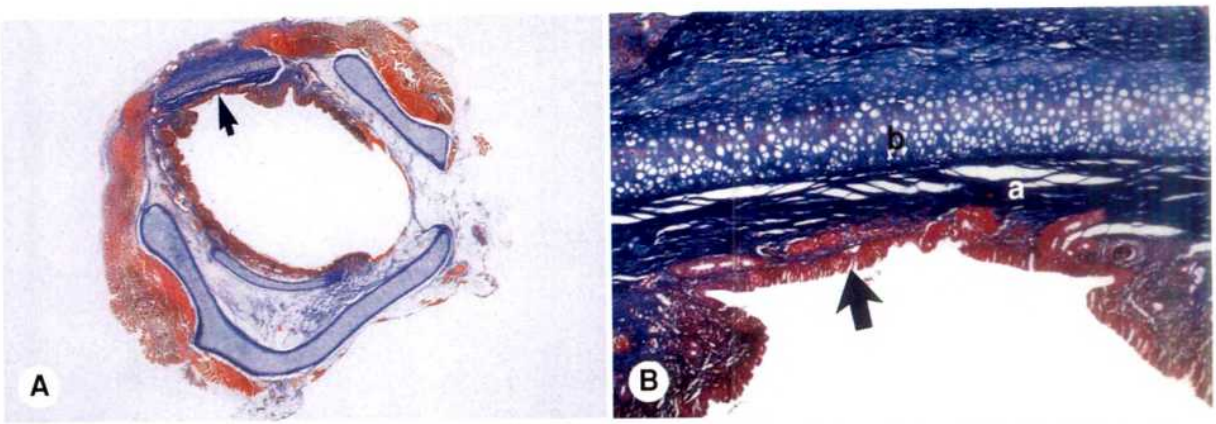

Fig 5. Results. A) Whole mount view of complete laryngotracheal airway showing complete epithelialization (arrow) at 6 weeks after surgery (original ×2). B) Close-up view (original ×40) showing complete layer of newly formed respiratory epithelium (arrow) over thick layer of fibrous tissue (a) and intact viable cartilage graft (b).

The original cartilage graft changed dramatically during the study period. In most cases, the graft underwent a significant degree of necrosis and resorption. Nevertheless, the area of viable cartilage remained relatively constant, as there was a simultaneous increase in new cartilage. The resorbed cartilage was largely replaced with new cartilage and firm fibrous tissue. The original cartilage graft acted as a "scaffold" for epithelialization, as well as neochondrification and the formation of fibrous tissue. New cartilage formed on the external surface of the graft and both cut ends of the tracheal cartilage, changing the overall shape and configuration of the original cartilage graft. Nevertheless, the structural support of the graft as an "airway expander" was still maintained. In all cases, the grafts remained in stable position without the support of a stent or endotracheal tube.

While none of the rabbits had any major problems with graft healing, there were a number of relatively minor problems. First, 2 rabbits developed small areas of granulation tissue and infection on the luminal surface of the graft. These appeared as small mounds of chronic inflammatory cells that were partially covered with an epithelial lining and protruded slightly into the lumen of the airway. Both processes were small and did not compromise the airway. However, they did result in a higher degree of cartilage necrosis and resorption (Fig 4). This inflammatory process was associated with increased necrosis of cartilage on the luminal surface of the airway. In addition, 1 rabbit died suddenly of a mucous plug. However, the graft was completely intact in the airway, and histologic analysis revealed that the graft cartilage was 100% viable and partially epithelialized (55%).

TABLE 2. CARTILAGE GRAFT SURVIVAL

Time (wk)	*Area of Original Cartilage Graft (mm^2)*	*Percent Viable Cartilage*	*Percent Necrosed Cartilage*	*Area of New Cartilage (mm^2)*
0	1.92 ± 0.0	100.0 ± 0.0	0.0	0.00 ± 0.0
1	2.79 ± 0.22	98.5 ± 0.19	1.5	0.07 ± 0.04
2	2.12 ± 0.39	95.6 ± 1.61	4.4	0.32 ± 0.13
3	1.58 ± 0.14	84.0 ± 7.56	16.0	0.29 ± 0.02
4	1.85 ± 0.60	75.5 ± 2.52	24.5	0.62 ± 0.13
6	1.85 ± 0.11	79.5 ± 10.74	20.5	1.00 ± 0.25
10	2.42 ± 0.51	61.0 ± 3.98	39.0	1.85 ± 1.13

Data are mean ± SE. Original graft (100%) = % Viable cartilage + % Necrosed cartilage.

Even though the rabbit experiment clearly demonstrated the overall trend in graft healing, the study still had several shortcomings. The first is the fact that while general trends are valid, rabbit wound healing may differ from human wound healing. Rabbits were chosen because they are a reliable model of the infant airway, and they have been used extensively in the past as an animal model for airway procedures. Further, it would have been impossible to conduct this type of histologic analysis in humans. The second major weakness was the use of auricular cartilage grafts, since costal cartilage grafts are commonly used in human LTR. Auricular grafts were chosen for ease of access. Auricular and costal cartilage are very different on a chemical and molecular level and may have different healing tendencies. Nevertheless, some clinicians use auricular grafts in human LTR with excellent results.[12]

The third shortcoming was that the rabbits in the study had a normal airway prior to the LTR. This experimental model correlates most closely with graft healing for mild or moderate cases of subglottic stenosis. It probably would have been ideal to study graft healing in a rabbit with experimentally induced severe subglottic stenosis. However, this would require a tracheotomy, which would be diffi-

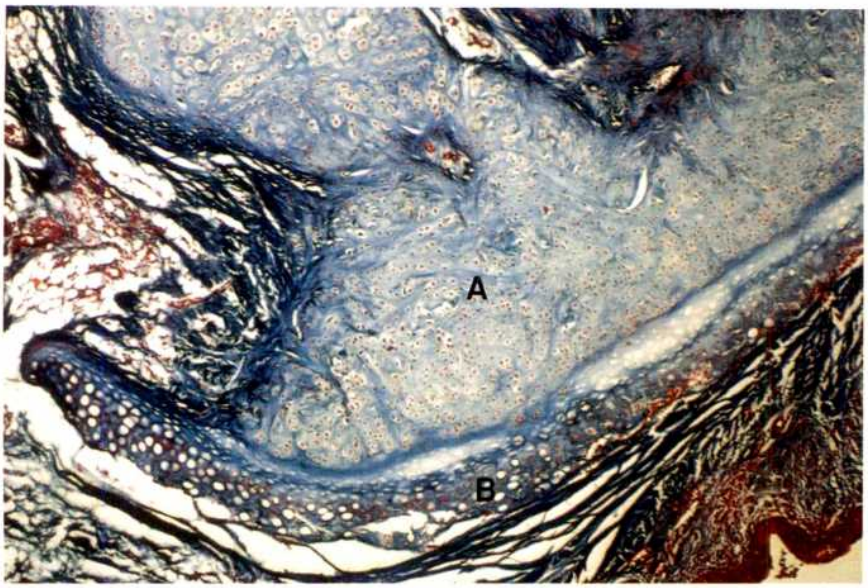

Fig 6. Substantial areas of neochondrification (A) on extraluminal surface of original graft (B). Note "remodeled" shape and configuration of cartilage graft.

cult to maintain in a chronic rabbit experiment.

Therefore, future studies are needed to optimize the graft healing process for the more severe grades of subglottic stenosis. The histologic rabbit model of LTR may serve as a basis for future studies. For instance, certain growth factors such as epidermal growth factor or bone morphogenetic protein could be used to accelerate epithelialization and strengthen the graft with the formation of new cartilage and bone, respectively. These growth factors may be applied to experimental grafts and analyzed in the same manner, with comparison to controls. This may be beneficial for the more severe grades of stenosis, in which excellent cartilaginous support is required. The "remodeling" of the original cartilage by necrosis, resorption, and neochondrification may not result in the ideal graft configuration for the more advanced grades of stenosis. Certain growth factors may alter this process. In addition, aerosolized steroids may retard the inflammatory response and decrease granulation tissue formation on the luminal surface. An analysis of these manipulations is important for future clinical work in pediatric airway reconstruction.

SUMMARY

This study demonstrated the sequential histologic events of graft healing. Graft healing in LTR is both a rapid and dynamic process. Epithelialization was complete in 21 days. Dramatic changes in the cartilage graft, such as resorption and neochondrification, started early and evolved rapidly over time. Eventually, most of the resorbed cartilage was replaced with new cartilage. These changes resulted in a progressive "remodeling" of the configuration of the original cartilage graft. Wound healing problems included inflammatory granulation tissue on the luminal surface of the graft that resulted in a greater degree of cartilage necrosis and resorption. However, in most cases there was near-perfect graft healing and complete epithelialization by 3 weeks. In addition, all the grafts were stable in the airway, without a stent or endotracheal tube. The sequential histologic model of graft healing will serve as a control model for future experimental studies.

REFERENCES

1. Cotton RT, Zalzal GH. Glottic and subglottic stenosis. In: Cummings CW, ed. Otolaryngology–head and neck surgery. St Louis, Mo: CV Mosby, 1993:1981-2000.

2. McDonald IH, Stocks JG. Prolonged nasotracheal intubation: a review of its development in a pediatric hospital. Br J Anaesth 1965;37:161-73.

3. Cotton R. Management of subglottic stenosis in infancy and childhood. Review of a consecutive series of cases managed by surgical reconstruction. Ann Otol Rhinol Laryngol 1978;87:649-57.

4. Cotton RT, Seid AB. Management of the extubation problem in the premature child. Anterior cricoid split as an alternative to tracheotomy. Ann Otol Rhinol Laryngol 1980;89:508-11.

5. Cotton RT. The problem of pediatric laryngotracheal stenosis: a clinical and experimental study on the efficacy of autogenous cartilage grafts placed between the vertically divided halves of the posterior lamina of the cricoid cartilage. Laryngoscope 1991;101(suppl 56).

6. Zalzal GH, Cotton RT, McAdams AJ. Cartilage grafts. Present status. Head Neck Surg 1986;8:363-74.

7. Zalzal GH, Cotton RT, McAdams AJ. The survival of the costal cartilage graft in laryngotracheal reconstruction. Otolaryngol Head Neck Surg 1986;94:204-11.

8. Pashley NR, Jaskunas JM, Waldstein G. Laryngotracheoplasty with costochondral grafts. A clinical correlate of graft

survival. Laryngoscope 1984;94:1493-6.

9. Cotton RT, Evans JNG. Laryngotracheal reconstruction in children. Five-year follow-up. Ann Otol Rhinol Laryngol 1981;90:516-20.

10. Odland G, Ross R. Human wound repair I. Epidermal regeneration. J Cell Biol 1968;39:135-51.

11. Wiatrak BJ, Albert DM, Holmes DK, Cotton RT. Cartilage graft epithelialization. A preliminary study using a goat model. Arch Otolaryngol Head Neck Surg 1993;119:777-81.

12. Lusk RP, Gray S, Muntz HR. Single-stage laryngotracheal reconstruction. Arch Otolaryngol Head Neck Surg 1991;117:171-3.

PHONOSURGERY

The European Laryngological Society's Workshop 1999: Phonosurgery will be held, in English, October 9-10, 1999, in Graz, Austria. For more information, contact Prof Dr G. Friedrich, Department of ENT, University of Graz, Medical School, Auenbruggerplatz 20, Graz, Austria; telephone ++43/316/385-2579; fax ++43/316/385-3549; e-mail gerhard.friedrich@kfunigraz.ac.at.

Ann Otol Rhinol Laryngol 108:1999

SWALLOWING DISORDERS IN PARALYSIS OF THE LOWER CRANIAL NERVES: A FUNCTIONAL ANALYSIS

SOPHIE PÉRIÉ, MD
PARIS, FRANCE
LAURENT COIFFIER, MD
PARIS, FRANCE
LAURENT LACCOURREYE, MD
ANGERS, FRANCE
VINCENT HAZEBROUCQ, MD
PARIS, FRANCE
STANISLAS CHAUSSADE, MD
PARIS, FRANCE
JEAN LACAU ST GUILY, MD
PARIS, FRANCE

Deficits of the lower cranial nerves (nerves IX, X, XI, and XII) occurring after treatment of skull base tumors may cause disabling swallowing disorders. To assess the mechanisms of swallowing disorders involved in such cases, we performed functional examinations: a videoendoscopic swallowing study and simultaneous manometry and videofluoroscopy in 7 patients. This study shows that the main mechanism of the swallowing disorders was a disturbance of the pharyngeal stage, including a decrease of pharyngeal propulsion, reduced laryngeal closure, and cricopharyngeal dysfunction, which led to aspiration. Decreased pharyngeal propulsion was found in 6 patients, with a very high correlation between fiberoscopy and simultaneous manometry-fluoroscopy. The responsibility of the upper esophageal sphincter in swallowing disorders was more difficult to assess. The role of the upper esophageal sphincter and pharyngeal propulsion in the onset of the problem is discussed in regard to the cricopharyngeal myotomy.

KEY WORDS — aspiration, cranial nerves, fluoroscopy, manometry, pharyngeal propulsion, swallowing disorders, upper esophageal sphincter, videoendoscopic swallowing study.

INTRODUCTION

The coordinated action of the muscles involved in swallowing is controlled by sensory and motor innervations provided from the trigeminal (V), facial (VII), glossopharyngeal (IX), vagus (X), spinal (XI), and hypoglossal (XII) cranial nerves.[1] The sequence of events of normal deglutition is well known and provides helpful guidelines in studying swallowing disorders.[2] However, the nature of swallowing dysfunction remains difficult to assess in some neurologic conditions, since both oral and pharyngolaryngoesophageal stages of the swallowing process may be impaired simultaneously, creating complex disorders. Paralyses of the lower cranial nerves are observed in various conditions such as skull base tumors and surgical traumas.[3-5]

Functional assessment of swallowing has evolved during the last 10 years with the use of videofluoroscopy, manometry of the pharynx and upper esophageal sphincter (UES), and videoendoscopic swallowing study (VESS).[6-11] The classic neurologic features of cranial nerve paralysis are well described. However, the swallowing functions observed through fiberoscopy, manometry, and videofluoroscopy have not been well described in patients with neurogenic dysphagia. The impairment of the UES in cranial nerve paralysis is of special therapeutic interest.

The purpose of this study was to assess which mechanisms are involved in neurogenic swallowing disorders caused by deficits in cranial nerves IX, X, XI, and XII. The role of the UES and pharyngeal propulsion is studied in these conditions, and the possible benefit of cricopharyngeal myotomy is discussed.

PATIENTS AND METHODS

Seven patients were included in this study. Five patients were female and 2 patients were male. The patients ranged in age from 19 to 75 years, with a mean age of 50.6 years. Patients were referred to our institution for swallowing disorders from December 1994 through October 1995. Swallowing disorders were related to a paralysis of cranial nerves IX, X, XI, and/or XII. Paralysis resulted from the removal of skull base tumors in 4 cases (tympanicum-jugulare paragangliomata, posterior fossa neuroma, cerebellopontine angle neuroma and meningioma), from skull base tumors that had been irradiated in 2 cases (cerebellopontine angle neuroma, nasopharyngeal cancer), and from a bypass operation of the cervical carotid artery in 1 case (Table 1). None of these patients had symptoms of dysphagia before their treatment. The time between cranial nerve deficit and evaluation varied from 1 month to 4 years (median 18.1 months). One patient was subjected to

From the Department of Otorhinolaryngology–Head and Neck Surgery, Faculté de Médecine Saint Antoine, Université Paris VI, Hôpital Tenon (Périé, Coiffier, Laccourreye, Lacau St Guily), and the Departments of Radiology (Hazebroucq) and Hepato-Gastroenterology (Chaussade), Faculté de Médecine Cochin, Université Paris V, Hôpital Cochin, Paris, France.

CORRESPONDENCE — Sophie Périé, MD, Service d'Oto-Rhino-Laryngologie et Chirurgie de la Face et du Cou, Hôpital Tenon, 4, rue de la Chine, 75020 Paris, France.

TABLE 1. CAUSES AND TREATMENT OF PARALYSES OF CRANIAL NERVES

Case No.	Age (y)	Disease	Treatment
1	19	Tympanicum-jugulare paragangliomata	Surgery
2	30	Nasopharyngeal cancer	Radiotherapy
3	41	Posterior fossa neuroma	Surgery
4	75	Cerebellopontine angle neuroma	Radiotherapy
5	64	Thrombosis of cervical carotid artery	Surgery
6	68	Cerebellopontine angle meningioma	Surgery
7	57	Cerebellopontine angle neuroma	Surgery of tumor and cricopharyngeal myotomy

surgical treatment (cricopharyngeal myotomy) prior to this evaluation (case 7). The clinical examinations, VESS, and follow-up were performed by the senior author (J.L.S.G.).

Symptoms, including dysphonia, dyspnea, dysphagia, blockage, multiple attempts to swallow each bolus, signs of aspiration, choking, and nasopharyngeal reflux, were recorded. Clinical examinations studied the lips, tongue, palate, larynx, and pharynx at rest and when swallowing. Motor functions and sensations were noted, as well as laryngeal elevation on voluntary swallowing of saliva.

Functional assessment of deglutition was performed on all patients and included 1) an examination during swallowing of dry and cream swallows by flexible fiberoptic laryngoscopy (Olympus ENF P3 or Machida ENT 3L) with video recording (VESS), and 2) a simultaneous pharyngeal-UES manometry and videofluoroscopy performed by separate investigators (V.H. and S.C.).

The protocol for VESS has been previously described.[8,10,11] Manometric analysis was carried out in all patients with a solid-state sleeve catheter (Konigsberg Instruments Inc, Pasadena, Calif), as described by Castell and Castell[6] in 1993. The circumferential transducer had a pressure rise rate of >2,000 mm Hg/s. Three transducers were located 3, 6, and 9 cm above the UES. The protocol for the videofluoroscopic study was based on modified barium swallow study.[12] Patients swallowed a radiopaque liquid (2 to 20 mL) or radiopaque paste, and/or cookies coated with barium. The images obtained in the lateral and posteroanterior positions were simultaneously observed with the manometric recording, by means of a computerized system. The manofluoroscopic recording was evaluated after 10 dry swallows.

The following features were recorded at the time of VESS and/or at simultaneous manometry and videofluoroscopy (Tables 2-4): 1) motor cranial nerve dysfunctions and laryngeal sensation (normal or decreased); 2) pharyngeal function, including initiation, propulsion, laryngeal elevation, and closure, and the coordination between pharyngeal propulsion and UES relaxation (normal or decreased); 3) pooling of saliva or cream, nasal reflux, and/or aspiration (absent or present); 4) UES manometric pressure at rest and UES relaxation, as well as UES opening at fluoroscopy (normal or decreased).

Laryngeal sensation was tested by touching the larynx with the tip of the flexible fiberoptic laryngoscope.[8] It was considered normal when it induced a gag response, and decreased when the stimulus induced a delayed or no gag response. Initiation of swallowing during VESS[11] was considered normal when the tongue action, as it propelled the bolus backward, triggered a pharyngeal swallow. A decreased initiation during VESS was characterized by a loss of the bolus into the pharynx before the pharyngeal swallow was elicited. Laryngeal closure during VESS[8] was considered normal when, during phonation, dry swallow, or cough, no glottic chink between the vocal folds was observed (Table 2).

Pharyngeal propulsion was considered normal when peristaltic waves in the pharyngeal constrictors propelled the entire cream bolus (laryngophar-

TABLE 2. RESULTS OF CLINICAL AND FIBEROSCOPY EXAMINATIONS

Case No.	Time From Nerve Deficit to Examination	Cranial Nerves Impaired	Laryngeal Sensation	Feeding Regimen	Swallowing Initiation at Fiberoscopy	Larynx Closure at Fiberoscopy
1	2 mo	VII, IX, X, XI, XII	Normal	Normal	Normal	Decreased
2	4 y	IX, X, XI, XII	Decreased	Selective	Decreased	Normal
3	7 mo	IX, X, XI, XII	Decreased	Blended	Normal	Decreased
4	2 mo	X	Normal	Normal	Normal	Decreased
5	1 mo	X	Normal	Selective	Normal	Normal
6	19 mo	IX, X	Normal	Gastrostomy tube	Decreased	Decreased
7	4 y	IX, X, XI, XII	Normal	Blended	Decreased	Decreased

TABLE 3. RESULTS OF FIBEROSCOPY AND SIMULTANEOUS MANOMETRY AND VIDEOFLUOROSCOPY

Case No.	*Cranial Nerves Impaired*	*Pharyngeal Propulsion*	*Larynx Elevation*	*Stasis*	*Nasal Reflux*	*Aspiration*
1	VII, IX, X, XI, XII	Decreased	Normal	+	+	–
		Decreased	Normal	+	–	–
2	IX, X, XI, XII	Decreased	Normal	+	–	+
		Decreased	Normal	+	–	–
3	IX, X, XI, XII	Decreased	Normal	+	+	+
		Decreased	Normal	+	–	–
4	X	Normal	Normal	–	–	+
		Normal	Decreased	–	+	–
5	X	Decreased	Normal	+	–	+
		Decreased	Decreased	+	–	+
6	IX, X	Aperistalsis	Decreased	+	–	+
		Aperistalsis	Decreased	+	–	+
7	IX, X, XI, XII	Aperistalsis	Normal	+	–	–
		Aperistalsis	Decreased	+	–	–

Top rows are results of fiberoscopy; bottom rows are results of simultaneous manometry and videofluoroscopy.
+ — present; – — absent.

ynx closure temporarily obscured any view) and cleared the pharyngeal residue (ie, generation of pressures within the pharynx, and visualization of effective peristaltic waves that transport the bolus with no pharyngeal pooling of contrast material on manofluoroscopy). Decreased pharyngeal propulsion was noted when residual pharyngeal propulsion and decreased pharyngeal clearance were observed, resulting in moderate pharyngeal pooling (ie, decreased pharyngeal pressures, some pharyngeal waves, and moderate pharyngeal pooling of contrast material on manofluoroscopy). Aperistalsis was noted when very slight pharyngeal contractions or no peristalsis was observed (the laryngopharynx remained visible during the pharyngeal swallow), resulting in marked pooling of food materials in the pharynx (ie, no generation of pharyngeal pressure, no pharyngeal contractions, and markedly pooled contrast material on manofluoroscopy). Laryngeal elevation was recorded as normal when the larynx moved toward the base of the tongue during swallowing (positioning the fiberoscope just above the palate, ie, anterior elevation of hyoid bone and larynx toward the base of the tongue on fluoroscopy). Stasis was defined as the pooling of saliva, cream, or contrast material in the oral cavity, valleculae, epilarynx, pharynx, or pyriform fossae on fiberoscopy and fluoroscopy. Nasal reflux was considered present when reflux of saliva, food substances, or contrast material was observed at the level of the palate on fiberoscopy and fluoroscopy. Aspiration was noted to be present when saliva, cream, or contrast material penetrated below the level of the vocal cords on fiberoscopy and fluoroscopy (Table 3).

Coordination was considered normal when the beginning, peak, and end of pharyngeal contraction were synchronous with the beginning, nadir, and end of UES relaxation.[6] The UES relaxation was considered normal when it was consistently complete (UES resting pressure decreasing by more than 80%). Decreased UES relaxation was noted to indicate incomplete or shortened UES relaxation. The UES opening was considered normal when it was complete and synchronous with pharyngeal bolus transport. It was considered decreased when it was de-

TABLE 4. COORDINATION BETWEEN PHARYNGEAL PROPULSION AND UES RELAXATION, AND UES FUNCTION AT SIMULTANEOUS MANOMETRY AND VIDEOFLUOROSCOPY

Case No.	*Cranial Nerves Impaired*	*Coordination on Manometry*	*UES Pressure at Rest on Manometry*	*UES Relaxation on Manometry*	*UES Opening on Fluoroscopy*
1	VII, IX, X, XI, XII	Normal	Normal	Normal	Normal
2	IX, X, XI, XII	Normal	Normal	Normal	Decreased
3	IX, X, XI, XII	Decreased	Normal	Decreased	Decreased
4	X	Decreased	Normal	Normal	Decreased
5	X	Decreased	Normal	Decreased	Decreased
6	IX, X	Decreased	Normal	Normal	Decreased
7	IX, X, XI, XII	Normal	Decreased	Normal	Normal

UES — upper esophageal sphincter.

layed or reduced, or when the closure was early (Table 4).

The consequences of swallowing disorders were evaluated by 1) the type of feeding, whether oral (normal, blended, or selective diet) or by gastrostomy feeding tube; 2) weight loss; and 3) occurrence of fever and/or pneumonia from aspiration.

RESULTS

Neurologic and otolaryngological examinations showed that the dysfunctions of swallowing were related to a partial or complete paralysis of unilateral lower cranial nerves IX, X, XI, and/or XII. Paralyses of nerve X, nerves IX and X, and nerves IX, X, XI, and XII were observed in 2, 1, and 4 patients, respectively (Table 2).

Symptoms included dysphonia (6 patients), nasal voice (3 patients), blockage (2 patients), aspiration (4 patients), and nasal regurgitation of liquids (2 patients).

The tongue was paralyzed and deviated toward the side of paralysis in 3 patients, and in 1 patient, tongue weakness was noted. The soft palate was paralyzed in 5 patients. Paralysis of the posterior pharyngeal wall was observed in 6 patients. The vocal fold was fixed in an intermediate or paramedian position in 6 patients. Mobility of the vocal fold was normal in 1 patient, but the motion of its arytenoid was decreased (case 5). The pyriform fossa was opened in 5 patients, and the hypopharynx showed pooling of saliva in 6 patients.

Analysis of the deglutition of dry and cream swallows by VESS (Tables 2 and 3) showed diminished laryngeal sensation in 2 patients, a delay of elicitation of the pharyngeal swallow in 3 patients, and incomplete laryngeal closure in 5 cases. A decrease of pharyngeal propulsion was observed in 6 patients (including 2 cases of aperistaltic pharynx), and a deficit of laryngeal elevation in 1 patient. Food stasis in the hypopharynx and/or in the epilarynx was noted in 6 patients. Nasopharyngeal regurgitation was found in 2 cases. Aspiration was observed in 5 patients.

Simultaneous manometry and fluoroscopy (Tables 3 and 4) showed a decrease of pharyngeal propulsion in 4 patients and aperistalsis in 2 patients. Stasis in the hypopharynx and/or in the epilarynx was seen in 6 patients, and in 1, a small diverticulum was observed. Minor nasal reflux was observed in 1 patient. Aspiration was noted in 2 patients. Synchronization between pharyngeal waves and UES relaxation was observed in 3 patients, whereas incoordination was recorded in the others. The UES basal pressure was normal in 6 patients and diminished in 1 other (case 7). Completeness of UES relaxation was preserved in 5 patients at manometry, but in 3 of them, UES opening was altered at fluoroscopy (reduced or delayed relaxation, or early closure).

Two patients had weight loss (3 kg in case 5, and 6 kg in case 7). Aspiration pneumonia occurred in 1 patient (case 7), and 1 patient had fever episodes after attempts at oral feeding (case 6). Two patients were able to eat a normal oral diet, 1 patient had a gastrostomy, and 4 patients required a blended or selective regimen.

DISCUSSION

The neural control of swallowing is complex, involving peripheral afferent inputs, the brain stem network, inputs from higher cortical and subcortical centers, and activation of muscles innervated by cranial nerves V, VII, IX, X, XI, and XII. In this study we specifically studied the effects of impairment of the lower cranial nerves on swallowing, without cortical or brain stem network lesions.

Complete excision of larger tumors of the skull base increases the risk of paralysis of multiple basal cranial nerves with resultant dysphagia and aspiration.[3,4,13] Cranial nerve damage may be the result of nerve sectioning, nerve traction, or hemostasis, or may be inherent to the disease.[5] Cranial nerve damage may also occur after radiotherapy, although the long-term outcome remains to be studied.[13]

The clinical and functional results of swallowing were different from one patient to another because of various causes of paralysis, ages, and times between nerve dysfunction (partial or complete nerve paralysis) and evaluation. All the patients had at least a unilateral paralysis of cranial nerve X. To evaluate the mechanisms of swallowing disorders, different examinations were used.

The VESS provides good evaluation of dysphagic patients, although interpretation of descriptive findings is highly subjective. However, VESS cannot assess UES function or coordination of swallowing, which are studied by videofluoroscopy and manometry.[11] In particular, evaluation of UES function is useful when hypopharyngeal residue or aspiration after swallowing is observed at VESS, since these manifestations are not related to a specific deficit. (They may be related to a UES dysfunction or decreased pharyngeal propulsion.) Simultaneous manometry and videofluoroscopy has the advantage of measuring different parameters of swallowing at the same time (pharyngeal propulsion and clearance forces, completeness of UES relaxation, and duration of UES opening).

Although the number of patients is small, this study shows that the main mechanism of swallowing disorders observed during functional examinations was a disturbance of the pharyngeal stage, including a decrease of pharyngeal propulsion, reduced laryngeal closure, and cricopharyngeal dysfunction. Disruption in the triggering of the pharyngeal swallow was less frequent. (Three patients had a delay of pharyngeal initiation.)

The main feature observed was a decrease of pharyngeal propulsion, including aperistalsis in 2 cases. In these 2 patients, a delay of swallow initiation was also observed, which could increase the severity of the disorders. We found a very good correlation between the results of VESS and those of simultaneous manometry-fluoroscopy in evaluating pharyngeal propulsion. In 2 patients in whom pharyngeal propulsion was highly disturbed or absent at the time of VESS, aperistalsis was found at simultaneous manometry-fluoroscopy. The consequence of such disturbed propulsion could be the impaired coordination observed between pharyngeal propulsion and UES relaxation.

Laryngeal paralysis with inability to approximate the vocal folds disturbs voice production and airway protection.[14] Since aspiration was observed either with or without the ability of the larynx to close the upper airway, swallowing disorders in cases of paralysis of cranial nerve X could be due to impairment of the denervated arytenoid, as well as impairment of the pharynx.[15] In contrast, the sensory laryngeal function was preserved in most of the patients, partly because the deficit was unilateral.[16] However, the method of sensory testing used was not quantitative.

The responsibility of the UES in swallowing disorders was more difficult to analyze. Discrepancies between manometry and fluoroscopy may be due to their examining different aspects of UES function.[17] Unlike manometry, videofluoroscopy analyzes UES opening. Dysfunction of UES opening may result either from decreased distending forces transmitted by the bolus (such as decreased pharyngeal propulsion), from incoordination between pharyngeal propulsion and UES relaxation, or from higher resistance to flow across the sphincter.[18-20] In cranial nerve X paralysis, primary dysfunction of the UES may be due to impaired passive compliance, since UES innervation is provided by the pharyngeal plexus and by the recurrent laryngeal nerve, which are impaired in cases of lower cranial nerve paralysis.[21]

Aspiration was one of the major severe consequences of the swallowing deficits. In this study, more aspiration was observed during VESS than during videofluoroscopy. The investigators of manometry and fluoroscopy explained these inconsistencies by the fact that they stopped ingestion of barium as soon as aspiration was observed and sometimes suspected, in order to decrease risks of severe penetration-aspiration. In addition, examinations were not carried out at the same time, and patients do not necessarily aspirate during each swallow.[22]

In this study, decreased pharyngeal propulsion, incomplete laryngeal closure, and UES impairment were the major deficits that kept patients from eating a normal diet. Decreased pharyngeal propulsion, especially an aperistaltic pharynx, seems to be the major deficit in cases 2, 6, and 7. In addition, the decreased laryngeal closure increased their swallowing disorders. One of them required a gastrostomy. Cricopharyngeal myotomy was not sufficient to relieve dysphagia in the patient who had pharyngeal aperistalsis (case 7). Aspiration after swallowing provoked by pooling of pharyngeal residues due to disturbed UES function and decreased pharyngeal propulsion obliged patient 5 to have a selective diet. The responsibility of a specific deficit in the swallowing disorder could not be determined in case 3, since many deficits were associated. Two patients (cases 1 and 4) were able to eat a normal diet. In case 1, normal UES function, absence of aspiration, and possibly her young age were favorable to a near-normal diet 2 months after surgery, in spite of multiple cranial nerve deficits. In case 4, compensatory postural techniques were effective in eliminating aspiration due to reduced laryngeal closure.

Cricopharyngeal myotomy may improve impairment of the swallowing process localized to the pharyngolaryngoesophageal stage.[23] The aim of myotomy is to open the UES, and success is correlated with adequate residual propulsion.[24] Cricopharyngeal myotomy may be proposed in patients with persisting disabling symptoms, but aperistalsis is a contraindication (cases 6 and 7). Myotomy could have helped patient 5 (decreased pharyngeal propulsion without aperistalsis, UES dysfunction), but he was able to eat a normal diet a few months later, as were patients 1 and 4. In patient 2, the impairment of initiation and the moderate UES dysfunction were not favorable to a myotomy, although residual pharyngeal propulsion was found during examinations. The procedure was suggested for patient 3 (residual pharyngeal propulsion, decreased UES relaxation), but the patient refused the surgery.

The use of several functional examinations (VESS, fluoroscopy, and manometry) of swallowing may be helpful in assessing deficits of swallowing caused by paralysis of the lower cranial nerves, since each

procedure may provide additional information about the swallowing function. Dysfunctions of pharyngeal propulsion, laryngeal closure, and/or UES function have to be investigated in such patients to select the appropriate management. The responsibility of these disturbed mechanisms needs to be assessed in a larger series. It is hoped that further advances in functional assessment of swallowing will allow for better identification of deficits and will be a useful guide for treatment.

REFERENCES

1. Kahrilas PJ. Pharyngeal structure and function. Dysphagia 1993;8:303-7.

2. Baredes S, Blitzer A, Krespi YP, Logemann JA. Swallowing disorders and aspiration. In: Blitzer A, Sasaki CT, Fahn S, Brin A, Harris KS, eds. Neurological disorders of the larynx. New York, NY: Thieme Publishers, 1992:201-13.

3. Leonetti JP, Smith PG, Grubb RL. Management of neurovascular complications in extended skull base surgery. Laryngoscope 1989;99:492-6.

4. Lawson W, Cece JA, Biller HF. Complications in the management of large glomus jugulare tumors. Laryngoscope 1987;97:152-7.

5. Mazzoni A, Sanna M, Saleh E, Achilli V. Lower cranial nerve schwannomas involving the jugular foramen. Ann Otol Rhinol Laryngol 1997;106:370-9.

6. Castell JA, Castell DO. Modern solid state computerized manometry of the pharyngoesophageal segment. Dysphagia 1993;8:270-5.

7. Kahrilas PJ, Dent K, Dodds WJ, Hogan WJ, Arndorfer AC. A method for continuous monitoring of upper esophageal sphincter pressure. Am J Dig Dis 1987;32:121-8.

8. Langmore SE, Schatz K, Olsen N. Fiberoptic endoscopic examination of swallowing safety: a new procedure. Dysphagia 1988;2:216-9.

9. Cook IJ, Dodds WJ, Dantas RO, et al. Timing of videofluoroscopic, manometric events and bolus transit during the oral and the pharyngeal phases of swallowing. Dysphagia 1989; 4:8-15.

10. Bastian RW. Videoendoscopic evaluation of patients with dysphagia: an adjunct to the modified barium swallow. Otolaryngol Head Neck Surg 1991;104:339-50.

11. Bastian RW. The videoendoscopic swallowing study: an alternative and partner to the videofluoroscopic swallowing study. Dysphagia 1993;8:359-67.

12. Logemann JA. Manual for the videofluorographic study of swallowing. Boston, Mass: College-Hill Press, 1986.

13. Poe DS, Jackson CG, Glasscock ME, Johnson GD. Long-term results after lateral cranial base surgery. Laryngoscope 1991;101:372-8.

14. Hoffman HT, McCulloch TM. Anatomic correlations in the surgical treatment of unilateral laryngeal paralysis. Head Neck 1996;18:174-87.

15. Wilson JA, Pryde A, White A, Maher L, Maran AGD. Swallowing performances in patients with vocal fold motion impairment. Dysphagia 1995;10:149-54.

16. Aviv JE, Sacco RL, Thomson J, et al. Silent laryngopharyngeal sensory deficits after stroke. Ann Otol Rhinol Laryngol 1997;106:87-93.

17. Mendelsohn MS, McConnel FMS. Function in the pharyngoesophageal segment. Laryngoscope 1987;97:483-9.

18. Dantas RO, Cook IJ, Dodds WJ, Kern MK, Lang IM, Brasseur GJ. Biomechanics of cricopharyngeal bars. Gastroenterology 1990;99:1269-74.

19. Brasseur J, Dodds W. Interpretation of intraluminal manometric measurements in terms of swallowing mechanics. Dysphagia 1991;6:100-19.

20. Cook IJ. Cricopharyngeal function and dysfunction. Dysphagia 1993;8:244-51.

21. Mu L, Sanders I. The innervation of the human upper esophageal sphincter. Dysphagia 1996;11:234-8.

22. Kaye GM, Zorowitz RD, Baredes S. Role of flexible laryngoscopy in evaluating aspiration. Ann Otol Rhinol Laryngol 1997;106:705-9.

23. McKenna JA, Dedo HH. Cricopharyngeal myotomy: indications and technique. Ann Otol Rhinol Laryngol 1992;101: 216-21.

24. Lacau St Guily J, Moine A, Périé S, Bokowy C, Angelard B, Chaussade S. Role of pharyngeal propulsion as an indicator for upper esophageal sphincter myotomy. Laryngoscope 1995; 105:723-7.

Ann Otol Rhinol Laryngol 108:1999

LARYNGEAL LONG LATENCY RESPONSE CONDITIONING IN ABDUCTOR SPASMODIC DYSPHONIA

FREDERIC W.-B. DELEYIANNIS, MD, MPH
SEATTLE, WASHINGTON

MICHAEL GILLESPIE
PHILADELPHIA, PENNSYLVANIA

TOSHIYUKI YAMASHITA, MD, SCD
TOKUSHIMA, JAPAN

STEVEN BIELAMOWICZ, MD
WASHINGTON, DC

CHRISTY L. LUDLOW, PHD
BETHESDA, MARYLAND

Previously, we demonstrated that patients with adductor spasmodic dysphonia (ADSD) have a disinhibition of laryngeal responses to sensory input. In this study, sensorimotor responses to stimulation of the superior laryngeal nerve were compared between 10 subjects with abductor spasmodic dysphonia (ABSD) and 15 normal volunteers. The groups had similar latency and frequency characteristics of their unconditioned adductor responses ($p > .05$). The conditioned R1 (early) responses of the subjects with ABSD were greater and more variable in amplitude than those of the normal volunteers ($p \leq .008$). Similar R2 (late) conditioning effects were found in both groups, with a nonsignificant trend toward reduced inhibition of contralateral R2 responses at lower interstimulus intervals ($p = .01$) in the patient group. Thus, inhibitory mechanisms that modulate the R1 laryngeal sensorimotor pathway in the brain stem may be abnormal in subjects with ABSD. Abnormal modulation of laryngeal sensorimotor responses seems present in both types of spasmodic dysphonia.

KEY WORDS — abductor spasmodic dysphonia, electromyography, laryngeal long latency response.

INTRODUCTION

Spasmodic dysphonia is an idiopathic voice disorder characterized by an impaired ability to control volitional and highly skilled movements of the vocal folds.[1] Two types of this disorder are known. The most common type is adductor spasmodic dysphonia (ADSD), in which hyperadduction of the vocal folds produces phonatory breaks during vowels.[2] These movements are associated with spasmodic bursts of the thyroarytenoid (TA) muscles.[3] A less common type is abductor spasmodic dysphonia (ABSD), which is characterized by breathy breaks due to prolonged voiceless consonants. These patients are slow to close the vocal folds for vowels following voiceless consonants. It is not known whether ABSD is caused by a lack of adductor muscle activation for vocal fold closure, or by hyperactivity in the abductor muscles opposing closing.[4] A variety of abnormalities in laryngeal muscle activity have been reported clinically, including cricothyroid (CT) and posterior cricoarytenoid (PCA) muscle bursts and/or altered TA muscle activity.[5,6]

Blink reflex response conditioning can be used to examine the effects of inhibitory interneurons on reflex responses.[7,8] The first afferent stimulus elicits the initial motor response while simultaneously exciting inhibitory interneurons, which then modify responses to subsequent stimuli.[7] By reducing the duration between the initial, "unconditioned" stimulus and the second, "conditioned" stimulus, the duration of the effect of the inhibitory interneurons can be quantified.[8] Several studies have found that blink reflex conditioning is abnormal in persons with focal dystonias such as oral mandibular dystonia, torticollis, and spasmodic dysphonia.[9,10] In addition, spinal reflex conditioning abnormalities have been found in focal dystonias, suggesting that other inhibitory mechanisms are altered in such patients.[11]

We have characterized and studied 2 laryngeal long latency reflex responses to sensory stimulation in humans.[12] An early response with a latency of 17 milliseconds (ms) occurs in the ipsilateral TA muscle (referred to as R1), while later responses between 60 and 75 ms (referred to as R2) occur in the ipsilateral and contralateral TA muscles. Because laryngeal reflex conditioning had been demonstrated in the cat,[13,14] we studied laryngeal reflex conditioning in a group of subjects with ADSD and compared them with normal volunteers.[15] The patients' unconditioned R1 and R2 responses were normal in latency

From the Voice and Speech Section, Division of Intramural Research, National Institute on Deafness and Other Communication Disorders, Bethesda, Maryland. Dr Deleyiannis is currently in the Department of Otolaryngology–Head and Neck Surgery, University of Washington, Seattle, Washington. This work was supported by the Division of Intramural Research, National Institutes of Health/National Institute on Deafness and Other Communication Disorders.

CORRESPONDENCE — Christy L. Ludlow, PhD, Voice and Speech Section, National Institute on Deafness and Other Communication Disorders, Building 10, Room 5D38, 10 Center Dr MSC 1416, Bethesda, MD 20892-1416.

and frequency characteristics, indicating that the peripheral nerves and brain stem pathways for these responses were intact.[15] In the same study, pairs of electrical pulses were presented at interstimulus intervals (ISIs) varying from 100 to 5,000 ms. The subjects with ADSD had reduced response inhibition; their conditioned ipsilateral R1 response amplitudes and the frequency of their conditioned contralateral R2 responses were increased compared to normal. These findings suggest a central disinhibition of laryngeal responses to sensory input in ADSD.

Whether ABSD is a disorder similar to ADSD is controversial.[16] The pathophysiology seems to vary a great deal more across individuals with ABSD than in individuals with ADSD.[5,6] Botulinum toxin injection into the TA muscles has been found effective in almost all patients with ADSD and is the treatment of choice for that disorder.[17-22] This treatment is much less effective, however, in patients with ABSD,[23] and a variety of muscles have been injected with much more variable results.[5,24]

Patients with ADSD have spasmodic activity in the TA muscle, and this is the muscle involved in the laryngeal adductor response. Patients with ABSD do not consistently have TA muscle bursts; rather, clinical reports have suggested that either the CT or the PCA muscle may have spasmodic activity.[5] In some cases, the abnormality may not be excessive spasmodic activity, but rather, a reduction in adductor TA activity coincident with the voiceless break. The purpose of this investigation was to examine subjects with ABSD to determine whether they have adductor laryngeal response conditioning abnormalities similar to those previously found in patients with ADSD. Because of their different clinical characteristics, patients with ABSD could be expected to have adductor laryngeal response characteristics different from those in patients with ADSD.

METHODS

Subjects. Ten subjects with ABSD and 15 normal volunteers were selected for study following informed consent. The data from 11 of the 15 normal volunteers were from our previous study comparing subjects with ADSD and normal volunteers on laryngeal adductor response conditioning.[15]

To select persons with ABSD alone, and to ensure that none of the subjects exhibited signs of a "mixed" spasmodic dysphonia with both ADSD and ABSD, the following criteria were used. First, subjects were examined with fiberoptic nasolaryngoscopy. They received the diagnosis of ABSD if they exhibited prolonged vocal fold opening during voiceless consonants such as /s/, /h/, /f/, /p/, /t/, /k/, and "th," and difficulty initiating vocal fold closure for vowels following these voiceless consonants. None had signs or symptoms of ADSD; that is, they were without vocal fold hyperadductions during vowels in sentences or during prolonged glottal stops in sentences such as "We eat eels every day."

Second, subjects were examined with a prerecorded set of instructions to sample speech items known to elicit speech symptoms typical of ABSD: the repetition of sentences with voiceless consonants, such as "The puppy bit the tape" and "When he comes home we'll feed him." In addition, subjects repeated sentences with glottal stops and continuous voicing, such as "We mow our lawn all year," known to elicit symptoms of ADSD. Patients with ABSD had frequent prolongation of voiceless consonants (/p/, /t/, /h/, /k/, /f/) in the first 2 sentences above, and no difficulty or symptoms on sentences with glottal stops and continuous voicing, such as the third sentence above.

Diagnostic agreement was required from an otolaryngologist and a speech pathologist with extensive experience in spasmodic dysphonia that the person's symptoms were commensurate with ABSD and not with those of any other voice disorder. The subjects were without other neurologic, psychiatric, movement, or speech disorders, and none had previously been treated with botulinum toxin injection. The normal volunteers were examined by an otolaryngologist and found to have normal laryngeal structure and function, and were without any current or past history of speech, voice, neurologic, or psychiatric disorders. There were 7 men in the normal volunteer group and 2 men in the patient group. The mean age of the normal volunteers was 33.1 years (range 22 to 53 years of age); the mean age of the subjects with ABSD was 35.9 years (range 32 to 40 years of age).

Procedures. Informed consent for agreement to participate in this study was obtained following the procedures approved by a National Institutes of Health Internal Review Committee. Subjects were placed in a supine position with the neck extended. After a ground electrode was attached, bipolar electromyography (EMG) needle electrodes were used to locate the laryngeal muscles by means of standard techniques.[25,26] Bipolar hooked wires placed within 27-gauge 37.5-mm needles were inserted into the TA muscles. Verification gestures for the right and left TA muscles consisted of increased activation during phonation and effort closure of the glottis without prominent onset and offset bursts indicative of lateral cricoarytenoid muscle placement. Once the correct location was achieved, the needles were

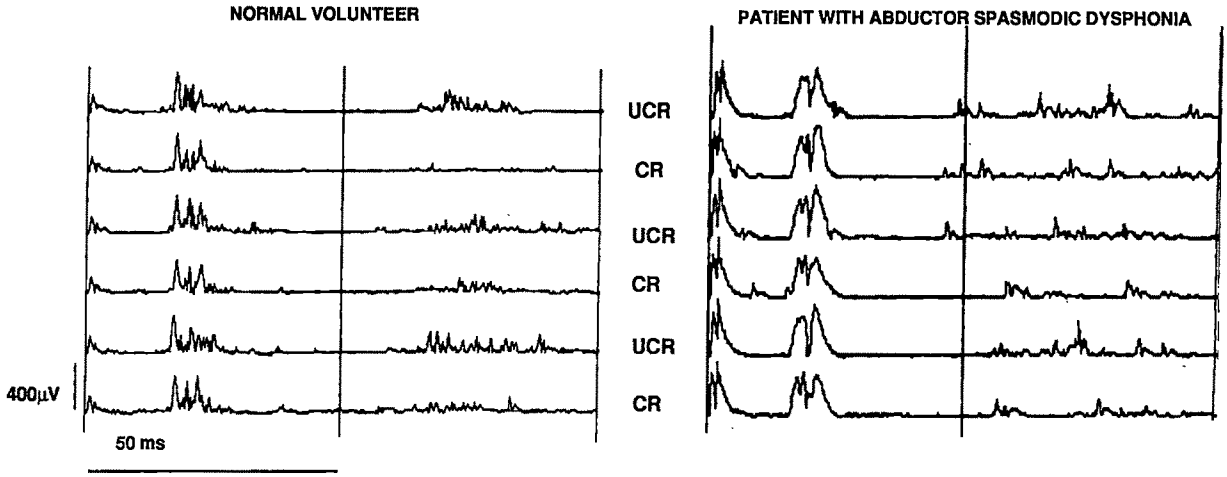

Fig 1. Examples of R1 and R2 laryngeal responses seen in ipsilateral thyroarytenoid muscles both in response to initial stimulation of superior laryngeal nerve (unconditioned response; UCR) and following second conditioned stimulus 500 ms later (conditioned response; CR). Three sets of sequential pairs of UCR and CR responses are shown for both normal volunteer and patient with abductor spasmodic dysphonia.

removed and the hooked wires remained in place during the study. Peak-to-peak 2-V sawtooth calibration signals were recorded for each EMG channel. The 2 EMG channels were bandpass-filtered between 100 and 5,000 Hz and recorded along with the stimulus trigger on a TEAC multiple-channel VHS FM recorder at 15 in/s.

After electrode placement, the room lighting was dimmed and the noise was minimized for 5 minutes to allow the subject to relax prior to recording muscle activity during quiet respiration. For stimulation of the right internal superior laryngeal nerve (SLN), 2 pairs of hooked wire electrodes were inserted on either side of the SLN proximal to its penetration through the thyrohyoid membrane.[12] The rostral, anode electrode and the caudal, cathode electrode were usually 0.5 to 1.5 cm apart and 1.0 to 3.5 cm in depth, depending on the subject's neck dimensions. A third hooked wire electrode was placed close to the midline of the superior border of the thyroid cartilage, between the stimulation and the EMG recording electrodes, to reduce stimulus artifact. A DISA 15EO7 current stimulator was used to deliver 1-ms rectangular current pulses covering a range of stimulation amplitudes from 0 to 6 mA. Starting at 0 mA, the current level was increased until the R1 response in the ipsilateral TA muscle no longer increased, that is, had reached supramaximal response levels. In some instances, the highest level that could be tolerated by the subject was selected if it was not certain that the supramaximal level was reached. The stimulus range was between 3 and 6 mA. Once the R1 response was elicited, 6 sets of stimulus pairs were presented at each of the following ISIs: 5 seconds, 2 seconds, 1 second, 500 ms, and 250 ms. In some preliminary, as yet unpublished work, we have found that TA muscle responses to stimulation of the internal branch of the SLN can vary, with responses being enhanced during inspiration over expiration. To control for these possible effects of the respiratory cycle on response amplitude, 3 of each set were initiated during inspiration, and 3 during expiration, at each ISI in all subjects.

Signal Analyses. The trigger, muscle, and calibration signals were digitized off-line at 5,000 samples per second with anti-aliasing low-pass filtering at 2,000 Hz. Linear interpolation from the calibration signals was used to convert the signals into volts. To correct for DC offset, nonrectified data were averaged for each EMG channel over 20 seconds of quiet respiration, and the averages were subtracted from the EMG signal for that channel. Next, the signals were rectified, and the minimum activation levels during quiet respiration were measured between motor unit firings for each EMG channel. This value was then subtracted from the respective signal to extract impedance noise.

Visual inspection identified muscle responses in the ipsilateral and contralateral TA EMG signals within 200 ms after each trigger (Fig 1). Response onset was identified at the initial deflection of the EMG response after the stimulus artifact had returned to baseline. Response offset was marked when the EMG signal returned to baseline and remained there for several milliseconds. To measure the mean amount of muscle activity in the absence of stimulation (baseline mean), the mean activity in microvolts was computed from a 20-ms window immediately prior to each stimulation trigger in each TA muscle.

Automated signal-processing algorithms were employed to perform the following measures with the

TABLE 1. MEAN LATENCIES FOR UNCONDITIONED R1 AND R2 RESPONSES IN NORMAL VOLUNTEERS AND ABDUCTOR SPASMODIC DYSPHONIA PATIENTS

		ABSD		*Normal Volunteers*		
Response	*Side*	*Mean*	*SD*	*Mean*	*SD*	*p**
R1	Ipsilateral	15.6	1.1	16.1	2.9	.65
R2	Ipsilateral	61.8	9.0	62.0	7.7	.96
R2	Contralateral	66.8	6.1	69.4	10.5	.57

Data are in milliseconds.
*Significance level given by *t*-tests.

TABLE 2. MEAN FREQUENCIES FOR UNCONDITIONED R1 AND R2 RESPONSES IN NORMAL VOLUNTEERS AND ABDUCTOR SPASMODIC DYSPHONIA PATIENTS

Response	*Side*	*ABSD*	*Normal Volunteers*	*p**
R1	Ipsilateral	88.3%	98.9%	.21
R2	Ipsilateral	90.0%	76.7%	.39
R2	Contralateral	74.1%	46.7%	.17

Percents are of subjects with unconditioned response to first stimulus.
*Significance level given by *t*-tests.

onsets and offsets labeled for each R1 and R2 response: 1) response latency, 2) response duration, and 3) sum of the muscle response (in microvolts). For subtracting the baseline activity levels in the muscle prior to stimulation from the sum of the muscle response, the following formula was used: response residual = [the sum (μV) contained in a response] – [baseline mean (μV) × response duration (s) × sampling rate (5,000)]. When the resulting response residual was negative or zero, the response was not included in the data, and a "no response" was recorded.

Both response residuals and the frequency of responses were computed to examine the effects of response conditioning. To measure conditioned response residuals, the residual of the second conditioned response was divided by the residual of the first unconditioned response and multiplied by 100. This measure was referred to as the percent of the unconditioned response. The means of the percents of the unconditioned responses were computed for each set of 6 pairs of responses for each subject at ISIs of 100, 250, 500, 750, 1,000, 2,000, and 5,000 ms. To measure conditioned response frequency, the percents of the 6 trials containing responses to the second stimulus were computed for each ISI for each subject. Thus, 6 measures of response conditioning were derived at each ISI for each subject: the mean of the percents of the 6 unconditioned responses for the conditioned R1, the ipsilateral R2, and the contralateral R2; and the percent occurrence of conditioned R1, ipsilateral R2, and contralateral R2 responses.

Statistical Analysis. For the initial unconditioned responses to the first stimulus, independent *t*-tests were used to compare group means of latencies for R1 responses and for ipsilateral and contralateral R2 responses between normal volunteers and patients with ABSD. The percents of the 6 trials containing responses to the first stimulus at each ISI were computed for each subject. The mean group frequencies were then compared for the unconditioned R1 and R2 responses with *t*-tests.

Multifactorial analyses of variance (ANOVAs) were computed to compare the 2 groups — the group with ABSD and the normal volunteers — on the measures of conditioned response amplitude and frequency. The factors included group effects, ISI effects for the 2 groups combined, subject effects nested within group, and group-by-ISI interaction effects to determine whether the 2 groups responded differently across ISIs. The 6 measures of response conditioning (the percent of the unconditioned response amplitude and conditioned response frequency for the ipsilateral R1 and ipsilateral and contralateral R2 responses) were tested with the same multifactorial ANOVA design. A Bonferroni correction was used to adjust for 6 comparisons, and a 2-tailed p value of .008 (.05/6 = .008) was used for statistical significance.

RESULTS

For the initial unconditioned responses, the mean latencies (Table 1) and frequencies (Table 2) of the ipsilateral R1, ipsilateral R2, and contralateral R2 responses were compared between the normal volunteers and subjects with ABSD. No significant differences were found ($p > .05$). For the conditioned responses, the group mean response amplitudes (the mean percents of the unconditioned response) for the R1 and R2 responses are shown in Fig 2. Similarly, the mean group percent occurrence of conditioned responses for the ipsilateral R1 and the ipsilateral and contralateral R2 are shown in Fig 3. Results of the multifactorial ANOVAs examining group effects (subjects with ABSD versus normal volunteers), subject effects within groups, ISI effects, and group-by-ISI interactions are provided in Table 3. We could not test subject within-group effects for the measure of response amplitude, because there were too few cases per cell in the multifactorial design. A significance criterion of $p \leq .008$ was used after a Bonferroni correction for multiple comparisons (.05/6 = .008).

Significant group effects were found for the ipsilateral conditioned R1 response amplitude. Figure 2 indicates that the subjects with ABSD had higher

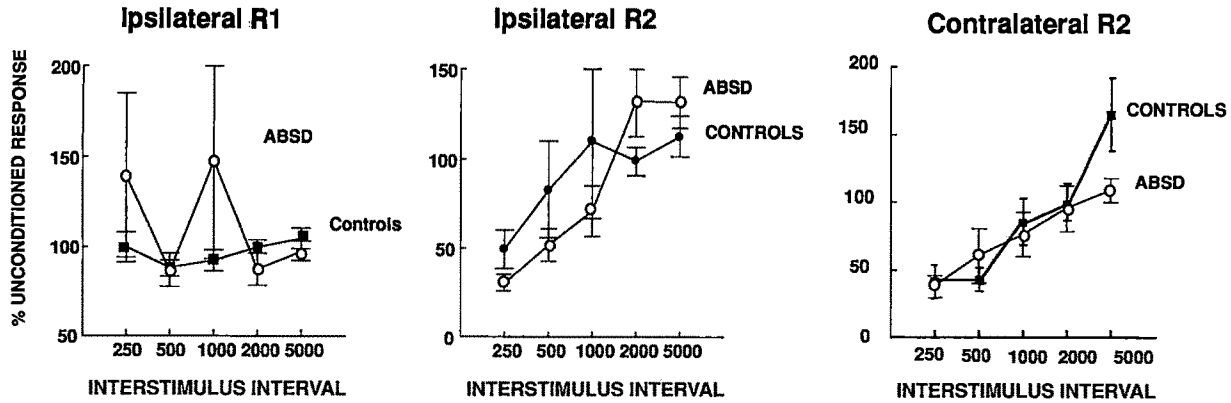

Fig 2. Plots of group means and standard errors of conditioned responses (measured as percent of amplitude of unconditioned preceding response) for patient group with abductor spasmodic dysphonia (ABSD) and normal volunteer group (controls) for ipsilateral R1, ipsilateral R2, and contralateral R2 thyroarytenoid muscle responses.

means and larger standard errors at 250 and 1,000 ISIs. Post hoc Mann-Whitney U tests comparing the group means at these 2 ISI levels were not significant ($p > .05$), most likely because of large within-group variance and the lower power of the nonparametric analyses.[27] No significant group or group-by-ISI interactions were found for conditioned ipsilateral and contralateral R2 response amplitudes (Table 3 and Fig 2).

For the ipsilateral R1 conditioned response frequency, significant group differences and significant subject effects within groups were found, but no significant group-by-ISI interactions. Overall, the subjects with ABSD had fewer ipsilateral R1 conditioned responses (Table 3 and Fig 3). For both the ipsilateral and contralateral conditioned R2 frequencies, significant subject effects and ISI effects were found, but no significant group effects or group-by-ISI interactions. The frequency of conditioned contralateral R2 responses tended to be greater in the subjects with ABSD relative to the normal volunteers (Fig 3). In fact, a nonsignificant group-by-ISI interaction F value of 6.742 with a probability of .01 indicated a trend for the subjects with ABSD to have less inhibition of contralateral R2 responses than the normal volunteers. This suggests that although the 2 groups had similar conditioning effects, the patients had a tendency for reduced inhibition of their contralateral R2 responses in comparison with normal.

Because of the significant subject effects, the individual subject data are plotted with the percent of the unconditioned response amplitude for the normal volunteers and the persons with ABSD in the top half of Fig 4, and the percent occurrence of R2 conditioned responses within each of the 2 groups is plotted in the bottom half of Fig 4. As can be seen, there are large individual subject differences, particularly in the ABSD group. These differences among subjects were most marked in the ABSD group on the measure of the percent of the unconditioned response amplitude for the conditioned response in the top right half of Fig 4. Three of the 10 subjects with ABSD had values that were outside the normal range. On the measure of the percent occurrence of R2 conditioned responses, in the lower half of Fig 4, at ISIs of 500 or less, 4 of the 10 patients with ABSD had

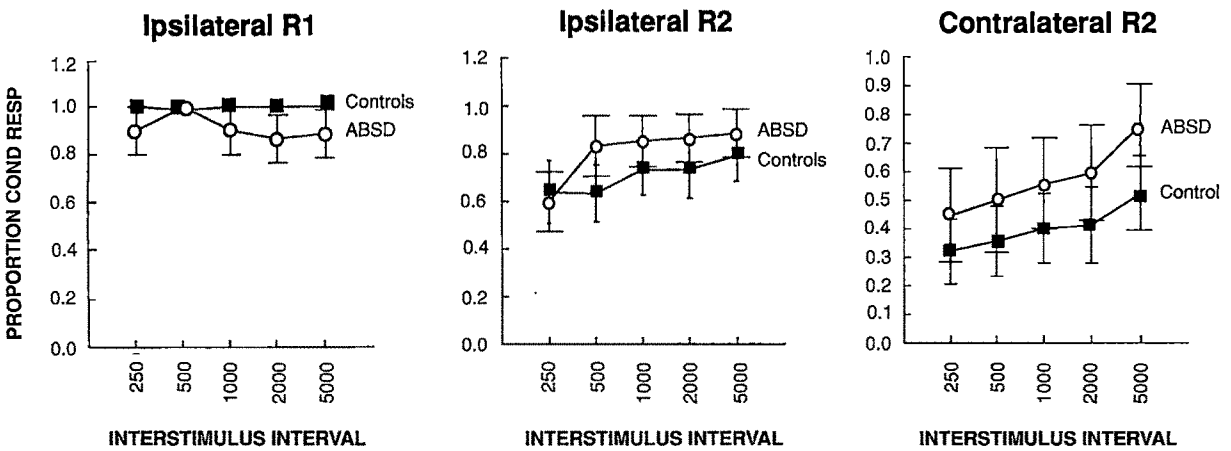

Fig 3. Plots of group means and standard errors of percent occurrences of conditioned responses for patient group (ABSD) and normal volunteer group (controls) for ipsilateral R1 and ipsilateral and contralateral R2 responses.

TABLE 3. RESULTS OF MULTIFACTORIAL ANALYSES OF VARIANCE FOR MEASURES OF RESPONSE CONDITIONING BETWEEN ABDUCTOR SPASMODIC DYSPHONIA PATIENTS AND NORMAL VOLUNTEER GROUPS AT VARIOUS INTERSTIMULUS INTERVALS

Response	*Side*	*Measure*	*Group F*	*Subjects Within-Group F*	*ISI F*	*Group-by-ISI F*
R1	Ipsilateral	% UCR	7.460*	†	0.728	2.22
R2	Ipsilateral	% UCR	0.814	†	7.73	0.59
R2	Contralateral	% UCR	0.078	†	1.801	0.02
R1	Ipsilateral	% CR	25.25*	29.97*	0.001	0.414
R2	Ipsilateral	% CR	0.219	9.433*	20.378*	1.475
R2	Contralateral	% CR	0.378	17.169*	27.067*	6.742

ISI — interstimulus interval, % UCR — mean percent of unconditioned response amplitude; % CR — mean percent of conditioned responses.
*p ≤ .008, corrected significance level for multiple comparisons (.05/6 = .008).
†Could not test subject within-group effect because of too few cases per cell in multifactorial design.

100% occurrence of conditioned R2 contralateral responses, while only 2 of the 15 normal volunteers had 100% occurrence of conditioned contralateral R2 responses.

DISCUSSION

This study demonstrated that the unconditioned adductor responses of the individuals with ABSD did not differ from those of normal volunteers. Because the latencies and frequencies of the unconditioned R1 and R2 responses were similar in the 2 groups, there was no evidence of pathophysiology involving the peripheral nerve or brain stem pathways. However, there was evidence that the modulation of R1 responses by inhibitory mechanisms differed from normal in persons with ABSD. The mechanisms that modulate the inhibitory interneurons in the R1 pathway seemed to be affected in subjects with ABSD. Although no significant group difference or group-by-ISI interactions were found in the conditioned R2 responses in this study, the patients tended to have less inhibition of their conditioned R2 responses. Thus, the inhibitory mechanisms that modulate the R2 responses were not as noticeably altered in subjects with ABSD as they were in subjects with ADSD. The R1 pathway has been well studied in animals and is thought to involve the nodose ganglion, nucleus tractus solitarius, reticular formation, and nucleus ambiguus.[28] Little is known about the R2 pathway, except that it is also polysynaptic and might have a transcortical component.[29]

In contrast to the findings here in subjects with ABSD, in our previous study of subjects with ADSD, there was evidence of adductor response disinhibi-

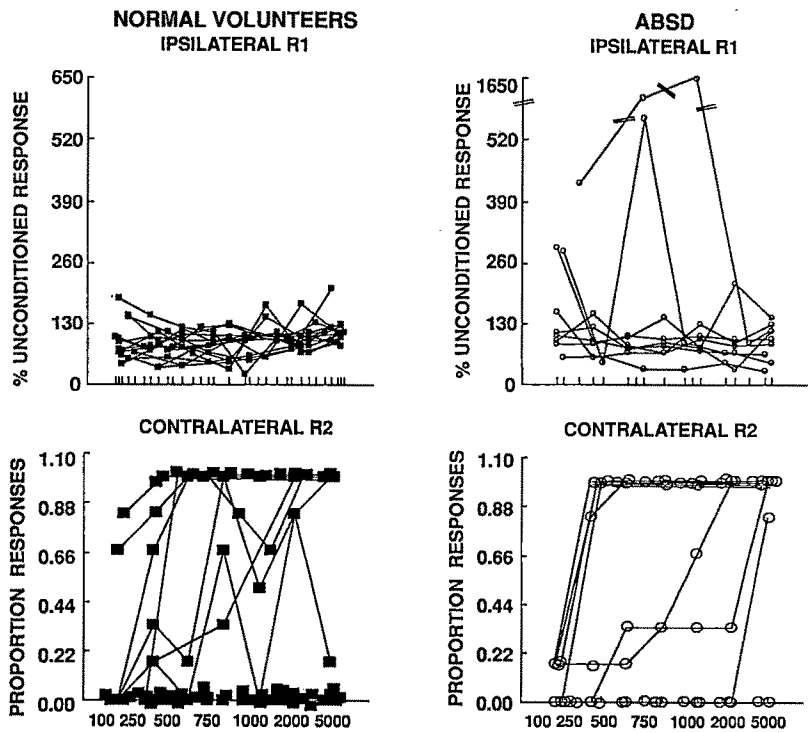

Fig 4. Top half of Figure shows individual subject data plotted for percent of unconditioned response amplitude for normal volunteers and persons with ABSD. Bottom half of Figure shows plotting of percent occurrence of R2 conditioned responses in individual subjects for each of 2 groups.

tion during conditioning for both the ipsilateral R1 and the contralateral R2 responses.[15] This difference suggests that persons with ABSD or with ADSD both have altered modulation of inhibitory mechanisms, but that the particular mechanisms affected may differ in the 2 types of spasmodic dysphonia. The R1 conditioned responses were significantly different from those of normal volunteers in both patient groups. In fact, the graphs in Figs 2 and 3 for the conditioned ipsilateral R1 response are very similar to the same types of graphs in our report on ADSD.[15] Thus, the R1 conditioning abnormalities are similar in both types of spasmodic dysphonia.

No significant group differences were found between normal volunteers and subjects with ABSD for R2 responses in this study, while in the previous study[15] of ADSD, the patient group had significantly more frequent conditioned R2 responses than the normal volunteers. However, a similar, nonsignificant tendency was found in the comparisons here between patients with ABSD and normal volunteers ($p = .01$). This suggests that the modulation of inhibitory mechanisms affecting R2 responses is affected in subjects with ABSD, but not to the same degree as in subjects with ADSD.[15]

Subjects with ABSD may have reduced abductor, instead of adductor, response inhibition that contributes to a relative hyperactivity of the abductor muscles. During electrical stimulation of the internal SLN, no long latency reflex responses occur in the CT muscles.[12] Because of the technical difficulties in obtaining a reliable EMG recording of the PCA muscle regardless of the technique used,[24,25,30] we have not frequently recorded from the PCA muscle while conducting this experiment. Occasionally, we have observed a single ipsilateral response in the PCA muscle at around 30 ms, which may be associated with vocal fold abduction following the initial R1. However, the physiological significance of this is limited, because the only movement observed during this procedure has been bilateral adduction of both folds, presumably due to the bilateral R2 response.[12] It might be important, however, to evaluate PCA responses further to determine if conditioning effects on this muscle are altered in ABSD. However, the heterogeneity of EMG findings in subjects with ABSD also suggests that other muscles besides the PCA may be involved in some patients with this disorder.[5]

Nevertheless, this study reports that subjects with ABSD had significant conditioning abnormalities, suggesting that inhibitory mechanisms are abnormally modulated in these patients. The differences between these findings in subjects with ABSD and in subjects with ADSD in a previous study[15] indicate that inhibitory mechanisms are altered differently in these 2 types of spasmodic dysphonia. This may explain the different vocal fold movement control abnormalities found in patients with these 2 types of spasmodic dysphonia.

ACKNOWLEDGMENTS — The authors thank Geralyn Schulz, PhD, for assistance with data analysis and Katsuiko Nakamura, MD, and Yasumasa Tanaka, MD, for assistance with subject testing.

REFERENCES

1. Aronson AE. Clinical voice disorders: an interdisciplinary approach. 2nd ed. New York, NY: Thieme-Stratton, 1985.

2. Parnes SM, Lavorato AS, Myers EN. Study of spastic dysphonia using videofiberoptic laryngoscopy. Ann Otol Rhinol Laryngol 1978;87:322-6.

3. Nash EA, Ludlow CL. Laryngeal muscle activity during speech breaks in adductor spasmodic dysphonia. Laryngoscope 1996;106:484-9.

4. Ludlow CL. Pathophysiology of the spasmodic dysphonias. In: Bell-Berti F, Raphael LJ, eds. Producing speech: contemporary issues for Katherine Safford Harris. Woodbury, NY: American Institute of Physics, 1995:291-308.

5. Ludlow CL, Naunton RF, Terada S, Anderson BJ. Successful treatment of selected cases of abductor spasmodic dysphonia using botulinum toxin injection. Otolaryngol Head Neck Surg 1991;104:849-55.

6. Watson BC, Schaefer SD, Freeman FJ, Dembowski J, Kondraske G, Roark R. Laryngeal electromyographic activity in adductor and abductor spasmodic dysphonia. J Speech Hear Res 1991;34:473-82.

7. Kimura J. Electrodiagnosis in diseases of nerve and muscle: principles and practice. Philadelphia, Pa: FA Davis, 1983: 323.

8. Sanes JN, Ison JR. Habituation and sensitization of components of the human eyeblink reflex. Behav Neurosci 1983;97: 833-6.

9. Cohen LG, Ludlow CL, Warden M, et al. Blink reflex curves in patients with spasmodic dysphonia. Neurology 1989; 39:572-7.

10. Tolosa E, Montserrat L, Bayes A. Blink reflex studies in focal dystonias: enhanced excitability of brainstem interneurons in cranial dystonia and spasmodic torticollis. Mov Dis 1988;3:61-9.

11. Panizza M, Lelli S, Nilsson J, Hallett M. H-reflex recovery curve and reciprocal inhibition of H-reflex in different kinds of dystonia. Neurology 1990;40:824-8.

12. Ludlow CL, Van Pelt F, Koda J. Characteristics of late responses to superior laryngeal nerve stimulation in humans. Ann Otol Rhinol Laryngol 1992;101:127-34.

13. Sessle BJ. Presynaptic excitability changes induced in single laryngeal primary afferent fibres. Brain Res 1973;53:333-42.

14. Sessle BJ. Excitatory and inhibitory inputs to single neurones in the solitary tract nucleus and adjacent reticular forma-

tion. Brain Res 1973;53:319-31.

15. Ludlow CL, Schulz GM, Yamashita T, Deleyiannis FW-B. Abnormalities in long latency responses to superior laryngeal nerve stimulation in adductor spasmodic dysphonia. Ann Otol Rhinol Laryngol 1995;104:928-35.

16. Karnell MP. Abductor and adductor spasmodic dysphonia: related until proven otherwise. Am J Speech Lang Pathol 1992;1:17-8.

17. Miller RH, Woodson GE, Jankovic J. Botulinum toxin injection of the vocal fold for spasmodic dysphonia. Arch Otolaryngol Head Neck Surg 1987;113:603-5.

18. Blitzer A, Brin MF. Laryngeal dystonia: a series with botulinum toxin therapy. Ann Otol Rhinol Laryngol 1991;100: 85-9.

19. Ludlow CL, Naunton RF, Sedory SE, Schulz GM, Hallet M. Effects of botulinum toxin injections on speech in adductor spasmodic dysphonia. Neurology 1988;38:1220-5.

20. Ludlow CL. Treatment of speech and voice disorders with botulinum toxin. JAMA 1990;264:2671-5.

21. NIH Consensus Development Conference statement: clinical use of botulinum toxin. Arch Neurol 1991;48:1294-8.

22. Truong DD, Rontal M, Rolnick M, Aronson AE, Mistura K. Double-blind controlled study of botulinum toxin in adductor spasmodic dysphonia. Laryngoscope 1991;101:630-4.

23. Ludlow CL, Bagley JA, Yin SG, Koda J. A comparison of different injection techniques in the treatment of spasmodic dysphonia with botulinum toxin. J Voice 1992;6:380-6.

24. Blitzer A, Brin M, Stewart C, Aviv JE, Fahn S. Abductor laryngeal dystonia: a series treated with botulinum toxin. Laryngoscope 1992;102:163-7.

25. Hirano M, Ohala J. Use of hooked-wire electrodes for electromyography of the intrinsic laryngeal muscles. J Speech Hear Res 1969;12:362-73.

26. Ludlow CL. Neurophysiological assessment of patients with vocal motor control disorders. In: Cooper JA, ed. Assessment of speech and voice production: research and clinical applications. Bethesda, Md: NIDCD Monograph, 1991:161-71.

27. Ferguson GA. Statistical analysis in psychology and education. New York, NY: McGraw-Hill Book Company, 1966:110.

28. Tanaka Y, Ludlow CL, Yoshida Y, Hirano M, Selbie WS. Expression of Fos-like immunoreactivity in the laryngeal reflex pathway of the cat's lower brainstem. In: Fletcher N, Davis P, eds. Controlling complexity and chaos: 9th Vocal Fold Physiology Symposium. San Diego, Calif: Singular Press, 1996:91-106.

29. Mochida A. Reflex control on laryngeal functions: vibration effect of the laryngeal mucosa on recurrent laryngeal nerve reflexes. J Otolaryngol Jpn 1990;93:938-47.

30. Kuna ST, Smickly JS, Insalaco G. Posterior cricoarytenoid muscle activity during wakefulness and sleep in normal adults. J Appl Physiol 1990;68:1746-54.

IMAGING CASE STUDY OF THE MONTH
HIGH JUGULAR BULB ADHERING TO THE EARDRUM

TAKEHISA SAITO, MD
KOUTETSU LEE, MD
HITOSHI SAITO, MD
FUKUI, JAPAN

INTRODUCTION

A high jugular bulb is defined as that showing an abnormally high position in the tympanic cavity, with or without a bony plate. A high jugular bulb can be seen through the eardrum in some instances. When the eardrum is not translucent, however, it is impossible to detect a high jugular bulb by otoscopic examination alone. The most serious problem involving this anomaly is the possibility of causing massive bleeding during middle ear surgery such as tympanotomy, tympanomeatal flap surgery, and tympanoplasty. In this report, a case of high jugular bulb accompanied by chronic otitis media with cholesteatoma is presented. Preoperative computed tomography (CT) revealed the bulb to be adherent to a retracted and thickened eardrum due to chronic inflammation. With the CT finding of a high jugular bulb, massive bleeding during surgery was avoided. The importance of detecting the existence of this disease before middle ear surgery and the importance of preoperative radiologic examination by CT are discussed.

CASE REPORT

A 75-year-old woman complained of left-sided hearing loss and otorrhea. She reported no tinnitus or dizziness. On the first consultation, an attic retraction pocket containing cholesteatoma debris was visible. The pars tensa of the eardrum was retracted and markedly thickened and calcified (Fig 1). A pure tone audiogram showed a mixed hearing loss with a 20- to 50-dB air-bone gap in the low to middle frequencies. Bone conduction on the left was similar to that on the right, showing presbyacusis. The tympanogram was type B. Since the patient refused cholesteatoma surgery, cholesteatoma debris was periodically removed in the clinic. However, debris could not be completely removed, and infection could not be controlled. The patient then agreed to surgery.

Computed tomography performed before surgery showed undeveloped mastoid air cells and a soft tissue density in the attic and antrum. In the tympanic cavity, a high jugular bulb was observed (Fig 2). This bulb extended superiorly to the round window niche and laterally contacted the eardrum (Fig 3). Because

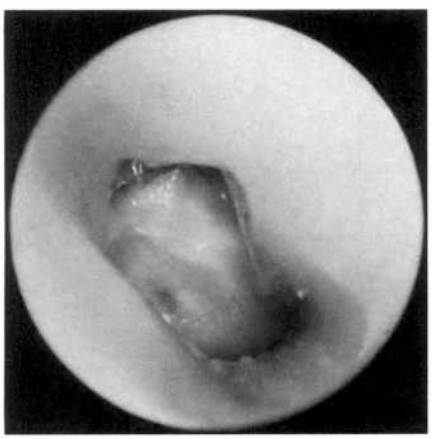

Fig 1. Preoperative findings of eardrum. Attic retraction pocket was observed.

Fig 2. Preoperative axial view of computed tomography scan of left temporal bone. High jugular bulb was in contact with eardrum (arrow).

From the Department of Otolaryngology, Fukui Medical University, Fukui, Japan.
CORRESPONDENCE — Takehisa Saito, MD, Dept of Otolaryngology, Fukui Medical University, Matsuoka-cho, Yoshida-gun, Fukui 910-1193, Japan.

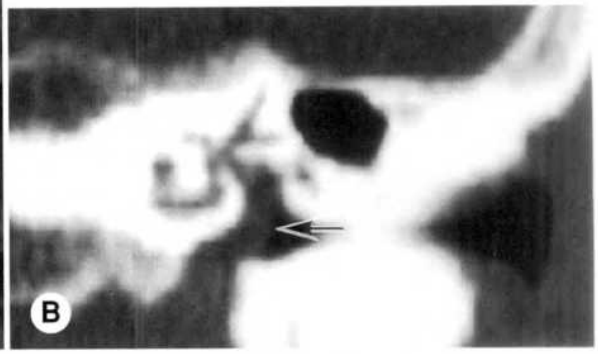

Fig 3. Soft tissue density shadow of high jugular bulb was observed around round window niche (arrows). A) Axial view. B) Coronal view.

of the thickened and calcified eardrum, the jugular bulb was not visible through the eardrum.

Tympanoplasty was performed. During elevation of the thickened eardrum at the inferoposterior part, venous blood oozed slightly. This oozing was easily stopped with pressure and a small amount of Avitene (MedChem Products, USA). The cholesteatoma matrix was exposed by attico-antrotomy, and the posterosuperior part of the bony canal was drilled down during this procedure. The incus and malleus head were completely destroyed and the horizontal part of the facial nerve was exposed by cholesteatoma. After removing the cholesteatoma, we attempted to elevate the eardrum in the pars tensa from the superior part. However, as soon as the eardrum was elevated to the level just superior to the round window niche, dark venous bleeding was seen again, although bleeding was controlled again with pressure from a piece of Avitene. It was suspected that the bleeding occurred from a small tear in the jugular bulb, which was adhering to the eardrum. The stapes remained intact, and the mobility of the footplate was moderate. It was suspected that the top of the jugular bulb was situated at the level between the round window niche and the stapes, although the top of the bulb was not clearly detected. The defect in the eardrum and skin of the posterior wall of the external auditory canal was reconstructed with temporal muscle fascia. Type III tympanoplasty was performed because the eardrum adhered to the stapes directly. The posterior wall of the bony external auditory canal was reconstructed with a piece of cortical bone. The mastoid cavity was obliterated by a Palva flap, hydroxyapatite granules, and bone paste.

DISCUSSION

The position of the jugular bulb is extremely variable and related to the position of the sigmoid sinus,[1] but is not related to the degree of temporal bone pneumatization.[2] When situated far back in the mastoid, the bulb is almost a direct continuation of the vertical part of the sigmoid sinus and the height of the bulb is relatively low. However, if the sinus is positioned far forward, it bends sharply upward into the bulb, which tends to be positioned higher.[1] A superiorly placed lateral jugular bulb is described as intruding into the middle ear, and a bulb that intrudes up into the tympanic cavity is called a high jugular bulb. In temporal bone studies, the incidence of high jugular bulbs protruding into the tympanic cavity was 25%,[3] and that of bulbs extending into the middle ear above the inferior rim of the bony annulus was 6%.[4] The height above the annulus varied from 0.6 to 4.0 mm, with a mean height of 2.2 mm.[4]

The presence of a high jugular bulb may be noted clinically by an abnormal otoscopic finding, hearing loss, or, less commonly, tinnitus. Abnormal otoscopic findings are noticed in high lateral jugular bulbs as a bluish discoloration in the posteroinferior quadrant of the eardrum. In our case, however, a thickened eardrum with calcification masked the existence of the high jugular bulb. Before the development of the CT scan, aberrant jugular bulbs were accidentally opened during middle ear surgery such as tympanotomy, tympanomeatal flap surgery, and tympanoplasty.[1,5-9] At present, it is not difficult to note the existence of a high jugular bulb before tympanoplasty, because radiologic confirmation of extent of the disease is performed by CT scan as a routine procedure. In our case, although the jugular bulb was not visible through the eardrum, massive bleeding during the surgery was avoided because the existence of a high jugular bulb was discovered by CT performed before surgery.

REFERENCES

1. Graham MD. The jugular bulb: its anatomic and clinical considerations in contemporary otology. Laryngoscope 1977;87:105-25.

2. Rauch SD, Xu W-Z, Nadol JB Jr. High jugular bulb: implications for posterior fossa neurotologic and cranial base surgery. Ann Otol Rhinol Laryngol 1993;102:100-7.

3. Savic D, Djeric D. Surgical anatomy of the hypotympanum. J Laryngol Otol 1987;101:419-25.

4. Overton SB, Ritter FN. A high placed jugular bulb in the middle ear: a clinical and temporal bone study. Laryngoscope 1973;83:1986-91.

5. Page JR. A case of probable injury to the jugular bulb following myringotomy in an infant ten months old. Ann Otol Rhinol Laryngol 1914;23:161-3.

6. Hough JVD. Congenital malformations of the middle ear. Arch Otolaryngol 1963;78:335-43.

7. Gejrot T. Retrograde jugularography in the diagnosis of abnormalities of the superior bulb of the internal jugular vein. Acta Otolaryngol (Stockh) 1964;57:177-80.

8. Smyth GDL, Black JHA. A case of protruding jugular bulb. Laryngoscope 1965;75:669-72.

9. Lloyd TV, Aman MV, Johnson JC. Aberrant jugular bulb presenting as a middle ear mass. Radiology 1979;131:139-41.

FIFTH INTERNATIONAL CONFERENCE ON HEAD AND NECK CANCER

The Fifth International Conference on Head and Neck Cancer will be held July 29–August 2, 2000, in San Francisco, California. For information, contact Concepts in Meetings & Events, Robin L. Wagner, President, 7819 Lloyd Ave, Pittsburgh, PA 15218-1941; telephone (412) 243-5156; fax (412) 243-5160; e-mail rlwa@med.pitt.edu.

IMAGING CASE STUDY OF THE MONTH

DETECTION OF UNKNOWN PRIMARY CANCER WITH FLUOR-DEOXY-GLUCOSE POSITRON EMISSION TOMOGRAPHY

MARKUS JUNGEHÜLSING, MD
KLEMENS SCHEIDHAUER, MD
HANS ECKEL, MD
UWE PIETRZYK, PHD
HARALD SCHICHA, MD
COLOGNE, GERMANY

INTRODUCTION

The definition of carcinoma of unknown primary (CUP syndrome) differs considerably in the literature, as do the clinically and histopathologically used judgment criteria.[1,2] Following the definition of Nissenblatt,[3] we presume a CUP syndrome in patients suffering from lymph node metastases without the primary cancer's being detected after the routinely performed diagnostic procedures. A CUP syndrome is diagnosed in 0.5% to 5%[4-6] of all malignant diseases, and 5% of lymph node metastases of the head and neck have an unknown primary cancer.[7]

^{18}FDG-PET (^{18}fluor-deoxy-glucose positron emission computed tomography) has been shown to be a sensitive new tool for the detection of squamous cell carcinomas.[8,9] The following case report exempli-

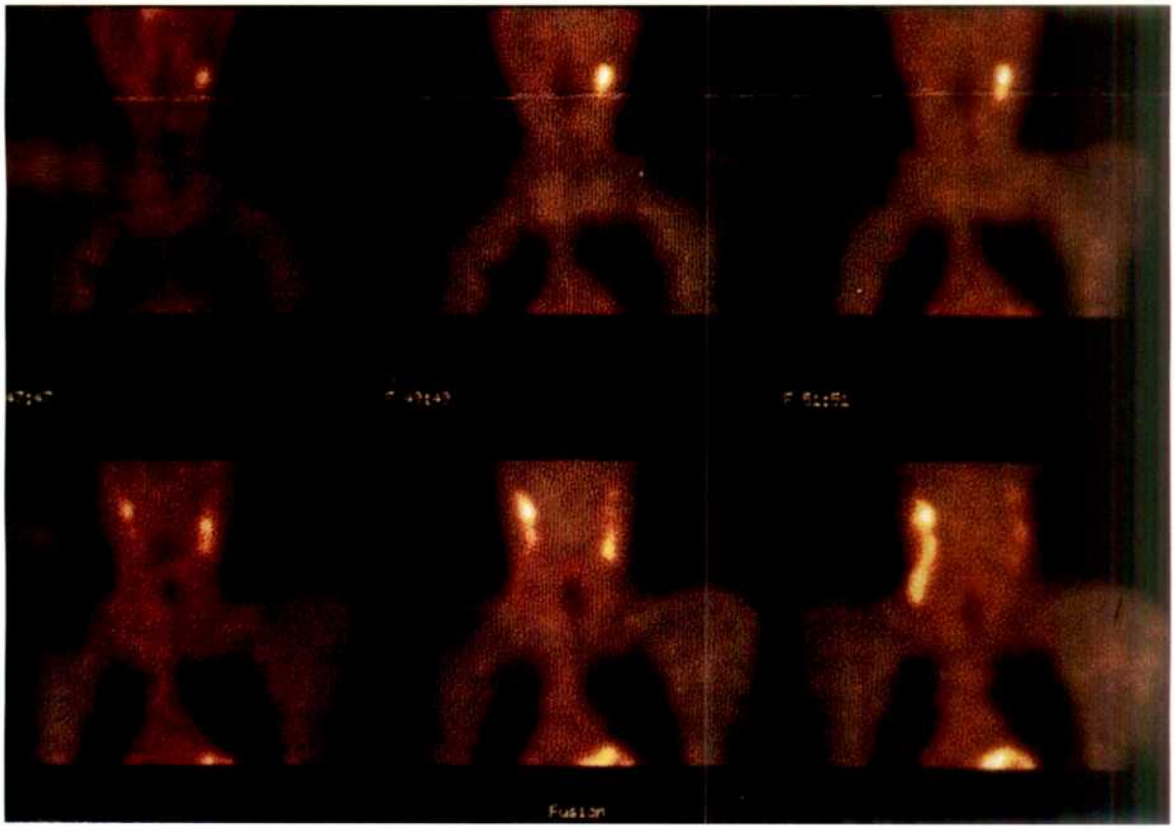

Fig 1. All images were obtained with Siemens Ecat Exact 921 PET Scan. Patient received intravenous injection of 370 megabecquerels ^{18}fluor-deoxy-glucose after 8 hours of fasting. Scanning was performed 1 hour after injection. Images were reconstructed with transmission-emission fusion technique. Coronal slices show multiple hot spots at both sides of neck, corresponding to cytologically proven metastatic spread into cervical lymph nodes.

From the Departments of Otolaryngology (Jungehülsing, Eckel) and Nuclear Medicine (Scheidhauer, Schicha), University of Cologne, and the Max Planck Institute for Neurologic Research (Pietrzyk), Cologne, Germany.

CORRESPONDENCE — Markus Jungehülsing, MD, Universitäts-Hals-, Nasen-, Ohrenklinik, 50924 Cologne, Germany.

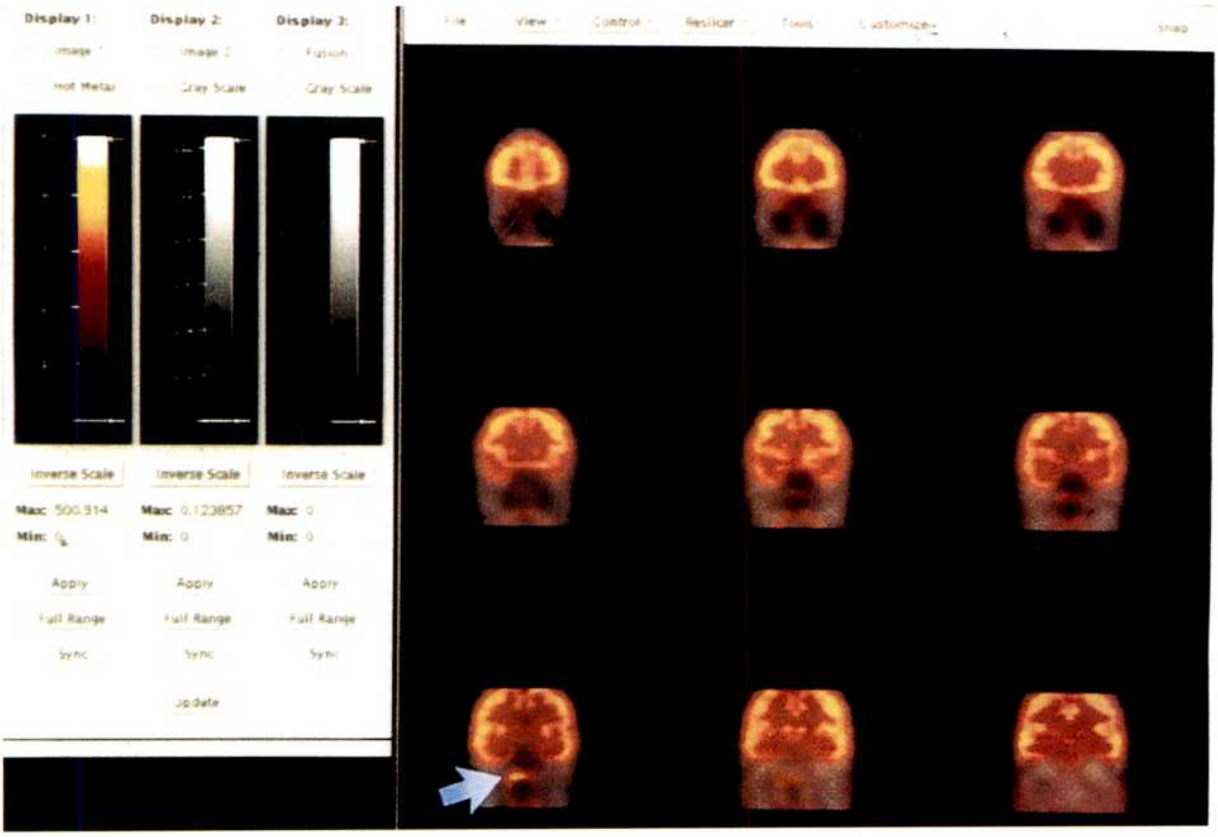

Fig 2. Coronal slices of head showing physiological ^{18}fluor-deoxy-glucose uptake of brain, and in addition, faint flat uptake in projection on roof of nasopharynx (arrow).

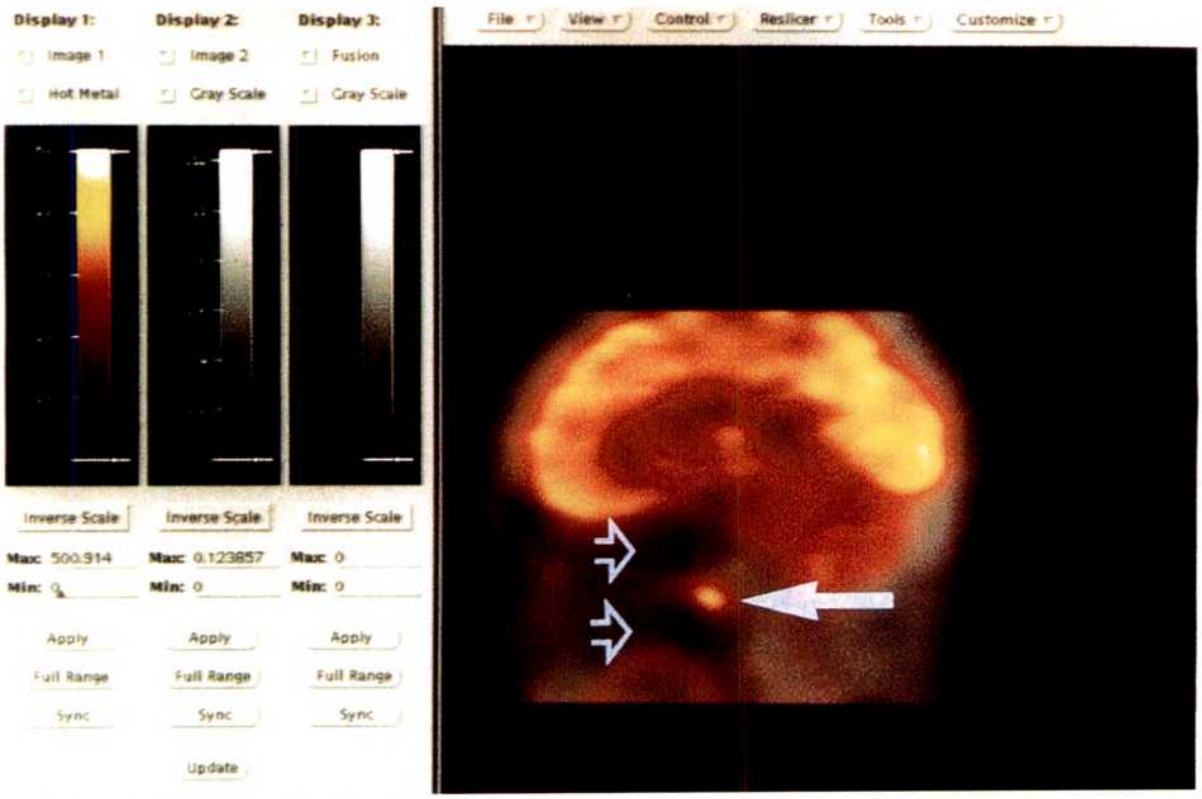

Fig 3. Median sagittal slice through head shows small primary carcinoma in posterosuperior nasopharynx (filled arrow), just between sphenoid sinus and nasopharyngeal roof (open arrows).

fies the detection of an unknown primary cancer by ^{18}FDG-PET and is the first report on ^{18}FDG-PET findings in undifferentiated carcinoma of the nasopharynx.[10]

CASE REPORT AND DIAGNOSTIC FINDINGS

A 60-year-old man presented with a prominent cervical lymph node in region V (regions classified by Medina[11]). Ultrasound of the neck showed several slightly enlarged cervical lymph nodes besides the palpable node. Fine needle biopsy revealed a poorly differentiated carcinoma. According to the propositions of Abbruzzese,[12] the patient underwent, in September 1996, the routinely performed diagnostic procedures, including endoscopy of the nasopharynx, oropharynx, hypopharynx, larynx, and esophagus with systematic biopsies in the regions advocated by Lefebvre et al.[13] Neither morphological change nor malignancy was diagnosed. Computed tomography of the skull base and thorax did not reveal any lesion. Laboratory analyses revealed a high blood sedimentation rate, but no pathological changes in electrolytes, differential blood count, or enzymes, and no Epstein-Barr virus capsid antibodies. Whole body bone scintigraphy did not show any region of increased ^{99m}technetium uptake.

Consequently, the patient's disease was classified as CUP syndrome, and ^{18}FDG-PET of the head, neck, and thorax was performed as part of an ongoing prospective study. It showed an enhanced ^{18}FDG uptake in multiple cervical lymph nodes (Fig 1). In addition, a distinctive focal tracer uptake was localized at the roof of the nasopharynx (Figs 2 and 3).

Subsequent excisional biopsy of the nasopharynx revealed an undifferentiated carcinoma measuring about 1 cm in diameter. Fine needle aspiration showed progressed metastatic spread into the cervical lymph nodes. The patient was submitted to radiotherapy.

DISCUSSION

In patients suffering from head and neck malignancies, the modern cross-sectional imaging methods (ultrasound, computed tomography, and magnetic resonance imaging) usually are able to depict the primary cancer as well as lymph node metastases with high sensitivity and accuracy.[14,15] Additionally performed endoscopy with fine needle aspiration cytology permits definite diagnosis in most patients. Improvement of cross-sectional imaging techniques and introduction of new immunocytochemical staining methods have considerably diminished the incidence of the so-called CUP syndrome.[1,2,12,13]

At the otolaryngology department of the University of Cologne between October 1993 and October 1996, new malignant lesions were diagnosed in 442 patients. Only 16 of the 442 (3.6%) patients showed CUP syndrome. Despite sophisticated therapeutic management, the prognosis of patients with CUP syndrome is poor (5-year survival of 6% to 35%[4,13]) and is dependent on the histology of the primary carcinoma and on the treatment strategy.[16] If the primary cancer appears only after therapy, it is still worse.[17] On the other hand, the survival time of patients in whom the primary tumor is diagnosed is superior to that of patients in whom the primary tumor remains unknown.[18] Therefore, special and even expensive pretherapeutic diagnostic procedures in these patients are justified.

^{18}Fluor-deoxy-glucose is subject to a specific metabolism that differs extremely in different tissues. Phosphorylation of ^{18}FDG is only possible by hexokinase, whereas normal glucose is also metabolized by glucokinase. Tumors in general show a high hexokinase activity and accumulate the metabolic product of ^{18}FDG.[19] Positron emission tomography detects and localizes the short-lived radionuclide and depicts hot spots in tomographic slices. There is no known contraindication to ^{18}FDG-PET such as allergy or intolerance, but in the condition of diabetes mellitus or enhanced blood glucose, tumor contrast may be weak; fasting of at least 8 hours is mandatory. The exposure to radiation is comparable to that with computed tomography, with an effective dose of 8 to 9 millisieverts per 370 megabecquerels of ^{18}FDG.[20]

In a study performed at the otolaryngology department of the University of Cologne, ^{18}FDG-PET revealed the primary cancer in 5 of 8 patients suffering from CUP syndrome (unpublished observations), and Schipper et al[21] detected 7 of 16 primary cancer sites with ^{18}FDG-PET. In conclusion, ^{18}FDG-PET adds important metabolic information to the morphological details of the conventional cross-sectional imaging techniques and may visualize malignant lesions more specifically. A larger study is under way to further define the place of ^{18}FDG-PET in patients suffering from CUP syndrome.

REFERENCES

1. Leonard RJ, Nystrom JS. Diagnostic evaluation of patients with carcinoma of unknown primary tumor site. Semin Oncol 1993;20:244-50.

2. Haskell CM, Cochran AJ, Barsky SH. Metastasis of unknown origin. Curr Probl Cancer 1988;12:5-57.

3. Nissenblatt MR. The CUP syndrome (carcinoma of unknown primary). Cancer Treat Rev 1981;8:211-24.

4. Altmann E, Cadmann E. An analysis of 1539 patients

with cancer of unknown primary site. Cancer 1986;57:120-4.

5. Smith PE, Krementz ET, Chapman W. Metastatic cancer without a detectable site. Am J Surg 1967;113:633-7.

6. Steckel RJ, Kagan AR. Diagnostic persistence in working up metastatic cancer with an unknown primary site. Radiology 1980;134:367-9.

7. Coker DD, Casterline PF, Chambers RG. Metastases to the lymph nodes of the head and neck from an unknown primary site. Am J Surg 1977;134:517-22.

8. Bailet JW, Abemayor E, Jabour BA, Hawkins RA, Ho C, Ward PH. Positron emission tomography: a new, precise imaging modality for detection of primary head and neck tumors and assessment of cervical adenopathy. Laryngoscope 1992; 102:281-8.

9. Jungehuelsing M, Scheidhauer K. FDG-PET im Vergleich mit CT, MRT, und Sonographie zum Staging von Kopf-, Hals-Plattenepithelkarzinomen. Eur Arch Otorhinolaryngol 1994;II:171-2.

10. Dohnert G. Lymphoepithelioma Schmincke-Regaud. Virchows Arch Pathol Anat Physiol Klin Med 1971;352:279-84.

11. Medina JE. A rational classification of neck dissections. Otolaryngol Head Neck Surg 1989;100:169-76.

12. Abbruzzese JL. An effective strategy for the evaluation of unknown primary tumors. Cancer Bull 1989;41:157-61.

13. Lefebvre JL, Coche-Dequeant B, Ton Van J, Buisset E, Adenis A. Cervical lymph nodes from an unknown primary tumor in 190 patients. Am J Surg 1990;160:443-6.

14. Mancuso A, Harnsberger H, Muraki A. Computed tomography of cervical and retropharyngeal lymph nodes: normal anatomy, variants of normal, and applications in head and neck cancer. Radiology 1983;148:709-23.

15. van den Brekel M, Castelijns J, Stel H. Detection and characterization of metastatic cervical adenopathy by MR imaging. Comparison of different MR techniques. J Comput Assist Tomogr 1990;14:581-9.

16. Daugaard G. Unknown primary tumours. Cancer Treat Rev 1994;20:119-47.

17. Hainsworth JD, Greco AF. Managing carcinomas of unknown primary site. Oncology (Huntingt) 1988;2:43-9.

18. Abbruzzese JL, Abbruzzese MC, Lenzi R, Hess KR, Raber MN. Analysis of a diagnostic strategy for patients with suspected tumors of unknown origin. J Clin Oncol 1995;13:2094-103.

19. Wilson CBJH. PET scanning in oncology. Eur J Cancer 1992;28:508-10.

20. Mejia AA, Nakamura T, Masatoshi I, Hatazawa J, Masaki M, Watanuki S. Estimation of absorbed doses in humans due to intravenous administration of fluorine-18-fluorodeoxyglucose in PET studies. J Nucl Med 1991;32:699-706.

21. Schipper JH, Schrader M, Arweiler D, Müller S, Sciuk J. Positron emission tomography to locate primary tumor in patients with cervical lymph node metastases from an occult tumor. HNO 1996;44:254-7.

BOOK REVIEWS

Office-Based Surgery in Otolaryngology

Andrew Blitzer, Harold C. Pillsbury, Anthony F. Jahn, and William J. Binder, editors. Hard cover, illustrated, indexed, 478 pages, 1998. Thieme, New York, NY, $98.

Purpose: To furnish a comprehensive review of the subject of surgery and procedures heretofore performed in the hospital.

Contents: The volume is divided into the following subject sections: basics, otology, laryngology, facial nerve surgery, rhinology, oral cavity, throat, and neck. The first section deals with the expanding managed care marketplace and includes office and surgical suite characteristics, Occupational Safety and Health Administration (OSHA) demands, insurance and legal issues, staffing and supplies, reimbursement issues, anesthesia needs, and pediatric procedures. The remaining sections, from otology to the neck, are brief discussions of surgical procedures.

Assets: The 65 contributors for this book provide well-organized information to aid the reader in choosing and performing office procedures and/or surgery. Section 1 contains an introduction to the basics of office surgery and practice in general. The first chapter, dealing with office design, is useful for both the novice and the experienced clinician. An ideal office is described, complete with equipment lists, staffing needs, and room diagrams that even include electrical outlets. A basic but extensive list of office manager duties is also given. The remaining introductory chapters are sketchy, offering the basics concerning OSHA requirements, insurance and legal issues, procedure room credentialing, and reimbursement issues. A useful chapter on the basics of office anesthesia and sedation is provided, describing suggested drugs and doses for typical procedures. A monitoring protocol is also included. This section concludes with an introduction to pediatric office procedures, of which most are typically performed without the need for a specific procedure room or operating suite.

Limitations: Many of the subjects discussed in the book are typical of everyday procedures and not considered surgery. It is difficult to sort out whether the book is referring to an operating room setting or a regular examination room. Nine out of the 12 procedures listed in the contents under otology are typically performed in an office setting on a daily basis.

Audience: This book is directed to the young otolaryngologist starting in practice.

DENNIS G. PAPPAS, MD
Birmingham, Alabama

Medical Warrior. Fighting Corporate Socialized Medicine

Miguel A. Faria, Jr. Hard cover, indexed, 207 pages, 1997. Hacienda Publishing, Macon, Ga, $23.95.

Purpose: To show that managed care and health maintenance organizations are not free market alternatives, but rather, a paradigm of corporate socialized medicine; that doctors, along with patients, need to mobilize to preserve the sanctity of the patient-doctor relationship and protest the health care and welfare of patients.

Contents: Part 1 provides arguments that some of the problems and answers to the dilemma of medicine reside in the pages of history. Faria draws parallels between the past and present regarding the plight of the Great Society, the Roman Empire, etc. In part 2, Faria attacks the issue of the environment (only 7 pages), claiming political power interests to be greater than environmental problems. Then there is a discussion of economic, political, and social control by the government of its subjects, and a section that advises physicians to base opinions on objective data and scientific facts rather than on emotions or expedience. The last part (part 5) consists of short essays on major health care reforms that are said to be leading us to socialized "corporate" medicine and the collapse of the American health care delivery system.

Assets: Succeeds in bringing much ammunition to the currently waged intellectual battle over health care reform.

Limitations: Dr Faria (obviously well read, cultured, intelligent, and with excellent communication skills) is at his best on subjects that deal directly with medicine (parts 1 and 5).

Audience: A momentous book for one searching for answers to moral, social, and economic problems, not to mention health system reform.

DENNIS G. PAPPAS, MD
Birmingham, Alabama

Imaging of the Temporal Bone

Joel D. Swartz and H. Ric Harnsberger, editors. Third edition. Hard cover, illustrated, indexed, 497 pages, 1998. Thieme, New York, NY, $248.

Purpose: To develop a basic didactic reference book that includes discussion and illustration of several lesser-known entities in addition to the more common.

Contents: Eight chapters involving anatomy (external canal, middle ear, facial nerve, vestibular cochlear nerve) and pathology (vascular anomalies, otodystrophies, trauma).

Assets: Images in the book depict excellent resolution of anatomic structures and pathological conditions. The reader is not distracted by multiple linear arrows, as in many books, identifying too many structures. Only pertinent temporal bone structures and maladies are acknowledged. There is comprehensive coverage of the temporal bone.

Limitations: For the otologist, there is too much anatomic text that is commonly available in basic otolaryngology books. Such in-depth anatomic discussion is relevant, though, for the radiologist.

Audience: Indeed, the authors meet their goal, in that the book is a good practical resource in daily practice for the otologist or otolaryngologist, and especially for the radiologist.

DENNIS G. PAPPAS, MD
Birmingham, Alabama

Treatment Options for Ménière's Disease. Endolymphatic Sac Surgery: Do It or Don't Do It?

I. Kaufman Arenberg and Malcolm D. Graham, editors. Hard cover, illustrated, indexed, 155 pages, 1998. Singular Publishing Group, San Diego, Calif, $125.

Purpose: The title tells it all.

Contents: There are 36 contributors and 25 chapters, not including the introduction and closing remarks. The main parts are those giving 1) background information such as basics of management and physiology, 2) arguments for the surgery, 3) arguments against the surgery, and 4) a general rationale for optional surgery for Meniere's disease.

Assets: The various authors have tried to include everything

useful to convince the reader of their decision for or against sac surgery. In fact, the reader may want to forget sac surgery and read through the book so as not to miss any of the information, data, etc, on Meniere's disease, which is comprehensive and useful. Chapter 16 dares to go beyond the proscribed limits set by most physicians for opinion and conveys the socio-economic aims of sac surgery. Though daring to do so may seem to involve monetary benefits, this feature has an important bearing on these discussions. Several authors discuss the shortcomings of available prosthetics used in shunt surgery. That is, the endolymphatic sac and ducts may be stenotic or fibrotic, and the prosthesis stem may be too large for the lumen to accommodate. Differences emerging from discussions are expressed by the authors, but the reader is not subjected to persuasion.

Limitations: The data pro and con sac surgery throughout the book are generally unscientific (lacking controls and statistical validity). Mainly for this reason, the reader cannot be "judge and jury" in sac surgery.

Audience: Though the doors on deciding on sac surgery are closed, the windows of opportunity are open for much information on Meniere's disease for all specialties that deal with this condition.

DENNIS G. PAPPAS, MD
Birmingham, Alabama

Web Doctor. Your Online Guide to Health Care and Wellness

Richard M. Sharp and Vicki F. Sharp. Soft cover, illustrated, indexed, 557 pages, 1998. Quality Medical Publishing, St Louis, Mo.

Web Doctor is a 500-page book that contains descriptions of 1,500 web sites that relate to medicine. In addition, there is a CD-ROM that provides Internet access through a web browser for these various medical sites.

Each web site included in the book was selected on the basis of whether it gives appropriate and relevant health care information, if it is a stable Internet location, if it has been updated on a regular basis, if it operates and functions well (having a reasonable download time), and if it has been an award-winning site and/or cited for its authoritative information.

The book is quite easy to use. There are 3 web sites per page, with a picture illustrating the home page of the web site and a description of the information contained in the site. The web pages are also indexed in the back of the book for easy access.

We are not made aware of any physicians or review panel that were involved in selecting the web sites or that were involved in the verification of the web sites' reliability. The authors of the book are both professors of education. The same authors were also instrumental in production of a book on best web sites for teachers and best mathematics and science web sites.

Unfortunately for the fields of otolaryngology and audiology, there are very few sites contained in the book. For example, the web site of the American Academy of Otolaryngology–Head and Neck Surgery is not listed. The only "ear" web page selected was from the Cochlear Fluids Research Laboratory at Washington University, St Louis, Mo. There are 2 sites listed under "deafness." One site is listed under "hearing." One web site does list and allow the user to download the information on all of the Academy's brochures. However, the number of sites available for the otolaryngology specialty would definitely be less than 10.

The inclusion of the site on cochlear fluid research raises a question as to the filter the authors used for the inclusion of sites and as to who is their target audience for the book.

The CD-ROM serves as an index of sites that can be easily searched and readily referenced with a web browser such as Netscape. The CD-ROM attempts to mimic a search engine in this regard. The only major drawback is that the web site is listed only by name and there is no attached description. Thus, the user will have to actually enter the on-line web site in order to determine whether or not the web site is appropriate for the problem he or she is trying to research. Aside from this drawback, the web browser was very easy to use.

In summary, I feel that *Web Doctor* is a useful reference tool for a general practitioner or for patients trying to research a particular illness. I, however, do not feel that it will be readily useful in the otolaryngologist's armamentarium.

KEVIN T. KAVANAGH, MD
Somerset, Kentucky

DOCUMENTATION OF THE PREVALENCE OF PENICILLIN-RESISTANT *STREPTOCOCCUS PNEUMONIAE* ISOLATED FROM THE MIDDLE EAR AND SINUS FLUID OF CHILDREN UNDERGOING TYMPANOCENTESIS OR SINUS LAVAGE

NINA L. SHAPIRO, MD
LOS ANGELES, CALIFORNIA
MICHELLE MARTIN, MT, SM
SAN DIEGO, CALIFORNIA
SETH M. PRANSKY, MD
SAN DIEGO, CALIFORNIA
JOHN S. BRADLEY, MD
SAN DIEGO, CALIFORNIA

With increasing pneumococcal resistance to penicillin and other antibiotics, use of antibiotic therapy for children with upper respiratory tract infections such as otitis media and sinusitis has become difficult. Selecting an appropriate treatment regimen has become more challenging due to frequent concomitant microbial resistance to multiple antibiotics. In a prospective, nonrandomized study, we obtained middle ear and sinus aspirate specimens from all children undergoing outpatient tympanocentesis or sinus lavage for any indication at our institution over two 4-week periods. One hundred fifty-four specimens were obtained. Of these, 12 grew *Streptococcus pneumoniae*, 7 of which were resistant to penicillin. A 6-month retrospective review of these patients' medical histories evaluated their antibiotic use prior to surgical intervention. An association between penicillin resistance and recent use of 2 or more antibiotics in children with positive *S pneumoniae* cultures was confirmed, as has been documented in prior reports. Those with penicillin-resistant *S pneumoniae* also demonstrated a higher incidence of multidrug-resistant organisms.

KEY WORDS — otitis media, penicillin, *Streptococcus pneumoniae*.

INTRODUCTION

Streptococcus pneumoniae accounts for 30% to 40% of cases of acute otitis media and sinusitis in children.[1] Penicillin-resistant *S pneumoniae* was first documented in the United States in 1974,[2] and the incidence of resistance has increased dramatically since then. From 1979 to 1987, penicillin resistance was found in 0.02% of cases of *S pneumoniae* infection; in 1992, 1.3% to 5% of cultures were penicillin-resistant. In 1995 to 1997, the incidence of penicillin-resistant *S pneumoniae* ranged from 17% to 42%.[2] Potential risk factors for antibiotic resistance have been well documented. These include current or prior antibiotic use, both for acute infections and as prophylaxis, recurrent infections in the prior 6 months, day care attendance, and age less than 24 months.[3-7]

The purpose of this study was to document the prevalence of penicillin-resistant *S pneumoniae* in the otolaryngology outpatient surgical setting in San Diego, California. All outpatients undergoing tympanocentesis or sinus lavage at our Children's Hospital Day Surgery Center over two 4-week periods were included.

PATIENTS AND METHODS

All patients undergoing tympanocentesis with or without tympanostomy tube placement, or sinus lavage with or without endoscopic sinus surgery, were included in the study. Institutional internal review board approval was obtained prior to commencing the study. The two 4-week testing periods were June 1996 and January 1997. Aerobic specimens were taken via a sterile aspirate suction trap (Juhn Tym-Tap, Xomed Surgical Products, Jacksonville, Fla) after entering the middle ear or sinus. We did not attempt to sterilize the external auditory canal or middle meatus, as previous reports have shown correlation between external skin or mucosal organisms and middle ear or sinus pathogens.[8] Fluid aspirate was plated on sheep blood agar plates and incubated overnight in 5% carbon dioxide at 35°C. Optochin disc α-hemolysis was utilized to identify positive *S pneumoniae* cultures. An *S pneumoniae* minimum inhibitory concentration (MIC) microtiter plate panel was then performed for antibiotic susceptibility testing.

The positive *S pneumoniae* cultures were evaluated for penicillin susceptibility according to the National Committee for Clinical Laboratory Standards

From the Division of Pediatric Otolaryngology (Shapiro, Pransky), the Microbiology Laboratory (Hartin), and the Division of Infectious Disease (Bradley), Children's Hospital and Health Center, San Diego, California. This study was supported by SmithKline-Beecham Laboratories.
Presented at the First Annual Symposium on Infectious Diseases in Pediatric Otolaryngology, Aspen, Colorado, August 10-12, 1997.
CORRESPONDENCE — Nina L. Shapiro, MD, Pediatric Otolaryngology/Division of Head and Neck Surgery, UCLA School of Medicine, 62-158 CHS, 10833 LeConte Ave, Los Angeles, CA 90095.

TABLE 1. MULTIDRUG RESISTANCE IN PATIENTS WITH PENICILLIN-RESISTANT *STREPTOCOCCUS PNEUMONIAE*

	Patient						
Antibiotic Resistance	*1*	*2*	*3*	*4*	*5*	*6*	*7*
Erythromycin	x	x	x			x	x
Clarithromycin	x	x	x				x
Cefuroxime	x	x	x		x		x
Trimethoprim-sulfamethoxazole	x	x		x	x	x	x
Chloramphenicol		x				x	x
Amoxicillin-clavulanate potassium	x						
Cefaclor	x				x		
Clindamycin		x					x

Patient 7 had intermediate penicillin susceptibility.

(NCCLS)[9] guidelines for penicillin susceptibility. Isolates with an MIC value to penicillin of ≤0.06 μg/mL were considered penicillin-susceptible; those with an MIC of 0.12 to 1.0 μg/mL were considered intermediately penicillin-resistant, and those with an MIC of ≥2.0 μg/mL were considered highly penicillin-resistant. We considered patients with intermediate resistance or high resistance to be penicillin-resistant.

The retrospective arm of this study involved identifying each patient with a positive intraoperative *S pneumoniae* culture. Records of prior antibiotic use were obtained from each of these patients' primary care physicians. There were multiple antibiotics utilized for acute therapy. The most commonly used antibiotics for acute middle ear and sinus infections included amoxicillin, amoxicillin–clavulanate potassium, erythromycin-sulfisoxazole, cefixime, and trimethoprim-sulfamethoxazole. Prophylactic antibiotic therapy, which consisted of one third to one half of the therapeutic antibiotic dosage given once daily for 30 to 60 days, was amoxicillin or trimethoprim-sulfamethoxazole. These antibiotics were chosen by individual primary care pediatricians in a catchment area of 2.5 million people prior to referral to the pediatric otolaryngologists in our group. Number of antibiotic "days" (number of days in 6 months prior to surgery receiving therapeutic or prophylactic antibiotics) was recorded for each patient with a positive *S pneumoniae* culture.

RESULTS

One hundred fifty-four cultures (111 patients; 105 middle ear; 6 sinus) were obtained. The age distribution in this study ranged from 3 to 161 months (mean 43.1 months; median 34 months; range 3 to 161 months). There were 99 patients who did not have positive cultures for *S pneumoniae*. The mean age of this group was 45.8 months (median 38 months; range 3 to 161 months). The mean age of patients with positive *S pneumoniae* cultures was 20.6 months (median 14.5 months; range 10 to 54 months). The mean age of patients with penicillin-susceptible *S pneumoniae* was 11.6 months (range 6 to 15 months). The patient with intermediately penicillin-susceptible *S pneumoniae* was 28 months old. The mean age of patients with penicillin-nonsusceptible *S pneumoniae* was 25.7 months (range 10 to 54 months). The mean age of patients with positive *S pneumoniae* cultures was significantly younger (p = .001, Mann-Whitney U-test) than that of patients in this study with negative *S pneumoniae* cultures.

TABLE 2. ANTIBIOTIC USE IN PRIOR SIX MONTHS IN PATIENTS WITH PENICILLIN-SUSCEPTIBLE *STREPTOCOCCUS PNEUMONIAE*

	Antibiotic Days	
Patient	*Therapy*	*Prophylaxis*
8	24	54
9	40	21
10	60	0
11	80	0
12	30	0
Mean (d)	46.8	15

There were 73 boys (65.8%) and 38 girls (34.2%) in this study. In the group with negative *S pneumoniae* cultures, there were 63 boys (63.6%) and 36 girls (36.4%). In the group with positive *S pneumoniae* cultures, there were 7 boys (58.3%) and 5 girls (41.7%). Among all study patients, there were more boys than girls (p = .01, binomial z-test). However, gender was not significantly associated with *S pneumoniae* culture results (p = .76, Fisher's exact test).

Twelve cultures of the 154 (8%) grew *S pneumoniae*. Positive cultures were evaluated by an MIC titer panel for antibiotic susceptibility. Six cultures were highly resistant (MIC ≥ 2.0 μg/mL) to penicillin. Four of these 6 were middle ear cultures, and 2 were sinus cultures. One culture (middle ear) had intermediate penicillin susceptibility (MIC 0.12 to 1.0 μg/mL). Five cultures (all middle ear) were penicillin-susceptible (MIC ≤ 0.06 μg/mL). Cultures with penicillin-nonsusceptible *S pneumoniae* had notably more multiple antibiotic resistance than those with penicillin susceptibility (Table 1).

Antibiotic therapy data for the 6 months prior to surgery were obtained from patient medical records of the referring primary care physicians. Antibiotic uses for acute infections and for prophylaxis were recorded separately. Antibiotic "days" (number of days receiving antibiotics) were recorded as an indicator for antibiotic use. Mean therapeutic and prophylactic antibiotic days for the penicillin-suscep-

TABLE 3. ANTIBIOTIC USE IN PRIOR SIX MONTHS IN PATIENTS WITH PENICILLIN-RESISTANT *STREPTOCOCCUS PNEUMONIAE*

	Antibiotic Days	
Patient	*Therapy*	*Prophylaxis*
1	Unknown	Unknown
2	Unknown	Unknown
3	110	60
4	122	0
5	92	10
6	58	0
7	40	0
Mean (d)	84.4	14

tible group were 46.8 and 15 days, respectively (Table 2). Mean acute and prophylactic antibiotic days for the penicillin-resistant group were 84.4 and 14 days, respectively (Table 3).

DISCUSSION

In this study, we document the prevalence of penicillin-resistant *S pneumoniae* in the outpatient otolaryngology surgical setting. The low actual prevalence (8%) of positive *S pneumoniae* cultures may be attributed to the patient population, in that we included all surgical outpatients, with or without acute infections, in the study. While the actual percentage of positive cultures was less than the prevalence of *S pneumoniae* seen in acute otitis media and acute sinusitis, the prevalence of penicillin-resistant *S pneumoniae* within all *S pneumoniae* isolates was high (7 of 12 or 58%). This prevalence of penicillin-resistant *S pneumoniae* is consistent with recent findings. Nelson et al[10] tested 62 middle ear isolates and 9 sinus isolates of penicillin-nonsusceptible *S pneumoniae*. Of the middle ear isolates, 35 of 62 (56%) were intermediately penicillin-nonsusceptible, and 27 of 62 (44%) were highly nonsusceptible. Five of the 9 sinus isolates (56%) were intermediately penicillin-nonsusceptible, and 4 of the 9 (44%) were highly nonsusceptible.[10]

We found that patients with penicillin-resistant *S pneumoniae* had a high incidence of multiantibiotic resistance on MIC testing (Table 1). The resistance rates for these organisms include β-lactam antibiotics (ampicillin), which act similarly to penicillin by interaction with penicillin-binding proteins on *S pneumoniae*. Alteration of these proteins is the primary mode of nonsusceptibility in nonsusceptible *S pneumoniae*.[11] β-Lactamase-producing antibiotics such as amoxicillin–clavulanate potassium may have equal resistance, as the resistance is not dependent on β-lactamase production. However, increasing the dosage of β-lactam antibiotics (amoxicillin 80 mg/kg per day or amoxicillin 40 mg/kg per day with amoxicillin–clavulanate potassium 40 mg/kg per day) may achieve higher middle ear fluid concentrations of antibiotics and perhaps improve antibiotic response.[3] Non–β-lactam antibiotics such as erythromycin and trimethoprim-sulfamethoxazole demonstrate similar patterns of resistance in penicillin-nonsusceptible *S pneumoniae* strains.[4,12] The mechanism of antibiotic resistance is different between antibiotic classes, with no linked resistance reported to date.

Patients with higher numbers of antibiotic "days" prior to surgery had a higher incidence of penicillin-resistant *S pneumoniae*. While the numbers in this study were small, precluding statistical significance, prior antibiotic use has been documented as contributing to incidence of nonsusceptible organisms. Block et al[6] compared 30% of 63 isolates of penicillin-nonsusceptible *S pneumoniae* from patients recently treated with antibiotics to 2% of 220 isolates of penicillin-nonsusceptible *S pneumoniae* from patients not recently treated with antibiotics. This difference was statistically significant ($p < .0001$; RR = 5.4; 95% confidence interval 3.98 to 7.3).[6]

Nasopharyngeal carriage of *S pneumoniae* is widely believed to precede middle ear carriage and/or infection.[13] Antibiotic use has been shown to be a risk factor for nasopharyngeal carriage, and consequently middle ear carriage, of penicillin-nonsusceptible *S pneumoniae*.[14] Several groups have looked at nasopharyngeal isolates for penicillin-nonsusceptible *S pneumoniae*. In rural Kentucky communities, current antibiotic use was more frequent in children carrying penicillin-nonsusceptible *S pneumoniae* than those with susceptible strains: 31 of 36 (86%) versus 30 of 80 (38%), respectively.[15] In a Tennessee community, 21 of 40 (53%) children with penicillin-nonsusceptible *S pneumoniae* had received β-lactam antibiotics in the prior 3 months, while 25 of 60 (42%) children with penicillin-susceptible *S pneumoniae* had used β-lactam antibiotics in the same time period ($p = .312$).[13]

The average age of patients in our study with positive *S pneumoniae* cultures was 20.6 months, and patients with penicillin-resistant *S pneumoniae* had a mean age of 25.7 months. The mean age of our study population was 43.1 months. The difference in mean age between patients positive for *S pneumoniae* and those negative for *S pneumoniae* was statistically significant ($p = .001$, Mann-Whitney U-test). An association between young age (<2 years) and *S pneumoniae* carriage and penicillin nonsusceptibility has been observed in prior reports.[6] Nasopharyngeal aspirates were evaluated in the Yukon-Kuskokwim Delta of Alaska, which has one of the highest pneumococcal bacteremia rates in the world. Age less than 24 months was a significant risk factor for

carriage of intermediately susceptible or highly nonsusceptible *S pneumoniae* in the nasopharynx ($p < .001$; RR = 3.0).[5]

Day care attendance,[6] Caucasian race,[4] and parental smoking[2] have all been associated both with higher rates of otitis media and with penicillin-nonsusceptible organisms. These variables were not the focus of the present study. The population under 24 months is at highest risk for both infection and infectious complications such as bacteremia and meningitis. Pneumococcal vaccination with the currently available 23-valent capsular polysaccharide vaccine cannot be routinely used in patients under 2 years, as they are not yet able to mount an effective, sustained immune response against polysaccharide antigens.[5] Several clinical trials utilizing conjugate vaccines, focusing on this age group, are in progress.[16,17]

This report is part of a series of recent documentations throughout numerous locations in this country confirming the overwhelming incidence of penicillin-nonsusceptible *S pneumoniae* in the pediatric population (First Annual Symposium on Infectious Diseases in Pediatric Otolaryngology, Aspen, Colorado, August 1997). The focus on curtailing overuse of antibiotics with increasing nonsusceptibility patterns must be addressed. It is clear from this and multiple previous studies[2-7,10,12-15] that antimicrobial resistance is of significant concern. We recommend reconsidering the utilization of long-term antibiotic therapy in cases of persistent middle ear effusion without evidence of acute infection. Children with middle ear effusion noted incidentally on examination should not be treated with antibiotic prophylaxis if they do not meet specific criteria.[18] Antimicrobial prophylaxis, which may consist of once-daily amoxicillin or sulfamethoxazole therapy, has been shown to benefit children with persistent middle ear effusion for greater than 3 months with accompanying hearing loss.[19] A second group of patients that meet criteria for antibiotic prophylaxis are those who develop 3 or more episodes of acute otitis media in a 6-month period, or 4 or more episodes in a 12-month period.[18]

Obtaining middle ear or sinus cultures on all patients prior to instituting antibiotic therapy would not be practical in children or adults. Children with recurrent acute infections refractory to several courses of antibiotics may merit middle ear or sinus culture to identify the causative organism. Community otolaryngologists may consider performing surveillance cultures during myringotomy and/or antral lavage to assess that individual community's prevalence of antimicrobial-resistant organisms.

The impact of antibiotic overuse must be emphasized to primary care physicians. Education of primary care physicians by otolaryngologists regarding the issue of antibiotic resistance after multiple courses of antibiotic therapy may reduce the incidence of multiagent-resistant bacteria. We are certainly not discouraging antibiotic utilization for acute otitis media or sinusitis per se. However, the propensity for increasing resistance with multiple courses of antibiotics needs to be addressed at the primary care level.[20]

ACKNOWLEDGMENTS — We gratefully acknowledge Kathyann Marsh, RN, MSN, Diane Bleyle, RN, Joan Young, RN, MS, and Rowena Bacungan, RN, for their help and participation in specimen and data collection.

REFERENCES

1. Dagan R, Abramson O, Leibovitz E, et al. Impaired bacteriologic response to oral cephalosporins in acute otitis media caused by pneumococci with intermediate resistance to penicillin. Pediatr Infect Dis J 1996;15:980-5.

2. Jacobs MR. Increasing importance of antibiotic-resistant *Streptococcus pneumoniae* in acute otitis media. Pediatr Infect Dis J 1996;15:940-3.

3. Kaplan SL, Bradley JS, Klugman KP, Leggiadro RJ. Consensus management of infections in children caused by *Streptococcus pneumoniae* with decreased susceptibility to penicillin. Pediatr Infect Dis J 1995;14:1037-41.

4. Hoffman J, Cetron MS, Farley MM, et al. The prevalence of drug-resistant *Streptococcus pneumoniae* in Atlanta. N Engl J Med 1995;333:481-6.

5. Ussery XT, Gessner BD, Lipman H, et al. Risk factors for nasopharyngeal carriage of resistant *Streptococcus pneumoniae* and detection of a multiply resistant clone among children living in the Yukon-Kuskokwim Delta region of Alaska. Pediatr Infect Dis J 1996;15:986-92.

6. Block SL, Harrison CJ, Hedrick JA, et al. Penicillin-resistant *Streptococcus pneumoniae* in acute otitis media: risk factors, susceptibility patterns, and antimicrobial management. Pediatr Infect Dis J 1995;14:751-9.

7. McCracken GH. Emergence of resistant *Streptococcus pneumoniae:* a problem in pediatrics. Pediatr Infect Dis J 1995; 14:424-8.

8. Ibekwe AO, Al Shareef Z, Benayam A. Anaerobes and fungi in chronic suppurative otitis media. Ann Otol Rhinol Laryngol 1997;106:649-52.

9. National Committee for Clinical Laboratory Standards. Performance standards for antimicrobial susceptibility testing: sixth informed supplement. NCCLS Document M100-S6. Vol 15. No. 4. Villanova, Pa: National Committee for Clinical Laboratory Standards, 1995.

10. Nelson CT, Mason EO, Kaplan SL. Activity of oral antibiotics in middle ear and sinus infections caused by penicillin-resistant *Streptococcus pneumoniae*: implications for treatment. Pediatr Infect Dis J 1994;13:585-9.

11. Appelbaum PC. Epidemiology and *in vitro* susceptibility of drug-resistant *Streptococcus pneumoniae*. Pediatr Infect Dis J 1996;15:932-9.

12. Friedland IR, McCracken GH. Management of infections caused by antibiotic-resistant *Streptococcus pneumoniae*. N Engl J Med 1994;331:377-82.

13. Arnold KE, Leggiadro RJ, Breiman RF, et al. Risk factors for carriage of drug-resistant *Streptococcus pneumoniae* among children in Memphis, Tennessee. J Pediatr 1996;128: 757-64.

14. Zenni MK, Cheatham SH, Thompson JM, et al. *Streptococcus pneumoniae* colonization in the young child: association with otitis media and resistance to penicillin. J Pediatr 1995; 127:533-7.

15. Duchin JS, Breiman RF, Diamond A, et al. High prevalence of multi-drug resistant *Streptococcus pneumoniae* among children in a rural Kentucky community. Pediatr Infect Dis J 1995;14:745-50.

16. Dagan R, Muallem R, Yagupsky P. Reduction of nasopharyngeal carriage of penicillin-resistant pneumococci by pneumococcal-OMPC conjugate vaccine during second year of life [Abstract]. In: Program and abstracts of the 35th Interscience Conference on Antimicrobial Agents and Chemotherapy, San Francisco, September 17-20, 1995. Washington, DC: American Society for Microbiology, 1995:G2.

17. Steinhoff MC, Edwards K, Keyserling H, et al. A randomized comparison of three bivalent *Streptococcus pneumoniae* glycoprotein conjugate vaccines in young children: effect of polysaccharide size and linkage characteristics. Pediatr Infect Dis J 1994;13:368-72.

18. Dowell SF, Marcy M, Phillips WR, Gerber MA, Schwartz B. Otitis media — principles of judicious use of antimicrobial agents. Pediatrics 1998;101:165-71.

19. Stool SE, Berg AO, Berman S, et al. Otitis media with effusion in young children. Clinical practice guideline. Agency for Health Care Policy and Research Publication No. 94-0622. Rockville, Md, 1994.

20. Paradise JL. Managing otitis media: a time for change. Pediatrics 1995;96:712-5.

≈

MIDDLE EAR MECHANICS

The Second International Symposium on Middle Ear Mechanics in Research and Otosurgery will be held October 21-24, 1999, in Boston, Massachusetts. For information, contact Harvard MED-CME, PO Box 825, Boston, MA 02117; telephone (617) 432-1525; web site http://www.med.harvard.edu/conted/.

Ann Otol Rhinol Laryngol 108:1999

ABILITY OF NUCLEUS COCHLEAR IMPLANTEES TO RECOGNIZE MUSIC

SHUJI FUJITA, MD JUICHI ITO, MD, PHD

OTSU, JAPAN

Eight adults with cochlear implants participated in experiments to test their ability to recognize music. Some subjects showed good ability to recognize songs that were sung with instrumental accompaniment but poor ability to recognize songs played on an electronic keyboard without verbal cues, indicating that they were recognizing the songs by verbal cues rather than by musical qualities such as tones and melodic intervals. This conclusion was strengthened by the finding that subjects were barely able to distinguish between songs with the same rhythm and pitch range, and they showed poor ability to discriminate musical intervals. (The closest discrimination was 4 semitones.) Subjects had good ability to distinguish among the synthesized sounds of various musical instruments played on the electronic keyboard. We speculate that subjects could distinguish the various musical instruments in the same way they distinguish among human voices using spectrographic patterns such as formants or maxima.

KEY WORDS — cochlear implant, music, pitch perception.

INTRODUCTION

As advances are made in cochlear implant technology and the number of cochlear implant recipients increases, demand is rising for implant systems that better meet their hearing needs. One concern of many who have received a cochlear implant is that they can no longer enjoy listening to music as they had before losing their hearing.

Only a few reports have been published about the ability of those with cochlear implants to recognize music. Eddington et al[1,2] reported on a deaf individual who, after receiving a cochlear implant prosthesis, could recognize 3 out of 5 songs, which were presented by the cochlear implant device as changes in the rate of electrical stimulation through a single electrode.

Pijl and Schwarz[3,4] also tested the abilities of cochlear implant recipients to recognize melodies and musical intervals when the pitches were presented through a single bipolar electrode as electrical stimuli at various rates. However, because multiple electrodes are usually stimulated in most current cochlear implants responding to sound, their results do not truly reflect the music recognition ability of individuals with modern cochlear implants. Furthermore, little has been published about the ability of persons with multichannel cochlear implants to recognize music in their daily lives, outside the laboratory setting.[5]

We investigated this topic by conducting a series of experiments in which we presented sound stimuli as sounds, rather than as direct electrical stimuli, to individuals with multichannel Nucleus cochlear implants. We evaluated the subjects' ability to recognize musical elements in the light of coding strategies used to code sound in cochlear implants.

MATERIALS AND METHODS

Candidates for this study were individuals who were postlingually deaf, still remembered nursery songs, could understand the concept of musical pitch (determined by careful questioning), and had cochlear implants with more than 17 pairs of electrodes functioning reliably. We determined that candidates understood the concept of "pitch" when they explained it as "frequency" or "highness or lowness" of a tone and differentiated it from other qualities such as loudness. The purpose and procedures of the experiment were presented to each candidate in writing, and those who understood musical pitch and gave written consent to participate were enrolled in the study.

Subjects. The 8 adults who agreed to participate in the study are profiled in Table 1. Their average age was 48.8 years (range 28 to 71 years), and their deafness had lasted between 2 months and 20 years. Seven subjects used mini sound processors with a multipeak (MPEAK) coding strategy, and the eighth used a SPECTRA 22 sound processor with a spectral peak (SPEAK) coding strategy. Two of the female subjects (subjects 1 and 3) had played the piano before losing their hearing, and they still played occasionally at the time of the study. The other 6 subjects had no formal musical training.

Equipment and Procedures. Nursery songs with vocal and instrumental accompaniment were obtained from commercial cassette audiotapes. The 20

From the Department of Otorhinolaryngology, Otsu Red Cross Hospital, Otsu, Japan.

CORRESPONDENCE — Shuji Fujita, MD, Dept of Otorhinolaryngology, Otsu Red Cross Hospital, 1-1-35 Nagara, Otsu, Shiga 520, Japan.

TABLE 1. PROFILES OF SUBJECTS

Subject No.	*Age (y)*	*Sex*	*Cause of Deafness*	*Duration of Deafness*	*Coding Strategy*
A	42	M	Bilateral Meniere's disease	6 y	MPEAK
B	31	M	Progressive SNHL	20 y	MPEAK
C	69	F	Unknown	10 mo	MPEAK
D	42	F	Unknown	2 mo	MPEAK
E	44	F	Unknown	12 y	SPEAK
F	28	F	Progressive SNHL	18 mo	MPEAK
G	71	F	Sudden SNHL	16 y	MPEAK
H	63	M	Sudden SNHL	13 mo	MPEAK

SPEAK — spectral peak, MPEAK — multipeak, SNHL — sensorineural hearing loss.

songs that were used were selected on the basis of these 3 criteria: the songs were known to most people, the vocal portions were clearly articulated, and only a few instruments were used in the accompaniment. For ease and uniformity of presentation, the songs were recorded on audiotape with a digital audiotape recorder (Sony TCD-D7). All other musical stimuli were played on an electronic keyboard (Yamaha PSS31) that has dozens of timbres simulating musical instruments. We simulated instruments on the keyboard rather than playing tape recordings of instruments because patients would have lost their focus if we had taken time to rewind a tape recording to the exact position of the next musical stimulus to be presented.

Experiments to test the subjects' music recognition ability were performed in a quiet room, with sounds presented at 65 to 75 dB sound pressure level (SPL) as measured near the microphone to the cochlear implant. Testing was conducted with each individual's speech processor on settings he or she used in daily life. Each subject was asked to perform the following tasks: 1) recognize nursery songs (both open and closed sets) sung with instrumental accompaniment (10 trials) and played on the keyboard (no vocal; 10 trials), 2) distinguish among 4 nursery songs with the same rhythm and pitch range, played on the keyboard (10 trials), 3) distinguish musical intervals played on the keyboard (10 trials for each of 6 intervals), and 4) distinguish which musical instrument was being played on the keyboard (10 trials). The battery of tasks required 1 to 1.5 hours to complete, and each subject completed the tasks in 1 day. We interviewed the subjects after each session.

The sound stimuli were analyzed spectrographically on a personal computer equipped with an analog-to-digital data conversion board, 16-bit resolution, and a sampling frequency of 22 kHz. A program written by the first author applied a Hanning window to the digitized data, followed by fast Fourier transformation of 512 points consecutively. The results were displayed graphically on the computer monitor and printed with gray scales.

Recognition of Nursery Songs (Open and Closed Sets). For this task, each subject was presented with 10 audiotaped songs chosen at random from among 20 nursery songs that were sung with accompaniment by more than 1 instrument. Each subject was told that he or she would hear popular nursery songs, but was not given a list of the songs (open set). The subject was asked to give the title or some words unique to the song on every trial, but no feedback was given for the response.

We then showed the subject a list of the 20 songs and asked him or her which songs were familiar. We selected 10 songs from among those the subject said were familiar to him or her and told the subject that 10 songs would be presented from this set (closed set), that the songs would be presented at random, and that each song in the selected group could be presented once, more than once, or never. The subject was required to provide a name for each song presented, even if he or she was not sure which song was being played. The results of the closed-set sessions were analyzed statistically.

We also performed testing with open and closed sets, as just described, for melody lines of nursery songs played on the keyboard, set in piano mode, without vocal or other instrumental accompaniment.

Distinguishing Among Songs With Same Rhythm and Pitch Range. At the start of this music recognition task, each subject was shown a list of 4 songs that have the same rhythm and similar pitch ranges (Fig 1). All of the subjects were familiar with all 4 songs. When played at the same tempo and on the same instrument, these songs differ from each other only in melody (the specific musical pitches and their sequence). A song selected at random from among these 4 songs was presented to each subject, and the subject was required to give a title. No feedback was given for the response. A total of 10 presentations were made by playing each song on the electronic keyboard and taking great care to play each song at the same tempo and rhythm. It was not difficult to reproduce the same tempo and rhythm each time, because the songs are short and the rhythm is simple.

Distinguishing Musical Intervals. To determine subjects' thresholds for distinguishing musical intervals, we presented each subject with 60 pairs of tones played on the keyboard in piano mode. Ten pairs of



Fig 1. Melodies with same rhythmic cues and narrow pitch range. Four melodies familiar to Japanese subjects and with identical rhythms and narrow pitch ranges in initial 4 measures were presented at same tempo. Some songs were transposed from original key of song, so that all 4 songs would be in same pitch range for this task.

tones were played for each interval of 2, 4, 6, 8, 10, and 12 semitones, in the range from 123 to 494 Hz, and subjects were required to indicate which tone of the pair was the higher in pitch. A computer program written by the first author was used to present the interval pairs so that the higher in pitch of the pair came first or last randomly, all the tones in the range of pitches were used equally often (or as closely as possible), and subjects were presented with an equal number of each interval pair. In addition, because some pitches may sound louder than others, the volume of each tone was varied randomly each time to avoid subjects' associating the loudness of the sound with its pitch.

Distinguishing Which Musical Instrument Is Being Played. We also tested each subject's ability to perceive, by the instrument's timbre, which of 5 instruments was being simulated on the keyboard. We selected piano, banjo, violin, harp, and trumpet for testing, and we presented octave scales in the same pitch range for each instrument. We found that initially subjects could not tell which instrument was being simulated, even if they had listened to the instrument before their loss of hearing. Therefore, before the actual experiment we taught them to recognize the simulated sounds of these 5 instruments by repeatedly playing scales in that instrumental mode and telling them the name of the instrument being played. Testing began only after each subject voiced confidence in his or her ability to distinguish among the instruments. Each subject was presented with 10 scales played in 1 of the 5 instrumental modes. Instrument modes were chosen randomly, and the volume was changed each time a scale was presented so that the subject would not be able to associate timbre and loudness. Subjects were required to name an instrument on each trial.

RESULTS

Recognition of Nursery Songs. Subjects could recognize an average of 3.9 nursery songs (range 0 to 9 songs) in an open set and an average of 5.3 nursery songs (range 1 to 10 songs) in a closed set of songs presented with vocal and instrumental accompaniment. Six of the 8 subjects were able to correctly identify more than 3 of 10 songs in a closed set — significantly more than would occur by chance ($p < .05$). That is, the probability of answering correctly 4 times in 10 trials if the subject responds randomly is $_{10}C_4 (1/10)^4(9/10)^6$ where $_{10}C_4$ (=210) is the number of combinations to choose 4 correct answers out of 10. The probability of obtaining more than 3 correct answers in 10 trials is $_{10}C_4(1/10)^4(9/10)^6 + {}_{10}C_5 (1/10)^5(9/10)^5 + \ldots + {}_{10}C_{10}(1/10)^{10}(9/10)^0 = .0128$ ($< .05$). The subjects who scored well on nursery song recognition included the 2 who had musical training, and the best score was achieved by the single subject whose cochlear implant used SPEAK coding strategy with a SPECTRA 22 sound processor. Those who correctly identified more songs reported in the interview that they recognized the songs on the test mostly by the words.

When the melody line only of nursery songs was presented on the keyboard, subjects' recognition scores fell considerably. The average number of correct answers was 1.7 of 10 (range 0 to 4) songs in an open set, and 2.1 of 10 (range 0 to 7) songs in a closed set. The 2 subjects who had musical training recognized significantly more songs than would occur by chance ($p < .05$), whereas the others did not. (See previous paragraph for calculation.) Most subjects reported that this task was harder than the first task (recognizing songs with vocal and musical accompaniment), although 1 subject reported that it was easier for him to follow the melody lines because of their simplicity.

Distinguishing Among Nursery Songs With Same Rhythm and Pitch Range. Figure 2 shows the results of subjects' attempts to discriminate among the melody lines of 4 rhythmically identical nursery songs played at the same tempo. Subjects would be expected to match the 4 songs with their titles by chance alone an average of 25% of the time (average of 2.5 correct answers in 10 trials). The distribution of responses in Fig 2 is consistent with chance responding, and in fact, the subjects reported in the interview that they were unable to discriminate among the 4 rhythmically identical songs.

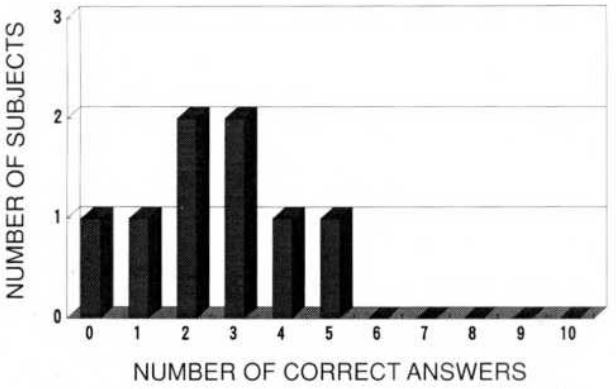

Fig 2. Ability of 8 subjects to recognize 4 rhythmically identical songs. For each trial, 1 of 4 songs was presented at random. Each subject underwent 10 trials and would average 2.5 correct answers by chance alone (no ability to distinguish which song was played). Distribution of results is consistent with chance, meaning that subjects could not distinguish among 4 songs.

Distinguishing Musical Intervals. The results of testing each subject's ability to distinguish tone intervals were graphed, and the results for 2 subjects are shown in Fig 3. Because the possibility that a subject would give a correct answer in 8 or more of 10 trials by random guessing is almost 5% ($_{10}C_8(1/2)^8(1/2)^2 + {}_{10}C_9(1/2)^9(1/2)^1 + {}_{10}C_{10}(1/2)^{10}(1/2)^0 = .547$), we defined the threshold for musical interval discrimination to be the smallest interval for which the subject gave at least 80% correct answers on trials of that interval and trials of all wider intervals. In Fig 3, by this definition, subject A's threshold for interval discrimination was 8 semitones and subject B had a threshold of more than 12 semitones.

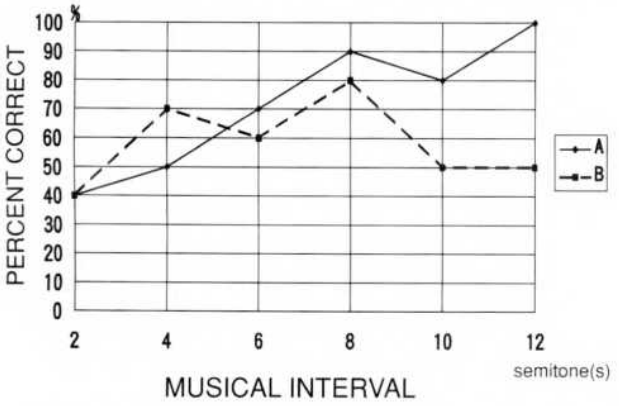

Fig 3. Protocol to determine each subject's threshold for distinguishing musical intervals. Ten pairs of simulated piano tones ranging over 2 octaves (fundamental frequencies between 123 and 494 Hz) were presented for each of 6 intervals (2, 4, 6, 8, 10, or 12 semitones apart). Because possibility of subject's achieving 8 or more correct answers in 10 trials is 5% if subject answers randomly, we defined threshold for interval discrimination to be smallest tone interval at and above which subject always scored 80% or better correct responses. With this definition, subject A's threshold for interval discrimination was 8 semitones and subject B's threshold was more than 12 semitones.

Figure 4 summarizes the interval discrimination thresholds for all subjects. On the basis of these results, subjects fell into 2 groups: the 5 who could distinguish musical intervals with greater (4 semitones) or lesser (10 semitones) precision and the 3 who could not distinguish intervals even of 12 semitones (a full octave) apart. Understanding the concept of musical pitch (higher or lower tones) was a prerequisite for participation in the study, so we are confident that the 5 subjects who discriminated intervals 4 to 10 semitones apart were in fact recognizing higher or lower pitches. The 3 who could not distinguish intervals stated in their interview that they had difficulty ranking musical pitches because the sound qualities of the 2 tones were too different to be able to compare them. One of these 3 subjects was the woman whose cochlear implant used SPEAK coding and who had a good ability to recognize songs with vocal and instrumental accompaniment.

Distinguishing Which Musical Instrument Is Being Played. Subjects correctly identified which of 5 musical instruments was being simulated an average of 5.6 (range 3 to 8) times in 10 trials. All subjects except 1 answered correctly 5 or more times in the 10 trials — considerably more than would be expected by chance alone ($p = {}_{10}C_5(1/5)^5(4/5)^5 + {}_{10}C_6(1/5)^6(4/5)^4 + \ldots + {}_{10}C_{10}(1/5)^{10}(4/5)^0 = .0328; < .05$). Although the experimental setting was the first time that subjects had listened to some of the musical instruments simulated using their cochlear implants, they reported in interviews that they found it easy to learn to distinguish the instruments by their timbres, even though the timbres heard with the cochlear implants were different from those they had

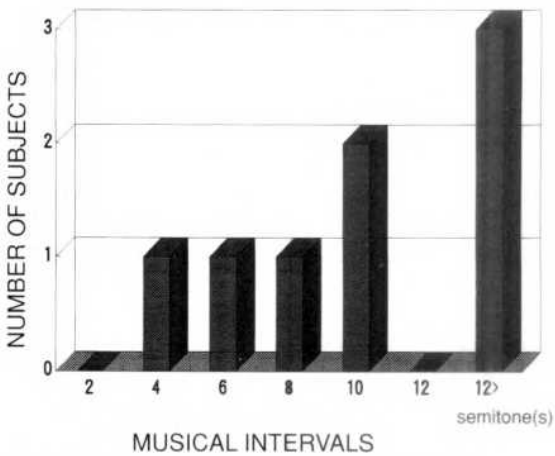

Fig 4. Distribution of thresholds for distinguishing musical intervals. Although subject with best ability to discriminate musical intervals could identify higher of 2 pitches 4 semitones (major third) apart, some subjects could not distinguish which pitch was higher even when tones were 12 semitones (octave) apart.

heard before their loss of hearing.

DISCUSSION

Some subjects had a good ability to recognize songs with vocal and instrumental accompaniment but had difficulty recognizing songs when the melody line only was played on a keyboard, without words. The results of testing indicated that subjects recognized songs using a combination of cues, including pitch, rhythm, and tempo, but mostly verbal information. The interviews with subjects reinforced the importance of verbal clues in recognizing songs.

The fact that musically trained subjects were better able to recognize nursery songs both with and without vocal elements indicates that they used their experience to extract maximal information from fragmentary musical evidence. These results are supported by a previous report that a musically trained subject with a multichannel cochlear implant was able to recognize melodies played on various musical instruments but that subjects without such training could not.[5]

The fact that individuals with cochlear implants using the SPEAK coding strategy are better able than those whose implants use the MPEAK coding strategy to hear speech in noisy environment[6] may explain the finding in our study that the subject with a SPEAK-strategy cochlear implant had the best ability to recognize songs with vocal and instrumental accompaniment. Nevertheless, most subjects in the study seemed to recognize familiar, simple songs by extracting the words from the complex sounds that were presented. Therefore, it is likely that if songs with unfamiliar or unclear words, such as opera or popular music, had been presented, subjects would have had much lower song recognition scores.

Discrimination of Songs With Same Rhythm and Pitch Range. The subjects in our study could not distinguish among familiar songs that had the same rhythm and pitch range, although subjects with cochlear implants in previous studies could make this distinction.[1-3] This discrepancy may be due in large part to the fact that the stimulation modes used in our study differed from those used previously. Whereas others stimulated the cochlear implant directly by applying tone frequencies through a single monopolar or a single bipolar electrode, we presented musical sounds that were picked up by the subject's sound processor and transformed to electrical stimuli delivered through multiple electrodes. Individuals with Nucleus cochlear implants can obtain information about pitch in 2 ways: 1) electrical stimulation of areas of the cochlea corresponding to frequencies of formants in MPEAK or maxima in SPEAK and 2) the rate of stimulation of electrodes in MPEAK. It is reasonable to presume that recognizing pitches coded by stimulation of multiple electrodes, as occurred in our study, would be more confusing than recognizing pitches coded by stimulation of a single monopolar or a single bipolar electrode, because electrical stimulation of each pair of multiple electrodes elicits a different-quality sound sensation. The results of a previous study[5] tend to confirm that subjects with cochlear implants have poor ability to detect pitch; in this study, individuals with multichannel cochlear implants (Nucleus or Ineraid) performed less well on a tone discrimination subtest than on a rhythmic subtest of a standardized test of musical perception.

Threshold for Discrimination of Musical Intervals. The ability of subjects in our study to discriminate musical intervals was very poor — the best threshold of discrimination was only 4 semitones (a major third), and 3 of the 8 subjects could not differentiate 2 tones as much as 12 semitones (an octave) apart. This poor pitch discrimination ability helps to explain why it was so difficult for the subjects in our study to discriminate among melody lines of nursery songs presented without verbal cues.

Studies conducted in normal-hearing subjects showed much more sensitive frequency discrimination, although the discrimination threshold depended on the signal intensity and frequency and the stimulation method used.[7-9] For example, normal-hearing subjects could discriminate a pair of pure tones 1.0 Hz apart when presented at 200 to 400 Hz at 40 dB SPL,[9] equivalent to 0.04 to 0.09 semitones. In contrast to these results in normal-hearing individuals, the frequency allocation of electrodes used in cochlear implants is very rough, as shown in Table 2. As a result of the wide range of pitches assigned to a small number of electrodes, pitch discrimination based on "place pitch" stimulation through a given electrode must necessarily be too imprecise to permit recognition of musical intervals.

Previous reports noted that changing the pulse rate on a single monopolar or a single bipolar electrode of a cochlear implant could result in the perception of a change in pitch, although wide intersubject variability was found — the saturation point above which the pitch sensation did not change ranged from 200 to 1,000 pulses per second.[10-12] Such variability in pitch recognition when stimuli are applied through a single monopolar or a single bipolar electrode and the confusion arising from stimulation via multiple electrodes may explain the variability noted in our study in the threshold for discriminating musical intervals.

TABLE 2. ONE EXAMPLE OF HOW UPPER FREQUENCY MAY BE ASSIGNED TO EACH ELECTRODE PAIR

Electrode Pair No.	*Upper Frequency (Hz)*
20	400
19	500
18	600
17	700
16	800
15	900
14	1,000
13	1,112
12	1,237
11	1,377
10	1,531
9	1,704
8	1,896
7	2,109
6	2,346
5	2,611
4	2,904
3	3,231
2	3,595
1	4,000

In this example, even though all 22 electrodes are usable and every second electrode is selected to form pair, frequency range allocated to each electrode pair is too wide to permit recognition of musical intervals on basis of "place pitch."

The only subject in our study whose cochlear implant used a SPEAK coding strategy showed the best ability of all 8 subjects to recognize songs with vocal and instrumental accompaniment and also demonstrated the poorest ability to recognize musical intervals. These findings may be accounted for by 2 changes in coding strategy implemented with SPEAK[13]: 1) stimulation through electrodes at a rate of about 250 Hz instead of at variable rates coupled to a fundamental frequency (glottal pitch) and 2) widening of the frequency range allocated to electrodes from 4,000 to 10,000 Hz.

Recognition of Timbre. The fact that subjects in our study could correctly recognize various instruments indicates that the cochlear implant system can produce a variety of (recognizable) stimuli that correspond to the timbres of various musical instruments. Each musical instrument has its own specific sound spectrographic pattern (Fig 5A), as does each vowel (Fig 5B), and cochlear implants are designed to use the spectrographic patterns of sounds, including formants and maxima, to code sounds. Individuals using cochlear implants learn to understand speech by distinguishing slight differences in the spectrographic patterns of phonemes, and we presume that subjects in this study were able to distinguish among various musical instruments in the same way. However, as shown in this and in a previous study,[5] individuals with cochlear implants cannot identify musical instruments by their "voices" unless they are given the opportunity to learn what various instruments sound like when their timbres are coded by the cochlear implant. Clearly, the timbres of musical instruments heard with a cochlear implant differ from the natural timbres of instruments, so in this regard, implant systems fail to transmit the sound qualities of musical instruments.

Effectiveness of MPEAK and SPEAK Coding Strategies. Although it is impossible for a cochlear implant device to transmit as much information to the central nervous system as a normal cochlea would, coding strategies such as MPEAK and SPEAK have been designed to extract and transmit those features of sound that are key to understanding human speech. The Nucleus cochlear implant system is so effective that some subjects in our study could recognize nursery songs by identifying the words of songs when

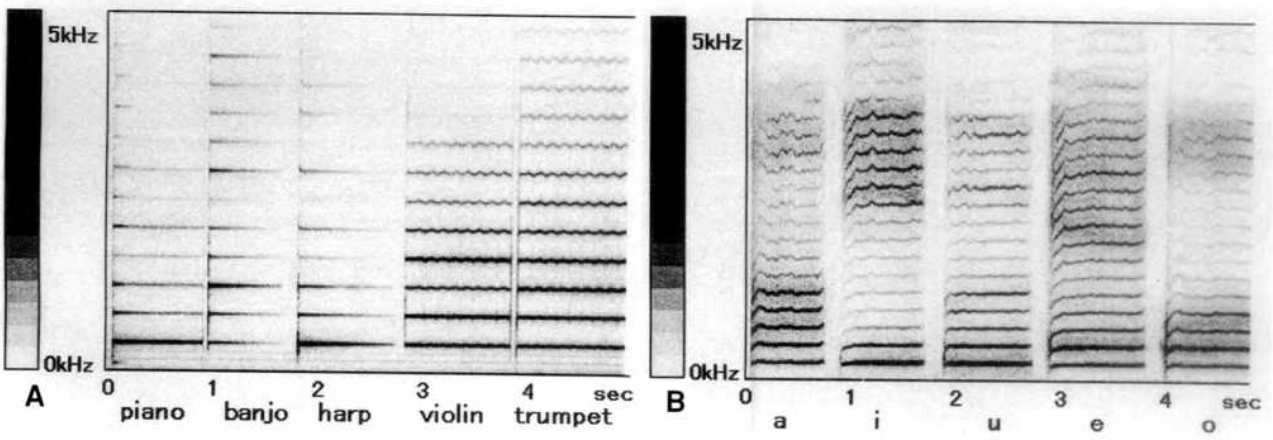

Fig 5. Sound spectrograms of A) 5 musical instruments simulated on electronic keyboard and B) 5 Japanese vowels. Each instrument has its own specific pattern of intense frequency regions, similar to formants in vowels, that are used by Nucleus cochlear implant to code sound.

presented in musical rhythm and pitch and with instrumental accompaniment — a complex task. The SPEAK coding system has been shown to provide better recognition of speech compared to the MPEAK coding system,[6] and the subject in our study with a cochlear implant that used the SPEAK coding strategy had the best ability to recognize nursery songs when presented with verbal cues. Nevertheless, this subject had no better ability to recognize pitches than did subjects with implants that used the MPEAK strategy. It thus appears that progress in providing for better recognition of speech does not necessarily contribute to enhanced ability to recognize nonverbal sounds such as music.

CONCLUSION

The results of this study show that the cochlear implant devices that are currently available have strengths and weaknesses. All subjects could easily learn to recognize timbres of various musical instruments, and they showed good ability to recognize familiar nursery songs. However, they had poor ability to discriminate musical intervals, as indicated by results of testing their ability to distinguish 4 nursery songs with the same rhythm played on a keyboard at the same tempo and by the results of testing musical interval discrimination directly. In fact, post-testing interviews confirmed that subjects recognized nursery songs mostly from verbal cues rather than by musical qualities such as tones and intervals. We hope that these findings regarding the music recognition ability of subjects with Nucleus cochlear implants will contribute to the design of future models of such devices.

REFERENCES

1. Eddington DK, Dobelle WH, Brackmann DE, Mladejovsky MG, Parkin J. Place and periodicity pitch by stimulation of multiple scala tympani electrodes in deaf volunteers. Trans Am Soc Artif Intern Organs 1978;24:1-5.

2. Eddington DK, Dobelle WH, Brackmann DE, Mladejovsky MG, Parkin JL. Auditory prostheses research with multiple channel intracochlear stimulation in man. Ann Otol Rhinol Laryngol Suppl 1978;87(suppl 53).

3. Pijl S, Schwarz DWF. Melody recognition and musical interval perception by deaf subjects stimulated with electrical pulse trains through single cochlear electrodes. J Acoust Soc Am 1995;98:886-95.

4. Pijl S, Schwarz DWF. Intonation of musical intervals by deaf subjects stimulated with single bipolar cochlear implant electrodes. Hear Res 1995;89:203-11.

5. Gfeller K, Lansing CR. Melodic, rhythmic, and timbral perception of adult cochlear implant users. J Speech Hear Res 1991;34:916-20.

6. Skinner MW, Clark GM, Whitford LA, et al. Evaluation of a new spectral peak coding strategy for the Nucleus 22 channel cochlear implant system. Am J Otol 1994;15(suppl 2):15-27.

7. Shower EG, Biddulph R. Differential pitch sensitivity of the ear. J Acoust Soc Am 1931;3:275-87.

8. Henning GB. Frequency discrimination of random-amplitude tones. J Acoust Soc Am 1966;39:336-9.

9. Wier CC, Jesteadt W, Green DM. Frequency discrimination as a function of frequency and sensation level. J Acoust Soc Am 1977;61:178-84.

10. Tong YC, Clark GM. Absolute identification of electric pulse rates and electrode positions by cochlear implant patients. J Acoust Soc Am 1985;77:1881-8.

11. Townshend B, Cotter N, Compernolle DV, White RL. Pitch perception by cochlear implant subjects. J Acoust Soc Am 1987;82:106-15.

12. Blamey PJ, Parisi ES, Clark GM. Pitch matching of electric and acoustic stimuli. Ann Otol Rhinol Laryngol Suppl 1995; 104(suppl 166):220-2.

13. Seligman P, McDermott H. Architecture of the Spectra 22 speech processor. Ann Otol Rhinol Laryngol Suppl 1995;104 (suppl 166):139-41.

OBJECTIVE EVALUATION OF NORMAL FACIAL FUNCTION

HENNING SCRIBA, PHD

SANDRO J. STOECKLI, MD
ANITA POLLAK, MD
DOROTHE VERAGUTH, MD
UGO FISCH, MD

ZURICH, SWITZERLAND

The aim of this investigation was the assessment of normal facial movements using the objective computer-assisted OSCAR method. Computerized black-and-white video images of 20 healthy volunteers were recorded with the face at rest, maximal wrinkling of the forehead, forced eye closure, and forced smiling. The mean regional symmetry index was found to be 91% (SD 6%; range 80% to 99%) for wrinkling of the forehead, 93% (SD 5%; range 82% to 100%) for forced eye closure, and 91% (SD 5%; range 79% to 98%) for maximal smiling. Clinical weighting gave a global symmetry index of 92% (SD 3%; range 88% to 96%). The presented results show that the physiological dynamic asymmetry of the normal face is 7% to 9%. No dominant facial side could be found. The comparison of the results obtained with the OSCAR method with those of the subjective House-Brackmann and Fisch grading systems showed that the physiological asymmetry of facial movements can only be accurately determined with a computer-assisted objective method.

KEY WORDS — facial asymmetry, normal facial function, objective scaling.

INTRODUCTION

Every objective or subjective scaling system assessing facial motor function compares pathological to presumed normal facial movements. The most commonly used subjective grading system is the House-Brackmann[1,2] (HB) classification. The observer attributes his or her subjective visual impression to 1 of 6 different grades. However, attribution to 1 HB grade may be difficult due to different degrees of motion in the upper and lower parts of the face. The Fisch[3,4] classification evaluates the resting tone and 4 major facial movements separately. The final percent grade is calculated by adding the weighted regional values to a maximum score of 100%, indicating normality. Subjective facial grading systems have been reported by others such as Yanagihara[5] and Stennert.[6] The aim of this investigation was to determine the physiological range of dynamic facial asymmetry in normal subjects by means of the previously described objective OSCAR method[7-10] (objective scaling of facial nerve function based on area analysis). The results are compared with data obtained by the HB and Fisch subjective grading systems.

MATERIALS AND METHODS

Computerized black-and-white video recordings were performed with the OSCAR system in 20 healthy volunteers (ages between 25 and 65 years; mean 39 years; 9 men, 11 women). In each subject, 5 series of static video images were recorded with the face at rest, maximal wrinkling of the forehead, forced eye closure, and maximal smiling. A cephalostat[7,8] was used to stabilize the subject's head relative to the video camera. The recording of 1 subject took about 20 minutes. The 3 technically best series were evaluated. For each movement, the image of the corresponding facial area was digitally subtracted from the image at rest and the change of luminance was calculated. The augmented perioral luminance during smiling is shown in the Figure as white ar-

Subtracted picture of smiling face with perioral augmented luminance.

From the Department of Dentofacial Orthopedics, University of Zurich (Scriba), and the Clinic of Otorhinolaryngology–Head and Neck Surgery, University Hospital Zurich (Stoeckli, Veraguth, Pollak, Fisch), Zurich, Switzerland.

CORRESPONDENCE — Henning Scriba, PhD, Zahnmedizinisches Zentrum, Plattenstrasse 11, CH-8028 Zurich, Switzerland.

TABLE 1. SYMMETRY INDICES

Symmetry Index	Poses of Face	Symmetry (%) Mean ± SD	Range
Regional	Smiling	91 ± 5	79-98
	Eye closure	93 ± 5	82-100
	Forehead wrinkling	91 ± 6	80-99
Global	Smiling (40%) + eye closure (40%) + forehead wrinkling (20%)	92 ± 3	88-96

TABLE 2. LEFT-RIGHT SYMMETRY INDICES

Left-Right Index	Poses of Face	Symmetry (%) Mean ± SD	Range
Regional	Smiling	101 ± 12	82-126
	Eye closure	101 ± 10	82-121
	Forehead wrinkling	100 ± 11	83-120
Global	Smiling (40%) + eye closure (40%) + forehead wrinkling (20%)	101 ± 8	88-112

eas. This off-line analysis took about 15 minutes. A regional symmetry index (RSI) was determined for each facial area as the percentage of change in luminance of the "weaker" side versus the "better" side, taking the latter as 100%. Thus, the RSI is always ≤100%.

For clinical evaluation, a global symmetry index (GSI) was derived, which represents the facial symmetry of each subject in 1 number. To calculate this parameter, the RSIs of the clinically more important eye and mouth movements were multiplied by 0.4 and the RSI of the forehead by 0.2 before summing.[10] The result is a GSI with a maximum of 100%, in which a weakness of the forehead contributes less to a bad result than a weakness of the mouth or the eye. Note that for calculating the GSI, the weaker region may not be consistently on the same side for each part of the face. Additionally, a left-right index (LRI) was calculated by adding the changes of luminance of all 3 facial areas during maximal movement on the left side and relating it to the sum of the changes on the right side, taking the latter as 100%. Thus an LRI of >100% is possible, and would indicate stronger movements on the left side. Video images of all recorded facial movements were used for clinical grading according to the HB and Fisch classifications by 7 independent and experienced observers.

RESULTS

Comparison Between Stronger and Weaker Facial Sides. The computerized assessment of the 3 facial poses in 20 normal subjects revealed a mean symmetry between 91% and 93% (Table 1). The lowest values of RSI found in 3 different subjects were 79% for the mouth, 82% for the eye, and 80% for the forehead movements.

The mean GSI representing a weighted average of smiling, eye closure, and wrinkling of the forehead was 92%, with a range between 88% and 96% (Table 1).

Comparison Between Left and Right Sides of Face. The stronger side of the face varied from one region to the other in 12 subjects. Stronger movements were found on the same side of the face for all 3 regions in 8 cases. In 5 of these cases, the stronger side was on the left, and in 3, it was on the right. Taking the right side as 100%, the mean LRI was 101% ± 8% (Table 2). This means that there was no significant dominance of one side of the face.

Comparison With Subjective House-Brackmann and Fisch Grading Systems. Video prints of the same 20 subjects were clinically assessed by 7 observers using the HB and Fisch grading criteria. Only 11 of 20 subjects were classified as HB grade I. Four of the 7 observers attributed an HB grade II to 9 subjects because of an asymmetry of the mouth when smiling. Because the HB grading system does not allow averaging, the subjects had to be classified according to the majority decision. Both groups with either HB grade I or II showed a similar range of GSI values between 88% and 96%.

The Fisch classification allows averaging of the percent grades given to the same subject by different observers. All subjects classified as HB grade II also had Fisch grades of less than 100%. The lowest value of 92% was given to 3 subjects. Subjects with Fisch grades of 100% (ie, "normal" facial movements) had a similar range of GSI as subjects with lower Fisch grades.

DISCUSSION

Facial grading systems are used to evaluate patients with facial palsy. All subjective grading systems depend on the perception of an observer. Therefore, the results are difficult to compare. Several groups have developed objective grading systems to eliminate interobserver differences. Most of these objective systems are based on computerized linear measurements.[11-15] However, evaluation of area changes in the moving face is more comprehensive than the analysis of linear displacements. Therefore, a computerized objective scaling system based on luminance variations of the skin in the face during change of facial expression was developed in this department in 1992.[7-10] Independently, in the same year, a similar system was proposed by Neely et al.[16]

Every scaling system of facial motor function com-

pares pathological to presumed normal movements. In the subjective HB and Fisch grading systems, normality is defined as complete symmetry of facial movements (grade I and 100%, respectively). Although it is well known from psychological studies[17-19] that the human face is never 100% symmetric, the range of physiological, dynamic facial asymmetry still remains to be defined.

The measurements obtained with the objective OSCAR method for the examined poses of the face (smiling, eye closure, forehead wrinkling) have resulted in a mean RSI of 91% to 93% and a GSI of 92% for the normal human face. This means that the mean physiological asymmetry of facial motor function is 7% to 9% (range 0% to 21%).

Burres[11] analyzed facial motor function in 30 healthy subjects using linear distance measurements and found a mean global facial asymmetry of 6.4% ±4.5% (no range is given). Kuzon et al[15] also evaluated normal facial movements with linear measurements. From their results, a global facial asymmetry of 3% to 14% can be extrapolated. In a further study, Isono et al[14] made a computerized analysis of the displacement of white marks attached to normal faces. During forced eye closure, the measured asymmetry was 3% to 16%. Yuen et al[20] examined the facial movements of normal volunteers using moiré topography.[21] Although 3 facial areas were assessed, only the asymmetry of the mouth region could be calculated and was between 0% and 10%. All these results are in good agreement with our measurements and confirm the fact that the definition of normal facial function in the HB and Fisch grading systems should comprise asymmetries of up to 10%.

In subjective grading systems, normality is defined as 100% symmetry. The evaluation of normal facial movements in our study revealed 100% symmetry (ie, HB grade I and Fisch 100%) in only 55% of the cases. These 2 groups could not be distinguished by the objective OSCAR method. This raises the question whether normality should not also include HB grade II, with only slight asymmetry, and Fisch grades of 90% to 99%. The mean LRI demonstrated that no significant difference was measurable between the sides of the face. In contrast to a dominant cerebral hemisphere and a dominant hand, there is no dominant side of the face.

CONCLUSIONS

The objective analysis of normal facial movements resulted in the presence of a mean asymmetry of 8%, with a maximum dynamic asymmetry of about 20% for a single region of the face. The computerized OSCAR method is able to measure small physiological asymmetries. Subjective grading systems like the HB and Fisch show difficulties in evaluating subtle differences.

ACKNOWLEDGMENTS — The authors thank Heidi Felix, MD, Andreas Böhmer, MD, and Thomas Linder, MD, for helping to analyze the video prints according to the House-Brackmann and Fisch grading systems and are grateful for their discussions and suggestions.

REFERENCES

1. House JW. Facial nerve grading systems. Laryngoscope 1983;93:1056-69.

2. House JW, Brackmann DE. Facial nerve grading system. Otolaryngol Head Neck Surg 1985;93:146-7.

3. Rickenmann J, Jaquenod C, Cerenko D, Fisch U. Comparative value of facial nerve grading systems. Otolaryngol Head Neck Surg 1997;117:322-5.

4. Fisch U. Surgery for Bell's palsy. Arch Otolaryngol 1981; 107:1-11.

5. Yanagihara N. Classification and standardized documentation of surgical results. In: Fisch U, ed. Facial nerve surgery. Proceedings of the Third International Symposium on Facial Nerve Surgery, Zurich, Switzerland, 1976. Amsterdam, the Netherlands: Kugler Medical Publishers, 1977:533-6.

6. Stennert E. Facial nerve paralysis scoring system. In: Fisch U, ed. Facial nerve surgery. Proceedings of the Third International Symposium on Facial Nerve Surgery, Zurich, Switzerland, 1976. Amsterdam, the Netherlands: Kugler Medical Publishers, 1977:543-7.

7. Gallati V, Scriba H. Computer assisted facial nerve grading. In: Samij MS, ed. Skull base surgery. 1st International Skull Base Congress, Hannover, 1992. Munich, Germany: Karger, 1994:1211-3.

8. Gallati V, Scriba H. Computer analysis of facial movements. In: Proceedings of the VII International Symposium on the Facial Nerve, Köln, 1992. Eur Arch Otorhinolaryngol Suppl 1994(suppl):187-8.

9. Scriba H, Meier-Gallati V, Pollak A, Scherler M, Fisch U. Objective evaluation of facial function. In: Proceedings of the 4th International Muscle Symposium, Zurich, Switzerland, 1995:172-4.

10. Meier-Gallati V, Scriba H, Fisch U. Objective scaling of facial nerve function based on area analysis (OSCAR). Otolaryngol Head Neck Surg 1998;118:545-50.

11. Burres SA. Facial biomechanics: the standards of normal. Laryngoscope 1985;95:708-14.

12. Burres S, Fisch U. The comparison of facial grading systems. Arch Otolaryngol Head Neck Surg 1986;112:755-8.

13. Frey M, Jenny A, Giovanoli P, Stüssi E. Development of a new documentation system for facial movements as a basis for the international registry for neuromuscular reconstruction in the face. Plast Reconstr Surg 1994;93:1334-49.

14. Isono M, Murata K, Tanaka H, Kawamoto M, Azuma H. An objective evaluation method for facial mimic motion. Otolaryngol Head Neck Surg 1996;114:27-31.

15. Kuzon WM, Marcus JR, Johnson PJ. A comparison of methods for the quantification of facial movements. In: Proceedings of the 4th International Muscle Symposium, Zurich,

Switzerland, 1995:179-81.

16. Neely JG, Cheung JY, Wood M, Byers J, Rogerson A. Computerized quantitative dynamic analysis of facial motion in the paralyzed and synkinetic face. Am J Otol 1992;13:97-107.

17. Skinner M, Mullen B. Facial asymmetry in emotional expression: a meta-analysis of research. Br J Soc Psychol 1991; 30:113-24.

18. Sackeim HA. Morphologic asymmetries of the face: a review. Brain Cogn 1985;4:296-312.

19. Kowner R. Facial asymmetry and attractiveness judgement in developmental perspective. J Exp Psychol Hum Percept Perform 1996;22:662-75.

20. Yuen K, Inokuchi I, Maeta M, Kawakami S, Masuda Y. Evaluation of facial palsy by moiré topography index. Otolaryngol Head Neck Surg 1997;117:567-72.

21. Takasaki H. Moiré topography. Appl Optics 1970;9: 1467-72.

≈

PHONOSURGERY

The European Laryngological Society's Workshop 1999: Phonosurgery will be held, in English, October 9-10, 1999, in Graz, Austria. For more information, contact Prof Dr G. Friedrich, Department of ENT, University of Graz, Medical School, Auenbruggerplatz 20, Graz, Austria; telephone ++43/316/385-2579; fax ++43/316/385-3549; e-mail gerhard.friedrich@kfunigraz.ac.at.

RESISTANCE TO ANTIMICROBIALS USED FOR THERAPY OF OTITIS MEDIA AND SINUSITIS: EFFECT OF PREVIOUS ANTIMICROBIAL THERAPY AND SMOKING

ITZHAK BROOK, MD, MSc
CHEVY CHASE, MARYLAND

ALAN E. GOBER, MD
WASHINGTON, DC

We undertook to identify the antimicrobial susceptibility of the pathogens isolated from patients with otitis media or maxillary sinusitis who failed to respond to antimicrobial therapy, and correlate it with previous antimicrobial therapy and smoking. We analyzed isolates recovered from 2 consecutive cultures obtained from middle ear aspirate obtained through an open perforation in 22 children with otitis, and maxillary sinus aspirate collected by endoscopy from 20 patients. Forty-seven isolates were repeatedly recovered from 42 culture-positive individuals. The organisms isolated were *Streptococcus pneumoniae* (15 isolates), *Haemophilus influenzae* (14), *Staphylococcus aureus* (7), *Moraxella catarrhalis* (6), and *Streptococcus pyogenes* (5). Resistance of at least 2 tube dilutions to the antimicrobial agents used was found in 23 of the 47 (49%) isolates that were found in 20 (48%) of the patients. These included 10 of 15 (67%) isolates of *S pneumoniae*, 4 of 14 (29%) *H influenzae* (all were β-lactamase producers), 4 of 7 (57%) *S aureus* (all β-lactamase producers), 5 of 6 (83%) *M catarrhalis* (all β-lactamase producers), and none of 5 *S pyogenes*. In the 21 patients who failed to respond to amoxicillin, *H influenzae* and *S pneumoniae* predominated. *Streptococcus pneumoniae* was recovered from 4 of the 11 (36%) after trimethoprim-sulfamethoxazole, 4 of 21 (19%) after amoxicillin, 2 of 3 (67%) after azithromycin dihydrate, and 1 of 4 (25%) after cefixime. A statistically significant higher recovery of resistant organisms was noted in those treated 2 to 6 months previously, and in those with sinusitis who smoked. The data illustrate the relationship between resistance to antimicrobials and failure of patients with otitis media and sinusitis to improve.

KEY WORDS — antimicrobials, *Haemophilus influenzae, Moraxella catarrhalis*, otitis media, sinusitis, smoking, *Streptococcus pneumoniae*.

INTRODUCTION

The growing resistance to antimicrobial agents of all respiratory tract bacterial pathogens has made the management of otitis media and sinusitis more difficult. Failure of antimicrobials to clear the infection can be due to the persistence of pathogen(s) that are resistant to the antimicrobial used.[1-7] Resistance to antimicrobials may develop as a result of recent antibiotic therapy.

This study reports the authors' recent experience in evaluating the antimicrobial susceptibility of organisms isolated from the middle ear and maxillary sinus of patients who experienced a persistent or unresponsive infection. A correlation was made between past antimicrobial therapy and exposure to smoking.

PATIENTS AND METHODS

The patients were seen in the outpatient clinic between September 1990 and August 1997. Patients included in the study were those who 1) complied with the antimicrobial therapy but failed to respond to the initial empiric antimicrobial therapy, 2) had persistent infection, and 3) were followed up by 1 repeated aspirate. The repeated aspirate was performed 5 to 10 (average 6.4) days after therapy was started. An isolate similar to one recovered in the initial culture had to be present in the repeated culture. None had had ear or sinus infection for at least 3 months before their initial visit, and they had not received antimicrobial therapy for at least 2 months. Antimicrobial dosages were those recommended by the manufacturer, and were chosen according to the patients' needs. Compliance with administration of antimicrobials was evaluated in all instances by examining the unused amount of medication. Past medical history, past antimicrobial therapy (2 to 6 months previously), and active or passive exposure to smoking (more than 2 cigarettes per day) was correlated with the microbiological finding.

Otitis Media. Twenty-two children with otitis media were included. Their ages ranged from 3 to 16 years; 14 were boys. They had acute otitis media with spontaneous perforation that drained purulent fluid. They continued to have drainage through the nonresolving perforation despite antimicrobial therapy. Specimens were collected as previously described.[8]

Sinusitis. Twenty patients with acute maxillary sinusitis were studied. Their ages ranged from 17 to

From the Department of Pediatrics, Georgetown University School of Medicine, Washington, DC.
CORRESPONDENCE — Itzhak Brook, MD, MSc, PO Box 70412, Chevy Chase, MD 20813-0412.

INCREASE IN ANTIMICROBIAL RESISTANCE (AT LEAST TWO TUBE DILUTIONS) OF ORGANISMS ISOLATED FROM EAR AND SINUS ASPIRATES OF FORTY-TWO PATIENTS WHO FAILED ANTIMICROBIAL THERAPY

Preceding Antimicrobial	*No. of Patients*	Streptococcus pneumoniae	Haemophilus influenzae	Moraxella catarrhalis	Streptococcus pyogenes	Staphylococcus aureus	*Total Isolates*
Amoxicillin	21	4/6	2/8	4/4	0/2	2/3	12/23
Trimethoprim-sulfamethoxazole	11	3/4	2/3	1/2	0/2	1/3	7/14
Cefixime	4	1/2			0/1	1/1	2/4
Cefuroxime axetil	3	0/1	0/2				0/3
Azithromycin dihydrate	3	2/2	0/1				2/3
Total	42	10/15	4/14	5/6	0/5	4/7	23/47

Data are number of isolates in which resistance increased for at least 2 tubes per total number of isolates.

58 years; 11 were men. Specimens were obtained through endoscopy, and the sinus secretions were collected with calcium alginate–tipped microswabs. The methods of diagnosis of sinusitis and of specimen collection were those previously described.[9]

Microbiology. Specimens were inoculated onto aerobic and anaerobic media and processed as previously described.[8,9] If the same organism was isolated from both aspirates in a case of bilateral disease, it was considered a single isolate for that patient. All isolates were kept frozen at –70°C until their susceptibility was tested. Antimicrobial susceptibility of all isolates was done by microdilution using cation-supplemented Mueller-Hinton broth plus 5% lysed and centrifuged horse blood as recommended by the National Committee for Clinical Laboratory Standards.[10] β-Lactamase activity was determined on all isolates by the nitrocefin method.[11]

RESULTS

Forty-seven isolates were repeatedly recovered from 42 culture-positive individuals. The organisms isolated were *Streptococcus pneumoniae* (15 isolates), *Haemophilus influenzae* non–type b (14), *Staphylococcus aureus* (7), *Moraxella catarrhalis* (6), and *Streptococcus pyogenes* (5; see Table).

Resistance of at least 2 tube dilutions to the antimicrobial agents used was found in 23 of the 47 (49%) isolates that were found in 20 (48%) of the patients. These included 10 of 15 (67%) *S pneumoniae* isolates, 4 of 14 (29%) *H influenzae* (all were β-lactamase producers), 4 of 7 (57%) S *aureus* (all β-lactamase producers), 5 of 6 (83%) *M catarrhalis* (all β-lactamase producers), and none of 5 S *pyogenes*.

In the 21 patients who failed to respond to amoxicillin, *H influenzae* and *S pneumoniae* predominated (see Table). *Streptococcus pneumoniae* was recovered from 4 of the 11 (36%) patients who failed trimethoprim-sulfamethoxazole, 4 of 21 (19%) who failed amoxicillin, 2 of 3 (67%) who failed azithromycin dihydrate, and 1 of 4 (25%) who failed cefixime. *Haemophilus influenzae* was recovered from 2 of the 11 (18%) who failed trimethoprim-sulfamethoxazole, and 2 of 21 (9%) who failed amoxicillin.

A correlation between antimicrobial resistance and patients' medical history was noted in only 2 items. These included previous antimicrobial therapy in 16 of 24 (67%) treated, compared to 3 of 18 (17%) untreated patients ($p < .05$), and smoking in 8 of 11 (73%) with sinusitis compared to no smoking in 2 of 9 (22%).

DISCUSSION

These data illustrate the relationship between resistance to antimicrobials and failure to improve of patients with otitis media and sinusitis. These findings confirm previous reports in which such a relationship was found.[1-7] Harrison et al[2] illustrated a higher rate of isolation of *H influenzae* and *S aureus* in patients with recently treated or persistent otitis media compared to untreated acute otitis media. In contrast, Pichichero and Pichichero[6] showed a lower rate of recovery of resistant organisms from persistent otitis media.

The recovery in 20 (48%) of our patients of organisms that were susceptible to the antimicrobial used is similar to that reported by Pichichero and Pichichero[6] (42 of 137 or 31%). These findings suggest that factors other than antimicrobial susceptibility can contribute to persistent infection. These include the presence of a concomitant viral infection,[12] bioavailability of the antimicrobials, penetration into the middle ear and sinus fluid, and activity in the pus.

This study highlights the important role of antibiotic-resistant pathogens in the failure to eradicate otitis media and sinusitis. The growing resistance of *S pneumoniae* to penicillin and other antimicrobials such as trimethoprim-sulfamethoxazole and macrolides[13] and the production of β-lactamase by *H influenzae* and *M catarrhalis*[14] are the major causes of resistance. Selection of antimicrobial agents can be

improved by knowledge of the resistant pattern of the organisms in the community, by consideration of the effect of previous antimicrobial therapy[14] or prophylaxis[15] that may select resistant strains, and by selective use of tympanocentesis that can be both diagnostic and therapeutic.[16]

The correlation between the increased recovery rate of antimicrobial-resistant bacteria and previous antibiotic therapy has been previously described.[14,15] However, the association between smoking and increased antimicrobial resistance has not been previously described. Active and passive smoking has been shown to increase susceptibility to respiratory infection,[17,18] which may expose the patient to repeated courses of antimicrobials. Passive smoking increases the carriage of *H influenzae* and *S pneumoniae* in children.[19] Further studies are warranted to investigate the association between smoking and response to antimicrobial therapy.

ACKNOWLEDGMENT — The authors acknowledge the secretarial assistance of Sarah Blaisdell.

REFERENCES

1. Teele DW, Pelton SI, Klein JO. Bacteriology of acute otitis media unresponsive to initial antimicrobial therapy. J Pediatr 1981;98:537-9.

2. Harrison CJ, Marks MI, Welch DF. Microbiology of recently treated acute otitis media compared with previously untreated acute otitis media. Pediatr Infect Dis 1985;4:641-6.

3. Carlin SA, Marchant CD, Shurin PA, Johnson CE, Murdell-Panek D, Barenkamp SJ. Early recurrences of otitis media: reinfection or relapse? J Pediatr 1987;110:20-5.

4. Barenkamp SJ, Shurin PA, Marchant CD, et al. Do children with recurrent *Haemophilus influenzae* otitis media become infected with a new organism or reacquire the original strain? J Pediatr 1984;105:533-7.

5. Del Beccaro MA, Mendelman PM, Inglis AF, et al. Bacteriology of acute otitis media: a new perspective. J Pediatr 1992;120:81-4.

6. Pichichero ME, Pichichero CL. Persistent otitis media: I. Causative pathogen. Pediatr Infect Dis J 1995;14:178-83.

7. Brook I, Yocum P. Bacteriology and β-lactamase activity in ear aspirates of acute otitis media that failed amoxicillin therapy. Pediatr Infect Dis J 1995;14:805-7.

8. Brook I, Frazier EH. Microbial dynamics of persistent otitis media in children. J Pediatr 1996;128:237-40.

9. Brook I, Frazier EH, Foote PA. Microbiology of the transition from acute to chronic maxillary sinusitis. J Med Microbiol 1996;45:372-5.

10. National Committee for Clinical Laboratory Standards. Methods for dilution antimicrobial susceptibility tests for bacteria that grow aerobically. 4th ed. M7-A4. Villanova, Pa: National Committee for Clinical Laboratory Standards, 1995.

11. O'Callaghan DH, Morris A, Kirby SM, Shingler AH. Novel method for detection of beta-lactamase by using a chromogenic cephalosporin substrate. Antimicrob Agents Chemother 1972;1:283-8.

12. Chonmaitree T, Owen MJ, Patel JA, Hedgpeth D, Horlick D, Howie VM. Presence of cytomegalovirus and herpes simplex virus in middle ear fluids from children with acute otitis media. Clin Infect Dis 1992;15:650-3.

13. Ednie LM, Spangler SK, Jacobs MR, Appelbaum PC. Susceptibilities of 228 penicillin- and erythromycin-susceptible and -resistant pneumonococci to RU 64004, a new ketolide, compared with susceptibilities to 16 other agents. Antimicrob Agents Chemother 1997;41:1033-6.

14. Brook I, Gober AE. Emergence of beta-lactamase–producing aerobic and anaerobic bacteria in the oropharynx of children following penicillin chemotherapy. Clin Pediatr (Phila) 1984;23:338-41.

15. Brook I, Gober AE. Prophylaxis with amoxicillin or sulfisoxazole for otitis media: effect on the recovery of penicillin-resistant bacteria from children. Clin Infect Dis 1996;22:143-5.

16. Howie VM. Otitis media. Pediatr Rev 1993;14:320-3.

17. Marcy TW, Merril WW. Cigarette smoking and respiratory tract infection. Clin Chest Med 1987;8:381-91.

18. Chen Y, Li WX, Yu SZ, Qian C-N. Epidemiological study of children's health. I. Passive smoking and children's respiratory diseases. Int J Epidemiol 1988;17:348-55.

19. Sung RY, Ling JM, Fung SM, et al. Carriage of *Haemophilus influenzae* and *Streptococcus pneumoniae* in healthy Chinese and Vietnamese children in Hong Kong. Acta Paediatr 1995;84:1262-7.

EXPRESSION OF INTERCELLULAR ADHESION MOLECULE–1 IN RAT INNER EAR DUE TO BACTERIAL OTITIS MEDIA

MICHIHIKO SONE, MD
NAGOYA, JAPAN
DANIEL M. CANAFAX, PHARMD
MINNEAPOLIS, MINNESOTA
HENRY Q. RUSSLIE
MINNEAPOLIS, MINNESOTA
MICHAEL M. PAPARELLA, MD
MINNEAPOLIS, MINNESOTA

Expressions of anti–*Streptococcus pneumoniae* antibody and anti–intercellular adhesion molecule–1 (ICAM-1) antibody in the inner ear were studied immunohistochemically in rats following inoculation of *S pneumoniae* type 6A into the middle ear cavity. Positive staining with anti–*S pneumoniae* antibody was detected in the marginal cells of the stria vascularis of rats sacrificed 3 days after *S pneumoniae* inoculation, but almost no staining was detected in those sacrificed at 14 days. Strong ICAM-1 expression was detected in the basal cell layer of the stria vascularis of rats sacrificed 3 days after inoculation, but the intensity of the staining had decreased by 14 days. These results suggest that the stria vascularis may be a site of the inner ear damage that follows bacterial inoculation into the middle ear cavity. The up-regulated expression of ICAM-1 in the basal cell layer may represent a reaction of the inner ear to the bacterial otitis media.

KEY WORDS — adhesion molecule, otitis media, rat, *Streptococcus pneumoniae*, stria vascularis.

INTRODUCTION

Several types of otitis media, including acute otitis media, mucous otitis media, and chronic otitis media, are caused by bacterial infection in the middle ear. In some clinical cases, otitis media is accompanied by inner ear disturbances that cause sensorineural hearing loss, especially in the high frequencies.[1] To elucidate the influence of the otitis media on the inner ear, animal studies have been conducted in chinchillas[2-6] and rats.[7-9] These studies have demonstrated morphologically and physiologically that bacterial exotoxins[2,4,8,9] and endotoxins[5,7] instilled into the middle ear cavity pass through the round window membrane (RWM) and cause inner ear damage. Recently, a newly developed polymerase chain reaction assay revealed evidence of a higher rate of pneumococcal causation in children with acute otitis media than is detected by bacterial culture, indicating that pneumococcus is highly causative of otitis media.[10] Studies of the inner ear effects of *Streptococcus pneumoniae* instillation into the middle ear cavities have also been conducted in chinchillas,[3,6] but anatomic differences exist between human and chinchilla middle ears. Rats are known to be a more suitable model for the study of otitis media, due to the anatomic similarities between human and rat middle ears.[11]

Intercellular adhesion molecule–1 (ICAM-1), a member of the immunogloblin supergene family, is up-regulated in immune responses or inflammation, and mediates cell activation and migration. It is expressed in fibroblasts, leukocytes, endothelial and epithelial cells, and many tumor cells. Adhesion molecules are known to play an important role not only in middle ear disease, including otitis media with effusion[12] and cholesteatoma,[13] but also in inner ear inflammation.[14-16]

To investigate the effects of bacterial otitis media on the cochlea, *S pneumoniae* type 6A was inoculated into middle ears of rats, and immunohistochemical methods were used to study the expression of anti–*S pneumoniae* antibody and anti–ICAM-1 antibody in the inner ear.

MATERIALS AND METHODS

Animals and Experimental Design. Eighteen healthy female Sprague-Dawley rats weighing 175 to 225 g were used in this study. During bacterial inoculation and at the time of sacrifice, animals were anesthetized with a mixture of ketamine hydrochloride (40 mg/kg), xylazine hydrochloride (8 mg/kg), and acepromazine maleate (1 mg/kg) administered intramuscularly. Bacterial inoculation was performed under the microscope, by instilling *S pneumoniae*

From the Department of Otorhinolaryngology, Nagoya University School of Medicine, Nagoya, Japan (Sone), and the University of Minnesota Otitis Media Research Center, Minneapolis, Minnesota (Russlie, Canafax, Paparella). This work was supported in part by the Yokoyama Foundation in Japan, the International Hearing Foundation, and research grant P01-DC00133 from the National Institutes of Health/National Institute on Deafness and Other Communication Disorders. This study was performed in accordance with the PHS Policy on Humane Care and Use of Laboratory Animals, the NIH *Guide for the Care and Use of Laboratory Animals*, and the Animal Welfare Act (7 U.S.C. et seq.); the animal use protocol was approved by the Institutional Animal Care and Use Committee (IACUC) of the University of Minnesota, Minneapolis.

CORRESPONDENCE — Michihiko Sone, MD, Dept of Otorhinolaryngology, Nagoya University School of Medicine, 65 Tsurumai-cho, Showa-ku, Nagoya, 466-8550 Japan.

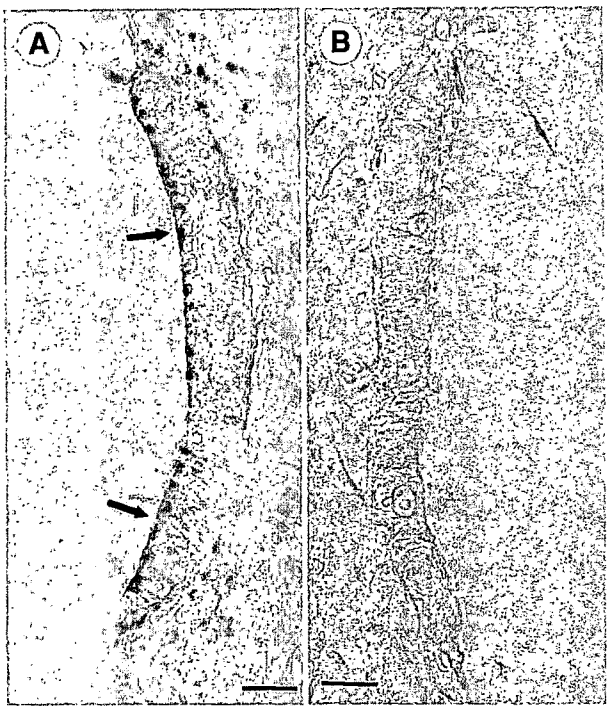

Fig 1. Immunohistochemical staining with anti–*Streptococcus pneumoniae* antibody in stria vascularis of *S pneumoniae*–inoculated rats. Scale bars — 20 μm. A) Positive staining (arrows) in marginal cells of rat sacrificed at 3 days. B) No staining in rat sacrificed at 14 days.

type 6A (5.0×10^7 colony-forming units per milliliter) into the right middle ear cavity of each animal through the tympanic membrane with a 25-gauge needle. No treatment was performed on the left ear of each animal. As a control, another group of animals received phosphate-buffered saline in the right middle ear cavity instead of *S pneumoniae*. Animals were painlessly sacrificed 3 days or 14 days following bacterial inoculation.

Tissue Preparation. Following sacrifice by intracardiac perfusion with periodate-lysine–4% paraformaldehyde fixative, the right temporal bone of each animal was removed and was fixed by the same fixative overnight at 4°C. All temporal bones were decalcified in 10% ethylenediaminetetraacetic acid and embedded in compound medium for frozen sections. Some temporal bones from the inoculated rats and controls were fixed by 10% buffered formalin and embedded in paraffin for hematoxylin and eosin staining.

Immunohistochemical Staining. Frozen tissue blocks of temporal bones containing the middle ear and the inner ear were sectioned at a thickness of 10 to 12 μm, and sections were attached on poly-L-lysine (Sigma, St Louis, Mo)–coated slides. Sections were incubated with rabbit anti–*S pneumoniae* antibody (Biodesign International, Kennebunk, Maine) or monoclonal mouse anti-rat ICAM-1 (CD54) antibody (Genzyme, Cambridge, Mass) as the primary antibody, and biotin-goat anti-mouse IgG or anti-rabbit IgG (Sigma) as the secondary antibody. To remove endogenous peroxidase, the slides were treated with 0.3% hydrogen peroxide in methanol. After incubation with avidin and biotinylated horseradish peroxidase reagents (Dako, Carpinteria, Calif), sections were developed with 3,3'-diaminobenzidine tetrahydrochloride and hydrogen peroxide, and counterstained with methyl green. Sections without primary antibody treatment served as negative controls.

RESULTS

Hematoxylin and eosin staining revealed acute inflammatory reactions in the middle ears of rats sacrificed 3 days after *S pneumoniae* inoculation, including infiltration of inflammatory cells, especially polymorphonuclear cells, in both the epithelial and subepithelial layers. Polymorphonuclear cells were also detected in the fibrous layer of the RWM and, occasionally, in the perilymphatic space of the scala tympani of the basal turn. These inflammatory changes were less extensive in rats sacrificed 14 days after inoculation. The inner ears of the inoculated rats showed no distinctive pathological changes at either 3 days or 14 days after *S pneumoniae* inoculation.

Immunohistochemical examination of the rat inner ears using anti–*S pneumoniae* antibody showed positive staining in the marginal cells of the stria vascularis (Fig 1A), but the positive staining was not necessarily intense in the lower turns. At 14 days after inoculation, no or occasionally weak staining was detected in the marginal cells of the stria vascularis (Fig 1B). No positive staining was detected in the control animals.

Weak staining with anti–ICAM-1 antibody was detected in the basal cell layer of the stria vascularis of the control animals (Fig 2A), while strongly positive staining was observed in the basal cell layer of the stria vascularis of the rats sacrificed 3 days after inoculation (Fig 2B). At 14 days after inoculation, the staining in the basal cell layer was less intense (Fig 2C). The Table shows the results of immunohistochemical staining in the inner ears of the inoculated rats.

DISCUSSION

The RWM is the most important pathway through which bacterial toxins pass from the middle to the inner ear. Structural changes of the RWM have been studied in chinchillas[2] and rats,[17] after middle ear application of bacterial exotoxin. Bacterial toxins have been surmised to promote the permeability of the RWM.[4] Severe toxin-mediated inner ear dam-

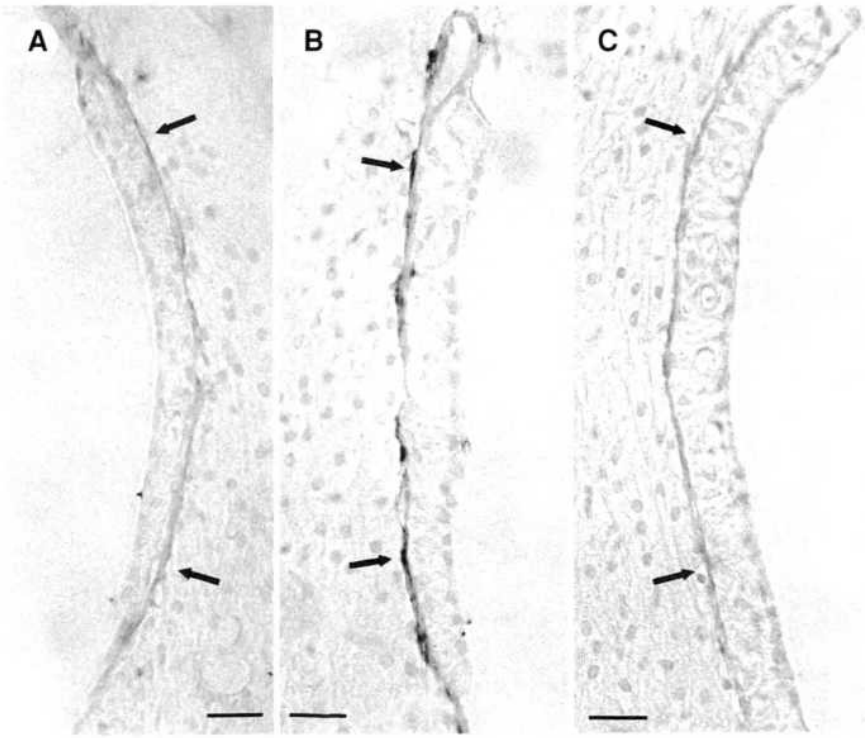

Fig 2. Immunohistochemical staining with anti–intercellular adhesion molecule–1 antibody in stria vascularis. Scale bars — 20 μm. A) Weakly positive staining (arrows) in basal cell layer of stria vascularis of control rat. B) Strongly positive staining (arrows) in basal cell layer of rat sacrificed at 3 days. C) Decreased intensity of staining (arrows) in basal cell layer of rat sacrificed at 14 days.

age, including inflammatory cell infiltration in the perilymphatic space, bleeding in the spiral ligament, vacuolization of the stria vascularis, and hair cell damage, was demonstrated in a study in chinchillas,[5] and these inner ear changes were considered to be irreversible.[8] *Streptococcus pneumoniae* type 7F inoculated into the middle ear was found to enter myelinated nerves and spread into the organ of Corti in the chinchilla model.[6]

The anti–*S pneumoniae* antibody used in the present study detects specific protein from a type 3 clinical specimen and reacts against all *S pneumoniae* serotypes. In a preliminary study, *S pneumoniae* was inoculated into the tympanic bulla of rats by a ventral approach, and the results were the same, in terms of histopathologic findings, as those presented in this paper. To keep surgical invasion to a minimum, bacterial inoculation was performed through the tympanic membrane.

Studies of the inner ear disturbances of rats following bacterial toxin application into the middle ear differ from those of the chinchilla model, in that the changes appear to be reversible.[7,9] Stenqvist et al[9] demonstrated in rats that electrophysiological changes of the inner ear were most severe 48 hours after bacterial exotoxin inoculation into the middle ear, and were found to be expressed most often in the higher-frequency region tonotopically adjacent to the RWM. This finding has been supported by clinical observation of sensorineural hearing loss in the high frequencies following otitis media.[1] In the present study, *S pneumoniae*–positive staining was detected in the marginal cells of the stria vascularis of rats sacrificed 3 days after inoculation. More severe inner ear disturbances have been found in the lower turns of animal models following bacterial toxin inoculation into the middle ear[3,7,9]; however, the positive staining found in the stria vascularis was not necessarily intense in the lower turns, and does not support more severe disturbances in the lower turns.

In a study of lipopolysaccharides injected directly into the perilymphatic space of guinea pigs, endotoxic damage in the stria vascularis was suggested to be

EXPRESSION OF ANTIBODIES IN INNER EAR OF INOCULATED RATS

		3 Days			*14 Days*		
Antibodies Against	*Sites*	*Basal Turn*	*Second Turn*	*Apical Turn*	*Basal Turn*	*Second Turn*	*Apical Turn*
Streptococcus pneumoniae	Marginal cell of stria vascularis	+ to ++	++	+ to ++	− to +	− to +	−
Intercellular adhesion molecule–1	Basal cells of stria vascularis	++ to +++	+++	+++	+	+	+

− — negative; + — weakly positive; ++ — moderately positive; +++ — strongly positive.

responsible for the inner ear disturbances following otitis media.[18] The *S pneumoniae*–positive staining seen in the present study may support the hypothesis that dysfunction of the stria vascularis, especially of the marginal cells, could be responsible for sensorineural hearing loss following bacterial otitis media.

Intercellular adhesion molecule–1 is a member of the immunoglobulin supergene family. It has a wide tissue distribution on both hematopoietic and nonhematopoietic cells. Expression of ICAM-1 is present at the basal level in normal tissues, and in high levels in inflamed tissues.[19] All cells containing ICAM-1 play an important role in immune or inflammatory responses. Up-regulation of ICAM-1 has been demonstrated in otitis media with effusion,[12] cholesteatoma,[13] and inner ear inflammation.[14] In a study of keyhole limpet hemocyanin inoculation into the scala tympani of rats systematically sensitized to keyhole limpet hemocyanin, expression of ICAM-1 was detected in the endothelium of the spiral modiolar vein and its collecting venules, the mesothelium of the perilymphatic space, the perineurium of the cochlear nerve, the spiral ligament, the basal cells of the stria vascularis, the epithelium of the endolymphatic sac, and the perisaccular region.[14] Prophylactic use of monoclonal antibody against ICAM-1 reduced inner ear inflammation induced by a secondary immune reaction, suggesting an important role of ICAM-1 in inner ear immunology.[16]

In the present study, strongly positive ICAM-1 staining was detected in the basal cell layer of the stria vascularis of rats sacrificed 3 days after inoculation. At 14 days, the intensity of the staining had diminished. Although positive staining was also detected in the inner ears of the control animals, the expression of ICAM-1 seen in the basal cell layer was considered to be up-regulated during the infection. Expression of ICAM-1 was not detected in any other site of the cochlea. The evidence of ICAM-1 up-regulation in the stria vascularis, demonstrated to be the main site targeted by *S pneumoniae*, may provide essential clues to inner ear effects due to bacterial otitis media, although the exact significance of ICAM-1 expression in the basal cell layer is unclear.

Capillaries entering and leaving the stria vascularis are surrounded by layers of basal cells and fibrocytes, and it can be speculated that these layers would control the vascular flow out of the stria vascularis.[20] Expression of ICAM-1 has an apparent relationship to blood flow. In vascular endothelial cells, shear stress generated by increased blood flow has been demonstrated to up-regulate expression of ICAM-1.[21] Anti–ICAM-1 antibody has been shown to have a significant effect in preserving microvascular blood flow in human wounds.[22] Considering these findings, up-regulation of ICAM-1 expression in the basal cell layer may represent a reaction to bacterial infection that alters blood flow in the stria vascularis.

Further studies are needed to elucidate the meaning of ICAM-1 expression in the stria vascularis. This study provides insight into the effect of bacterial otitis media on inner ear function, in relation to expression of adhesion molecules in the inner ear.

ACKNOWLEDGMENT — We thank JoAnn Knox for editing the manuscript.

REFERENCES

1. Paparella MM, Morizono T, Le CT, et al. Sensorineural hearing loss in otitis media. Ann Otol Rhinol Laryngol 1984; 93:623-9.

2. Schachern PA, Paparella MM, Goycoolea M, Goldberg B, Schlievert P. The round window membrane following application of staphylococcal exotoxin: an electron microscopic study. Laryngoscope 1981;91:2007-17.

3. Morizono T, Giebink GS, Paparella MM, Sikora MA, Shea D. Sensorineural hearing loss in experimental purulent otitis media due to *Streptococcus pneumoniae*. Arch Otolaryngol 1985;111:794-8.

4. Ikeda K, Morizono T. Changes of the permeability of round window membrane in otitis media. Arch Otolaryngol Head Neck Surg 1988;114:895-7.

5. Kawauchi H, DeMaria TF, Lim DJ. Endotoxin permeability through the round window. Acta Otolaryngol Suppl (Stockh) 1988(suppl 457):100-15.

6. Schachern PA, Paparella MM, Hybertson R, Sano S, Duvall AJ. Bacterial tympanogenic labyrinthitis, meningitis, and sensorineural damage. Arch Otolaryngol Head Neck Surg 1992; 118:53-7.

7. Spandow O, Anniko M, Hellström S. Inner ear disturbances following inoculation of endotoxin into the middle ear. Acta Otolaryngol (Stockh) 1989;107:90-6.

8. Lundman L, Santi PA, Morizono T, Harada T, Juhn SK, Bagger-Sjöbäck D. Inner ear damage and passage through the round window membrane of *Pseudomonas aeruginosa* exotoxin A in a chinchilla model. Ann Otol Rhinol Laryngol 1992;101: 437-44.

9. Stenqvist M, Anniko M, Pettersson Å. Effect of *Pseudomonas aeruginosa* exotoxin A on inner ear function. Acta Otolaryngol (Stockh) 1997;117:73-9.

10. Virolainen A, Salo P, Jero J, Karma P, Eskola J, Leinonen M. Comparison of PCR assay with bacterial culture for detecting *Streptococcus pneumoniae* in middle ear fluid of children with acute otitis media. J Clin Microbiol 1994;32:2667-70.

11. Hermansson A, Emgård P, Prellner K, Hellström S. A rat model for pneumococcal otitis media. Am J Otolaryngol 1988; 9:97-101.

12. Himi T, Kamimura M, Kataura A, Imai K. Quantitative

analysis of soluble cell adhesion molecules in otitis media with effusion. Acta Otolaryngol (Stockh) 1994;114:285-8.

13. Bujía J, Holly A, Kim C, Scanady N, Kastenbauer E. Expression of human intercellular adhesion molecules in middle ear cholesteatoma. Am J Otolaryngol 1994;15:271-5.

14. Suzuki M, Harris JP. Expression of intercellular adhesion molecule-1 during inner ear inflammation. Ann Otol Rhinol Laryngol 1995;104:69-75.

15. Gloddek B, Arnold W. Role of adhesion molecules for the immunological defense of the inner ear. ORL 1995;57:10-4.

16. Takasu T, Harris JP. Reduction of inner ear inflammation by treatment with anti–ICAM-1 antibody. Ann Otol Rhinol Laryngol 1997;106:1070-5.

17. Spandow O, Hellström S, Anniko M. Structural changes in the round window membrane following exposure to *Escherichia coli* lipopolysaccharide and hydrocortisone. Laryngoscope 1990;100:995-1000.

18. Guo Y, Wu Y, Chen W, Lin J. Endotoxic damage to the stria vascularis: the pathogenesis of sensorineural hearing loss secondary to otitis media? J Laryngol Otol 1994;108:310-3.

19. Montefort S, Holgate ST. Adhesion molecules and their role in inflammation. Respir Med 1991;85:91-9.

20. Watanabe K. Ultrastructural characteristics of capillaries entering and leaving the stria vascularis. Ann Otol Rhinol Laryngol 1986;95:309-12.

21. Tsuboi H, Ando J, Korenaga R, Takada Y, Kamiya A. Flow stimulates ICAM-1 expression time and shear stress dependently in cultured human endothelial cells. Biochem Biophys Res Commun 1995;206:988-96.

22. Mileski WJ, Rothlien R, Lipsky P. Interference with the function of leukocyte adhesion molecules by monoclonal antibodies: a new approach to burn injury. Eur J Pediatr Surg 1994; 4:225-30.

≈

EUROPEAN SOCIETY OF PEDIATRIC ORL

The Vth International Conference of the European Society of Pediatric ORL will be held July 9-13, 2000, in Graz, Austria. For more information, contact Claire Zwerina, Secretary to Prof Stammberger, ENT-Department, University Hospital, Auenbruggerplatz 20, A-8036 Graz, Austria; fax ++43/316/385/3425.

SPONTANEOUS CEREBROSPINAL FLUID OTORRHEA FROM A TEGMEN DEFECT: TRANSMASTOID REPAIR WITH MINICRANIOTOMY

RUDOLF KUHWEIDE, MD JAN W. CASSELMAN, MD, PHD

BRUGES, BELGIUM

Spontaneous cerebrospinal fluid (CSF) otorrhea is a rare condition that presents in 2 clinical categories. In congenital labyrinthine malformations, it leads to bouts of meningitis in a hearing-impaired child. In the adult age group, a spontaneous CSF leak almost always results from a dural and bony defect in the tegmen area. Possible pathogenic mechanisms include progressive sagging and rupture of dura through a congenital tegmen dehiscence and progressive bone erosion by aberrant arachnoid granulations. These patients usually present with a middle ear effusion, resulting in clear discharge after myringotomy with tube insertion. Based on 4 patients with a CSF leak from a tegmen defect, this report reviews the clinical findings and diagnostic approach. The surgical management by a 5-layer closure using a transmastoid approach with minicraniotomy is outlined. This procedure offers a relatively simple and reliable method for repair without the inherent risks of a middle fossa craniotomy.

KEY WORDS — abnormalities, cerebrospinal fluid otorrhea, encephalocele, meningocele, otitis media with effusion.

INTRODUCTION

Leakage of cerebrospinal fluid (CSF) through the temporal bone is mostly secondary to accidental or surgical trauma, infection, or a neoplasm. There may, however, be no apparent cause, and then the CSF otorrhea is defined as being spontaneous. Spontaneous CSF otorrhea is a rare condition that presents in 2 major clinical categories, according to age.

In childhood, a congenital labyrinthine malformation often engenders a free communication between the subarachnoid and perilymphatic spaces. This allows CSF to flow directly from the internal auditory canal to the oval and round windows. Eventually, the CSF reaches the middle ear compartment, either after a minor head trauma; spontaneously, due to pressure erosion of a (defective) footplate; or in the form of a surgically induced perilymphatic gusher, as is possible with cochlear implantation in Mondini's dysplasia or stapedotomy in X-linked progressive mixed deafness. Other and perilabyrinthine pathways of spontaneous and congenital CSF fistulas have been reported occasionally — 3 via a widened fallopian canal, and 2 via Hyrtl's fissure — and the possibility of a leak via the petromastoid canal encasing the subarcuate artery has been invoked.[1,2] Spontaneous CSF leakage in a congenitally malformed ear manifests itself clinically as a history of recurrent bouts of meningitis. Due to the preexisting cochleovestibular deficit, both the middle ear effusion (which is a frequent finding in children) and the intermediate stage of labyrinthitis pass unnoticed.

A presumably smaller group of patients present with spontaneous CSF otorrhea at an older age, between 40 and 70 years.[2] The leak results from a dural and mastoid plate defect, most often in the middle cranial fossa, and more precisely in the area of the tegmen tympani. When extensive, the defect usually admits the herniation of brain tissue (encephalocele), while a small defect contains only arachnoid tissue (meningocele). The usual picture is that of middle ear effusion resulting in clear discharge after myringotomy with ventilation tube insertion. In 1995, May et al[3] reviewed the literature on spontaneous CSF leaks in the temporal bone and added 12 institutional cases to a total of 44 reported. They thus suggested that this entity might be more prevalent than previously thought. In keeping with this, Pappas et al[4] counted 61 cases up to 1996, nearly half of them being reported since 1992. The same group identified 5 cases in 3 years.[5] We recently diagnosed 3 cases within a year and report here our experience with 4 institutional cases of adult-onset spontaneous CSF otorrhea.

CASE REPORTS

Case 1. A 64-year-old man was first seen in 1986 with right-sided otorrhea of half a year's duration. The otorrhea followed the insertion of a ventilating tube, most likely after a diagnosis of serous otitis media. There had been no prior history of head trauma, infection, or ear surgery. Physical examination showed a Goode T-tube surrounded by a small

From the Departments of Otorhinolaryngology–Head and Neck Surgery (Kuhweide) and Radiology (Casselman), AZ Sint Jan Hospital, Bruges, Belgium.

CORRESPONDENCE — Rudolf Kuhweide, MD, Dept of Otorhinolaryngology, AZ Sint Jan, Ruddershove 10, B-8000 Brugge, Belgium.

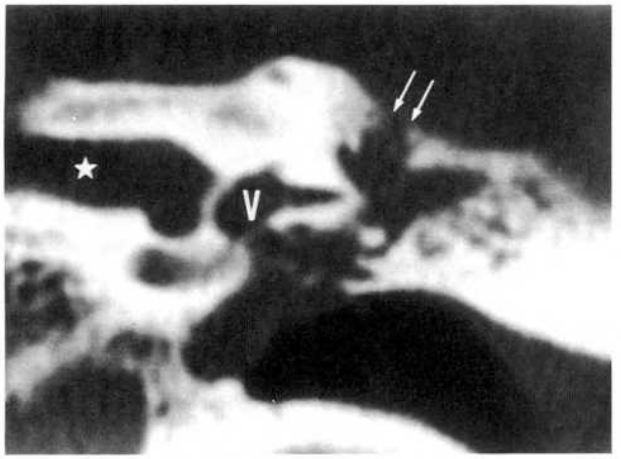

Fig 1. (Case 2) Coronal computed tomography scan of right temporal bone. Middle ear cavity is completely obliterated. Small interruption is suspected in tegmen, just medial to Koerner's septum (arrows). Asterisk — internal auditory canal, V — vestibule.

amount of watery discharge. Audiometry showed a 20-dB conductive hearing loss. The discharge was clear and said to be copious at times. As proof, the patient brought a 10-mL sample of clear fluid, which contained 48 mg/dL glucose. A computed tomography (CT) scan did not show structural inner ear deformities, but was read as not conclusive with regard to the tegmen. Mastoidectomy demonstrated a large encephalocele protruding from a bony defect in the tegmen overlying the antrum. With manipulation, clear fluid could be seen escaping along the brain herniation. Because of its dimensions, the tegmen defect was addressed by the middle fossa approach in the neurosurgery department. The dural defect was repaired by direct suture, and the temporal bone defect was closed with autologous cortical bone fragments. The patient remained asymptomatic 18 months following surgery.

Case 2. A 71-year-old man presented with a longstanding history of right ear fullness, pulse-synchronous tinnitus, and hearing loss, with temporary relief after myringotomy. There was no history of head trauma, infection, or ear surgery. Physical examination revealed an opaque tympanic membrane on both sides. Audiometry showed a right-sided conductive hearing loss of about 50 dB. Repeat myringotomy showed clear fluid, and a tube was inserted. In the following weeks, the patient noticed clear discharge, but only at night. On 3 different occasions, otomicroscopy revealed either no or only minute amounts of fluid around the tube, even after squeezing of the internal jugular vein. Yet, this small fluid sample sufficed to identify 2 electrophoretically separated bands of transferrin, confirming the CSF nature. A CT scan (Fig 1) did not demonstrate a distinct tegmen defect, although the right middle ear and mastoid were completely opacified and the tegmen line was blurred in a small area just medial to Koerner's septum. In that particular area, some granulation tissue was disclosed at mastoid exploration. With manipulation, a CSF leak became apparent. A minicraniotomy[6] was performed, and the defect was closed as described in the Discussion. A spinal drain, which was inserted in the operating room before surgery, was allowed to drain immediately after sealing the leak and was removed 5 days later. Almost 2 years later, the patient remains symptom-free.

Case 3. A 51-year-old man was referred with a 6-month history of intermittent clear discharge and persistent hearing loss in the right ear after myringotomy with tube insertion performed elsewhere. He denied any head trauma, infection, or prior ear surgery. Physical examination showed a moist external canal. Audiometry showed a right-sided conductive hearing loss of 15 dB. A CT scan revealed a large tegmen defect extending from Koerner's septum to the incudal body (Fig 2A). There was an associated soft tissue density that on magnetic resonance imaging (MRI) demonstrated slight spontaneous hyperintensity and distinct partial enhancement (Fig 2B) suggesting inflammatory tissue. Mastoidectomy disclosed CSF flowing from a seeming inflammatory mass that was amputated and on pathological examination proved to be a brain herniation covered by inflamed mucosa. The defect was closed as described in the Discussion. The lumbar drain was removed after 3 days because of headache and insufficient external drainage. Eighteen months after surgery, the patient continues to be symptom-free.

Case 4. A 60-year-old man who had been found to have Goodpasture's syndrome and was on dialysis presented with a dull tympanic membrane and a 25-dB conductive hearing loss on the right side. The history was negative with regard to head trauma, infection, or ear surgery. Myringotomy yielded rather purulent material, which continued to flow profusely for weeks despite aggressive systemic and local antibiotherapy and progressively evolved to a more watery color. A β2-transferrin test was positive. A CT scan showed a questionable tegmen defect located quite laterally, just underneath the mastoid cortex. The ear dried up a couple of days before planned surgery, and the patient declined further treatment.

DISCUSSION

Spontaneous CSF otorrhea is a rare condition that presents in 2 major clinical categories according to age. In childhood, it is due to a congenital labyrinthine malformation. Clinically, this presents as a history of recurrent bouts of meningitis in a hearing-

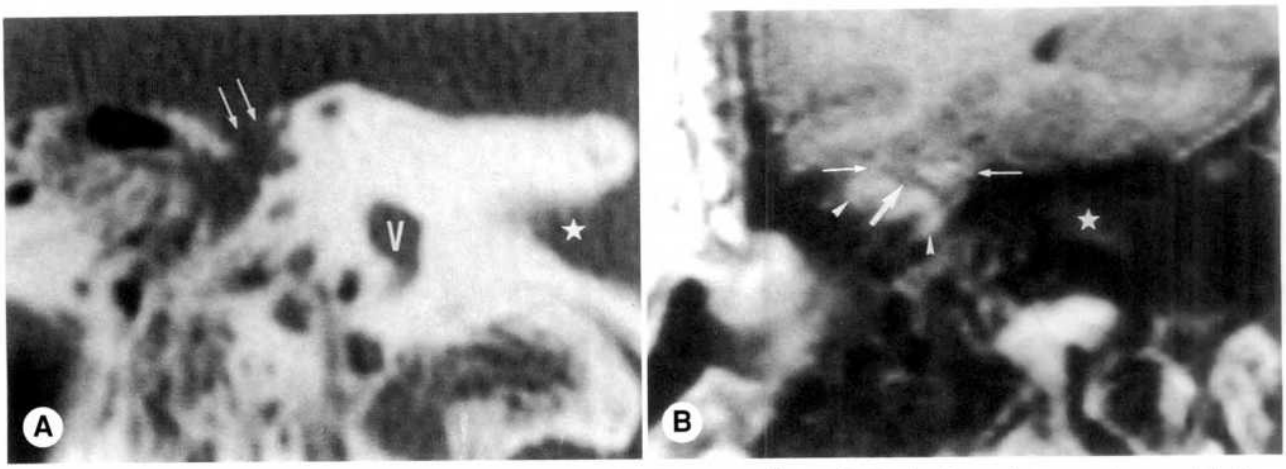

Fig 2. (Case 3) A) Coronal computed tomography scan of right temporal bone. Defect is shown in tegmen tympani, just medial to Koerner's septum (arrows). Underlying antrum is completely obliterated. Asterisk — internal auditory canal, V — vestibule. B) T1-weighted gadolinium-enhanced spin-echo image, 450/14/4 (repetition time/echo time/acquisitions), through right temporal bone. Defect in tegmen tympani is again demonstrated (long arrows). Tissue, isointense with gray matter, is extending through defect into antrum (large arrow). In antrum, this tissue is surrounded by area of higher signal intensity (arrowheads), probably representing enhancing inflammatory or granulation tissue. Asterisk — internal auditory canal.

impaired child. In adulthood, it is due to a bony and dural defect, occurring most often in the area of the tegmen tympani. The exact pathogenesis remains obscure, although it may possibly involve a (minor) congenital anomaly in the adult-onset group as well.

One or more bony dehiscences in the tegmen were found in about 20% of randomly selected temporal bones in 3 separate studies.[7-9] They were thought to account for a number of fatalities, with air being driven intracranially through the defect after myringotomy and external ear canal insufflation in the treatment of (apparent) serous otitis media. These defects might also be responsible for spontaneous CSF leaks, by way of a 1-way valve system. Hereby, the pulsatile CSF pressure progressively drives the dura through the dehiscence, and the dura cannot return, due to the blocking action of brain tissue.[10] Moreover, the dura weakens with aging. Finally, the sagging dura and arachnoidea would rupture and create a CSF leak. The question arises, however, as to why only a minor fraction of patients with a presumed congenital tegmen defect develop a CSF leak. Increased intracranial pressure, low-grade mastoid inflammation, and dural weakening with age have been postulated as contributing factors.[8] Increased intracranial pressure might be responsible for the development of multiple skull base CSF fistulas, not only in the tegmen, but in the ethmoid and sphenoid sinuses as well.[3,4]

Richard Gacek[11,12] suggests another theory on the origin of spontaneous CSF leaks, predicated on arachnoid granulations. Arachnoid granulations, also known as arachnoid villi or Pacchioni's granulations, represent the principal mechanism for CSF resorption. They consist of pedunculated protrusions of arachnoidal tissue into the lumen of a venous sinus — mainly the superior sagittal sinus and its branches. The dura, which still encloses them, is reduced to a tiny membrane. The pressure difference drives the CSF into the venous blood. In older people, the arachnoid granulations increase in size and may penetrate the bone, seeking contact with the diploic veins.[13] This causes the so-called foveolae granulares, little pinholes that can be seen along the middle line of the skull vault inner surface. The appearance of arachnoid granulations in the dural surfaces of the temporal bone probably represents a congenital anomaly, since they have no contact with a venous sinus. Alternatively, their location in the posterior fossa dural lining might represent an aborted attempt to reach the sigmoid sinus in order to resorb CSF.[11]

Gacek[11,12] suggests that the pulsatile pressure of the CSF inside these arachnoid granulations produces bone erosion and thus a communication with mastoid air cells. Moreover, in older people, arachnoid granulations exhibit a particular propensity to invade bone, as stated above. So far, however, temporal bone arachnoid granulations have only been reported on the posterior fossa plate, whereas spontaneous CSF leaks involving the posterior fossa plate are rare.[4,8,11] Little pinholes have been observed in the middle fossa surface in 22% of dried temporal bone specimens,[8] concurring with the 21% incidence of presumed congenital tegmen dehiscences.[7] Whether both findings reflect the actual occurrence of arachnoid granulations through one fifth of middle fossa plates, as suggested by Gacek,[11] remains to be proven. By analogy, arachnoid granulations may also be found in

the roof of the sphenoid and ethmoid sinuses, where they have been associated with spontaneous CSF rhinorrhea.[14]

The usual clinical picture is that of an adult with middle ear effusion, resulting in clear discharge after myringotomy with (or sometimes without, as in case 4) ventilation tube insertion. Frequently, the discharge only manifests in the supine position. Compression of the jugular vein or performance of the Valsalva maneuver may precipitate the discharge. In contrast to the pediatric age group, only about one tenth[3,5] to one fifth[8] of the adults have a history of meningitis. A salty taste and watery rhinorrhea are infrequent findings in these patients, probably because the flow rate of CSF leakage and subsequent exit through the eustachian tube is low. All 4 cases presented were in middle-aged to elderly men. In the literature, however, women outnumber men.[2] All 4 had their leak on the right side, and remarkably, the same holds true for the majority of reported cases. Perhaps this reflects the usual right-sided dominance in the venous outflow of the brain, which is presumptively attributed to the lower pressure in the right jugular bulb due to a gravitation effect and the direct suction action from the right cardiac atrium during diastole.[15] Attempts to correlate the venous outflow of the brain to muscle development in connection with right-handedness have given inconsistent results.[16] Curiously, a marked right-sided dominance was noted in the rare postsurgical occurrence of brain herniation in chronic otitis media as well.[17]

Diagnosis largely depends on suspicion. Identification of β2-transferrin in a fluid sample currently is the most simple and reliable way to demonstrate that the clear discharge has a CSF source.[18] The main advantages of this technique compared to glucose testing are that it requires only a small amount of fluid and contamination by pus or blood does not invalidate the test. High-resolution CT may show a discontinuity of the tegmen plate associated with a soft tissue density in the mastoid. The soft tissue density may represent either granulation tissue or brain tissue, an encephalocele being present in about 75% of the cases.[2] Magnetic resonance imaging has not proven to be of great use, since herniated brain tissue is nonfunctioning and hence does not show the same MRI characteristics as normal brain tissue. Recently, flow-sensitive MRI has emerged as a promising technique in the evaluation of CSF leaks.[19] Intrathecal injection of iodine-containing radiocontrast agents may be beneficial in identifying the fistulous tract in patients with several traumatic skull base defects, but seems superfluous when a positive β2-transferrin test in the ear prompts a surgical exploration. Moreover, the diagnostic ability of intrathecal contrast studies drops dramatically when one is dealing with intermittent leaks.[5,19] In these circumstances, radionuclide cisternography is more helpful, but it significantly lacks spatial resolution. Intrathecal radiolabeled albumin may still play a role in excluding slow CSF egress from a skull base defect as an underlying cause of recurrent meningitis in a patient with intact tympanic membranes. Overall systematic application of any form of cisternography in the diagnostic workup of a spontaneous CSF leak is not advocated.[5,12] On the other hand, intrathecal fluorescein injection may take part in the surgical treatment of CSF leaks. In case no CSF leak is found or if adequate sealing of the leak is doubtful, fluorescein can be injected into the lumbar drain inserted prior to surgery. Since transient neurologic complications[20] have occurred with the use of fluorescein, the intrathecal injection of Ringer's solution along with positive pressure ventilation may be a relatively safe alternative. If the fluorescein dye is diluted sufficiently, however, significant adverse effects are not expected.[3,10,21]

A positive β2-transferrin test justifies a surgical exploration, for the condition is life-threatening.[3,8] Computed tomography serves as a guide in defect localization and appropriate surgical approach.[5] Rarely, a defect is found in the posterior fossa plate or in the tegmen overlying the mastoid. Treatment then consists of a canal wall–up mastoidectomy with fat obliteration of the cavity. Total middle ear fat obliteration would be appropriate should there be no serviceable hearing, possibly as part of a subtotal petrosectomy procedure. A middle fossa approach seems indicated only when dealing with one of the following situations: a recurrence after attempted closure from the mastoid, a very large tegmen tympani defect, multiple tegmen defects, or a defect in the anterior inaccessible part of the tegmen with serviceable hearing. Multisite involvement occurs in 5% to 10% of cases.[4]

In the vast majority, the defect is either questionable on CT or localized in the posterior part of the tegmen tympani, which is accessible from the mastoid — if necessary, by including removal of the incus and malleus head and subsequent incus interposition. The preferred surgical technique in these circumstances is a transmastoid repair with a minicraniotomy, as proposed by Adkins and Osguthorpe.[6] A very restricted craniotomy is fashioned in the temporal squama, exposing the dura just superior to the tegmen plate and lateral to the site of the leak. The dura is carefully elevated from the tegmen, and any herniated brain tissue is cauterized and amputated.

This technique was successfully used in 2 of our cases. The defect was closed in 5 layers. Intracranially, a piece of temporal fascia was placed against the dura and a slice of conchal cartilage was put over the defect. In both cases, after release of the elevated dura, these layers were sufficient to stop the CSF leak. The third layer consisted of closure of the bony defect from the mastoid surface. This was done by filling the gap with bone paté mixed with fibrin glue, covered by a second piece of temporal fascia. To provide additional support, in the first case a pedicled temporalis muscle flap was rotated into the cavity, as described by Adkins and Osguthorpe.[6] The placement of a roll of silicone sheeting[3] was found to be a more elegant solution in the second case, while at the same time ensuring mastoid ventilation in a more reliable way. The preoperative placement of a lumbar drain assists in reducing the CSF pressure during closure of the leak, if required. It would also allow the intrathecal injection of Ringer's solution or fluorescein when no leak is found. Postoperative lumbar CSF drainage can act as a safety measure, the duration depending on the apparent adequacy of the repair.[3] Yet, the very need for postoperative lumbar drainage may be questioned.

The transmastoid approach for repair of tegmen defects does not necessarily include the shaping of a minicraniotomy. Temporal fascia and a piece of homologous preserved septal cartilage[22] or a mastoid cortical bone chip[23] can be tucked intracranially from the mastoid side of the defect, much like a buttonhole[10,22] or a toggle.[23] However, this technique has mainly been used for repair of small to medium-sized brain herniations following trauma or surgery, which generally did not show any leak of CSF into the middle ear unless intraoperatively touched. Moreover, traumatic or iatrogenic CSF leaks are known to have a higher inclination toward spontaneous healing. On the other hand, it has been shown repeatedly that spontaneous CSF leaks have a particular disposition to recur.[5,8] Thus, we feel that the addition of a minicraniotomy helps considerably in the performance of a transmastoid repair of spontaneous CSF leaks. A minicraniotomy avoids the morbidity of a full middle fossa craniotomy,[6] recommended by some if a tegmen defect is exhibited by CT[8] or if an encephalocele is found.[2] Others advocate a combined transmastoid and middle fossa craniotomy, referring to a possibly unexpected multisite involvement.[24] May et al[3] have described a solution in between a middle fossa craniotomy and a minicraniotomy, called the keyhole craniotomy. This allows the introduction of a fascia-covered titanium mesh, obviating the need for an ossicular chain disruption if the epitympanic space is involved.

Long-term follow-up has been recommended, since 2 out of a series of 12 spontaneous CSF leak patients have developed a second skull base leak.[4]

REFERENCES

1. Gacek RR, Leipzig B. Congenital cerebrospinal otorrhea. Ann Otol Rhinol Laryngol 1979;88:358-65.

2. Wetmore SJ, Herrmann P, Fisch U. Spontaneous cerebrospinal fluid otorrhea. Am J Otol 1987;8:96-102.

3. May JS, Mikus JL, Matthews BL, Browne JD. Spontaneous cerebrospinal fluid otorrhea from defects of the temporal bone: a rare entity? Am J Otol 1995;16:765-71.

4. Pappas DG Jr, Pappas DG Sr, Hoffman RA, Harris SD. Spontaneous cerebrospinal fluid leaks originating from multiple skull base defects. Skull Base Surg 1996;6:227-30.

5. Pappas DG Jr, Hoffman RA, Holliday RA, et al. Evaluation and management of spontaneous temporal bone cerebrospinal fluid leaks. Skull Base Surg 1995;5:1-7.

6. Adkins WY, Osguthorpe JD. Mini-craniotomy for management of CSF otorrhea from tegmen defects. Laryngoscope 1983;93:1038-40.

7. Ahren C, Thulin CA. Lethal intracranial complications following inflation in the external auditory canal in treatment of serous otitis media and due to defects in the petrous bone. Acta Otolaryngol (Stockh) 1965;60:407-20.

8. Ferguson BJ, Wilkins RH, Hudson W. Spontaneous CSF otorrhea from tegmen and posterior fossa defects. Laryngoscope 1986;96:635-44.

9. Lang DV. Macroscopic bony deficiency of the tegmen tympani in adult temporal bones. J Laryngol Otol 1983;97:685-8.

10. Neely JG, Neblett CR, Rose JE. Diagnosis and treatment of spontaneous cerebrospinal fluid otorrhea. Laryngoscope 1982;92:609-12.

11. Gacek RR. Arachnoid granulation cerebrospinal fluid otorrhea. Ann Otol Rhinol Laryngol 1990;99:854-62.

12. Gacek RR. Evaluation and management of temporal bone arachnoid granulations. Arch Otolaryngol Head Neck Surg 1992;118:327-32.

13. Gomez DG, DiBenedetto AT, Pavese AM, Firpo A, Herscham DB, Potts DG. Development of arachnoid villi and granulations in man. Acta Anat (Basel) 1981;111:247-58.

14. Kaufman B, Nulsen FE, Weiss MH, Brodkey JS, White RJ, Sykora GF. Acquired spontaneous nontraumatic normal-pressure cerebrospinal fluid fistulas originating from the middle fossa. Radiology 1977;122:379-87.

15. Kuhweide R, Ampe W, Depondt M, D'Hont G. Vascular tinnitus and arteriovenous meningeal fistula. Acta Otorhinolaryngol Belg 1988;42:513-28.

16. Adams WM, Jones RL, Chavda SV, Pahor AL. CT assessment of jugular foramen dominance and its association with hand preference. J Laryngol Otol 1997;111:290-2.

17. Jackson CG, Pappas DG Jr, Manolidis S, et al. Brain herniation into the middle ear and mastoid: concepts in diagnosis and surgical management. Am J Otol 1997;18:198-206.

18. Bassiouny M, Hirsch BE, Kelly RH, Kamerer DB, Cass SP. Beta2 transferrin application in otology. Am J Otol 1992;

13:552-5.

19. Levy LM, Gulya AJ, Davis SW, LeBihan D, Rajan SS, Schellinger D. Flow-sensitive magnetic resonance imaging in the evaluation of CSF leaks. Am J Otol 1995;16:591-6.

20. Moseley JI, Carton CA, Stern WE. Spectrum of complications in the use of intrathecal fluorescein. J Neurosurg 1978; 48:765-7.

21. Terrell JE. Endoscopic approach to cerebrospinal fluid leaks and encephaloceles. Curr Opin Otolaryngol 1997;5:25-31.

22. Feenstra L, Sanna M, Zini C, Gamoletti R, Delogu P. Surgical treatment of brain herniation into the middle ear and mastoid. Am J Otol 1985;6:311-5.

23. Feenstra L, Blom E. The mastoid approach for brain herniation into the middle ear. Clin Otolaryngol 1983;8:187-90.

24. Lundy LB, Graham MD, Kartush JM, LaRouere MJ. Temporal bone encephalocele and cerebrospinal fluid leaks. Am J Otol 1996;17:461-9.

≈

UC OTOLARYNGOLOGY UPDATE: 1999

The UC Otolaryngology Update: 1999 will be held November 4-6, 1999, in San Francisco, California. For information, contact Office of Continuing Medical Education, Registration Office, Office of CME, UCSF Box 0742, LH-450, University of California, San Francisco, CA 94143-0742; telephone (415) 476-5808; fax (415) 502-1795; web site http://cme.ucsf.edu.

INTRACOCHLEAR SCHWANNOMA AND COCHLEAR IMPLANTATION

JONA KRONENBERG, MD

ZEEV HOROWITZ, MD MINKA HILDESHEIMER, PHD

TEL HASHOMER, ISRAEL

A case of intracochlear schwannoma in a 58-year-old candidate for cochlear implantation is described. The tumor was located in the basal turn of the cochlea and was discovered only during surgery. Computed tomography and magnetic resonance imaging obtained prior to surgery failed to detect the tumor. Intralabyrinthine schwannomas are rare tumors that grow either in the vestibule, as intravestibular schwannomas, or in the cochlea, as intracochlear schwannomas. Complete removal of this tumor was achieved through a posterior tympanotomy approach. Cochlear implantation, which resulted in good hearing, was successfully performed 3 years later.

KEY WORDS — cochlear implant, intracochlear schwannoma.

INTRODUCTION

Acoustic neuromas are benign tumors derived from the perineural Schwann cells of the eighth cranial nerve. These tumors usually arise from the vestibular nerve within the internal auditory canal and expand into the cerebellopontine angle. Intralabyrinthine schwannomas are uncommon, and only 23 cases have been reported in the world literature.[1-7] These were diagnosed accidentally, either during labyrinthectomy and vestibular neurectomy or at autopsy. These intralabyrinthine tumors were described as either intravestibular[1] or intracochlear schwannomas.[2]

This report adds a unique case of an intracochlear schwannoma found during cochlear implantation surgery. To the best of our knowledge, this is the first case of surgical removal of an intracochlear schwannoma prior to cochlear implantation.

CASE REPORT

A 58-year-old patient with complete bilateral deafness was referred to our department for cochlear implantation. On the left side, he had had an acoustic neuroma removed 24 years prior to admission. On the right side, his hearing had gradually deteriorated for unknown reasons, resulting in complete hearing loss. In May 1993, he was admitted for cochlear implantation on the right side. Computed tomography performed prior to surgery revealed no abnormalities on the right side, and on the left side, bony changes consistent with the surgical removal of the acoustic neuroma were found. The patient had neither vestibular complaints nor tinnitus. A posterior tympanotomy was performed, and the scala tympani of the basal turn was opened through a cochleotomy. A white, firm mass was discovered in the basal turn of the cochlea, leaving the apex of the cochlea free of tumor. No bony erosion was noted anywhere in the labyrinth. The tumor was completely resected. As the histologic frozen section proved to be a schwannoma, the procedure was terminated. Magnetic resonance studies obtained after surgery showed no residual tumor. During 3 years of follow-up, there was no recurrence.

In July 1996, a cochlear implantation was undertaken with a 22-channel Nucleus Spectra device. The facial recess was found to be obliterated, and the opening in the cochlea was plugged by connective tissue. This plug was easily removed, and the entire length of the active electrode array was inserted. Hearing rehabilitation commenced 4 weeks after implantation. Only the 10 apical electrodes could be used for electrical stimulation. The remaining electrodes caused an unpleasant sensation in the lower part of the face during activation, probably caused by spread of the electrical current through the connective tissue. Nevertheless, the results of the patient's auditory speech perception were fairly good. The score on syllables of Hebrew words presented in closed set was 100%. The score was 30% on open-set presentation of topic-related, everyday sentences developed at the City University of New York for this and related studies adapted to Hebrew. The patient managed to use the telephone when talking with people known to him.

DISCUSSION

Acoustic neuromas (vestibular schwannomas) usually arise from the vestibular nerve in the internal

From the Departments of Otolaryngology–Head and Neck Surgery (Kronenberg, Horowitz) and Communication Disorders (Hildesheimer), Sheba Medical Center, Tel Hashomer, and Sackler Faculty of Medicine, Tel-Aviv University, Tel-Aviv, Israel.

CORRESPONDENCE — Jona Kronenberg, MD, Dept of Otolaryngology–Head and Neck Surgery, Sheba Medical Center, Tel Hashomer, Israel.

auditory canal, but they can be found anywhere along the path of the eighth nerve. They rarely present within the labyrinth, arising from the terminal fibers of the vestibular or cochlear sensory end organs. The extension of intralabyrinthine schwannoma in the inner ear varies. Miyamoto et al[1] described an isolated tumor in the vestibule, while others described the tumor in the cochlea only.[2] When the tumor originated in the cochlea, the scala tympani of the basal turn was the common site of growth.[3] More extensive tumors have been found, in both the vestibule and cochlea.[4] In most cases there was no extension of the tumor into the internal auditory canal.[5] In our case, the schwannoma developed in the basal turn only, leaving the apical part of the cochlea free of any tumor.

Intralabyrinthine schwannomas are difficult to diagnose. In most cases, the patient history, otoneurological tests, and imaging including computed tomography and magnetic resonance imaging fail to demonstrate the existence of a tumor. It is usually diagnosed accidentally during labyrinthectomy for Meniere's disease,[5] vestibular neurectomy,[6] or autopsy.[2] Only 1 case has been discovered radiographically.[4]

In early reports, intralabyrinthine schwannoma was usually combined with neurofibromatosis.[7] More recent reports have described intralabyrinthine schwannoma in patients without neurofibromatosis.[8] Most of the recent cases have been diagnosed as Meniere's disease.[6] Among the 23 cases reported, 7 patients suffered from complete deafness, but patients with nearly normal hearing were also described.[6] In our case, the patient had complete hearing loss that had become progressively worse during the 10 years prior to surgery.

Although intralabyrinthine schwannoma is a rare occurrence and cannot usually be diagnosed without surgery, it is important to question its existence, especially in deaf patients who are candidates for cochlear implantation surgery and in whom no explanation for deafness was found. As cochlear implantation has become popular nowadays, we can assume that more cases of intralabyrinthine schwannoma will be found.

Complete removal of small tumors via the original cochlear implantation approach seems to be sufficient for small intralabyrinthine schwannomas. If this proves to be effective, implantation can proceed.

REFERENCES

1. Miyamoto RT, Isenberg SF, Culp WM, Tubergen LB. Isolated intralabyrinthine schwannoma. Am J Otol 1980;1:215-7.

2. Ohtani I, Suzuki C, Aikawa T. Temporal bone pathology in intracochlear schwannoma with profound hearing loss. Auris Nasus Larynx 1990;17:17-22.

3. Jorgensen MB. Intracochlear neuroma. Acta Otolaryngol (Stockh) 1960;54:227-32.

4. Karlan MS, Basek M, Potter GB. Intracochlear neurilemoma. Arch Otolaryngol 1972;96:573-5.

5. Huang T-S. Primary intralabyrinthine schwannoma. Ann Otol Rhinol Laryngol 1986;95:190-2.

6. Sataloff RT, Roberts BR, Feldman M. Intralabyrinthine schwannoma. Am J Otol 1988;9:323-5.

7. Scott P. Auditory nerve tumors. J Laryngol Otol 1938;53:772-81.

8. Babin RW, Harker LA. Intralabyrinthine acoustic neurinomas. Otolaryngol Head Neck Surg 1980;88:455-61.

DO COCHLEAR NUCLEI CONTRIBUTE TO AUDITORY LATERALIZATION?

A STEREOLOGICAL EVALUATION OF NEURON NUMBERS

ERDAL AĞAR, PHD
SERIF DEMİR, MSC
ADNAN KORKMAZ, PHD
MUSTAFA AYYILDIZ, PHD
MEHMET BOSNAK, MSC
CAFER MARANGOZ, PHD
SAMSUN, TURKEY

The aim of this study was to estimate the total number of cells in the subdivisions of the cochlear nucleus (CN) of the rat with unbiased stereological methods. The total number of neurons was determined in both the ventral cochlear nucleus (VCN) and the dorsal cochlear nucleus (DCN) to compare the right and left sides. The total cell numbers were 15,280 in the left VCN, 15,400 in the right VCN, 10,260 in the left DCN, and 10,860 in the right DCN. Comparison of the right and left major subdivisions of the CN of the rat showed that there was no significant difference between the right and left sides of the rat CN. This result indicates that the CNs do not contribute to auditory lateralization in the rat in regard to cell numbers.

KEY WORDS — asymmetry, hearing system, rat, stereology.

INTRODUCTION

Asymmetries of the cerebral hemispheres have been reported by many authors as the basis for cerebral dominance.[1-7] These right-left comparisons were established both anatomically and functionally. Despite the fundamental biological importance of the existence of a peripheral lateralization, these studies were mainly centered at the level of the cortical surface.[1-4] There is evidence that the auditory system also possesses peripheral lateralization.[8,9] This has been confirmed by a more recent study of Khalfa and Collet.[10] By studying the activity of the medial olivocochlear efferent system in human subjects, they noted a right ear prevalence of this system in both sexes.

In addition to the need for further physiological investigations to establish such a physiological asymmetry, it is also of interest to know whether the morphological characteristics of cells of certain nuclear structures of the peripheral auditory system are also involved in this lateralization.

One of these structures is the cochlear nucleus (CN), the first relay station of the central auditory pathway, which is situated laterally on the brain stem at the transition of the medulla oblongata and the pons.[11,12] The neuronal architecture and physiological properties of the CN neurons almost certainly play a key role in defining the functional organization of the ascending auditory system.[13,14]

To this end, we have estimated the total neuron number in the 2 major subdivisions of the rat CN with unbiased stereological methods to compare the right and left sides of this part of the peripheral auditory system.

MATERIALS AND METHODS

Eight adult male Wistar rats were anesthetized with an intraperitoneal injection of urethane (1.25 g/kg) and perfused through the left cardiac ventricle with 10% neutral-buffered formalin. Brain stems were dissected out, soaked for a week in the same fixative, and embedded in Paraplast. The CN in each block was cut exhaustively in the coronal plane with a microtome setting of 6 μm. Every 20th and 21st sections were sampled for cell counting and stained with cresyl fast violet. The total number of neurons in the subdivisions of the CN were estimated by the fractionator method.[15]

Definition of Cochlear Nucleus and Its Subdivisions. The total number of neurons was estimated in the 2 major subdivisions of the CN, namely, the ventral cochlear nucleus (VCN) and the dorsal cochlear nucleus (DCN). The granule cells were excluded from the estimates. The cytoarchitectonic characteristics of the VCN, DCN, and cochlear granule cell domains were identified according to the criteria provided by many authors.[16,17]

Fractionator Sampling and Estimates of Total Neuron Number. The basic principle of the fractionator technique has been given elsewhere.[15] This tech-

From the Departments of Physiology (Ağar, Bosnak, Demir, Ayyildiz, Marangoz) and Histology-Embryology (Korkmaz), Medical School, University of Ondokuz Mayis, Samsun, Turkey.

CORRESPONDENCE — Erdal Ağar, PhD, Department of Physiology, Medical School, University of Ondokuz Mayis, 55139 Samsun, Turkey.

nique involves counting particles (neurons) with systematically sampled disectors[18] in a known fraction of the volume of the structure (CN) being analyzed. The total number of particles is estimated by multiplying the total number of counted particles by the reciprocal of the used sampling fractions. The main advantages of using this unbiased estimator are that estimates of the total particle number are not affected by dimensional changes of the tissue caused by histologic procedures and that the section thickness, magnification, area of the disector frame, and volume of the structure of interest need not be known. Provided that the technical requirement for the disector principle (ie, the distance between the section planes of physical disectors should be less than the minimum height of the particles that are to be counted[18]) is satisfied and the sampling is made in a systematic and random fashion, the only parameter that needs to be known for the fractionator is the sampling fraction.[15,19] The following sampling protocol of the CN is based on the study of Pakkenberg and Gundersen.[19]

The first sampled section pair was selected at random from a starting point within the first 20-section interval. Thereafter, every 20th section and its neighbor were sampled and stained. The section sampling fraction (f_1) was therefore $f_1 = 1/20$. Section pairs not containing the CN were discarded. This sampling fraction yielded on average 14 to 15 section pairs per CN.

Comparison of section pairs was achieved by making use of a video recording setup. One section from each section pair was viewed with an Olympus BH-2 microscope and displayed on a monitor at a final magnification of 170× (objective 4×). At this magnification, 1 of the 2 main CNs (ie, the VCN or DCN) was entirely within 1 field of view on the monitor. A test lattice that comprised an unbiased sampling frame of area a (frame) = 15×20 cm^2 that was further subdivided into 100 small rectangles of area 1.5×2 cm^2 was superimposed on the monitor image. Each small rectangle (at 170× magnification) corresponded to the area of the unbiased sampling frame at 1,700× magnification — the magnification at which counting was performed.

The profile area of each subnucleus was also sampled in a uniform, random manner, and thus, an equal probability of being selected was given to all parts of the sectioned profiles of the VCN and DCN that appeared on the sampled sections. This was achieved by counting and selecting fields in the small rectangles at 170× magnification. The selected fields were then displayed at a magnification of 1,700× (objective 40×) and stored on a videotape. The coordinates of the selected fields at 170× magnification, as well as landmarks like blood vessels and edges of the nuclei, were recorded before they were stored. This facilitated location of the corresponding field in the other section. Counting of fields at the lower magnification was made in a zigzag way and started with the first field in which more than half of the rectangle was filled. Fields not filling more than half of the rectangle were considered outside. Starting randomly, we selected and recorded every fifth field. Consequently, the areal sampling fraction, f_2, was $f_2 = 1/5$.

These consecutive images were then played back as sequential frozen frames on another monitor while the microscope images of their corresponding fields on the other section were displayed on the first monitor. Counting of neuronal nuclei with the disector principle were made at this stage. The small rectangles inside the unbiased sampling frame that were used for sampling fields at the lower magnification are now (at the higher magnification) further help in locating neuronal nuclei. The images on these 2 monitors (1 from the microscope and the other from the video) were used as a disector pair.[18] All profiles of neuronal nuclei of any size sampled in the unbiased sampling frame[20] on the first section but missing from the second section were counted. Cells classified as neurons ranged in morphology from those having a large euchromatic nucleus surrounded by a clearly defined cytoplasm containing Nissl bodies and exhibiting some emerging dendritic processes to those having only a thin rim of cytoplasm but still with a clear nucleus. All other profiles that could not be classified as neurons on these paraffin sections were considered to be glial or small granule cells and were therefore not counted. These excluded profiles appeared as dense bodies or cells with a small heterochromatic nucleus with no visible cytoplasm around it. This setup for viewing section pairs simultaneously provided results equal to those achieved by 2 projection microscopes.[19] The number of counted nuclei was designated ΣQ^-. The total number of nuclei, N, in each subnucleus was estimated from the equation $N = \Sigma Q^- \times 1/f_1 \times 1/f_2$.

The above-mentioned magnifications and sizes of the counting frame and rectangles are given only for descriptive purposes, since it is not necessary to make absolute measurements when using the fractionator. The sampling fractions used were based on a pilot study. On average, 100 and 150 nuclei were counted in each DCN and VCN, respectively, which provided a number estimate with a coefficient of error (CE) of 5%.

Statistics. Differences between the total number

TOTAL NUMBER OF NEURONS IN RAT COCHLEAR NUCLEUS FROM EIGHT ANIMALS

Region	*N*	*CE*	*CV*
Right VCN	15,400	0.042	0.060
Left VCN	15,280	0.041	0.069
Right DCN	10,860	0.049	0.165
Left DCN	10,260	0.054	0.132

N — total number of nuclei, CE — coefficient of error, CV — coefficient of variation, VCN — ventral cochlear nucleus, DCN — dorsal cochlear nucleus.

of neurons (N) in each subdivision of the right and left CNs were examined with a paired Student's *t*-test.

To assess the appropriateness of the sampling scheme employed, the observed relative variance of the estimates of N in each group (ie, the CV^2 of N of the VCN and DCN on the right and left) and the relative variance of the estimate made in the individuals (ie, the CE^2) were calculated and evaluated in a stereological context.[19,21] The group means and their coefficient of variation (CV) for N were calculated separately for each subdivision on either side. The CE, which expresses the precision of the estimates of N, was calculated with the quadric approximation formula.[19]

RESULTS

The means of the total number of neurons were determined in both the VCN and DCN to compare the right and left sides of the CN. The total cell number was 15,280 in the left VCN and 15,400 in the right VCN, and there was no statistical difference between the left and right VCNs ($p > .05$). The total cell numbers were 10,260 and 10,860 in the left and right DCNs, respectively. There was also no statistical difference between the left and right DCNs ($p > .05$). The means of the total number of neurons of the VCN and DCN along with their CE and CV are summarized in the Table.

The CEs for the individual estimates of the 2 subdivisions on both sides ranged between 0.0041 and 0.054 (mean CE = 0.048). This evidence suggests that very reliable estimates were obtained ($CE \leq 0.05$). The observed interanimal CV for the VCN and DCN varied from 0.06 to 0.165 (mean CV = 0.11). For each of the 2 cochlear subdivisions of the right and left sides, the observed mean variance of the estimates of N made in the individuals (CE^2) was less than half of the observed variance of the group (CV^2). The CE^2/CV^2 is 0.19, indicating that approximately 80% of the group variances arose from true interanimal differences (biological differences) and that the overall sampling scheme employed is appropriate.

DISCUSSION

Anatomic and physiological studies describe specific connections between the CNs and other higher auditory centers.[14,22,23] Anatomic and physiological asymmetries are found in the hearing system.[8-10,24] Considering the anatomic asymmetries established at the cortical surface, it seems logical to expect similar findings in subcortical structures. This study reports unbiased estimates of the total number of neurons of the 2 subdivisions of the rat CN. The stereological technique used for counting is unaffected by the methodological biases that have been reported for previously available methods. (See West,[21] Coggeshall,[25] and Coggeshall and Lekan[26] for detailed recent discussions of the stereological and previously available methodologies.) In addition, this study provides information about the variances of the individuals and group estimates of the total number of neurons in the VCN and DCN. The total cell number was 15,280 in the left VCN and 15,400 in the right VCN, and there was no statistical difference between the left and right VCNs ($p > .05$). The total cell numbers were 10,260 and 10,860 in the left DCN and the right DCN, respectively. There was also no statistical difference between the left and right DCNs ($p > .05$). To our knowledge, this is the first time such information has been reported, and this may clearly indicate that the CNs do not contribute to auditory lateralization in regard to cell number. A corresponding finding has been reported for the human medial superior olivary nucleus,[27] in which the average numbers of neurons in the right and left columns were similar. Based on physiological measurements of the olivocochlear system, however, a statistically greater right-side activity among 44 young subjects has been reported.[10] Although these findings do not negate the importance of the existent interplay between regional morphometric characteristics and accompanied functional outcomes (eg, neuropathologic states, in which the total number of neurons of related structures is significantly reduced and functional asymmetries accompanied regional morphological asymmetries), they provide a further experimental rationale for the development and design of future electrophysiological settings and more rigorous stereological studies.

In this study, the means of group estimates of neuron number differ by 0.8% in the VCN and by 5.5% in the DCN. By using an unbiased estimator, the fractionator, and the paired *t*-test, we have failed to detect significant differences in the total number of neurons between the right and left sides of the 2 subdivisions. Though the precision of the individual estimates of the total number of neurons is very sensitive ($CE \leq 0.05$) in demonstrating that no lateral dif-

ferences with regard to N exist, new insights into the relationship between functional and morphological asymmetries might be obtained on smaller margins with a higher degree of precision. Since the major factor contributing to the observed relative variance for the group in this study is the inherent biological variance in the individual rats, the most efficient way to produce an increase in the precision of the group mean would be by increasing the number of rats in the groups.

CONCLUSION

The rationale behind this study was twofold. First, quantitative morphological data are a prerequisite to understanding the structural basis of functions,[6] and only the recently founded unbiased methodology has the power of producing such data reliably.[21,26] Second, morphological laterality studies of the CN subdivisions can provide valuable information as to the contribution of certain parameters (eg, volume, size, number) to the functional auditory lateralization. The quantitative analysis of the CN neurons presented is a necessary baseline for studying further the biological substrates for functional lateralization.

The presented results show that although the CN does not contribute to auditory lateralization in regard to cell number, the CN probably does contribute to it functionally, since the function of a nucleus is the result of interaction of many factors such as the number of synapses, neural circuits, dendritic fields, ionic mechanisms, and intrinsic electrical properties of neurons. However, the cellular events that take place during neuronal processing within the CN and the exact role of neurons in acoustic processing are poorly understood.[28,29] These will need to be further investigated electrophysiologically. A remaining point of uncertainty concerns the possible roles of other factors such as the size, volume, and connectivity pattern of the CN. It will also be necessary to conduct further studies on other nuclei belonging to the auditory system, because the development of each nucleus of the auditory system might be affected, organized, and completed by the other nuclei.

REFERENCES

1. Weis S, Haug H, Holoubek B, Örün H. The cerebral dominances: quantitative morphology of the human cerebral cortex. Int J Neurosci 1989;47:165-8.

2. Dowling GA, Diamond MC, Murphy GM, Johnson RE. A morphological study of male rat cerebral cortex asymmetry. Exp Neurol 1982;75:51-67.

3. Kolb B, Sutherland RJ, Nonnemann AJ, Whishaw IW. Asymmetry in the cerebral hemispheres of the rat, mouse, rabbit, and cat: the right hemisphere is larger. Exp Neurol 1983;78: 348-59.

4. Sherman GF, Galaburda AM, Geschwind N. Neuroanatomical asymmetries in non-human species. Trends Neurosci 1982;12:429-31.

5. Denenberg VH. Hemispheric laterality in animals and the effects of early experience. Behav Brain Sci 1981;4:1-49.

6. Rosen GD, Sherman GF, Galaburda AM. Biological substrates of anatomic asymmetry. Prog Neurobiol 1992;39:507-15.

7. Wildgruber DH, Ackermann H, Klose U, Kardatzki B, Grodd W. Functional lateralization of speech production at primary motor cortex: a fMRI study. Neuroreport 1996;7:2791-5.

8. Kimura D. The asymmetry of the human brain. Sci Am 1973;228:70-8.

9. Divenyi PL, Robinson AJ. Nonlinguistic auditory capabilities in aphasia. Brain Lang 1989;37:290-326.

10. Khalfa S, Collet L. Functional asymmetry of medial olivocochlear system in humans.Towards a peripheral auditory lateralization. Neuroreport 1996;7:993-6.

11. Lorente de No R. The primary acoustic nuclei. New York, NY: Raven Press, 1981.

12. Osen KK. Cytoarchitecture of the cochlear nuclei in the cat. J Comp Neurol 1969;136:453-83.

13. Harrison JM, Irving R. Ascending connections of anterior ventral cochlear nucleus in the rat. J Comp Neurol 1966; 126:51-64.

14. Warr WB. Parallel ascending pathways from the cochlear nucleus: neuroanatomical evidence of functional specialization. Sens Physiol 1983;7:1-38.

15. Gundersen HJG. Stereology of arbitrary particles. A review of unbiased number and size estimators and the presentation of some new ones, in memory of William R. Thompson. J Microsc 1986;143:3-45.

16. Muganini E, Osen KK, Dahl AL, Fredrich VL Jr, Kort G. Fine structure of granule cells and related interneurons (termed Golgi cells) in the cochlear nucleus complex of cat, rat and mouse. J Neurocytol 1980;9:537-70.

17. Osen KK. Course and termination of the primary afferents in the cochlear nuclei of the cat. Arch Ital Biol 1970;108: 21-51.

18. Sterio DC. The unbiased estimation of number and sizes of arbitrary particles using the disector. J Microsc 1984;134: 127-36.

19. Pakkenberg B, Gundersen HJG. Total number of neurons and glial cells in human brain nuclei estimated by the disector and the fractionator. J Microsc 1988;150:1-20.

20. Gundersen HJG. Notes on the estimation of the numerical density of arbitrary profiles: the edge effect. J Microsc 1977; 111:219-23.

21. West MJ. New stereological methods for counting neurons. Neurobiol Aging 1993;14:275-85.

22. Kane EC, Conlee JW. Descending inputs to the caudal cochlear nucleus of the cat: degeneration and autoradiographic studies. J Comp Neurol 1979;187:759-84.

23. Kane EC, Finn RC. Descending and intrinsic inputs to dorsal cochlear nucleus of cats: a horseradish peroxidase study. Neuroscience 1977;2:897-912.

24. Previc FH. A general theory concerning the prenatal ori-

gins of cerebral lateralization in humans. Psychol Rev 1991;98: 299-334.

25. Coggeshall RE. A consideration of neural counting methods. Trends Neurosci 1992;15:9-13.

26. Coggeshall RE, Lekan HA. Methods for determining numbers of cells and synapses: a case for more uniform standards of review. J Comp Neurol 1996;364:6-15.

27. Nara T, Goto N, Shin-Ichiro H, Okada A. Development of the human medial superior olivary nucleus: a morphometric study. Early Hum Dev 1994;40:13-21.

28. Edelman GM, Gall WE, Cowan WM. Auditory function, neurobiological bases of hearing. New York, NY: John Wiley & Sons, 1988.

29. Ağar E. Electrophysiological properties of cochlear nucleus neurones [Thesis]. Newcastle upon Tyne, England: University of Newcastle upon Tyne, 1992.

≈

XVI IBERO-AMERICAN CONGRESS OF NEUROLOGY

The XVI Ibero-American Congress of Neurology will be held in Rosario, Argentina, April 16-19, 2000. For information, contact Soledad Piuma, Congresos Internacionales, Moreno 584, 9P, Buenos Aires, Argentina; fax 54 11 3310223; e-mail spiuma@congresosint.com.ar.

Ann Otol Rhinol Laryngol 108:1999

RESULTS OF PARTIAL LARYNGECTOMY FOR BENIGN NEURAL TUMORS OF THE LARYNX IN CHILDREN

ERÉA-NOËL GARABÉDIAN, MD
PARIS, FRANCE
DENIS AYACHE, MD
PARIS, FRANCE
VINCENT DUCROZ, MD
PARIS, FRANCE
JEAN MICHEL TRIGLIA, MD
MARSEILLE, FRANCE

The objective of this study was to assess the long-term results of partial laryngectomy for benign neural tumors of the larynx. We reviewed 8 patients with laryngeal involvement — 7 with neurofibromatosis and 1 without — treated between 1980 and 1994. The mean age was 6.5 years. A partial laryngectomy was performed in 7 cases. All the tumors were located in the aryepiglottic folds. Clinical, radiologic, and endoscopic follow-ups were used for evaluating recurrence. A good laryngeal airway, swallowing without aspiration, and voice quality were sought in assessing the functional results. Five patients had good functional results with no recurrences. One patient died of malignant transformation and metastatic dissemination of his disease. To summarize, partial laryngectomy is a relatively safe and effective procedure, even in childhood, for treating this rare localization of neurofibromatosis. A malignant transformation of the tumor is possible and carries a poor prognosis.

KEY WORDS — child, laryngeal neurofibroma, neurofibromatosis, partial laryngectomy.

INTRODUCTION

Benign neural tumors of the larynx are rare. Approximately 100 childhood and adult cases were reported in one review,[1] and 18 childhood cases in another.[2] There are 3 main histologic types of tumor: schwannoma, neurofibroma, and plexiform neurofibroma. These tumors may occur in isolation or may be associated with neurofibromatosis. The aim of this study was to assess the results of partial laryngectomy in these types of tumors. The problem of malignant transformation of the tumors is also dealt with.

PATIENTS AND METHODS

This report is a retrospective review of 8 children between 2 months and 13 years of age, with a diagnosis of neural tumors involving the larynx, who were admitted to 2 tertiary-care centers between 1980 and 1994, namely, the otolaryngology departments of Armand-Trousseau Children's Hospital in Paris and La Timone Children's Hospital in Marseille. Data included sex, age at diagnosis, family history, presenting symptoms, site of the tumors, pathological diagnosis, treatment, recurrences, and functional results.

Approaches were employed similar to those used for pharyngolaryngeal surgery, such as a supraglottic hemipharyngolaryngectomy. All procedures were performed under general anesthesia with the patient ventilated via an endotracheal tube (or via the tracheotomy cannula, in those patients tracheotomized preoperatively). In all cases except 1 (patient 8), a lateral pharyngotomy was performed with a skin incision along the anterior border of the sternocleidomastoid muscle, localization and incision of the perichondrium of the posterior edge of the thyroid lamina, and scrapping of the pyriform fossa. The tumor mass was located at the level of the cricothyroid membrane and sometimes extended to the carotid sinus. Thus, the pharynx was opened at a distance from the tumor, at the level of the homolateral vallecula. The tumor was excised in a stepwise fashion, always including resection of the homolateral arytenoid and the aryepiglottic fold. Depending on the degree of spread of the tumor, the resection was sometimes extended to include the contralateral arytenoid, part of the homolateral thyroid lamina, and part of the epiglottis. Closure was achieved by suturing the pharyngeal mucosa to a musculoperichondrial flap.

The occurrence of relapse was verified by endoscopic examination under general anesthesia and, in more recent cases, by a computed tomography (CT) scan. The quality and the caliber of the laryngeal airway were assessed clinically during spontaneous breathing at rest, on effort, and during sleep, as well as during the postoperative endoscopies. Aspiration was assessed indirectly by regular clinical examina-

From the Department of Pediatric Otolaryngology, Armand-Trousseau Children's Hospital, Paris (Garabédian, Ducroz, Ayache), and the Department of Pediatric Otolaryngology, La Timone Children's Hospital, Marseille (Triglia), France.

CORRESPONDENCE — Eréa-Noël Garabédian, MD, ENT and Cervicofacial Surgery Department, Armand-Trousseau Children's Hospital, 26 avenue du Dr Netter, 75012 Paris, France.

TABLE 1. CLINICAL FEATURES

Patient No.	Age	Sex	Presenting Symptoms	NF	Family History of NF	Tumor Site	Histopathology
1	6 y	M	Stridor, dyspnea	Type I	Yes	R aryepiglottic fold, R false vocal cord	Neurofibroma
2	4 y	M	Respiratory distress	Type I	No	R aryepiglottic fold, R arytenoid, posterior commissure, L arytenoid	Plexiform neurofibroma
3	2 mo	F	Stridor, dyspnea	Type I	Yes	R aryepiglottic fold	Plexiform neurofibroma
4	2 y	F	Stridor during sleep	Type I	No	R aryepiglottic fold	Plexiform neurofibroma
5	13 y	F	Dyspnea, dysphagia	Type II	No	L aryepiglottic fold, L false vocal cord	Antoni B neurilemoma
6	5 y	M	Change in voice, dyspnea	No	No	R aryepiglottic fold	Antoni A neurilemoma
7	18 mo	M	Stridor, dyspnea	Type I	No	R aryepiglottic fold, R false vocal cord, posterior commissure, L arytenoid, retrocricoid area	Plexiform neurofibroma
8	10 y	F	Dyspnea on exertion	Type I	Yes	R pyriform fossa, R vallecula	Neurofibroma

NF — neurofibromatosis.

tion for inhalation pneumopathies. Some patients had cineradiographic swallowing studies performed. Vocal outcome was assessed by a phoniatrician using recorded material.

RESULTS

The various clinical and histologic data of the 8 patients are shown in Table 1. Seven patients had associated neurofibromatosis (6 type I, 1 type II). The patient without neurofibromatosis was included in the study because the evolution of his disease raises the question of malignant transformation of these tumors. Computed tomography was performed in 4 patients. Nuclear magnetic resonance imaging was carried out in 3 patients. All the data regarding surgical interventions are listed in Table 2. The median age at the time of operation was 5.36 years. As in patient 8, when the symptoms are not severe and complete excision is impossible, conservative treatment is proposed.

There was no perioperative mortality. The median time to restarting oral food intake and removal of the nasogastric feeding tube was 12.5 days. All patients who underwent surgery were able to eat and swallow without any significant aspiration, as indicated by the absence of any pulmonary disorders. In 3 patients, swallowing cineradiography confirmed the absence of aspiration. The vocal quality of the 6

TABLE 2. TREATMENT

Patient No.	Early Tracheotomy	Tracheotomy During Surgery	Surgical Approach	Pathological Margins	Time to Decannulation	Time to Oral Intake	Follow-up
1	No	Yes	Lateral pharyngotomy, right supraglottic hemipharyngolaryngectomy	Involved	3 d	18 d	1 y 1 mo
2	Yes		Lateral pharyngotomy, right supraglottic hemipharyngolaryngectomy extended to left arytenoid, right thyroid cartilage resection	Involved	40 mo	12 d	9 y 6 mo
3	No	No	Lateral pharyngotomy, right supraglottic hemipharyngolaryngectomy	Unknown		10 d	5 y 4 mo
4	Yes		Lateral pharyngotomy, right supraglottic hemipharyngolaryngectomy	Free	13 d	13 d	1 y
5	No	No	Lateral pharyngotomy, left supraglottic hemipharyngolaryngectomy	Unknown		10 d	5 y 5 mo
6	No	No	Thyrotomy, right supraglottic hemipharyngolaryngectomy	Unknown		10 d	12 y
7	Yes		Lateral pharyngotomy, right supraglottic hemipharyngolaryngectomy	Involved		15 d	3 y

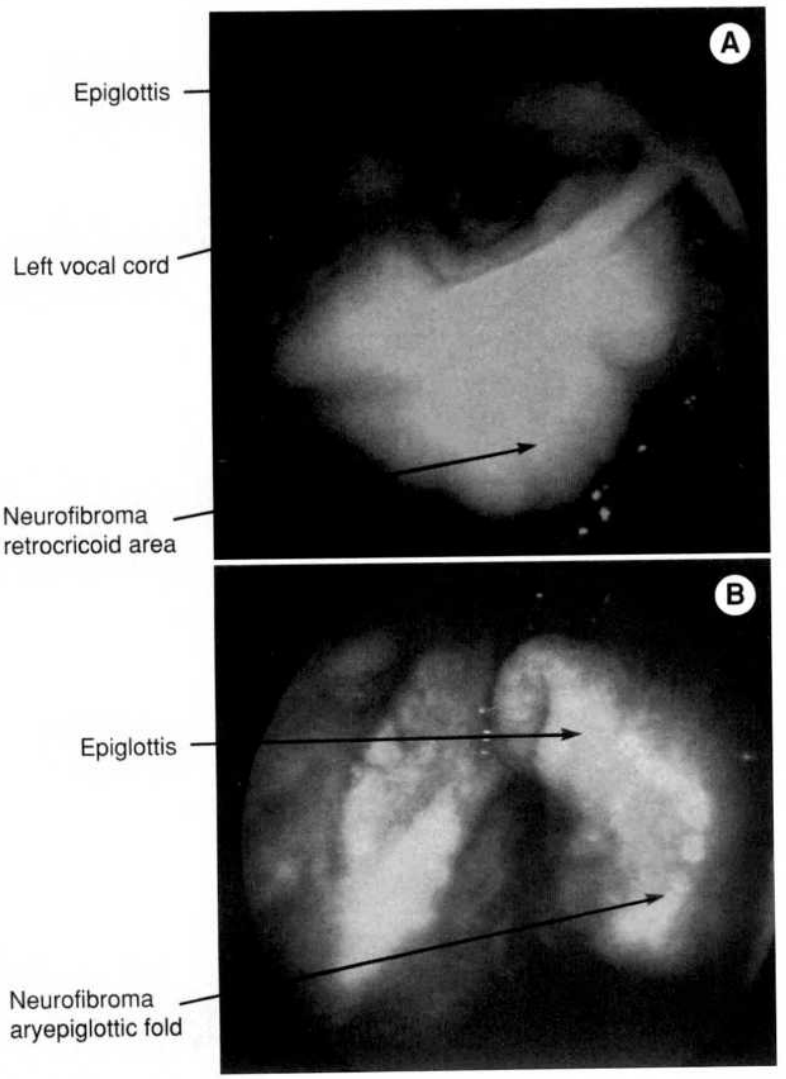

Endoscopic views of laryngeal neurofibromas. A) Patient 7. B) Patient 3.

patients who could be decannulated was satisfactory, with a socially acceptable voice. The 3 patients operated on without a previous tracheotomy were able to be extubated 24 hours after surgery. Three of the 4 patients who were tracheotomized, either preoperatively or perioperatively, were able to be decannulated: patient 1 on day 3; patient 4 on day 13; and patient 2 at 40 months after the operation, due to stenosis of the vestibule of the larynx that necessitated a laryngoplasty with restoration of the luminal caliber. This procedure, which allowed decannulation of the patient, was only carried out after ensuring that there was no evidence of tumor recurrence. Patient 7 could not be decannulated despite 2 attempts at relieving the laryngeal obstruction and potassium titanyl phosphate (KTP) laser treatment. The patient had a residual neurofibroma of the postcricoarytenoid region that could only be operated on externally by performing a total laryngectomy (see Figure, A). Patient 8 was not operated on, since her respiratory symptoms only consisted of laryngeal dyspnea on exertion. Moreover, the extent of the cervical neurofibromas was such that total resection was impossible without significant postoperative morbidity. Five of the 7 patients who had surgery have not had any tumor recurrence, with an average postoperative follow-up of 5.5 years.

Five years after excision of a schwannoma of the left aryepiglottic fold, patient 6 presented with a recurrence of the tumor at the same site. A supraglottic hemipharyngolaryngectomy was performed in 1984, and the histology demonstrated a highly cellular, malignant schwannoma with a high mitotic index. Despite further surgery in 1989, followed by external cervical radiotherapy of 65 Gy, the patient died in March 1991 of a cervicomediastinal extension of the tumor and of pulmonary metastases. Patient 7, having had a right supraglottic hemipharyngectomy in 1992, has presented again with a relapse of his tumor in the left postcricoarytenoid region. This recurrence is not amenable to partial laryngectomy and is currently being controlled by courses of KTP laser treatment.

DISCUSSION

Friedrich von Recklinghausen is credited with introducing the term neurofibromatosis in 1882. There are 2 distinct types of neurofibromatosis: neurofibromatosis type I is the peripheral form, also called von Recklinghausen's disease. It is transmitted as an autosomal dominant trait and occurs in approximately 1 in 4,000 live births. The genetic defect has been localized to the proximal long arm of chromosome 17. The diagnosis of neurofibromatosis type I requires the presence of 2 or more of the following[3]: 1) more than 6 café au lait spots (prepubertal diameter >0.5 cm, postpubertal diameter >1.5 cm), 2) 2 neurofibromas or 1 plexiform neurofibroma, 3) axillary or inguinal freckling, 4) optic glioma, 5) sphenoid dysplasia or thinning of the long bones with or without pseudoarthrosis, or 6) 2 or more Lisch (iris) nodules.

Diagnosis is usually made before the age of 10 (50%).[4] Von Recklinghausen's disease may occur with a negative family history in up to 50% of cases. Neurofibromatosis type II is distinct from type I and is characterized by central lesions, specifically bilateral acoustic neurinomas. It is also transmitted as an autosomal dominant trait and occurs in approximately 1 in 50,000 live births. Molecular genetic studies have localized the genetic abnormality near the center of the long arm of chromosome 22. Neurogenic tumors arising primarily from the larynx are rare. A survey of neurilemoma and neurofibroma cases in the literature showed that more than 100 cases have been reported.[1] These tumors are most commonly reported as occurring in association with neurofibromatosis, but can also occur without neurofibromatosis.

Schwannoma or neurilemoma, a solitary and encapsulated tumor, was originally called neurinoma. In a retrospective study of neurogenic tumors of the larynx over the 80-year period from 1907 to 1986, Stanley et al[5] reported 7 cases of schwannoma. An association with neurofibromatosis is very rare[1] but nevertheless possible,[6,7] as seen in the histology of patient 5. In general, these tumors remain benign, and their possible malignant transformation is very exceptional.[8,9]

Two cases of schwannoma are reported in this series of patients. The first case (No. 5) occurred in a female patient presenting with neurofibromatosis type II, with bilateral acoustic neurinomas, meningioma of the posterior fossa, and schwannomas of the cauda equina. According to Costantino et al,[7] schwannomas seem to be most frequently associated with neurofibromatosis type II, rather than with type I. The second patient (No. 6) presented without similar manifestations of neurofibromatosis. Neurofibroma and plexiform neurofibroma are the 2 other main histologic types of neural tumors of the larynx. Neurofibroma is most frequently localized in the laterocervical region (patient 8), and localization restricted to the larynx is rare. In 1987, Fukuda et al[1] recorded 57 cases of laryngeal neurofibroma reported in the literature. Eighteen cases of laryngeal neurofibroma in children have also been documented.[2] Nonplexiform neurofibroma may present as a solitary lesion or in association with neurofibromatosis type I. Plexiform neurofibroma, however, is much more specific for von Recklinghausen's disease. These 2 types of neurofibroma, nonplexiform and plexiform, differ in their cellular architecture, and plexiform neurofibroma has a greater tendency to infiltrate adjacent tissues.

The clinical presentation of these tumors is fairly stereotypical. These tumors affect the supraglottic region of the larynx, specifically the aryepiglottic fold and the arytenoid, in 50% to 80% of cases.[1,10] The predominant localization in the inlet of the larynx is also found in our series, with the aryepiglottic fold being affected in 7 of our 8 cases (see Figure, B). This localization of the tumor suggests that it originates from the superior laryngeal nerve and/or from the anastomoses between the superior laryngeal nerve and the recurrent laryngeal nerve (Galen's anastomosis).[11]

Bilateral involvement of the inlet of the larynx is possible, as observed in 2 cases in our series (Nos. 2 and 7). Such bilateral involvement makes surgical excision and postoperative care more difficult. A subglottic site has also been described in approximately 5% of cases.[1]

In this series, the average age at diagnosis was 5 years (range 2 months to 13 years), which is the same as that published in the literature (4.5 years).[1] The symptomatology in children is essentially marked by signs of respiratory obstruction (stridor, inspiratory dyspnea, respiratory distress), sometimes leading to an early tracheotomy. In our series, early tracheotomy had to be carried out in 3 cases. Out of 9 cases of childhood laryngeal neurofibromatosis,[1] an early tracheotomy was performed in 50% of cases.

The radiologic features of CT scanning in our series are the same as those described in the literature.[12] The tumors presented as rounded or oval, clearly delineated masses. They were hypodense as compared to muscle, and the injection of a contrast material made little (increased) or no difference to the density. On T1-weighted magnetic resonance imaging (MRI), the tumors were isointense, whereas on T2-weighted MRI, they were hyperintense. The role

of MRI lies, above all, in its ability to clearly define the limits of the tumor. In plexiform neurofibroma, it allows assessment of the extent of the infiltration.[13]

The treatment of these tumors by surgery is difficult. Indeed, the infiltrative and microinvasive nature of neurofibroma, especially plexiform neurofibroma, makes total resection difficult, and even impossible in some cases.[4,14] The treatment must therefore take into consideration the severity of the symptoms and the surgical options available while preserving laryngeal function. When the symptoms are not severe and complete excision is impossible, as in patient 8, conservative treatment is advisable. An exclusively endoscopic approach can be considered when dealing with a pedunculated tumor of limited extent. Out of 57 cases of laryngeal neurofibroma,[1] endoscopic treatment, with or without the use of laser ablation, was performed in 37 cases. In our patients, endoscopic excision as the sole form of treatment was impossible because of the extensive infiltration of surrounding tissues by the tumors. However, in patient 7, laser therapy was used to control residual tumor deposits and thus avoid a total laryngectomy, which was the only measure that would have allowed the complete resection of the tumor. Sidman et al[14] also used laser treatment to relieve laryngeal obstruction as a palliative measure in order to avoid a total laryngectomy. No series have compared the rate of relapse following endoscopic excision with that following open surgery. Nevertheless, it seems probable that endoscopic surgery might not be able to achieve a complete resection of a tumor that has spread deep along the superior laryngeal nerve fibers. Various open surgical approaches have been put forward. A median approach using a laryngofissure seems to be the most widely used (11 of 57 adults; 50% in children).[1] Although, at the glottic level, a good field of view can be achieved, this incision may not be sufficient for visualization of the laryngeal inlet. Therefore, we prefer a lateral pharyngotomy. It allows easy access to the inlet, the vestibule of the larynx, and the pyriform fossa. Thus, a partial laryngectomy — that is, a supraglottic hemipharyngolaryngectomy — can be performed by closely following the tumor margins. When the tumor does not cross the midline and is localized to the aryepiglottic fold and to the arytenoid, this approach allows a partial laryngectomy to be carried out with only minor complications.

Tracheotomy was not performed systematically, and was not performed in patients 3, 5, and 6. In these cases, it was possible to extubate the patient rapidly. When tracheotomy was required early on because of the severity of the dyspnea, it was possible to decannulate the patient shortly after partial laryngectomy (patients 1 and 4).

The postoperative consequences are more serious when the lesion crosses the midline and involves the contralateral section of the laryngeal inlet and vestibule. Thus, for patient 2, a complete excision without recurrence was complicated by a stenosis of the laryngeal vestibule. Decannulation could only be performed after a laryngeal reconstruction with restoration of the luminal caliber, more than 3 years after surgery, and only after ensuring that there was no evidence of tumor recurrence. In patient 7, resection was incomplete, with residual tumor deposits in the contralateral arytenoid and postcricoid area that were controlled by KTP laser treatment. Currently, the diameter of the laryngeal passage is stable, and the patient can breathe and talk with the tracheotomy cannula occluded. Decannulation is now possible and will be performed soon. In these 2 cases, however, total laryngectomy was avoided. Like Maisel and Ogura,[15] we prefer to incompletely excise a benign tumor rather than impose the mutilation of a total laryngectomy.

The indications for partial laryngectomy remain exceptional in pediatric laryngology, and the functional results of such interventions and the outcome with respect to the tumor have not been detailed in the literature. Apart from benign neural tumors of the larynx, we have performed this type of surgery in 2 children with cervical cystic hygroma that had spread to the aryepiglottic fold but not to the base of the tongue. In these 2 cases, the functional outcome was good and decannulation was possible.

Close and prolonged medical supervision of these patients is needed. Indeed, the malignant transformation of a benign neural tumor of the larynx into a malignant schwannoma can compromise the prognosis. Malignant schwannoma may arise from Schwann cells, but an etiologic origin from perineurial fibroblasts has also been proposed.[16] A causal relationship between neurofibromatosis type I and malignant schwannoma has been described. The incidence of these tumors in von Recklinghausen's disease varies between 5% and 15%.[6,10,16] However, no such causal relationship exists between neurofibromatosis type II and malignant schwannoma.[7] Malignant transformation must be suspected in the face of a rapid increase in the volume of the neurofibroma and of the onset of pain. The tumor is nonencapsulated, locally aggressive, and infiltrates adjacent tissues.[16] Regional lymph node involvement is not usual, although hematogenous metastases may occur, primarily to the lungs. The treatment consists of wide surgical excision followed by radiotherapy. The prog-

nosis is poor, and the 5-year survival rate is between 19% and 50%.[4] The survival rates are better in well-differentiated, as opposed to undifferentiated, forms.[17] The prognosis is also poor in malignant schwannoma associated with von Recklinghausen's disease.[16]

The case of patient 6 suggests either an association between neurinoma and malignant schwannoma or a malignant transformation of the neurinoma. In fact, the malignant transformation of schwannoma is rare.[6,18] This patient did not present with associated neurofibromatosis, and in addition, the delay between the first resection and the relapse of the tumor was quite long (5 years).

Therefore, the possibility of a malignant transformation of these benign neural tumors of the larynx requires a prolonged clinical, endoscopic, and radiologic follow-up.

CONCLUSION

The majority of neural benign tumors of the larynx in childhood are neurofibromas, although neurinomas may also occur. Both of these tumors can arise in association with neurofibromatosis or in isolation. Surgical excision by partial laryngectomy allows local control of unilateral, supraglottic tumors and provides good functional results, as well as satisfactory treatment of the tumor. In cases in which complete clearance of the tumor would require a total laryngectomy, we prefer instead a partial laryngectomy with KTP or carbon dioxide laser therapy for the tumor remnants. Finally, long-term follow-up is essential in view of the possibility of malignant transformation, which carries a poor prognosis.

REFERENCES

1. Fukuda I, Ogasawara H, Kumoi T, Sugihara K, Wada H. Subglottic neurofibroma in a child. Int J Pediatr Otorhinolaryngol 1987;14:161-70.

2. Greinwald J, Derkay G, Schechter G. Management of massive head and neck neurofibromas in children. Am J Otolaryngol 1996;17:136-43.

3. Willcox T-O Jr, Rosenberg S-I, Handler S-D. Laryngeal involvement in neurofibromatosis. Ear Nose Throat J 1993;72: 811-2.

4. White AK, Smith RJH, Bigler CRR, Schauer PR. Head and neck manifestations of neurofibromatosis. Laryngoscope 1986;96:732-7.

5. Stanley RJ, Scheithauer BW, Weiland LH, Neel HB III. Neural and neuroendocrine tumors of the larynx. Ann Otol Rhinol Laryngol 1987;96:630-8.

6. Holt G-R. E.N.T. manifestations of von Recklinghausen's disease. Laryngoscope 1978;88:1617-32.

7. Costantino PD, Friedman CD, Pelzer HJ. Neurofibromatosis type II of the head and neck. Arch Otolaryngol Head Neck Surg 1989;115:380-3.

8. Das Gupta TK, Brasfield RD, Strong EW, Hadju SI. Benign solitary schwannomas (neurilemmomas). Cancer 1969;24: 355-66.

9. Russel DS, Rubinstein LJ. Pathology of tumors of the nervous system. London, England: Edward Arnold, 1959:242-80.

10. Garabédian E-N, Riviere F, Cotin G, Menard M. Localisations laryngées de la maladie de Recklinghausen. Ann Pediatr (Paris) 1987;34:443-6.

11. Czinger J, Fekete-Szabo G. Neurofibroma of the supraglottic larynx in childhood. J Laryngol Otol 1994;108:156-8.

12. Stines J, Roode A, Carolus J-M, Perrin C, Becker S. CT findings of laryngeal involvement in von Recklinghausen disease. J Comput Assist Tomogr 1987;11:141-3.

13. Martin D-S, Stith J, Awwad E-E, Handler S. MR in neurofibromatosis of the larynx. AJNR Am J Neuroradiol 1995; 16:503-6.

14. Sidman J, Wood RE, Poole M, Postma DS. Management of plexiform neurofibroma of the larynx. Ann Otol Rhinol Laryngol 1987;96:53-5.

15. Maisel RH, Ogura JH. Neurofibromatosis with laryngeal involvement. Laryngoscope 1974;84:132-40.

16. Jackson RM, Rice DH, Crockett DM. Malignant schwannoma of the cervical vagus nerve in a patient with neurofibromatosis. Otolaryngol Head Neck Surg 1986;94:641-4.

17. Conley JJ. Neurogenic tumors of the head and neck. J Otolaryngol Soc Aust 1973;3:362-8.

18. Lebreton E, Merle M, Maneaud M, Foucher G, Schwartz N, Michon J. Les schwannomes des nerfs périphériques. Leurs localisations et leurs traitements. Ann Chir Plast Esthet 1985;30: 309-15.

EXTRACAPSULAR SPREAD AND DESMOPLASTIC PATTERN IN NECK LYMPH NODES: TWO PROGNOSTIC FACTORS OF LARYNGEAL CANCER

MARIA P. PRIM, MD
ROSARIO MADERO, MD
JUAN I. DE DIEGO, MD
MANUEL NISTAL, MD
DAVID HARDISSON, MD
JAVIER GAVILÁN, MD
MADRID, SPAIN

The influence of extracapsular spread (ECS) and a desmoplastic pattern (DP) of metastatic cervical lymph nodes in patients with laryngeal cancer is presented. The study includes 128 patients surgically treated between 1984 and 1992 for squamous cell carcinoma of the larynx with pathologically proven lymph node metastasis. The results were studied from 2 major standpoints: survival and recurrence. The 3-year survival rates were as follows: patients without ECS 73.4%, and with ECS 28.9% ($p < .001$); patients without a DP 76.9%, and with a DP 43.3% ($p < .03$). Also, the 3-year recurrence rates in the neck showed significant differences: patients without ECS 10.7%, and with ECS 49.6% ($p < .001$); patients without a DP 10%, and with a DP 31.6% ($p = .1142$). Postoperative radiotherapy did not appear to improve the outcome.

KEY WORDS — desmoplastic pattern, extracapsular spread, laryngeal cancer, lymph node metastasis, prognostic factors.

INTRODUCTION

There is general agreement that the stage of laryngeal carcinoma at the time of therapy is the most important identifiable factor in predicting prognosis. In staging systems, neck metastasis is an adverse prognostic factor with greater impact on prognosis than the characteristics of the primary tumor.

However, all otolaryngologists have observed in their clinical practice that comparably staged patients with histologically positive nodes frequently have a diverse clinical course and response to similar treatment. The reasons for this can be other features of the patient's disease, such as the biological behavior of the tumor or the immune response of the host, that are not reflected in staging systems for laryngeal cancer.[1]

Some authors have studied the possible influence of extracapsular spread (ECS)[2-8] and a desmoplastic pattern (DP)[3] as prognostic factors for survival and regional recurrence in patients with neck node metastasis. Extracapsular spread could reflect tumor aggressiveness and may also indicate depressed host immunosurveillance with failure to contain tumor spread.[5] The pathophysiology for a DP is still controversial.

The purpose of this work is to study the impact of ECS and DP in metastatic lymph nodes of patients surgically treated for laryngeal carcinoma.

MATERIALS AND METHODS

Between 1984 and 1992, 150 patients with malignant neoplasms of the larynx and pathologically proven metastatic nodes were surgically treated at the Department of Otorhinolaryngology of La Paz Hospital. Nineteen patients received other treatments prior to surgery and were excluded from the study. Three subjects with tumors other than squamous cell carcinoma were also rejected. The remaining 128 patients were selected for the analysis. All patients had a complete 3-year follow-up.

The median age was 57.6 years (range 40 to 83 years). All but 3 patients were men. The types of

TABLE 1. NECK DISSECTIONS

Neck Dissection	*No. of Patients*
Delphian node excision	3
Functional	
Unilateral	40
Bilateral	40
Radical (unilateral)	31
Functional + radical	11
Other	3

TABLE 2. CLASSIFICATION OF PATIENTS ACCORDING TO T AND N STAGES

	N0	*N1*	*N2a*	*N2b*	*N2c*	*N3*	*Total*
T1	3	1	0	1	0	3	8
T2	14	5	3	2	0	1	25
T3	17	12	8	5	1	6	49
T4	11	6	4	8	13	4	46
Total	45	24	15	16	14	14	128

From the Departments of Otorhinolaryngology (Prim, De Diego, Gavilán), Pathology (Hardisson, Nistal), and Research (Madero), La Paz Hospital, Autonomous University, Madrid, Spain.

CORRESPONDENCE — Maria P. Prim, MD, Servicio de ORL, Hospital Universitario La Paz, Paseo de la Castellana, 261, 28046 Madrid, Spain.

TABLE 3. HISTOPATHOLOGIC FINDINGS IN NECK SPECIMENS

Features	*Findings*	*No. of Patients*
ECS	Yes	75
	No	53
DP	Yes	112
	No	16

ECS — extracapsular spread, DP — desmoplastic pattern.

neck dissection used are detailed in Table 1. The surgical specimens were retrospectively evaluated by pathologists (D.H. and M.N.) who had no knowledge of the patients' clinical course. This evaluation consisted of a review of the original slides to look for ECS and DP. All neck lymph node specimens were classified into 2 categories with respect to both ECS and DP, ie, no ECS (neck metastasis confined within the lymph nodes) versus ECS (tumor involving extracapsular surrounding tissue); and no DP (no fibroblastic reaction of the lymph node to metastatic tumor) versus DP (connective tissue reaction within the node).

The number of dissected nodes, the number of positive nodes, and the size of the nodes in each patient were also recorded. The 1988 American Joint Committee TNM classification was used for staging.[9] The distribution of patients according to T and N stage is given in Table 2. Until 1990, postoperative radiotherapy was used in all cases with positive nodes. Starting in 1991, radiotherapy was used on a more selective basis. Only patients with positive or unsatisfactory surgical margins and/or carcinomatous lymphangitis were irradiated. A total dose of 6,000 cGy was delivered on a 200-cGy/d, 5-d/wk schedule. All patients had a minimum follow-up of 3 years or until death.

The data were statistically studied on an Inves Pentium computer with the BMDP statistical package (Statistical Software, 1993). The Kaplan-Meier method was used for survival analysis and neck recurrence-free curves. The comparison among survival curves and curves of neck recurrence was made by means of the Mantel-Cox (log-rank) test. All statistical tests received the same level of significance of .05.

RESULTS

The average number of lymph nodes studied and number of positive nodes dissected in each patient were 16.6 and 4.4, respectively. All lymph nodes were smaller than 2.5 cm. The histopathologic findings are shown in Table 3.

TABLE 4. DISTRIBUTION OF PATIENTS ACCORDING TO ECS AND POSTOPERATIVE RT

	No RT	*RT*
ECS	14	61
No ECS	12	41

RT — radiotherapy.

TABLE 5. OUTCOME (N = 128 PATIENTS)

	No.	*%*
Alive with NED	42	32.8
Died of disease	66	51.6
Died of unrelated causes	16	12.5
Alive with disease	3	2.3
Lost to follow-up	1*	0.8

NED — no evidence of disease.
*Considered as dead of disease.

Twenty-six patients were not irradiated postoperatively. Distribution of postoperative radiotherapy with respect to ECS is shown in Table 4. Two subjects (both with ECS and a DP) were additionally treated with chemotherapy.

The median survival for the 128 patients included in the study was 60.7 months after the date of neck dissection. The outcome is detailed in Table 5. Ninety-four patients did not have a recurrent neck tumor. In this subgroup, 38 (40.4%) patients died of their cancer (local and/or distant recurrence), 14 (14.9%) died of unrelated causes, and 42 (44.7%) are alive. The remaining 34 patients with recurrent neck cancer after dissection did much worse. Only 3 (8.8%) patients in this group are alive; 29 (85.3%) died of the head and neck neoplasm, and 2 (5.9%) died of other causes.

The survival rate with regard to ECS was as follows: patients without ECS 73.4%, and patients with ECS 28.9% (see Figure, A). This difference is highly significant ($p < .001$). Likewise, the neck recurrence rate was different between both groups: 49.6% for patients with ECS and 10.7% for patients without ECS ($p < .001$).

Also, ECS seems to be related to local relapse of the tumor. Patients with ECS had a 36.1% rate of local recurrence, and those without ECS only a 15.7% rate ($p < .03$). This finding was confirmed with the multivariate analysis.

A DP also had a prognostic impact on survival. Survival was 76.9% for patients without a DP, in contrast to 43.3% for those with a DP (see Figure,

TABLE 6. SURVIVAL ACCORDING TO ECS AND DP

	No ECS		*ECS*	
	%	*(n)*	*%*	*(n)*
No DP	75.0	(16)		(0)
DP	71.8	(37)	27.4	(75)

% — Percentage of survivors, n — number of subjects.

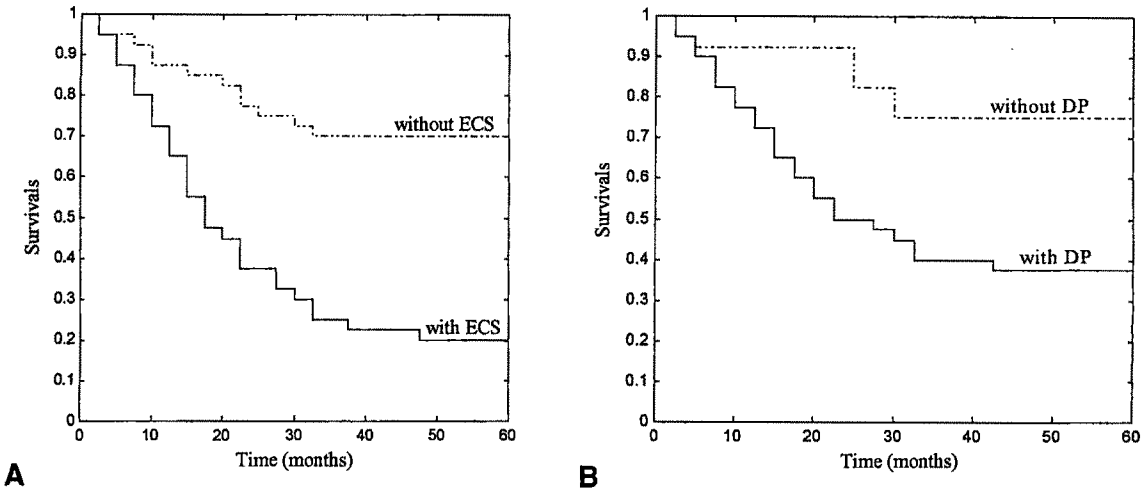

Actuarial disease-free survival curves after surgery according to A) extracapsular spread (ECS) and B) desmoplastic pattern (DP).

B; p < .03). The neck recurrence rate was 10% in patients without a DP, and 31.6% in those with a DP (p = .1142). However, a DP did not show a relationship to local recurrence: 29.0% in patients with a DP and 20.0% in patients without a DP (p > .05).

The number of lymph nodes affected with either ECS or a DP did not affect the survival or the recurrence rate in the neck (p > .05). Likewise, the size of the lymph nodes had no relation to recurrence or survival (p > .05).

In the group of patients with neither ECS nor a DP, the survival rate was higher (Table 6). No difference with respect to survival exists between this group and the subjects without ECS but with a DP (p > .05). Nevertheless, the patients with both ECS and a DP have a poorer survival in comparison to the other groups (p < .001). There were no patients without a DP and with ECS in our series.

The impact of ECS on the prognosis of laryngeal cancer is significant in both treatment groups (surgery alone and surgery with postoperative radiotherapy). Moreover, patients with ECS treated with postoperative radiotherapy had the lowest survival rate of all groups (Tables 7 and 8).

Likewise, a DP had an adverse influence on survival in the group of irradiated patients (Tables 9 and 10), whereas in the group of patients treated with surgery alone, the numbers are too small to obtain significant results.

DISCUSSION

Our current ability to clinically detect cervical metastasis is unfortunately limited. Imaging techniques are not the solution,[10] and attempts to improve the diagnostic accuracy by means of lymphangiography or radionuclide scanning are imprecise and expensive. Ultrasound fine needle aspiration cytology[11] can be a good diagnostic method, but it is rarely available and requires experience and dedication to be clinically helpful. More sensitive methods to detect microscopic disease have been frustrated by the lack of suitable markers.[12] Hence, surgery is the only available method to relatively safely assess the clinical status of neck lymph nodes in patients with head and neck cancer.

An additional advantage of the surgical approach to the neck in patients with head and neck cancer is the chance for histologic evaluation of the lymph nodes and the subsequent accuracy of the diagnosis.

There is a general belief in the medical literature that ECS carries a particularly bad prognosis. According to several studies, lymph node metastasis with ECS is associated with a decrease in survival

TABLE 7. SURVIVAL ACCORDING TO POSTOPERATIVE RT AND ECS

	No RT		*RT*		
	%	*(n)*	*%*	*(n)*	*p*
ECS	33.0	(14)	18.4	(61)	.699
No ECS	70.7	(12)	71.6	(41)	.930
p	.0403		<.0001		

% — Percentage of survivors, n — number of subjects.

TABLE 8. DISEASE-FREE PATIENTS ACCORDING TO POSTOPERATIVE RT AND ECS

	No RT		*RT*		
	%	*(n)*	*%*	*(n)*	*p*
ECS	17.9	(14)	25.7	(61)	.0527
No ECS	46.7	(12)	75.8	(41)	.3200
p	.0011		<.0001		

% — Percentage of disease-free patients, n — number of subjects.

TABLE 9. SURVIVAL ACCORDING TO POSTOPERATIVE RT AND DP

	No RT		RT		
	%	(n)	%	(n)	p
DP	48.6	(24)	35.2	(88)	.731
No DP	100.0	(2)	70.7	(14)	.581*
p	.2909*		.0417		

% — Percentage of survivors, n — number of subjects.
*Unreliable because of small number of cases.

TABLE 10. DISEASE-FREE PATIENTS ACCORDING TO POSTOPERATIVE RT AND DP

	No RT		RT		
	%	(n)	%	(n)	p
DP	31.4	(24)	42.3	(88)	.330
No DP	50.0	(2)	80.8	(14)	.275*
p	.6840*		.0278		

% — Percentage of disease-free patients, n — number of subjects.
*Unreliable because of small number of cases.

ranging between 27% and 60%[4,6-8] and a twofold increase in regional recurrence.[7] However, in the work of Mamelle et al,[13] ECS did not have any prognostic value in head and neck squamous cell carcinomas.

In our series, ECS was associated with an approximately 45% decrease in survival. Our results also show that a single node with ECS is enough to decrease survival and increase the regional recurrence rate, because the number of lymph nodes with ECS does not appear to have clinical importance. A possible interpretation of this fact is that ECS encountered in any node may reflect a more aggressive tumor and may indicate a depressed host immunosurveillance with failure to contain tumor spread[5] (including the primary location). However, the biological significance of ECS with respect to both recurrence and survival remains unclear.

A DP is also a reliable predictor of a poor prognosis. This histologic factor is characterized by the connective tissue (fibroblastic) reaction of the involved lymph node to metastatic tumor. The origin of this response is not clear, but it may result from an unknown interaction between the tumor and host. Olsen et al[3] noted that a stromal DP was associated with a sixfold to sevenfold increased risk of neck recurrence. In our experience, this factor also shows a negative influence on prognosis, with a 30% decrease in survival. Radiotherapy did not improve survival or recurrence in any group of patients.

Elective treatment of the neck is indicated for most laryngeal cancers of supraglottic or subglottic origin.[12,14,15] In our opinion, neck dissection permits the otolaryngologist a more complete assessment of the stage of the disease. In addition, it allows the surgeon to obtain other prognostic pathological parameters that remain unknown in the irradiated or surgically untreated patient.

Further studies are required to evaluate the benefit of treatments other than surgery in the management of patients with histopathologic adverse prognostic factors.

CONCLUSIONS

Extracapsular spread and a DP are 2 reliable pathological prognostic factors for lymph nodes in patients with squamous cell carcinoma of the larynx. Future prospective studies will permit a more accurate determination of the presence or absence of other possible histopathologic risk factors and the influence of combined therapeutic approaches to this subset of patients.

ACKNOWLEDGMENTS — We thank Dr L. W. DeSanto for his invaluable help in the revision and correction of this manuscript. We also acknowledge Cristina García Bermúdez and Professor Ernesto Gambao Galán for their help with the Figure.

REFERENCES

1. Gavilán J, Gavilán C. Conservation surgery for early glottic cancer. In: Smee R, Bridger GP, eds. Laryngeal cancer. Amsterdam, the Netherlands: Elsevier, 1994:14-9.

2. Snow GB, Annyas AA, Van Slooten EA, Bartelink H, Hart AAM. Prognostic factors of neck node metastasis. Clin Otolaryngol 1982;7:185-92.

3. Olsen KD, Caruso M, Foote RL, et al. Primary head and neck cancer. Histopathologic predictors of recurrence after neck dissection in patients with lymph node involvement. Arch Otolaryngol Head Neck Surg 1994;120:1370-4.

4. Hirabayashi H, Koshii K, Uno K, et al. Extracapsular spread of squamous cell carcinoma in neck lymph nodes: prognostic factor of laryngeal cancer. Laryngoscope 1991;101:502-6.

5. Johnson JT, Barnes L, Myers N, Schramm VL, Borochovitz D, Sigler BA. The extracapsular spread of tumors in cervical node metastasis. Arch Otolaryngol 1981;107:725-9.

6. Snyderman NL, Johnson JT, Schramm VL, Myers EN, Bedetti CD, Thearle P. Extracapsular spread of carcinoma in cervical lymph nodes. Impact upon survival in patients with carcinoma of supraglottic larynx. Cancer 1985;56:1597-9.

7. Esclamado RM, Carroll WR. Extracapsular spread and the perineural extension of squamous cell cancer in the cervical plexus. Arch Otolaryngol Head Neck Surg 1992;118:1157-8.

8. Noone RB, Bonner J, Raymond S, Brown AS, Graham WP, Lehr HB. Lymph node metastases in oral carcinoma (a correlation of histopathology with survival). Plast Reconstr Surg 1974;53:158-66.

9. Beahrs OH, Henson DE, Hutter RVP, Myers MH, eds. Manual for staging of cancer. 3rd ed. Philadelphia, Pa: JB Lippincott, 1988:39-41.

10. Mancuso AA. Evaluation and staging of laryngeal and

hypopharyngeal cancer by computed tomography and magnetic resonance imaging. In: Silver CE, ed. Laryngeal cancer. New York, NY: Thieme, 1991:46-94.

11. Van den Brekel MWM, Castelijns JA, Stel HV, et al. Occult metastatic neck disease: detection with US and US-guided fine-needle aspiration cytology. Radiology 1991;180:457-61.

12. Johnson JT, Myers EN. Cervical lymph node disease in laryngeal cancer. In: Silver CE, ed. Laryngeal cancer. New York, NY: Thieme, 1991:22-6.

13. Mamelle G, Pampurik J, Luboinski B, Lancar R, Lusinchi A, Bosq J. Lymph node prognostic factors in head and neck squamous cell carcinomas. Am J Surg 1994;168:494-8.

14. Gavilán C, Gavilán J. Five-year results of functional neck dissection for cancer of the larynx. Arch Otolaryngol Head Neck Surg 1989;115:1193-6.

15. Herranz-González J, Gavilán J, Martínez-Vidal J, Gavilán C. Supraglottic laryngectomy: functional and oncologic results. Ann Otol Rhinol Laryngol 1996;105:18-22.

FIFTH INTERNATIONAL CONFERENCE ON HEAD AND NECK CANCER

The Fifth International Conference on Head and Neck Cancer will be held July 29–August 2, 2000, in San Francisco, California. For information, contact Concepts in Meetings & Events, Robin L. Wagner, President, 7819 Lloyd Ave, Pittsburgh, PA 15218-1941; telephone (412) 243-5156; fax (412) 243-5160; e-mail rlwa@med.pitt.edu.

LEIOMYOSARCOMA OF THE LARYNX
REVIEW OF THE LITERATURE AND REPORT OF TWO CASES

RÓBERT PACZONA, MD
LÁSZLÓ TISZLAVICZ, MD, PHD
JÓZSEF JÓRI, MD, PHD
JENÖ CZIGNER, MD, PHD, DSC
SZEGED, HUNGARY

Leiomyosarcoma of the larynx is an extremely rare malignancy. Until now, only 35 cases have been reported, and only 19 were reported in English. We present 2 new cases observed in the last 3 years at our department. Correct histologic diagnosis can only be made on immunohistochemical and electron microscopic grounds. A 65-year-old man previously treated for a premalignant vocal cord lesion and a 31-year-old woman who previously underwent operation on a benign vocal cord lesion are presented. Only surgical treatment (total laryngectomy and endolaryngeal laser resection) was performed. Thirty-six and 22 months after the initial surgical intervention, both patients are alive and well, with no evidence of local recurrence or distant metastasis.

KEY WORDS — laryngeal neoplasm, laser surgery, leiomyosarcoma, soft tissue sarcoma, surgical treatment.

INTRODUCTION

Malignant mesodermal neoplasms of the larynx are very rare compared to epithelial tumors, accounting for less than 1% of all malignant tumors in this region.[1] Leiomyosarcoma is a malignant tumor of smooth muscle origin and represents 5% to 7% of all soft tissue sarcomas.[2]

Leiomyosarcomas can be divided into 3 groups according to their localization in the body. Tumors arising in the female genital tract or the walls of the gastrointestinal region and retroperitoneal and intra-abdominal leiomyosarcomas are the most frequent group; they can be regarded as a prototype of this rare tumor, since they show all the histologic characteristics of malignancy and sometimes illustrate the problems of diagnosis. Leiomyosarcomas of the cutaneous and subcutaneous tissues are the second group and usually have a good prognosis.[2] In the third group, leiomyosarcomas of vascular origin can be found; these rare tumors arise in the walls of veins.[3] However, leiomyosarcomas have also been located in other parenchymal organs and in several unusual soft tissue sites.

In the head and neck area, smooth muscle is sparse; it is usually found in the walls of arteries and veins, the erector pili muscle of the skin, the posterior wall of the trachea, and the middle and lower thirds of the esophagus.[4] Some cases of leiomyosarcoma in the sinonasal tract, oral cavity, tongue, hypopharynx, cervical esophagus, and trachea have been reported.[5-7] The first case of laryngeal leiomyosarcoma was published by Jackson and Jackson[8] in 1939, and to our knowledge, 34 further cases have been reported in the literature.[9-41] We present 2 new cases of this disease occurring in our department in the last 3 years. The literature, diagnostic problems, and treatment options and management of this exceptionally rare neoplasm are discussed in this paper.

CASE REPORTS

Case 1. A 65-year-old man with an 8-month history of hoarseness presented to our department for the first time in 1993. Indirect laryngoscopy revealed a whitish gray plaque on the first third of both true vocal cords. The vocal cords moved fully and there was no cervical lymphadenopathy. Chest radiography demonstrated no focal lesions, and the complete blood count was normal. During suspension microlaryngoscopy, after we took a specimen for histologic investigation, the lesion was vaporized by a carbon dioxide (CO_2) laser. Histology revealed hyperkeratosis and mild dysplasia. The patient was controlled regularly, and 1½ years later, his voice worsened. He was readmitted in October 1994. General examination did not reveal anything new. Direct laryngoscopy showed a 1.4 × 1.0-cm, broad-based, smooth, pinkish and polypoid neoplasm on the left true vocal cord. The first biopsy was not able to confirm exactly the origin of the tumor; the possibility of either fibrosarcoma, leiomyosarcoma, or spindle cell carcinoma was suggested. Because of the presence of a malignant tumor and a clinically palpable, suspicious lymph node on the left side of the neck, total laryngectomy and modified radical neck dissection were carried out. There were no complications dur-

From the Departments of Otorhinolaryngology (Paczona, Jóri, Czigner) and Pathology (Tiszlavicz), Albert Szent-Györgyi Medical University, Szeged, Hungary.

CORRESPONDENCE — Róbert Paczona, MD, Dept of Otorhinolaryngology, Albert Szent-Györgyi Medical University, H-6725, Szeged, Tisza Lajos krt. 111. Hungary.

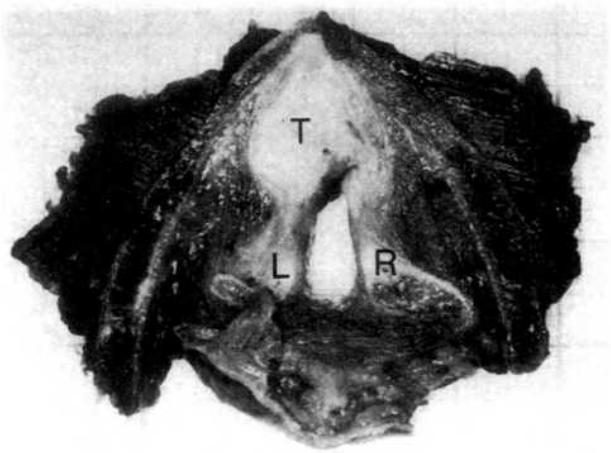

Fig 1. (Case 1) Horizontal section of larynx at level of true vocal cords. T — tumor, L — left vocal cord, R — right vocal cord.

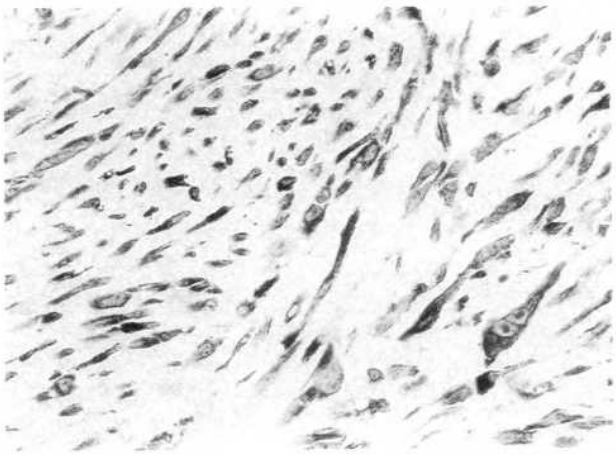

Fig 2. (Case 1) Tumor cells immunohistochemically showed strong positive staining against smooth muscle–specific actin (α-actin-avidin-biotin complex, original ×224).

ing the surgery, and recovery was uneventful. The patient had good esophageal speech. At the last control examination, in October 1997, he was doing well, with no evidence of recurrence or metastasis.

Macroscopically, the tumor, 13 mm in diameter, involved the first third of the left vocal cord without invasion of the thyroid cartilage, and extended into the subglottis and anterior commissure (Fig 1). Light microscopy revealed an extensively ulcerated tumor composed mostly of elongated spindle-shaped cells with cigar-shaped and blunt-ended nuclei. Up to 9 mitoses per 10 high-power fields were found. Immunohistochemistry revealed strong positive intracytoplasmic expression of the intermediary filaments vimentin and desmin. All of the tumor cells were markedly positive for smooth muscle–specific actin antigen (Fig 2). Cytokeratin, S-100 protein, α-1-antitrypsin, lysozyme, epithelial membrane antigen (EMA), and multi–drug-resistant 1 protein (MDR-1) were negative. The proliferating cell nuclear antigen (PCNA) reaction was positive in about 30% of the cells. The tumor morphology was interpreted as leiomyosarcoma of the larynx with reactive lymphadenopathy. No metastasis was found in the lymph nodes.

Case 2. A 31-year-old woman was referred to an otolaryngology specialist because of several months' history of hoarseness. Indirect laryngoscopy revealed that her left true vocal cord was swollen and the mucosa was inflamed. Conservative therapy and antibiotics were administered. Her voice continued to deteriorate, and she was admitted to our department in April 1995. Stripping of both vocal cords was performed for Reinke's edema. Four months later, a synechia occurred in the anterior commissure and was cut through in another otolaryngology department. In 8 weeks, the vocal cords scarred together again. Under general anesthesia, direct suspension laryngoscopy was performed, the web was cut through again, and repeated stripping of both vocal cords was performed. Histopathology revealed no malignancy; only slight epithelial inflammation was found. Her voice deteriorated further, and she was able to speak in a very low voice only. She was readmitted to our otolaryngology department in October 1995. General examination did not reveal anything abnormal. Chest X-ray studies showed no abnormality, and laboratory data were also normal. There was no evidence of enlarged cervical lymph nodes. Direct microlaryngoscopy was carried out under general anesthesia. Examination showed a thick, rough and hard web in the anterior commissure, and the left vocal cord was swollen, but there was no evidence of ulceration (Fig 3). First the web was cut through by a CO_2 laser, and the covering mucosa and the superficial layer of lamina propria of the left vocal cord were incised. Between the fascicles of the vocalis muscle, a macroscopically "encapsulated," crumbling, whitish tumorlike mass was found. A specimen from this tissue was taken for histology and the tumor was removed by CO_2 laser. Computed tomography scans of the larynx did not show any involvement or destruction of the thyroid cartilage. However, the medial margin of the surgical specimen was close to the tumor; thus, an additional surgery was performed. The patient refused total laryngectomy; therefore, an endolaryngeal exenteration of the affected side was performed by CO_2 laser. The left false vocal cord, the whole left true vocal cord (preserving the perichondrium of the thyroid cartilage, from the anterior commissure back to the arytenoid cartilage and down the cricothyroid membrane, reaching the subglottic area), and the adjacent paraglottic space were

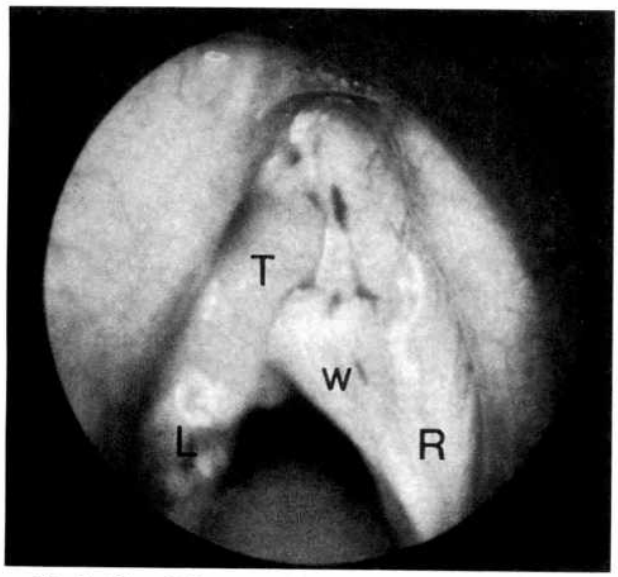

Fig 3. (Case 2) Laryngomicroscopic view. T — tumor, L — left vocal cord, R — right vocal cord, W — web between vocal cords.

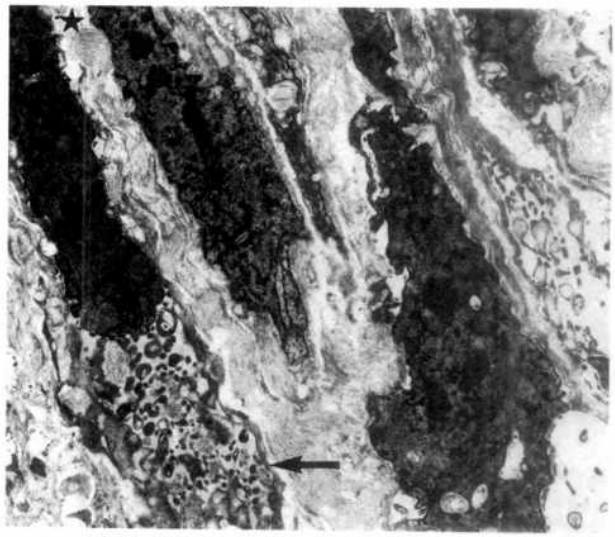

Fig 4. (Case 2) Electron microscopic structure of leiomyosarcoma (original ×7,000). Nuclei are pleomorphic, and cytoplasmic organelles are disorganized. Bundles of thin filaments (star) are limited to zones along plasma membrane or parallel to nuclei. Pinocytotic vesicles (arrow) are present at plasma membrane.

removed. There were no complications, and the patient did well postoperatively. At the last control, 22 months after the surgery, she had moderate breathy, hoarse dysphonia.

Histologically, the vocalis muscle and the mucous glands were infiltrated by a cell-rich malignant tumor, composed of interlacing bundles of smooth muscle fibers with spindle cells showing acidophilic cytoplasm, moderate pleiomorphism, and numerous mitoses. The nuclei were vesicular, and the mitotic rate was mild (up to 5 mitoses per 10 high-power fields). The tumor cells showed strong positive staining against antibodies to vimentin, desmin, and smooth muscle–specific actin and negative staining to cytokeratin, EMA, S-100 protein, and MDR-1 protein. Forty percent of the tumor cells' nuclei were positive with the PCNA reaction. Electron microscopically, the tumor cells contained cytoplasmic bundles of thin myofilaments along the cell membrane. Nuclear polymorphism, free ribosomes, and high amounts of mitochondria were also visualized. The tumor cells were embedded in abundant extracellular collagenous matrix (Fig 4). The tumor was interpreted as leiomyosarcoma of the larynx.

DISCUSSION

The pathogenesis of leiomyosarcoma is uncertain. Few predisposing or etiologic factors have been recognized in this disease up to now.[3] Some reports in the literature indicate that rarely, leiomyosarcomas are radio-induced.[21] Since, in the larynx, blood vessels are the only structures with smooth muscle tissue, it is not unlikely that the tumors develop from smooth muscle in the tunica media of vessel walls.[34] Some authors have suggested that these tumors are derived from dispersed undifferentiated mesenchymal tissue or that leiomyosarcomas originate from myoepithelial cells in the submucous glands of the respiratory epithelium, since their structure is similar to that of smooth muscle cells.[42]

The most frequent age at presentation of laryngeal leiomyosarcoma is the fifth decade of life, although it can be also manifested during childhood.[20,27] Most patients are younger than 50 years; the male-to-female ratio, contrary to other forms of leiomyosarcoma, is 4:1. Unlike squamous cell carcinoma, leiomyosarcoma has no known risk factors such as heavy tobacco and/or alcohol consumption.

The presenting signs and symptoms do not differ from those of other laryngeal tumors. The main symptom of the disease is hoarseness; the average time of its duration is several weeks. Glottic lesions, depending on their size and location, might cause mainly stridor and different degrees of dyspnea. Tumors localized in the supraglottic region can be characterized by foreign body sensations during swallowing, various degrees of dysphagia, and radiating earache. More infiltrative malignancies cause consequent obstructive and compressive signs. Macroscopically, the tumor is larger than 2.5 cm in maximal diameter, generally grayish red, and smooth-surfaced, showing submucosal spreading. Supraglottic tumors are mostly broad-based; glottic forms can be polypoid. Tumors are manifested almost equally in the supraglottic and glottic regions, while subglottic localization is rare (see Table[8-41]). The consistency is firm on instrument palpation. Tumor infil-

PRESENTED CASES OF LARYNGEAL LEIOMYOSARCOMAS

Authors	*Age*	*Sex*	*Tumor Site*	*Initial Treatment*	*Follow-up*
Jackson and Jackson[8]*	NA	NA	Infrahyoid epiglottis	NA	NA
Frank[9]*	28	F	Infrahyoid epiglottis	Endoscopic resection + RT	NED 19 mo
Eggstone and Wolf[10]*	NA	NA	NA	NA	NA
Manara[11]	45	M	Right aryepiglottic fold	RT	NED 3 mo
Penelli and Mazzili[12]	52	M	Bilateral true vocal cords	TL	NED 12 mo
Smolikova and Ermejev[13]	11	F	Left true vocal cord	Laryngofissure + cordectomy	NED 24 mo
Kawabe and Kondo[14]*	45	M	Left true vocal cord	Endoscopic resection + RT; second treatment, TL + left RND + chemotherapy	Died 48 mo
Amendola[15]	29	F	Subglottic region	Endoscopic resection	NED 18 mo
Talavera et al[16]	50	M	Right true vocal cord	Laryngofissure + cordectomy; second treatment, TL	NA
Gryczinski[17]	70	M	Right false vocal cord	Endoscopic resection	NED 6 mo
Wolfowitz and Schmaman[18]*	40	M	Right true vocal cord	TL	NED 18 mo
Friedmann[19]*	NA	NA	NA	NA	NA
Chizh et al[20]	8	F	Infrahyoid epiglottis	RT + TL	NED 24 mo
McKillop et al[21]*	44	F	Right aryepiglottic fold	TL	NED 12 mo
De Rosa et al[22]	28	M	Infrahyoid epiglottis	Supraglottic partial laryngectomy + bilateral FND	Died 6 mo
Kleinsasser and Glanz[23]*	60	M	Left false vocal cord	RT; second treatment, TL	Died 33 mo
	35	M	Right false vocal cord	Vertical partial laryngectomy + RT; second treatment, TL + RT	NED 14 y
Lehmann et al[24]*	41	F	Subglottic region	NA	NA
Balestri and Ghigi[25]	38	M	Anterior commissure	TL + right RND + left FND	Died 12 mo
Giordano et al[26]	NA	NA	NA	NA	NA
Sokolenko et al[27]	46	M	Left true vocal cord	Endoscopic resection; second treatment, RT + TL	NED 36 mo
Lindholm and Lofgren[28]*	66	M	Right true vocal cord	Vertical partial laryngectomy + pedicled composite graft	NED 32 mo
Di Luzio Paparatti et al[29]	NA	NA	NA	NA	NA
Zak and Rowinska[30]	NA	NA	NA	NA	NA
Fukuda et al[31]*	NA	NA	Right true vocal cord	Laryngofissure + cordectomy	NED 24 mo
Bertheau et al[32]	45	M	Left true vocal cord	TL	NED 9 mo
Chen et al[33]*	69	M	Left false vocal cord	Vertical partial laryngectomy + left FND + RT	NED 18 mo
Tewary and Pahor[34]*	56	M	Right true vocal cord	TL	NED 36 mo
Carles et al[35]	43	M	Left false vocal cord	Supracricoid partial laryngectomy	NED 10 mo
Rowe-Jones et al[36]*	87	M	Right true vocal cord	Endoscopic resection + RT	NED 3 mo
Sellari-Franceschini et al[37]*	66	M	Right false vocal cord	TL + RT	Died 3 mo
McKiernan and Watters[38]*	43	M	Left false vocal cord	Supraglottic partial laryngectomy + RT	NED 6 mo
Helmberger et al[39]*	87	M	Right false vocal cord	TL	NED 30 mo
Samlali et al[40]	26	M	Right false vocal cord	TL + chemotherapy	Died 6 mo
Lippert et al[41]*	50	M	Left true vocal cord	Endoscopic resection (CO_2 laser)	NED 25 mo
Our case 1*	65	M	Left true vocal cord	TL + left FND	NED 36 mo
Our case 2*	31	F	Left true vocal cord	Endoscopic resection (CO_2 laser)	NED 24 mo

NA — no information available, RT — radiotherapy, NED — no evidence of disease, TL — total laryngectomy, RND — radical neck dissection, FND — functional neck dissection.

*English-language publication.

trates the surrounding tissues, and ulceration of the epithelial surface can be observed occasionally. On the tumor cut section, a whitish gray fleshy mass aspect can be visualized, sometimes showing a lobulated form with foci of hemorrhage and necrosis.

Leiomyosarcoma can be revealed by a simple indirect laryngoscopy in most cases. In determining the extent of these tumors and planning the surgical approach, modern radiographic imaging techniques such as coronal and/or axial computed tomography

scans and magnetic resonance imaging studies of the head and neck region provide a reasonable assessment of the anatomic boundaries of the primary tumor, as well as any destruction of the laryngeal cartilages or infiltration of the paraglottic space and/or preepiglottic space.[33] Because the treatment and prognosis rely mostly on detailed histopathologic examination, tissue sampling is essential prior to definitive management. Despite the progress made in the histologic differential diagnosis of mesodermal neoplasms, the correct histologic diagnosis of leiomyosarcoma is still a matter of concern. Leiomyosarcoma should be differentiated mostly from spindle cell tumors, ie, fibrosarcoma, malignant schwannoma, and spindle cell carcinoma. The microscopic appearance of these malignancies might be very similar to that of leiomyosarcoma, but in the cells of spindle cell carcinoma and neurofibrosarcoma, sparse longitudinally oriented fascicles might be seen. Further, the cells of fibrosarcoma are tapered, and in contrast, the cells of schwannoma are buckled. In addition, these malignancies do not contain glycogen in their cytoplasm. Apart from these important points of differentiation, exact histologic classification of spindle cell tumors remains for immunohistochemical analysis and electron microscopic studies.[43] In immunohistochemical studies, antibody markers against desmin, vimentin, and the muscle-specific isoform of actin allow a correct diagnosis of leiomyosarcoma. For more accurate histologic diagnosis of leiomyosarcoma, electron microscopy is also very helpful. The diagnostic features are cytoplasmic parallel actin filaments and the presence of fusiform dense bodies among them.[43] The distinction between leiomyoma and leiomyosarcoma might also be very difficult. Mitotic activity is the main criterion for diagnosis of leiomyosarcoma[23]; however, cellular atypia should also be considered. Neoplasms with 5 or more mitoses per 10 high-power fields with moderate to marked cellular atypia are regarded as leiomyosarcoma.[3] The PCNA immunoreactivity may provide an insight into the biological potential of the tumors and might be helpful in distinguishing between leiomyoma and leiomyosarcoma.[44] Ultrastructurally, leiomyosarcomas differ from leiomyomas: they have greater nuclear polymorphism, fewer and more disordered myofilaments, and the presence of free ribosomes.[45] To our knowledge, MDR-1 protein reaction has not been investigated until now in leiomyosarcoma. In our cases we found that the neoplastic cells were not stained positively with MDR-1.

The few cases of laryngeal leiomyosarcoma published so far do not allow us to draw valid conclusions as to the various modalities of therapy (see Table). It is generally accepted that the mainstay of treatment of sarcomas of head and neck is still wide surgical extirpation.[46] The extent of excision depends on the localization and the degree of differentiation of leiomyosarcoma. The most aggressive surgical therapy in laryngeal malignant tumors, which provides pathologically free margins and extent resection, is total laryngectomy. The head and neck surgeons preferred this as initial therapy in one third of the reported cases.[12,18,20,21,24,32,34,37,39,40] In cases with limited tumor invasion, as in squamous cell carcinoma of the larynx, the principles of transoral operation or conservation surgery are applicable, and tumor should be removed by partial laryngectomy or endoscopic laser resection.[8-10,13-17,19,22,23,25-31,33,35,36,38,41] Radiotherapy as a primary treatment has limited value, but as a complementary, postoperative option, it may permit a more conservative resection.[11,14,23,33,36,38] The role of adjuvant chemotherapy is controversial.[40] The incidence of local recurrence and regional and distant metastases is lower than that reported in other sites of the head and neck region.[5]

Predicting the final outcome of laryngeal leiomyosarcoma is very difficult, as there is only 1 patient with more than a 5-year follow-up in the literature.[23] Local recurrences and regional and widespread metastases are rare, but may appear even several years after primary treatment; thus, careful follow-up of patients is mandatory. Our patients, 36 and 22 months after the initial surgical therapy, are doing well, with no evidence of local recurrence or distant metastasis.

CONCLUSIONS

As the biological behavior of laryngeal leiomyosarcoma is not well known, it is difficult to determine the best treatment option in such cases. The age of the patient, the relatively little experience with laryngeal soft tissue malignancies, and the uncertainty of the histologic diagnosis prompted us to perform total laryngectomy in the first case. On the basis of the reported successful partial laryngectomy cases, we accepted the second patient's request to perform conservation laryngeal surgery instead of total laryngectomy. The modern endolaryngeal microlaryngoscopic laser surgery proved to be a satisfactory treatment modality.

REFERENCES

1. Michaels L. Ear, nose and throat histopathology. Berlin, Germany: Springer-Verlag, 1987:441-3.

2. Fields JP, Helwig EB. Leiomyosarcomas of the skin and subcutis. Cancer 1981;47:156-68.

3. Enzinger FM, Weiss SW. Leiomyosarcoma. In: Enzinger FM, ed. Soft tissue tumors. 2nd ed. St Louis, Mo: Mosby, 1988: 402-21.

4. Cottran RS, Kumar V, Robbins SL. The musculoskeletal system. In: Robbins SL, ed. Pathologic basis of disease. 4th ed. Philadelphia, Pa: WB Saunders, 1989:1377.

5. Mindell RS, Calcaterra TC, Ward PH. Leiomyosarcoma of the head and neck. Laryngoscope 1975;5:904-10.

6. Haedicke G, Kaban LB. Smooth-muscle tumors of the oral cavity. Plast Reconstr Surg 1988;81:264-9.

7. Thedinger BA, Cheney ML, Montgomery WM, Goodman M. Leiomyosarcoma of the trachea. Case report. Ann Otol Rhinol Laryngol 1991;100:337-40.

8. Jackson C, Jackson CL. Sarcoma of the larynx. In: Jackson C, ed. Cancer of the larynx. 1st ed. Philadelphia, Pa: WB Saunders, 1939:167-8.

9. Frank DL. Leiomyosarcoma of the larynx. Arch Otolaryngol 1941;34:493-500.

10. Eggstone AA, Wolf D. Histopathology of the ear, nose and throat. Baltimore, Md: Williams and Wilkins, 1947:959.

11. Manara E. I tumori mesenchimali maligni della laringe. Considerazioni su di un raro caso di leiomiosarcoma. Otorinolaringol Ital 1959;28:167-78.

12. Penelli N, Mazzili G. Leiomiosarcoma della laringe. Arch Ital Laringol 1962;70:343-55.

13. Smolikova VI, Ermejev AS. Leiomyosarcoma of the larynx [in Russian]. Vestn Otorinolaryngol 1964;24:95-7.

14. Kawabe Y, Kondo T. A laryngeal leiomyosarcoma. Evaluation of the authors' case and observation of the literature. Otolaryngology (Tokyo) 1967;39:427-32.

15. Amendola L. Leiomiosarcoma della laringe. Valsalva 1969;44:268-74.

16. Talavera S, Segura Coronado E, Sanchez Hidalgo A. Asociación laringocele-leiomiosarcoma de la cuerda vocal. Acta Otorrinolaringol Esp 1969;20:74-85.

17. Gryczinski M. Leiomyosarcoma of the larynx [in Polish]. Otolaryngol Pol 1971;25:545-8.

18. Wolfowitz BL, Schmaman A. Smooth muscle tumors of the upper respiratory tract. S Afr Med J 1973;47:1189-91.

19. Friedmann I. Sarcomas of the larynx. Can J Otolaryngol 1975;4:297-302.

20. Chizh I, Ogorodnikova LS, Birina LM, Ratner ON. Leiomyosarcoma of the larynx in an 8-year-old girl [in Russian]. Vestn Otorinolaringol 1976;36:104-5.

21. McKillop JH, Doig JA, Kennedy FS, Thomson JA, Greig WR. Laryngeal malignancy following iodine-125 therapy for thyrotoxicosis. Lancet 1978;2:1177-9.

22. De Rosa G, Palombini L, D'Angelo L. I leiomiomi della laringe. Rassegna della letteratura e presentazione di 2 casi. Pathologica 1978;70:209-15.

23. Kleinsasser O, Glanz H. Myogenic tumors of the larynx. Arch Otorhinolaryngol 1979;225:107-19.

24. Lehmann W, Pidoux JM, Widmann JJ. Larynx. Microlaryngoscopy and histopathology. Paris, France: Inpharzam Medical Publications, 1981:64-5.

25. Balestri J, Ghigi V. Leiomiosarcoma della laringe. Otorinolaringologia 1981;31:141-2.

26. Giordano C, Beatrice F, Vercellino N. Un caso dei leiomisarcoma della laringe. Otorinolaringologia 1981;31:141.

27. Sokolenko SM, Kornilov BE, Averin AA. Leiomyosarcoma of the larynx [in Russian]. Vestn Otorinolaringol 1984; 3:75-8.

28. Lindholm CE, Lofgren L. Airway repair with pedicled composite grafts. Clinical experience. Otolaryngol Head Neck Surg 1987;96:48-54.

29. Di Luzio Paparatti U, Perrazetti F, Ruggeri L. Un caso dei leiomiosarcoma della laringe. Riv Eur Sci Med Farmacol 1988;10:41-4.

30. Zak A, Rowinska E. Coexistence of leiomyosarcoma and carcinoma planoepitheliale of the larynx [in Polish]. Wiad Lek 1988;41:1387-9.

31. Fukuda H, Tsuji DH, Kawasaki Y, Kawaida M, Sakou T. Displacement of ventricular fold following cordectomy. Auris Nasus Larynx 1990;17:221-8.

32. Bertheau P, Deboise A, De Roquancourt A, Brocheriou C. Léiomyosarcome du larynx. Étude histologique, immunohistochimique et ultrastructurale d'une observation avec revue de la littérature. Ann Pathol 1991;11:122-7.

33. Chen JM, Norvick WH, Logan CA. Leiomyosarcoma of the larynx. J Otolaryngol 1991;20:345-8.

34. Tewary AK, Pahor AL. Leiomyosarcoma of the larynx: emergency laryngectomy. J Laryngol Otol 1991;105:134-6.

35. Carles D, Devars F, Saurel J, Traissac L, Boudard P. Léiomyosarcome du larynx: présentation d'un cas. Rev Laryngol Otol Rhinol (Bord) 1992;113:115-7.

36. Rowe-Jones JM, Solomons NB, Ratcliffe NA. Leiomyosarcoma of the larynx. J Laryngol Otol 1994;108:359-62.

37. Sellari-Franceschini S, Segini G, Testi G, Berrettini S, Braschini P, Marcetti G. Leiomyosarcoma of the larynx. Review of the literature and a case report. Rev Laryngol 1994; 115:345-8.

38. McKiernan DC, Watters GWR. Smooth muscle tumors of the larynx. J Laryngol Otol 1995;109:77-9.

39. Helmberger RC, Croker BP, Mancuso AA. Leiomyosarcoma of the larynx presenting as a laryngopyocele. AJNR Am J Neuroradiol 1996;17:1112-4.

40. Samlali R, Acharki A, Sahraoui S, Tihyfa M, Benider A, Kahlain A. Léiomyosarcome du larynx. Revue de la littérature, à propos d'un cas. Bull Cancer (Paris) 1996;83:882-5.

41. Lippert BM, Schluter E, Claassen H, Werner JA. Leiomyosarcoma of the larynx. Eur Arch Otorhinolaryngol 1997; 254:466-9.

42. Ohashi Y, Nakai Y, Muraoka M, Takano H. Asymptomatic leiomyosarcoma of maxillary sinus accompanied by primary mucocele. Arch Otorhinolaryngol 1984;240:73-8.

43. Kuruvilla A, Wenig BM, Humphrey DM, Heffner DK. Leiomyosarcoma of the sinonasal tract. A clinicopathologic study in nine cases. Arch Otolaryngol 1990;116:1278-86.

44. Franquemont DW, Geary W. Gastrointestinal stromal tumors and proliferating cell nuclear antigen [Editorial]. Am J Pathol 1993;100:369.

45. Ferenczy A, Richardt RM, Okagaki T. A comparative ultrastructural study of leiomyosarcoma, cellular leiomyoma and leiomyoma of the uterus. Cancer 1971;28:1004-18.

46. Tran LM, Mark R, Meier R, Calcaterra TC, Parker RG. Sarcomas of the head and neck. Prognostic factors and treatment strategies. Cancer 1992;70:169-77.

COMPARISON OF PERINATAL AND ADULT MULTI-INNERVATION IN HUMAN LARYNGEAL MUSCLE FIBERS

SOPHIE PÉRIÉ, MD

JEAN LACAU ST GUILY, MD ALAIN SEBILLE, MD

PARIS, FRANCE

The innervation of human laryngeal myofibers appears distinct from that of skeletal myofibers, because some of them exhibit multiple neuromuscular junctions. We attempted to understand the significance of the multi-innervation phenomenon by comparing intrinsic laryngeal muscles obtained from autopsies of a fetus, a stillbirth, and a 7-month-old infant to muscles from adults. In longitudinal sections (40 to 60 μm thick) the cholinesterase sites and the nerve terminals were stained simultaneously for light microscopy. Multi-innervation reached no more than 23% at 7 months, and this percentage decreased notably with age. Until 7 months, end plates were innervated either by single or by multiple axons (unineuronal and polyneuronal innervation), whereas in adults, the pattern was exclusively unineuronal. Moreover, the structure of neuromuscular junctions in the young was limited to 1 spot of acetylcholinesterase, while in adults the end plate zones increased in size and complex axon terminals were observed. These observations are consistent with a delayed maturation of human laryngeal innervation compared to that of skeletal muscles.

KEY WORDS — cholinesterase, laryngeal muscles, multi-innervation, neuromuscular junction, unineuronal and polyneuronal innervation.

INTRODUCTION

The myofibers of mammalian skeletal muscles commonly exhibit 1 neuromuscular junction (NMJ; focally innervated myofibers) innervated by a single motor axon (unineuronal innervation; Fig 1). In fact, embryonic end plates are co-innervated by several motor axons (polyneuronal innervation), but become innervated by a single motor axonal branch during early postnatal life owing to the apoptosis of most of the motoneurons.[1-3] This synaptic dynamic is true of human skeletal innervation.[4] However, innervation of the human intrinsic laryngeal myofibers appears distinct from that of skeletal muscle fibers, since multiple NMJs on a single muscle fiber (multi-innervated myofiber) have been reported in adults.[5-7] This feature has also been reported in extraocular muscles.[8-11] A single axon seems to be devoted to innervating the single or the multiple NMJs of each of the adult laryngeal myofibers, indicating a unineuronal pattern of innervation.[12] In young infants, an immature structure of NMJs was described in thyroarytenoid and posterior cricoarytenoid muscles,[13,14] but the status of multi-innervation (existence, and unineuronal or polyneuronal origin) of these fibers remains unknown. Thus, we attempted to understand the multi-innervation phenomenon by comparing the morphological structures and the innervation pattern of NMJs in laryngeal muscles of the perinatal period to those of adults.

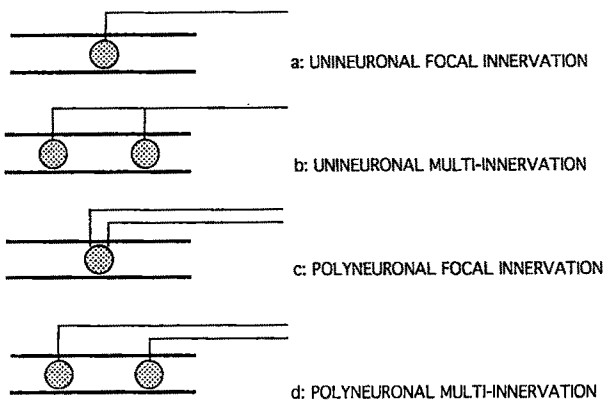

Fig 1. Overview of innervation in human laryngeal muscles. Innervation of laryngeal adult muscle fibers was exclusively found to be unineuronal (a, b). Until 7 months of age, innervation was found to be both unineuronal and polyneuronal (a, b, c, d).

MATERIALS AND METHODS

Muscles. Twenty human intrinsic laryngeal muscles (5 thyroarytenoid, 5 posterior cricoarytenoid, 5 interarytenoid, 5 cricothyroid) were obtained from autopsies according to current French law. The muscles were excised within 30 hours of death. None of the patients presented neuromuscular disorders or pharyngolaryngeal tumors. The specimens were provided from a 31-week-old fetus, a stillbirth, a 7-month-old infant, and 2 adults (41 and 54 years old).

From the Department of Otolaryngology–Head and Neck Surgery, Tenon Hospital (Périé, Lacau St Guily), and the Atelier de Régénération Neuromusculaire, INSERM U153 (Périé, Sebille), Faculty of Medicine Saint Antoine, University Paris VI, Paris, France. This study was supported by the Association Française contre les Myopathies. Dr Périé received a grant from the Fondation pour la Recherche Médicale (Paris, France).

CORRESPONDENCE — Sophie Périé, MD, Dept of Otolaryngology–Head and Neck Surgery, Tenon Hospital, 4, rue de la Chine, 75020 Paris, France.

Fig 2. Scattered distribution of neuromuscular junctions and structures of neuromuscular junctions (original ×250). End plates are blue-stained with 5-bromoindoxyl acetate, and axons are black with gold-silver impregnation. Thyroarytenoid muscle (41-year-old man). Arrow — structure of "complex" neuromuscular junction (multibranched end plate) displaying several cholinesterase spots.

The muscles were mounted on pieces of cork with tragacanth gum, quickly frozen by immersion in isopentane cooled with liquid nitrogen, and stored at −80°C. Serial longitudinal sections of the whole muscle (40 to 60 μm thick) were cut with a cryostat microtome at −26°C and mounted on polysilane-precoated glass slides.

Staining. The sections were stained simultaneously for cholinesterase (ChE) activity in blue with 5-bromoindoxyl acetate and for nerve terminal visualization in black with gold-silver impregnation. The original procedure described for rodents[15] was modified as follows.

1. Incubation for 5 minutes in 20% solution of sodium sulfate. Flash washing in deionized water.

2. Incubation for 60 minutes, at 37°C, at pH 7.2, in 4 mg 5-bromoindoxyl acetate, 0.3 mL ethanol 100%, 63 mg potassium ferrocyanide, 50 mg potassium ferricyanide, 33 mg calcium chloride, 1 mL of a solution of 0.1-mol/L Tris, and 30 mL deionized water. Flash washing in deionized water and dehydration in 70%, 90%, and 100% ethanol.

3. Incubation for 5 minutes in 0.5% celloidin in 1:1 ethanol-ether. Immersion in ethanol 70% for 1 minute.

4. Incubation for 15 minutes, at pH 7, in 20 mL formaldehyde, 4.25 g sodium chloride, and 180 mL deionized water. Flash washing in deionized water.

5. Incubation for 20 to 25 minutes, at 37°C in 10% chloral hydrate, 1% pyridine, and 100 mL deionized water.

6. Incubation for 40 minutes, at 37°C in 6 g silver nitrate, 50 mg calcium carbonate, 30 mg cupric sulfate, and 30 mL of deionized water. Washing in deionized water (3 times for 1 minute).

7. Incubation in 2 baths, for 3 seconds and 3 minutes, in a solution containing 1% hydroquinone and 5% sodium sulfite in 100 mL deionized water. Washing in deionized water (3 times for 1 minute).

8. Incubation for 5 minutes in 5% sodium thiosulfate. Flash washing in deionized water.

9. Incubation in 0.2% tetrachloroaurate for 8 minutes.

10. Incubation for 5 minutes in 5% sodium thiosulfate. Dehydration in ethanol 70% (1 minute), 95% (2 minutes), and 100% (2 minutes). Immersion in 1:1 ether-ethanol (2 minutes). Rinsing in xylene for 5 minutes before mounting.

Quantitative Histology. The sections were quantified by the same observer at 250× and 400× magnifications with an ocular micrometer. Myofibers longer than 200 μm in the infant and 300 μm in the adults showing the presence of at least 1 NMJ were selected to record the following features: 1) the diameter (micrometers) of the myofiber, 2) the length (micrometers) of each NMJ and the structure of the NMJ as "platelike," "grapelike," or "complex,"[16] 3) the number of ChE spots in each NMJ, 4) the number of NMJs in each myofiber (focal innervation or multiinnervation) and the distances between multiple end plates, and 5) the unineuronal or polyneuronal innervation of each NMJ.

Thus, each muscle was characterized by the mean diameter of its fibers, the mean length of the NMJs, the percentage of multi-innervated fibers, the percentage of NMJs with 1 ChE spot, and its unineuronal or polyneuronal pattern of innervation.

However, it was very difficult to individualize each of the muscle fibers from the others in the fetus and the stillbirth, due to the slight contrast of the striations in these myofibers. Thus, in the fetus and the

LENGTH OF NEUROMUSCULAR JUNCTIONS

Age		*Thyroarytenoid*	*Posterior Cricoarytenoid*	*Interarytenoid*	*Cricothyroid*
7 mo	N	1,218	1,100	1,182	981
	Mean ± 1 SE (μm)	38 ± 0.32	32 ± 0.27	37 ± 0.30	25 ± 0.49
	Range (μm)	15-75	10-100	15-90	15-40
	Single ChE spot	95.5%	98.9%	98.8%	99.6%
41 y	N	764	712	670	704
	Mean ± SE (μm)	52 ± 0.82	51 ± 0.69	47 ± 0.63	41 ± 0.42
	Range (μm)	15-180	20-130	15-200	15-130
	Single ChE spot	81.0%	88.5%	84.8%	90.5%
54 y	N	838	825	1,324	1,238
	Mean ± 1 SE (μm)	53 ± 1.02	51 ± 0.70	42 ± 0.49	36 ± 0.38
	Range (μm)	5-210	15-150	15-120	15-90
	Single ChE spot	71.5%	87.2%	85.8%	94.0%

ChE — cholinesterase.

stillbirth, the aspect of NMJs and the pattern of their innervation were only qualitatively recorded. In each of the other muscles, an average of 801 myofibers were investigated, in which an average of 930 NMJs were studied.

RESULTS

The myofiber diameter ranged from 10 to 20 μm in all the muscles of the fetus, 15 to 30 μm in the infant, and 20 to 35 μm in the adults. The NMJs were scattered throughout all the laryngeal muscles without a definite end plate zone (Fig 2).

Whatever the muscle observed, the mean length of the NMJs was 32 μm in infant muscles and 47 μm in adult muscles (see Table). This difference was significant.

In fetus and infant muscles, the NMJs presented only a platelike structure (Fig 3A,B). In contrast, the 3 structures of platelike, grapelike, or "complex" nerve terminals were observed in adult muscles (Fig 2, arrow; Fig 3C,D). In the infant, more than 95% of the NMJs displayed 1 spot of ChE, whereas in adults, 2 or more ChE spots were frequently observed (Fig 3 and Table). From the fetus and the 7-month-old infant, multi-innervation was observed as in adults. As seen in Fig 4, the percentage of multi-innervated fibers varied with the muscle (highest percentage in interarytenoid muscles) and decreased significantly from the infant to the adults. Most of the multi-innervated fibers displayed only 2 end plates (Fig 3A,D,E). The distance between 2 NMJs on the same myofiber varied from 10 to 200 μm in the infant, and from 10 to 700 μm in the adults. In the adults, some of these double NMJs were displayed opposite one another on each extremity of 1 diameter of the muscle fiber (Fig 3E). This feature was not observed in muscles of the younger specimens.

Until 7 months of age, the innervation of the NMJs was found to be both unineuronal and polyneuronal (Fig 3A,B). Polyneuronal innervation was not observed in adult muscles, in which the unineuronal mode took place exclusively: terminal sprouts of a single axon innervated all the NMJs of the same myofiber (Fig 3C-E).

DISCUSSION

The combined method described by Pestronk and Drachman[15] for staining end plates and axons was mainly used to study axonal sprouting in various models of neural regeneration in rodents.[17] We introduced a few modifications in the original procedure to obtain a good staining of human myofibers. In this study, all the NMJs were observable in longitudinal sections, but not all of them were analyzed. Several fibers presented too short a segment to detect multi-innervation. Moreover, it was not possible in some cases to distinguish the separation between 2 adjacent myofibers. At least, it was sometimes not possible to distinguish NMJs with multi-spots of ChE from multiple NMJs side by side. In other cases, axon terminals were cut near the NMJs and the parent axon was not observable. In all these cases, the NMJs were not recorded.

The method used in this work permits a qualitative comparison of perinatal and adult multi-innervation. However, no statistical statements were made, since the structure of the NMJs and the pattern of innervation could not be quantitatively recorded in the fetus and the stillbirth (due to the slight contrast of the myofiber striations at this age).

In contrast with the distribution of NMJs in skeletal muscles, in which a band of end plates is found at the midpoint of the muscle belly,[18] no motor end plate zones were observed in the laryngeal muscles studied. Neuromuscular junctions were randomly distributed along the myofibers, as was previously reported in human thyroarytenoid muscles,[5,6,19] but not in the posterior cricoarytenoid,[20] cricothyroid,[21] interarytenoid,[22] and lateral cricoarytenoid[23] mus-

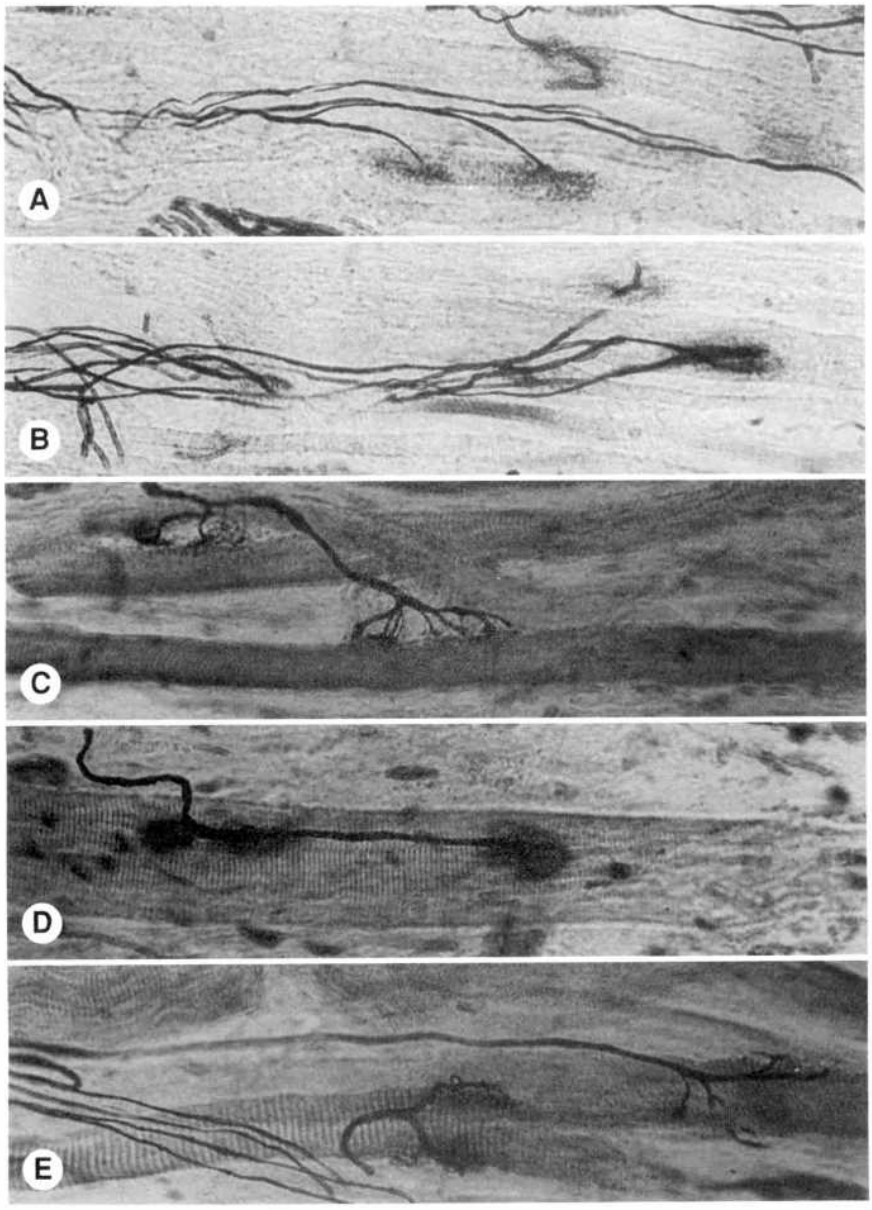

Fig 3. Patterns of innervation of laryngeal muscle fibers (original ×400). A,B) "Platelike" neuromuscular junctions with 1 spot of cholinesterase. A) Two neuromuscular junctions receiving terminal nerve endings from distinct axons (polyneuronal innervation of multi-innervated myofiber; thyroarytenoid muscle from 7-month-old infant). B) Two axons innervate single neuromuscular junction (polyneuronal focal innervation; posterior cricoarytenoid muscle from 7-month-old infant). C) Unineuronal focal innervation of 2 "grapelike" end plates (thyroarytenoid muscle from 54-year-old man). D) Multi-innervated myofiber with 2 "platelike" neuromuscular junctions innervated by single axon (unineuronal multi-innervation; thyroarytenoid muscle from 41-year-old man). One of end plates displays 2 spots of cholinesterase, and other only 1. E) Double neuromuscular junctions opposite one another, innervated by single axon (unineuronal multi-innervation; interarytenoid muscle from 41-year-old man).

cles.

During the embryonic development of vertebrates, NMJs transiently receive nerve terminals from more than 1 axon (polyneuronal innervation), and all of them, except 1, are lost during the process of synapse elimination from the end of the embryonic period to early postnatal life.[3,24] Thus, in focally innervated muscles, each NMJ is usually innervated by a single terminal axon (unineuronal focal innervation). In the case of mature multi-innervated muscle fibers, NMJs could receive nerve endings from a single axon (unineuronal multi-innervation) or from different axons (polyneuronal multi-innervation; Fig 1). Since we found that innervation in adult laryngeal muscles is exclusively unineuronal,[12] we suggest that the polyneuronal innervation pattern observed in the 7-month-old infant could express a delayed withdrawal of axon terminals from NMJs established during the embryonic period. The persistence of perinatal polyneuronal innervation in human intrinsic laryngeal muscles is also associated with a higher percentage of multi-innervated myofibers than in adults. It could result from the relationship between the process of synapse elimination and the loss of axon terminals at NMJs.[25] Moreover, the decrease of multi-innervation observed in adults continues in the elderly, due to retrograde axonal degeneration with aging.[12]

After birth, the maturation of the NMJs consists of the extension of nerve terminal arborization at the synaptic sites.[3] In the thyroarytenoid muscles of an 8-month-old fetus and a 3-year-old child, poor arborization of nerve terminals until the third year of life was described, suggesting the persistence of maturation of laryngeal nerve terminals beyond 3

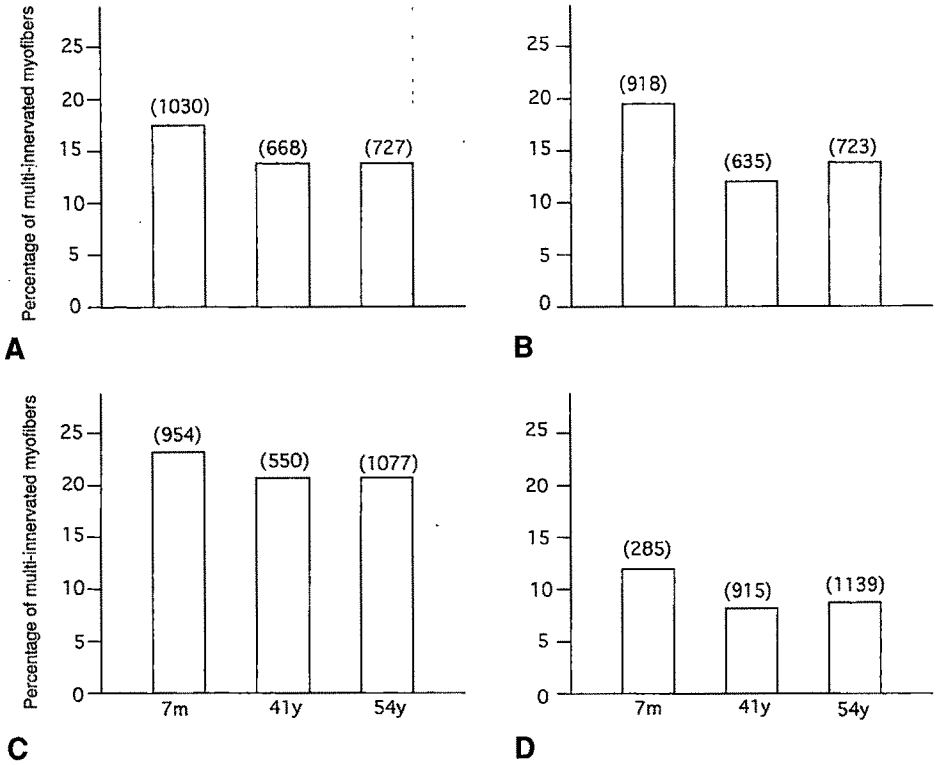

Fig 4. Percentages of multi-innervated myofibers (unineuronal and polyneuronal) in total numbers of fibers recorded (in parentheses). A) Thyroarytenoid muscles. B) Posterior cricoarytenoid muscles. C) Interarytenoid muscles. D) Cricothyroid muscles.

years of age.[13] In the fetus, small "platelike" NMJs were also reported in the posterior cricoarytenoid muscles, with no secondary clefts and with few ChE sites.[26] The later development of striations in intrinsic laryngeal myofibers from embryos and the lack of distinct striations in fetal myofibers were also reported.[13,27] This was the cause of our incapacity to perform quantitative measurements in the fetus and newborn. In laryngeal muscles, the increase in number of ChE sites and the arborization of nerve endings seem to take place slowly during development.[14] "Complex" NMJs, observed in the adult, are probably the outcome of this growth pattern. Double NMJs, opposite one another, were never observed before 7 months of age and could result from the segmentation of a single NMJ that occurs when the myofiber increases in size with maturation.

These results can be discussed with those observed in extraocular muscles, since multi-innervation was also described there.[8-11] The percentage of multi-innervated myofibers in such muscles is nearly the same as those we found in intrinsic laryngeal muscles.[9,10] However, in extraocular muscles, the pattern of innervation (unineuronal or polyneuronal) was previously controversial.[28,29] Finally, Oda[30] demonstrated that multi-innervated myofibers of human extraocular muscles receive terminal nerve endings from different axons (polyneuronal multi-innervation). Thus, this pattern of innervation is different from the unineuronal pattern of innervation that we found in laryngeal muscles. To our knowledge, no comparison between perinatal and adult multi-innervation in human extraocular muscles has been reported in the literature.

In conclusion, the persistence of embryonic polyneuronal innervation in intrinsic laryngeal muscles of the infant was the striking feature that we observed. This finding could result from a delayed process of synapse elimination occurring later than in skeletal muscles, since unineuronal innervation was exclusively found in adults. This hypothesis is supported by the observation that mature motor innervation of human laryngeal muscles is not present at birth. Further studies are needed to relate these findings to the laryngeal dysfunctions observed in newborns.

ACKNOWLEDGMENTS — We thank P. Callard, MD (Laboratoire d'Anatomopathologie, Hôpital Tenon, Paris, France), and N. Brousse, MD (Laboratoire d'Anatomopathologie, Hôpital Necker, Paris, France), for their participation in analysis of the muscle biopsies. A. Blitzer, MD (Department of Clinical Otolaryngology, St Luke's–Roosevelt Hospital Center, New York; New York Center for Voice and Swallowing Disorders), and R. L. Crumley, MD (Department of Otolaryngology–Head and Neck Surgery, UCI Medical Center, University of California, Irvine), stimulated this manuscript by helpful discussions.

REFERENCES

1. Brown MC, Jansen JKS, Van Essen D. Polyneuronal innervation of skeletal muscle in newborn rats and its elimination during maturation. J Physiol (Lond) 1976;261:387-424.

2. Jansen JKS, Fladby T. The perinatal reorganization of the innervation of skeletal muscle in mammals. Prog Neurobiol 1990;34:39-90.

3. Van Essen DC, Gordon H, Soha JM, Fraser SE. Synaptic dynamics at the neuromuscular junction: mechanisms and models. J Neurobiol 1990;21:223-49.

4. Betz WJ. Motoneuron death and synapse elimination in vertebrates. In: Salpeter MM, ed. Neurology and neurobiology: the vertebrate neuromuscular junction. Vol 23. New York, NY: Alan R Liss, 1987:117-62.

5. Rudolph G. Particularités des synapses neuromusculaires dans le muscle vocal de l'homme. Rev Laryngol (Bord) 1962; 83:569-83.

6. Rossi G, Cortesina G. Multi-motor end-plate muscle fibres in the human vocalis muscle. Nature 1965;206:629-30.

7. Bendiksen FS, Dahl HA, Teig E. Innervation pattern of different type of muscle fibres in the human thyroarytenoid muscle. Acta Otolaryngol (Stockh) 1981;91:391-7.

8. Cheng K. Cholinesterase activity in human extraocular muscles. Jpn J Ophthalmol 1963;7:174-83.

9. Teravainen H. Different types of nerve endings in extraocular muscles of the rat. Z Zellforsch 1968;90:372-88.

10. Salpeter MM, McHenry FA, Feng HH. Myoneural junctions in the extraocular muscles of the mouse. Anat Rec 1974; 179:201-24.

11. Mayr R, Gottschall, J, Gruber H, Neuhuber W. Internal structure of cat extraocular muscle. Anat Embryol 1975;148: 25-34.

12. Périé S, Lacau St Guily J, Callard P, Sebille A. The innervation of adult human laryngeal myofibers. J Neurol Sci 1997;149:81-6.

13. Konig WF, Von Leden H. The peripheral nervous system of the human larynx. Part III: The development. Arch Otolaryngol 1961;74:494-500.

14. Gambino DR, Malmgren LT, Gacek RR. Age-related changes in the neuromuscular junctions in the human posterior cricoarytenoid muscles: a quantitative study. Laryngoscope 1990;100:262-8.

15. Pestronk A, Drachman DB. A new stain for quantitative measurement of sprouting at neuromuscular junctions. Muscle Nerve 1978;1:70-4.

16. Salpeter MM. Vertebrate neuromuscular junctions: general morphology, molecular organization, and functional consequences. In: Salpeter MM, ed. Neurology and neurobiology: the vertebrate neuromuscular junction. Vol 23. New York, NY: Alan R Liss, 1987:1-53.

17. Pestronk A, Drachman DB. Motor nerve sprouting and acetylcholine receptors. Science 1988;199:1223-5.

18. Coers C. Structure and organization of the myoneural junction. Int Rev Cytol 1967;22:239-67.

19. Rosen M, Malmgren LT, Gacek RR. Three-dimensional computer reconstruction of the distribution of neuromuscular junctions in the thyroarytenoid muscle. Ann Otol Rhinol Laryngol 1983;92:424-9.

20. Gambino DR, Malmgren LT, Gacek RR. Three dimensional computer reconstruction of the neuromuscular junction distribution in the human posterior cricoarytenoid muscle. Laryngoscope 1985;95:556-60.

21. De Vito M, Malmgren LT, Gacek RR. Three-dimensional distribution of neuromuscular junctions in human cricothyroid. Arch Otolaryngol 1985;111:110-3.

22. Freije J, Malmgren LT, Gacek RR. Motor end-plate distribution in the human interarytenoid muscle. Arch Otolaryngol Head Neck Surg 1987;113:63-8.

23. Freije J, Malmgren LT, Gacek RR. Motor end-plate distribution in the human lateral cricoarytenoid muscle. Arch Otolaryngol Head Neck Surg 1986;112:176-9.

24. Bennett MR, Pettigrew AG. The formation of synapses in striated muscle during development. J Physiol (Lond) 1974; 241:515-45.

25. Redfern PA. Neuromuscular transmission in new-born rats. J Physiol (Lond) 1970;209:701-9.

26. Yoshihara T, Kandu T, Yaku Y, Kaneko T. Neuromuscular junctions of the posterior cricoarytenoid muscle in human adult, human fetus and cat histochemical and electron microscopic study. Acta Otolaryngol (Stockh) 1984;97:161-8.

27. Muller F, O'Rahilly R, Tucker JA. The human larynx at the end of the embryonic period proper. 2. The laryngeal cavity and the innervation of its lining. Ann Otol Rhinol Laryngol 1985;94:607-17.

28. Pilar G. Further study of the electrical and mechanical responses of slow fibers in cat extraocular muscles. J Gen Physiol 1967;50:2289-300.

29. Bach-y-Rita P, Lennerstrand G. Absence of polyneuronal innervation in cat extraocular muscles. J Physiol (Lond) 1975; 244:613-24.

30. Oda K. Motor innervation and acetylcholine receptor distribution of human extraocular muscle fibers. J Neurol Sci 1986; 74:125-33.

COMPARISON OF NERVE BANKING TECHNIQUES IN DELAYED LARYNGEAL REINNERVATION

K. LINNEA PETERSON, MD
SEATTLE, WASHINGTON

ROBERT J. ANDREWS, MD
LOS ANGELES, CALIFORNIA

JOEL A. SERCARZ, MD
LOS ANGELES, CALIFORNIA

KEVIN KEVORKIAN, MD
LOS ANGELES, CALIFORNIA

MING YE, MD
LOS ANGELES, CALIFORNIA

KEITH E. BLACKWELL, MD
LOS ANGELES, CALIFORNIA

GERALD S. BERKE, MD
LOS ANGELES, CALIFORNIA

Successful laryngeal transplantation will require adequate reinnervation of the larynx to allow phonation, coordinated swallowing, and respiration. A delay between laryngectomy and transplantation would be necessary in oncology patients because of the need for immunosuppression. In these patients, reinnervation of the donor organ would require "banking" and recovery of dormant recipient recurrent laryngeal nerves (RLNs). This pilot study was undertaken to compare the effectiveness of RLN storage using 1 of 2 techniques: 1) inserting the nerve into a muscle pocket or 2) anastomosing the proximal RLN stump to the ansa cervicalis. Six months following nerve transection and "banking," the proximal anterior branch of the RLN was reanastomosed to the distal anterior segment and the posterior branch was anastomosed directly to the posterior cricoarytenoid muscle. Tensionometry, image analysis, and electromyographic data were collected 1 year later. Results show reinnervation of adductors and abductors with both techniques. Banking of the RLN branches during total laryngectomy is effective and should permit delayed physiological reinnervation following laryngeal transplantation.

KEY WORDS — delayed reinnervation, laryngeal reinnervation, laryngeal transplantation.

INTRODUCTION

Laryngeal transplantation remains an elusive goal of laryngologists. Several criteria must be met in order for laryngeal transplantation to be successful. The donor organ must work as a dynamic functional unit that allows phonation, coordinated swallowing without aspiration, and an adequate airway diameter. These functions must be equal to or better than those of patients with a total laryngectomy and excellent tracheoesophageal fistula speech.

Immunosuppression must be adequate to allow organ survival without significant compromise of the patient's overall health or oncological result. Unless more targeted immunosuppression is developed, patients with malignancies will require a delay between laryngectomy and transplantation in the range of 1 to 2 years in order to reduce the likelihood of recurrence. This delay adds complexity to an already challenging task, requiring return of appropriate function of a recipient nerve that has been dormant for an extended period of time. The nerve must have adequate axon sprouting into the donor larynx to reinnervate the musculature. Once the larynx has been transplanted, 6 to 12 months must pass before the functional outcome is known. In the interim, the patient requires tracheostomy and must depend on alternative methods of communication, such as use of an electrolarynx.

Techniques and outcomes of laryngeal reinnervation have varied. Methods include direct anastomosis,[1,2] nerve grafting[3] with nerves such as the vagus and phrenic, laryngeal nerve-muscle pedicle,[4] and nerve-muscle pedicle reinnervation with a branch of the ansa.[5] Outcome has been contradictory at times, with some investigators reporting poor outcome with little evidence of reinnervation[6] and others reporting moderate to good results.[5,7,8] More recent techniques have involved selective reinnervation of the abductor and adductor branches of the recurrent laryngeal nerve (RLN).[2,8] These results have been promising, achieving reinnervation and function while minimizing the problem of synkinesis[9] and paradoxical vocal cord motion. However, each of these studies was done with immediate repair or grafting.

From the Division of Head and Neck Surgery, University of California, Los Angeles School of Medicine, Los Angeles, California. This work was supported by Veterans Administration Merit Review Grant 0001. This study was performed in accordance with the PHS Policy on Humane Care and Use of Laboratory Animals, the NIH *Guide for the Care and Use of Laboratory Animals*, and the Animal Welfare Act (7 U.S.C. et seq.); the animal use protocol was approved by the Institutional Animal Care and Use Committee (IACUC) of the University of California, Los Angeles.

Presented at the meeting of the Pacific Coast Oto-Ophthalmological Society, San Diego, California, June 21-24, 1997. Winner of the 1997 Resident Research Award of the Pacific Coast Oto-Ophthalmological Society.

CORRESPONDENCE — K. Linnea Peterson, MD, Virginia Mason Medical Center, Dept of Otolaryngology, X10-ON, 1100 Ninth Ave, Seattle, WA 98111.

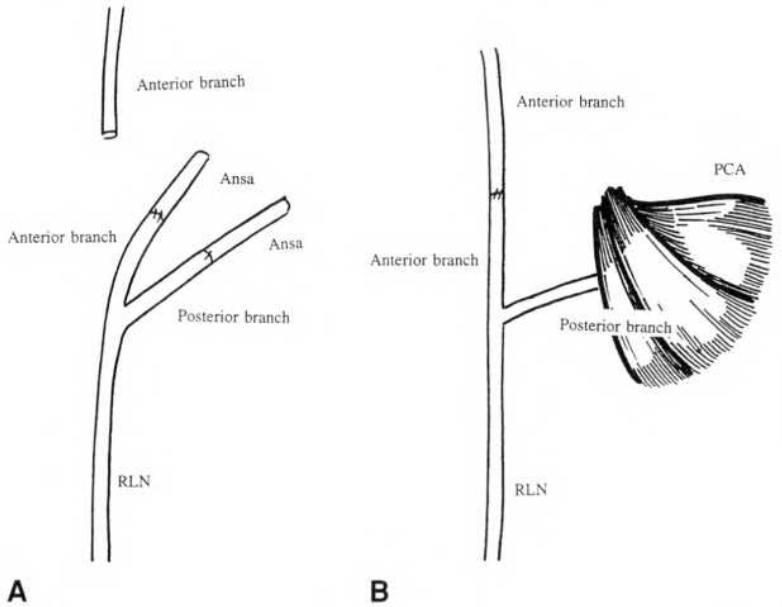

Fig 1. Schematic of surgical procedure for ansa storage. A) Stage 1 procedure with anastomosis of proximal anterior and posterior branches to ansa cervicalis branches. B) Stage 2 procedure with anastomosis of proximal anterior branch to distal segment of anterior branch, and placement of posterior segment into pocket of posterior cricoarytenoid (PCA) muscle. RLN — recurrent laryngeal nerve.

The current study was undertaken to address the outcome of "banking" nerves for later transplantation, to minimize degeneration of the nerve. Two different methods were used and results were compared in this preliminary study. Neural storage, or anastomosis to a branch of the ansa, was compared to the use of a nerve-muscle pedicle or a nerve-muscle "pocket."

MATERIALS AND METHODS

Experimental Model. Two male mongrel dogs (25 and 35 kg) were studied. The first dog underwent division of the anterior and posterior branches of the RLN with anastomosis of the proximal segments to the ansa cervicalis. The second dog underwent division of these branches with use of a nerve-muscle pedicle to the sternothyroid muscle for the posterior branch, with the anterior branch being tucked directly into a muscle pocket of this same muscle.

Methods. Each dog was anesthetized with intravenous pentobarbital sodium and placed supine on an operating table. Direct laryngoscopy was performed to confirm normal laryngeal anatomy. The animal was intubated with a 7.0 endotracheal tube under direct visualization, and kept under general anesthesia with inhalation of halothane in the range of 1% to 1.5%, with oxygen at 4 L/min.

A midline incision was made from the upper border of the thyroid cartilage to just below the cricoid cartilage. The superior laryngeal nerve was identified and preserved. The inferior border of the cricopharyngeus was cut to allow access to the distal portion of the RLN at the point of bifurcation into anterior and posterior branches, and the branches were then isolated on the left side. In the first experimental dog, branches of the ansa cervicalis were identified and cut. The proximal segments of the anterior and posterior branches of the RLN were then anastomosed to distal segments of the ansa (Fig 1). The second experimental animal had a muscle pedicle cut from the posterior cricoarytenoid (PCA) muscle for the posterior branch of the RLN. This muscle pedicle was sutured to the sternothyroid muscle. The anterior branch was cut, and the proximal neural end was placed into a pocket in the strap muscle and secured (Fig 2). The wounds were then closed, and the animals were recovered.

The dogs were kept for 6 months and then returned to the operating room for a second procedure, at which time the anterior and posterior branches of the RLN were reanastomosed or placed into target muscles. By the same protocol, the dogs were placed under general anesthesia. Via the same approach, the anterior and posterior branches of the RLN were isolated. The proximal and distal ends of the anterior branches were identified and reanastomosed; in the first dog, this required transection of the RLN-ansa segment. The new anastomosis may have contained a portion of the ansa graft. The posterior branch was cut, again possibly with some ansa graft, and the end was inserted into a pocket of the PCA muscle. In the second dog, the proximal portion of the anterior branch was cut just prior to its insertion into the strap muscle. The distal end of the anterior branch was located, and the nerve ends were reanastomosed. The posterior branch was cut just as it entered the strap muscle, and the proximal end was tucked into the PCA muscle. The dogs were again recovered, with suture removal at about 2 weeks.

One year later, the dogs were returned for a third

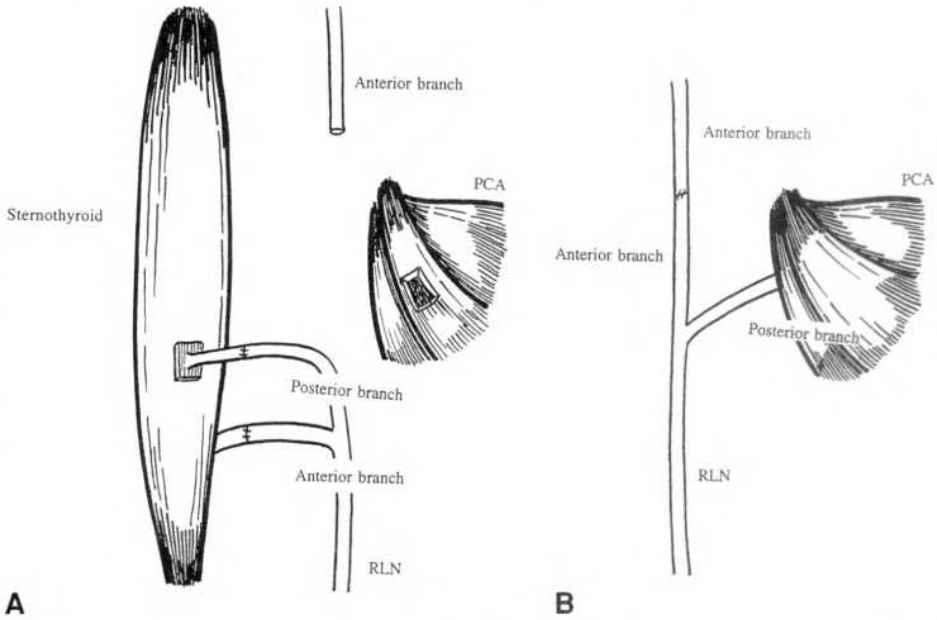

Fig 2. Schematic of surgical procedure for muscle storage. A) Stage 1 procedure with banking of anterior branch into pocket of sternothyroid muscle and muscle pedicle of posterior branch into strap muscle. B) Stage 2 procedure with anastomosis of proximal and distal ends of anterior segment, and placement of posterior segment into pocket in PCA muscle.

surgery, at which time tensionometry, video, and electromyography (EMG) data were collected. The same protocol for general anesthesia was followed. A midline incision was made from the superior end of the thyroid cartilage to just above the sternal notch. A distal tracheostomy was placed, and the oral endotracheal tube was removed. A mouth gag was used to allow direct visualization of the larynx. A button was placed through the epiglottis to suspend the epiglottis out of the field of view. Videolaryngoscopy and tensionometry were performed with obstructive respiratory dyspnea. Electromyography was performed under conditions of obstructive respiratory dyspnea and pharyngeal stimulation, recording signals from the PCA and thyroarytenoid (TA) muscles, respectively. The first dog, with muscle banking, developed bilateral tension pneumothoraces during the experiment and was unable to be resuscitated. Tensionometry data are not available for this animal.

The RLNs were dissected out bilaterally, and rubber electrodes (monopolar, flexible, conductive neoprene with silicone, coated by insulating silicone KE45 W) were applied. Videolaryngoscopy and tensionometry data were collected with nerve stimulation. Finally, the animals were humanely euthanized according to the Animal Care and Use protocol. The anterior and posterior branches, as well as the main trunk, of the left RLN were harvested from both animals. The larynx was also removed. All tissue was placed in 10% formalin for fixation.

Equipment. For videolaryngoscopy, a 0° Storz endoscope was placed through the mouth and above the vocal cords. A video camera was used to record images on a Sony U-matic Videocassette Recorder, model VO-9850 (Sony, Japan). Analysis was performed with ImagePro for Windows 3.1 software (Media Cybernetics, NJ) on a Zeos 486 PC, with a FlashPoint ISA (Version 2.0, Integral Technologies, Indianapolis, Ind) color frame grabber. Measurements were made of vocal cord excursion under the given conditions, to compare the relative excursion of each side against the midline. Measurements were made of glottal area in the relaxed state and with maximal abduction. Measurements with nerve stimulation were compared from separate trials.

Abductory force measurements were made by a "tensionometer," as described by Nasri et al,[10] by placing a straight rod with a plate with a surface area of 3.06 mm^2 just lateral to the midportion of the arytenoid. The tensionometer was adapted with a digital force gauge (DF-0.5R, Shimpo, Japan). Adductory measurements were made with the same rod, by placing the plate medial to the true vocal cord, just anterior to the anterior border of the arytenoid. Comparative measurements were made for abductory and adductory force under each set of conditions. Five sequential measurements of abduction or adduction were made for each trial. Zero and peak readings were recorded, and the zero settings were subtracted out.

A constant current nerve stimulator was used (WR Medical Electronics Co, St Paul, Minn, model S2LH) for RLN stimulation. The frequency and duration of stimuli were 80 Hz and 1.5 milliseconds' duration, respectively. The stimulus levels for abduction measurements were set by finding the threshold level for maximal abduction. The adductory measurements were made at the threshold for complete glottal closure.

Electromyography was performed with the Nicolet

TABLE 1. TENSIONOMETRY DATA FOR ANSA STORAGE ANIMAL

	Right	*Left*
PCA (abduction)		
Tube occlusion	1.95 ± 0.71	2.42 ± 0.24
RLN stimulation	2.72 ± 0.08	1.98 ± 0.40
TA (adduction)		
RLN stimulation	4.38 ± 0.50	4.50 ± 0.25

Data are in grams (mean ± SD).
PCA — posterior cricoarytenoid, RLN — recurrent laryngeal nerve, TA — thyroarytenoid.

TABLE 2. IMAGE ANALYSIS COMPARING EXCURSIONS OF RIGHT VERSUS LEFT CORDS AND GLOTTAL AREA IN ANSA STORAGE ANIMAL VERSUS MUSCLE STORAGE ANIMAL

	Right	*Left*	*Change in Area**
Tube occlusion			
Ansa	57.13 ± 1.99	42.87 ± 1.99	36.97 ± 4.42
Muscle	61.80 ± 2.32	38.20 ± 2.32	30.89 ± 3.88
Stimulation of RLN			
Muscle	33.79 ± 6.66	37.22 ± 4.13	
After SLN transection			
Muscle			15.89 ± 4.21

Data are percent (mean ± SD).
SLN — superior laryngeal nerve.
*Relaxed state to maximal abduction.

Viking IV system (Nicolet, Madison, Wis). Concentric needle electrodes (26 gauge, 3.7 cm long, recording area 0.068 mm^2; Nicolet) were used, with the needles placed into the respective muscles via a transoral approach.

All animal protocols were approved by the UCLA Animal Care and Use Committee and were performed in compliance with the local, state, and federal regulations for the humane use of animals in research.

Statistical Analysis. Statistical analysis was performed by a 1-way, repeated-measures analysis of variance comparing sides under each set of conditions. Tensionometry data were assessed to compare abductory and adductory force on sides under conditions of nerve stimulation and obstructive respiratory dyspnea. The data were analyzed with SYSTAT software. Glottal images obtained from nerve stimulation were analyzed to compare vocal cord excursions on each side. These data are reported in terms of mean and standard deviation.

RESULTS

Tensionometry. Tensionometry data are available only for the dog that underwent ansa storage (Table 1 and Fig 3). The results show no significant difference between the left side and the right for abductory force under conditions of tube occlusion. With stimulation of the posterior branch of the RLN, abductory force was greater on the right than the left, with a statistically significant difference: $p < .05$, $F(1,4) = 25.35$. With stimulation of the main trunk of the RLN, there was nearly equal force of adduction and no statistically significant difference.

Image Analysis. Video data demonstrated vocal cord excursion from midline of right versus left vocal cords, as well as change in glottal area from the relaxed state to full abduction under varying conditions (Table 2 and Fig 4). These results show the excursion on the right to be approximately 57% of the glottal width, versus 43% for the left under conditions of tube occlusion for the animal with ansa storage (SD 1.99%). This 43% for the left represents 75% of the excursion demonstrated on the right. The animal with muscle storage had 62% for the right versus 38% for the left, under the same conditions (SD 2.32% for both sides). This is 62% of the expected excursion, or the excursion found on the right. The change in glottal area from the relaxed state to full abduction with tube occlusion shows a 36.97% change (SD 4.42%) in total area with ansa storage,

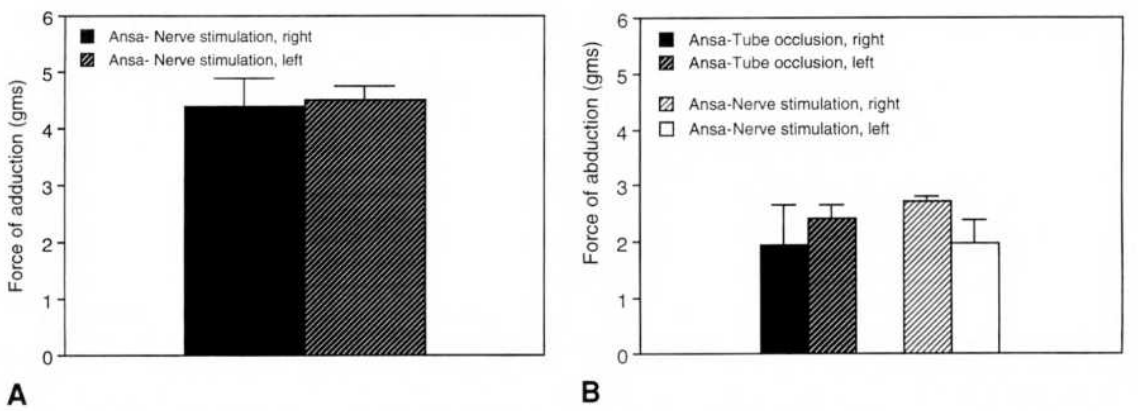

Fig 3. Ansa storage. A) Force of adduction with nerve stimulation, right versus left. B) Force of abduction, tube occlusion versus nerve stimulation, right versus left.

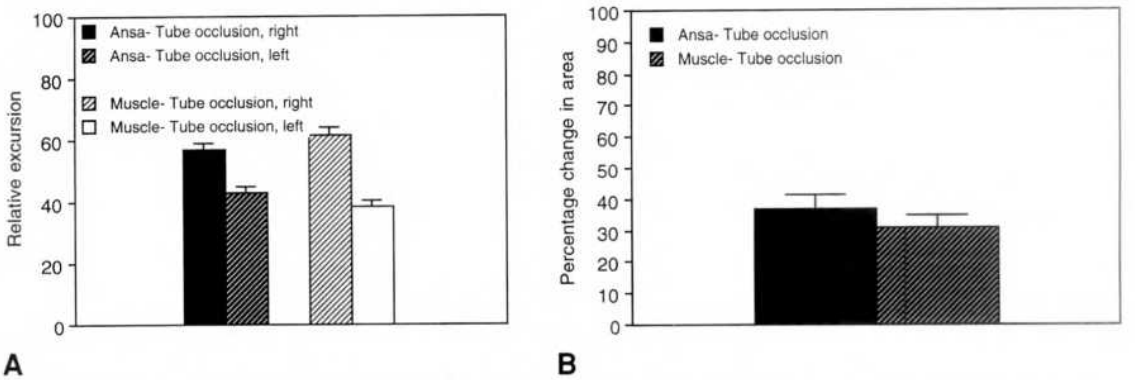

Fig 4. Image analysis. A) Relative excursion with tube occlusion, ansa versus muscle storage, right versus left. B) Percentage change in area with tube occlusion, ansa versus muscle storage.

versus only a 30.89% change (SD 3.88%) with muscle storage. The results for RLN stimulation show a 33.79% change (SD 6.66%) in area with stimulation on the right versus a 37.22% change (SD 4.13%) with stimulation on the left in the dog with muscle banking. No RLN stimulation data are available for the ansa storage dog.

Electromyography. The EMG data for the 2 animals showed evidence of selective reinnervation of the TA and PCA muscles (Figs 5 and 6). There was physiologically appropriate firing of motor units, the PCA firing with respiration and the TA firing with pharyngeal stimulation and adduction. The dog with ansa storage showed a single motor unit for both the TA and PCA muscles. The dog with muscle storage demonstrated similar signals, although with smaller motor units.

DISCUSSION

The success of laryngeal transplantation for cancer patients requires the coordination of immunosuppression and functional reinnervation. The latter appears to be the most limiting factor, while improvements in immunosuppression have allowed excellent results in solid organ transplantation. Techniques in reinnervation have evolved, especially over the past 20 years, with methods to avoid synkinesis. In our laboratory, selective reanastomosis of the adductor and abductor branches has been successful in achieving reinnervation with functional, physiological motion.[2,10]

The desire to avoid immunosuppression of cancer patients requires a delay in transplantation until the risk of cancer recurrence is low. In order for these patients to be eligible for future transplantation, they would need to have their RLNs preserved by "banking" them to prevent nerve degeneration.

The results of this study demonstrate return of physiological motion following denervation of the anterior and posterior branches of the RLN with a 6-month delay between transection and reanastomosis. One year was allowed for neural regeneration prior to data collection. Two different techniques of banking were used: ansa cervicalis storage with neural anastomosis of the proximal segments of the anterior and posterior branches of the RLN to branches of the ansa; and muscle storage with the anterior branch tucked into a pocket in the sternothyroid muscle, and a muscle pedicle of the posterior branch attached to this same strap muscle.

Tensionometry data show good return of force with ansa storage, with nearly equal adductory force. Abductory force also had good recovery, with no statistically significant difference between the operated and control sides with obstructive respiratory dyspnea. With nerve stimulation, there was a significant difference, with the left being weaker than the right. Tensionometry measures could not be performed in the muscle banking animal.

The image data also support the recovery of both laryngeal abduction and adduction. Both animals had

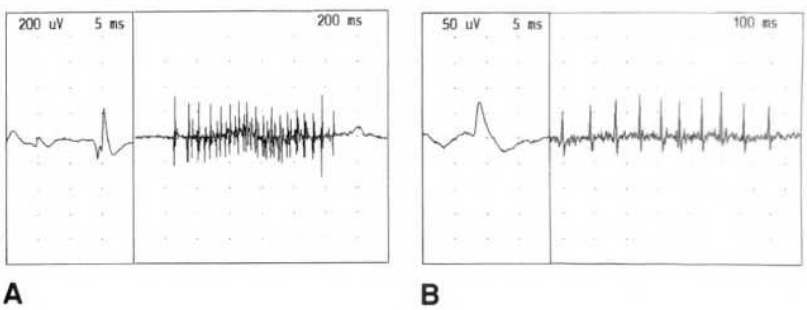

Fig 5. Electromyography with ansa storage. A) PCA muscle with tube occlusion in single motor unit followed by burst of activity with abduction. B) Thyroarytenoid (TA) muscle with glottal closure in single motor unit and activity with adduction.

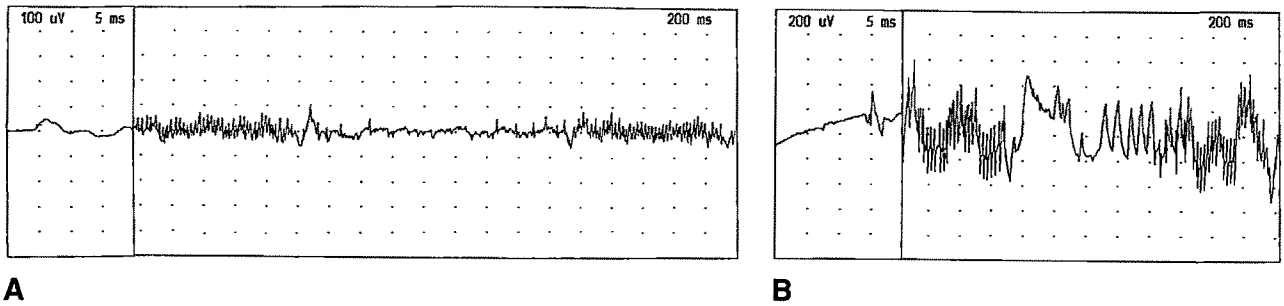

Fig 6. Electromyography with muscle storage. A) PCA muscle with tube occlusion in distant single motor unit and tracing showing phasic activity with respiration. B) TA muscle with glottal closure in single motor unit and tracing showing variation in activity with contraction.

appropriate vocal cord motion with obstructive respiratory dyspnea and nerve stimulation. The ansa storage animal had an excursion of 75.04% of expected for the operated side with obstructive respiratory dyspnea (42.87% of total glottal excursion on the operated side versus 57.13% for the nonoperated or control side). The dog with muscle storage achieved 61.8% of excursion with tube occlusion. Comparison of changes in glottal area with tube occlusion demonstrate a greater percentage change from the relaxed state to complete abduction in the animal with ansa storage versus the muscle banking dog (36.97% change for ansa versus 30.89% change for muscle).

Electromyography data also demonstrated reinnervation in both animals, with PCA motor units firing appropriately with respiration under obstructive dyspnea conditions. Thyroarytenoid motor units fired with light anesthesia and subsequent glottal closure.

Overall, results from "banking" the nerves demonstrated functional recovery and reinnervation without synkinesis following 6 months of neural storage. Both methods were successful. Anastomosis to a similar-size nerve such as the ansa cervicalis would be expected to be preferable for nerve preservation, rather than storage in a muscle. Because only 2 animals were studied, additional investigation is necessary to determine whether one method offers a consistent advantage over the other.

Moreover, results from this study indicate that current patients who undergo total laryngectomy should, when it is oncologically feasible, undergo banking of the anterior and posterior RLN branches on at least 1 side. It is impossible to predict how immunosuppression techniques will evolve. Total laryngectomy patients with banked nerves will have the potential to undergo laryngeal transplantation with return of physiological function.

ACKNOWLEDGMENTS — The authors thank Jody Kreiman, PhD, for her assistance with statistical analysis, Deborah Watson, MD, for her illustrations, and Michael Graves, MD, for his help with electromyography.

REFERENCES

1. Gordon JH, McCabe BF. The effect of accurate neurorrhaphy on reinnervation and return of laryngeal function. Laryngoscope 1968;78:236-50.

2. Green DC, Berke GS, Graves MC, Natividad M. Physiologic motion after vocal cord reinnervation: a preliminary study. Laryngoscope 1992;102:14-21.

3. Iwamura S. Functioning remobilization of the paralyzed vocal cord in dogs. Arch Otolaryngol 1984;100:122-9.

4. Hengerer AS, Tucker HM. Restoration of abduction in the paralyzed canine larynx. Arch Otolaryngol 1973;97:247-50.

5. Tucker HM. Human laryngeal reinnervation. Laryngoscope 1976;86:769-79.

6. Takashiro T. Experimental studies on the reinnervation of larynx after accurate neurorrhaphy. Laryngoscope 1972;82:225-36.

7. Murakami Y, Kirchner JA. Vocal cord abduction by regenerated recurrent laryngeal nerve: an experimental study in the dog. Arch Otolaryngol 1971;94:64-8.

8. Crumley RL. Selective reinnervation of vocal cord adductors in unilateral vocal cord paralysis. Ann Otol Rhinol Laryngol 1984;93:351-6.

9. Crumley RL. Laryngeal synkinesis: its significance to the laryngologist. Ann Otol Rhinol Laryngol 1989;98:87-92.

10. Nasri S, Sercarz JA, Azizzadeh B, Kreiman J, Berke GS. Measurement of adductory force of individual laryngeal muscles in an in vivo canine model. Laryngoscope 1994;104:1213-8.

PEDIATRIC TRACHEOSTOMY: A CHANGING PROCEDURE?

RALPH F. WETMORE, MD
MARY E. THOMPSON, RN, BSN
ROGER R. MARSH, PHD
LAWRENCE W. C. TOM, MD
PHILADELPHIA, PENNSYLVANIA

In 1982, the experience with tracheostomy at The Children's Hospital of Philadelphia was reported for 1971 through 1980. We have now reviewed 450 cases for the period from 1981 through 1992, and compared the characteristics of these cases with those in the previous review. Long-term follow-up was available on 83% of cases, and the median follow-up was 2.96 years. Patients received a tracheostomy for airway obstruction (38%), chronic ventilation (53%), or multiple indications (9%). The mean duration of tracheotomy (adjusted for death and loss to follow-up) was 2.13 years. The tracheostomy-related mortality was 0.5%, and the non–tracheostomy-related mortality was 22%. Nineteen percent of patients had complications in the first postoperative week, and 58% had 1 or more late complications. In comparison with the previous study from our institution, there was a great increase in long-term tracheostomy and a continuing trend away from tracheostomy for short-term airway management. Better monitoring and improvements in parental teaching may have contributed to a decrease in tracheostomy-related mortality.

KEY WORDS — airway obstruction, tracheostomy.

INTRODUCTION

In 1982, we reported the pediatric tracheostomy experience at The Children's Hospital of Philadelphia from January 1971 through December 1980.[1] Several important trends were evident from that review. The yearly incidence of tracheostomy remained relatively constant during the decade of study. Upper airway obstruction (24%) and neurologic disorders (24%) were the primary diagnoses. The most common indication for tracheostomy was prolonged intubation (53%), with the other major indications being upper airway obstruction (39%) and pulmonary toilet (4%). The overall complication rate was 49%, with an early complication rate of 28% and a late complication rate of 53%. The tracheostomy-related mortality was 2%. To determine if there had been a change in the demographics and complication rates of pediatric tracheostomy over the past 2 decades, we conducted a review of the tracheostomy experience from 1981 through 1992 for comparison with our previous study.

METHODS

Tracheostomies performed at The Children's Hospital of Philadelphia from January 1981 through December 1992 were reviewed retrospectively. A list was compiled from the operative logs and included tracheostomies performed by the otolaryngology and general surgery services. A total of 450 cases were identified. These were analyzed with respect to the following variables: age, diagnosis, indication for procedure, duration of tracheostomy, early and late complications, and mortality. Early complications were defined as those occurring in the operating room or during the first postoperative week. At the end of the first week, the tracheostomy stoma was felt to be mature, and the first tube change was performed. Late complications were defined as those occurring after the first week. Documentation was variable, because some patients were transferred to other institutions within days of their surgery and because parts of the chart could not be located in some cases. Demographic data, diagnoses, and indications for tracheostomy were available for at least 97% of cases. Records were available for 373 patients during the first week. Long-term follow-up data (90 days or until death or decannulation) were available for 373 patients. Some children in the early complication analysis were lost to long-term follow-up or died within the first week. An equal number of cases excluded from that analysis received long-term tracheostomy care by our department and are included in the late complication series.

RESULTS

The great majority (67%) of the pediatric tracheostomies were performed during the first year of life (Fig 1). The number of tracheostomies performed remained relatively constant during the years of the study, without obvious changes in age distribution. As with the previous study, there was a slight male predominance (58%). The primary indications for

From the Department of Pediatric Otolaryngology, The Children's Hospital of Philadelphia and the University of Pennsylvania School of Medicine, Philadelphia, Pennsylvania.

CORRESPONDENCE — Ralph F. Wetmore, MD, Dept of Pediatric Otolaryngology, The Children's Hospital of Philadelphia, 34th St and Civic Center Blvd, Philadelphia, PA 19104.

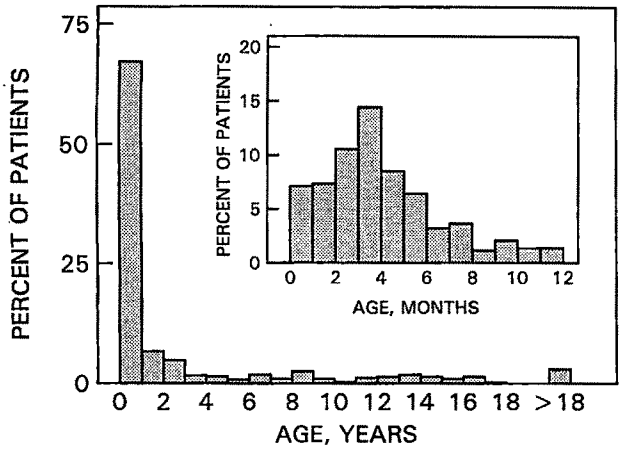

Fig 1. Distribution of patients by age at time of tracheostomy: 1981-92 (n = 436 patients).



Fig 2. Primary diagnoses of tracheostomy patients: 1981-92 (n = 445 patients). Bronchopulmonary dysplasia was more common, and croup much less common, than in previous decade. UAOBS — upper airway obstruction, Misc. — miscellaneous.

tracheostomy remained virtually unchanged from the 1971-80 study, with prolonged ventilation remaining the most frequent indication for surgery (53% of cases in both series). Airway maintenance was the primary indication in 39% of cases in the first series and in 38% in this series. The remaining cases had other or multiple indications.

Bronchopulmonary dysplasia (BPD) was the primary diagnosis of greatest incidence (29%), followed by neurologic disorders (24%; Fig 2). Use of tracheostomy for the management of croup was much less common in the 1981-92 study compared to the 1971-80 study: 1.1% versus 7.6%, a significant reduction ($p < .001$). The duration of tracheostomy ranged from 5 days to 12.8 years. The median was 778 days, as estimated by using the Kaplan-Meier statistic to adjust for intercurrent death and incomplete follow-up. An increase in tracheostomies of greater than 24 months' duration in this study compared to the previous one (53% versus 17% as estimated from Kaplan-Meier curves) was due to the increase in chronically ventilated patients (Fig 3). Of the 373 patients with long-term follow-up, 190 were decannulated, 94 died, and 89 were still cannulated. For these cannulated patients, the median follow-up was 2.96 years.

Among the 373 patients with 1 week of follow-up, 71 patients suffered 92 early complications (Table 1). Obstruction of the tracheostomy tube was the most common early complication, seen in 10% of cases. Accidental decannulation was seen less frequently than in the 1971-80 study (5% versus 24%). In examining the prevalence of early complications, there was no statistically significant difference between children under 1 year of age and those older than 1 year.

Among the 373 patients with long-term follow-up, there were 409 late complications affecting 216 patients (Table 2). Of the late complications, tracheal

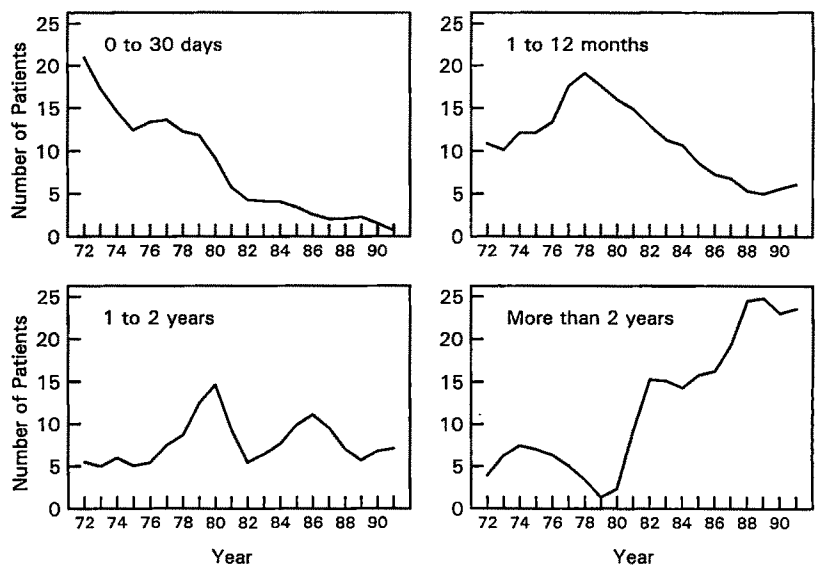

Fig 3. Duration of tracheostomy from 1971 to 1992 at Children's Hospital of Philadelphia, adjusted for death and loss to follow-up. Three-point smoothing was employed. For example, each 1972 data point is sum of one half of original 1972 datum, plus one quarter of 1971 and 1973 points. Likewise, 1991 — last point — is weighted average of 1990 through 1992. Trend away from short-term tracheostomy continues, and there is great increase in long-term tracheostomy.

TABLE 1. EARLY COMPLICATIONS (WITHIN SEVEN DAYS)

Complication	Patients No.	Patients %
Obstruction	37	9.9
Accidental decannulation	18	4.8
Infection	18	4.8
Pneumothorax	5	1.3
Pneumomediastinum	3	0.8
Pneumonia	3	0.8
Emphysema	2	0.5
Hemorrhage	1	0.3
Other	5	1.3
All complications	92	24.7
Patients with 1 or more complications	71	19.0
Patients with none	302	81.0
Total patients	373	100.0

Based on patients followed up for at least 7 days, or until death or decannulation.

granulomas were most common (41%), while the prevalence of tracheocutaneous fistula remained almost exactly the same as in the 1971-80 study (20%). Children under 1 year of age were significantly more likely than older children to have complications; 66% of the younger and 42% of the older children had 1 or more complications ($p < .001$).

In reviewing overall mortality, the Kaplan-Meier survival curves, adjusted for cases decannulated or lost to follow-up, show a higher short-term mortality in the 1971-80 series, which included many children receiving a tracheostomy for cardiac surgery (Fig 4). The adjustment for decannulated patients permits comparisons between the 2 series in spite of their very different durations of tracheostomy and illustrates the survival experience of those patients

TABLE 2. LATE COMPLICATIONS (AFTER 7 DAYS)

Complication	Patients No.	Patients %
Tracheal granuloma	152	40.8
Tracheocutaneous fistula	73	19.6
Infection	55	14.7
Stomal granulation	36	9.7
Obstruction	31	8.3
Accidental decannulation	21	5.6
Pneumonia	8	2.1
Tracheomalacia	5	1.3
Pneumothorax	2	0.5
Hemorrhage	2	0.5
Other	24	6.4
All complications	409	109.7
Patients with 1 or more complications	216	57.9
Patients with none	157	42.1
Total patients	373	100.0

Based on patients followed up for at least 90 days, or until death or decannulation.

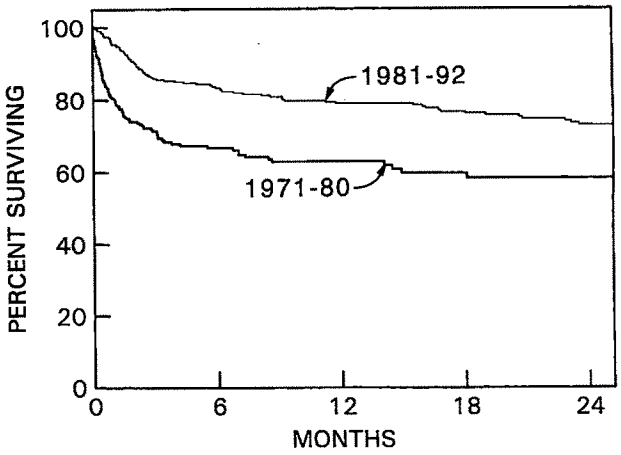

Fig 4. Kaplan-Meier curves for 1971-80 and 1981-92 series comparing survival of children with tracheostomies. Higher mortality in 1971-80 series reflects greater use of tracheostomy for airway management in acutely ill patients during that period.

who were tracheostomized for long periods, but it does exaggerate the actual mortality per tracheostomy. Tracheostomy-related mortality declined from 2% in the 1971-80 study to 0.5% in the current series. Mortality from other causes, not adjusted for loss to follow-up, was 22% in this series and 26% in the previous series.

COMMENT

The incidence of tracheostomy in the 1981-92 study remained relatively constant with only a slight decrease in number compared to the 1971-80 study from our institution: 37.5 cases per year versus 42 cases per year.[1] Figure 5 demonstrates a declining incidence of tracheostomy when compared to the number of hospital admissions. Figure 1 illustrates the peak prevalence at 3 to 4 months of age — a

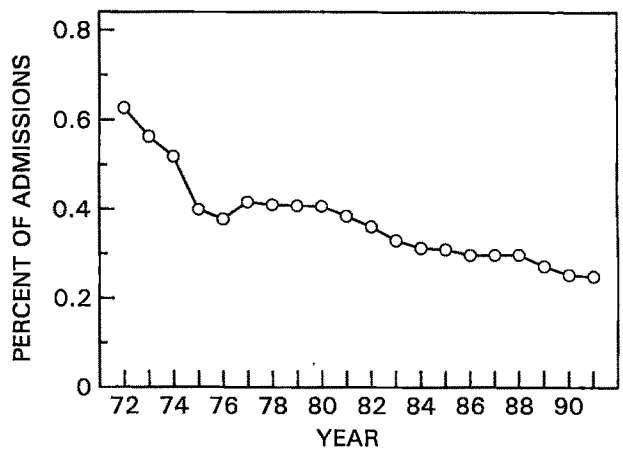

Fig 5. Incidence of tracheostomy as percentage of hospital admissions from 1971 to 1992 at Children's Hospital of Philadelphia. Number of procedures per year has been fairly constant, but percentage of admissions has declined as number of admissions per year has increased. Three-point smoothing was used, as described in Fig 3.

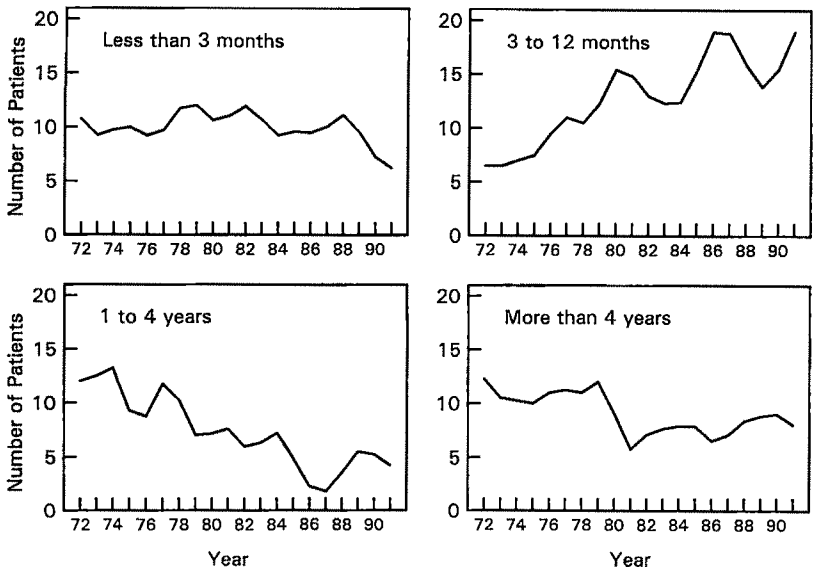

Fig 6. Trends of age at tracheostomy from 1971 through 1992. Three-point smoothing was employed, as described in Fig 3. Proportion of infants has increased with greater number of cases of bronchopulmonary dysplasia and decreased use of tracheostomy in short-term management of acutely ill patients and surgical cases.

peak noted by other authors.[2] Nearly three quarters of patients in this series were under the age of 2, compared to 58% in the 1971-80 series. This trend toward younger age is illustrated in Fig 6 and has been reported by others.[3] In several series of pediatric tracheostomy patients, the male-female ratio ranges from equal to a male predominance of 2 to 1.[2-9] Our series had a male-female ratio of 1.41 to 1.

In comparing the 1971-80 and 1981-92 series, there has been essentially no change in the proportion of indications for tracheostomy. These values are similar to those reported by Waki et al,[8] but differ from those of Crysdale et al,[4] who reported a much greater incidence in children suffering from airway obstruction. Ward et al[9] have reported an increasing incidence of tracheostomy for prolonged ventilation and a coinciding decrease for airway obstruction, but their study included only children under 5 years of age.

In the 1971-80 study, upper airway obstruction and neurologic disorders were the most frequent diagnoses. In the current study, the incidence of neurologic disorders has remained the same, while BPD has become the most frequent diagnosis of pediatric tracheostomy patients. The statistically significant increase in patients with BPD in the 1981-92 study as compared to the 1971-80 study (29% versus 12%; $p < .001$) is a reflection of the longer survival of patients with this disorder who would not have survived in the past. While the incidence of tracheostomy for BPD has increased, there has been a coinciding decrease in the need for tracheostomy in the treatment of laryngotracheobronchitis (croup) that is a reflection of improved airway management by pediatric intensivists at this hospital.

In the 1971-80 study, 34% of the tracheostomies were of less than 1 month's duration, adjusted for losses to follow-up and death. Use of tracheostomy for cardiac and craniofacial surgery and to manage the airway in acute epiglottitis accounted for many of these cases. In the 1981-92 review, only 6% of tracheostomies were of less than 1 month's duration, and approximately 72% were of up to a year's duration. This increase in the duration of tracheostomy is demonstrated in Fig 3 and reflects an increasing need for chronic ventilation and increased survival of such patients — a change noted by other authors.[3,6]

The prevalence of early complications in the 1981-92 study mirrors that of the previous study, although obstruction of the tracheostomy tube occurred more commonly in the 1981-92 study. Other major complications include accidental decannulation and infection involving either the stoma or the trachea. These 3 major complications were reported commonly in other series.[4,9] Pneumothorax and pneumomediastinum occurred in a few patients in this series and were the most frequent complications in series by Arcand and Granger,[3] Line et al,[5] and Waki et al.[8]

Tracheal granulation and persistent tracheocutaneous fistula were the most commonly reported late complications, as observed by others.[3,4,8,9] Accidental decannulation occurs more frequently than the 6% represented in the current series. Many episodes of accidental decannulation remain unreported unless significant morbidity occurs.

The tracheostomy-related mortality in the current series, at 0.5%, was one quarter of that seen in the 1971-80 series. This mortality compares favorably to tracheostomy-related mortalities seen in other series, which range from 0.9% to 5%.[2-6,8,9] The decrease in tracheostomy-related mortality may be due in large part to the introduction of practical pulse

oximetry monitors; the first Nellcor model was cleared for marketing by the US Food and Drug Administration in late 1982 and rapidly gained acceptance at this institution. Parent education has also gained more attention over the years, and may have contributed further to the decline in tracheostomy-related mortality. The non–tracheostomy-related mortality of 22% in this series compares to 26% in the previous series and a range of 14% to 33% in the literature.[1-6,8,9]

CONCLUSIONS

Pediatric tracheostomy has shown a slight decrease as a percentage of hospital admissions over the past 20 years. The survival of a greater number of critically ill infants who require chronic ventilation has placed a greater demand upon the procedure of tracheostomy to provide access to the airway. As a result, pediatric tracheostomy was performed more often in younger children, especially infants, during the past decade than in the previous one. Early and late complications remain unchanged, although there have been shifts in their incidence. Better monitoring and improvements in parental teaching may have contributed to the decrease in tracheostomy-related mortality.

REFERENCES

1. Wetmore RF, Handler SD, Potsic WP. Pediatric tracheostomy. Experience during the past decade. Ann Otol Rhinol Laryngol 1982;91:628-32.

2. Zeitouni A, Manoukian J. Tracheotomy in the first year of life. J Otolaryngol 1993;22:431-4.

3. Arcand P, Granger J. Pediatric tracheostomies: changing trends. J Otolaryngol 1988;17:121-4.

4. Crysdale WS, Feldman RI, Naito K. Tracheotomies: a 10-year experience in 319 children. Ann Otol Rhinol Laryngol 1988;97:439-43.

5. Line WS, Hawkins DB, Kahlstrom EJ, MacLaughlin EF, Ensley JL. Tracheotomy in infants and young children: the changing perspective 1970-1985. Laryngoscope 1986;96:510-5.

6. Palmer PM, Dutton JM, McCulloch TM, Smith RJH. Trends in the use of tracheotomy in the pediatric patient: the Iowa experience. Head Neck 1995;17:328-33.

7. Swift AC, Rogers JH. The changing indications for tracheostomy in children. J Laryngol Otol 1987;101:1258-62.

8. Waki EY, Madgy DN, Zablocki H, Belenky WM, Hotaling AJ. An analysis of the inferior based tracheal flap for pediatric tracheotomy. Int J Pediatr Otorhinolaryngol 1993;27:47-54.

9. Ward RF, Jones J, Carew JF. Current trends in pediatric tracheotomy. Int J Pediatr Otorhinolaryngol 1995;32:233-9.

Ann Otol Rhinol Laryngol 108:1999

FLUORESCENCE-GUIDED BIOPSY IN THE DIAGNOSIS OF AN UNKNOWN PRIMARY CANCER IN PATIENTS WITH METASTATIC CERVICAL LYMPH NODES

BOONCHU KULAPADITHAROM, MD

VIPA BOONKITTICHAROEN, PHD SOMYOS KUNACHAK, MD

BANGKOK, THAILAND

This study was conducted to determine the effectiveness of fluorescence-guided biopsy in diagnosis of unknown primary cancers in the head and neck. Thirteen patients with biopsy-proven cervical node metastases were evaluated prospectively with laser-induced fluorescence (LIF) endoscopy in parallel to panendoscopy. Among the 13 positive sites suggested by LIF imaging, 5 were confirmed by histopathology as squamous cell carcinoma, 4 as dysplasia, 2 as inflammation, and 2 as normal. Panendoscopy with random biopsies located 2. The 2 cases of squamous cell carcinomas discovered conventionally were identified by histologic sections from ipsilateral tonsillectomy. In this series, the unknown primary cancers were localized by LIF imaging and conventional means at rates of 38.5% and 15.4%, respectively. The LIF imaging not only aided in revealing a greater proportion of occult primary cancers, but also helped in reducing the number of unnecessary biopsies. Fluorescence-guided biopsy diagnosis provides useful information for therapeutic planning with curative aim or for adequate palliation.

KEY WORDS — fluorescence-guided biopsy, head and neck, laser-induced fluorescence imaging, unknown primary cancer.

INTRODUCTION

Detection of an unknown primary cancer has long been regarded as a difficult diagnostic problem. In the head and neck, approximately 5%[1] to 20%[2] of patients with metastatic neck nodes show no evidence of the primary cancer despite meticulous diagnostic workups of the upper aerodigestive tracts. Furthermore, a conventional panendoscopy with multiple biopsies of the presumed sites of occult primary cancers, ie, nasopharynx, tonsil, base of tongue, and pyriform sinus, can only achieve a 10% detection rate.[2-4] In patients who undergo radical neck dissection alone, the primary cancer will surface months or years later in 20% to 40% of cases.[4] An additional 30% of the primary sites can be located at autopsy.[2]

Endoscopic localization of suspicious areas is based on the evidence of irregularity or granularity of the mucosal lining. Therefore, the sensitivity of endoscopic detection is limited by the capability of the human eye to visualize gross structural changes. A great majority of the primary malignancies that escape detection may still be confined, in their early stages of growth, to changes that involve molecular rather than structural alterations. Obviously, only devices or tests that are capable of sensing molecular signals or describing biochemical events can overcome this diagnostic barrier to disease discovery. Spectroscopy of in vivo tissue fluorescence is an example. Fluorescence endoscopic imaging using a helium-cadmium (He-Cd) laser has been demonstrated in the lung[5] and in the head and neck[6,7] to be particularly effective in discovering early cancers that are invisible by white light endoscopy. In the head and neck, the sensitivity and specificity of this imaging modality are estimated to be 92.9% and 78.6%, respectively.[7] To our knowledge, no study has been conducted using laser-induced fluorescence (LIF) imaging to evaluate patients with unknown primary cancers in the head and neck. This study aimed to determine how effective LIF imaging is in guiding the surgeon to the site of occult primary cancer.

MATERIALS AND METHODS

Patients. Over a period of 2 years (July 1995 to June 1997), 18 patients who had upper or midcervical masses proven to be metastases from squamous cell or undifferentiated carcinoma underwent extensive searches for locations of the primary cancers. All the efforts, ie, thorough history review, complete head and neck examinations, and extensive radiologic investigations, failed to demonstrate the occult primaries. The patients were then referred to LIF imaging prior to undergoing panendoscopy as a conventional workup process. However, 5 patients were excluded for lymphoma, poor general condition or cooperation, intolerance to local anesthesia, and incomplete

From the Department of Otolaryngology, Faculty of Medicine, Ramathibodi Hospital, Mahidol University, Bangkok, Thailand.

CORRESPONDENCE — Boonchu Kulapaditharom, MD, Dept of Otolaryngology, Faculty of Medicine, Ramathibodi Hospital, Mahidol University, Rama VI Road, Bangkok 10400, Thailand.

TABLE 1. CHARACTERIZATION AND GRADING OF FLUORESCENCE IMAGE

Fluorescence Grade	*Fluorescence Image*	*Likelihood Ratio** *Previous Study*[7]	*Likelihood Ratio** *Present Study*
IIIb	Single or multiple focal dark areas + clustered brown or rust-red dots	14.04	5.18
IIIa	Single or multiple focal dark areas	4.07	10.37
IIb	Diffuse dark area + clustered brown or rust-red dots	1.00	0.00
IIa	Diffuse dark area	0.36	0.77
Ib	Green area + scattered bright red dots	0	0
Ia	Green area	0	0

*Index describing how many times more likely it is for specified fluorescence grade to be found in malignant condition as compared to nonmalignant.

investigation. The patients of both sexes, between 35 and 81 years old, gave informed consent to enroll in an institutionally approved program on tumor detection by LIF imaging.

Imaging Device. The imaging system (Xillix Technologies Corp, Vancouver, Canada) is equipped with a fiberoptic endoscope (Olympus BF 20D) that can either be connected to an external xenon light source for white light investigation or attached to an He-Cd laser (442 nm) for fluorescence endoscopy. The system is assembled with 2 cameras, ie, RGB and LIFE cameras. One serves in capture of refracted white light, and the other detects LIF signals. During the examination, the collected light signals were processed onto the imaging board of the system computer for image reconstruction. True color image generated by white light and pseudocolor image reconstructed from fluorescent light were projected on a video monitor in real time. Images from sites of interest were stored in the system hard drive and recalled for subsequent analysis.

Fluorescence Imaging and Biopsy. Under local anesthesia, the patient was first examined with a fiberoptic endoscope with xenon white light to visualize the upper aerodigestive tracts including the nasopharynx, opening of the eustachian tubes, tonsils, base of tongue, pyriform sinuses, and larynx. This was meant to document the patient's anatomy and to observe primarily for any structural abnormality. The investigation was then repeated with an He-Cd laser to search for an abnormal fluorescence pattern. At least 18 images, both white light and fluorescent light, were collected from each patient. The fluorescence images were graded into 6 levels according to the criteria defined in Table 1.[7] Biopsies were directed to all sites that displayed grade IIb, IIIa, or IIIb fluorescence. For areas with normal or unremarkable fluorescence, ie, grade Ia, Ib, or IIa, biopsies were performed by random sampling. A likelihood ratio was calculated for each fluorescence grade based on the histopathologic diagnosis.[8]

TABLE 2. DISTRIBUTION OF FLUORESCENCE IMAGES AMONG SIX DIFFERENT GRADES

Site	*Fluorescence Grade* *Ia*	*Ib*	*IIa*	*IIb*	*IIIa*	*IIIb*
Nasopharynx	5	2	5	0	0	1
Eustachian tube						
Right	10	0	1	0	2	0
Left	12	0	1	0	0	0
Tonsil						
Right	10	0	2	0	1	0
Left	11	0	0	0	1	1
Base of tongue	6	0	3	0	3	1
Pyriform sinus						
Right	9	0	3	0	0	1
Left	12	0	0	0	0	1
Larynx	12	0	0	0	1	0

Data were collected from 13 patients (total 117 images).

A few days later, the patient was sent for panendoscopy. The medical staff in charge of this procedure did not belong to the same group conducting the fluorescence study and had no knowledge of any fluorescence findings. Biopsy was directed to areas of abnormal mucosa. In case of no visible abnormality, bilateral biopsies were conducted at random in the nasopharynx, tonsil, base of tongue, and pyriform sinus, and last, tonsillectomy was performed on the side of a positive node.

RESULTS

Fluorescence Imaging. A total of 117 fluorescence images were collected from 13 patients with cervical node metastatic squamous cell or undifferentiated carcinoma without apparent primary cancers. The images were rated according to the criteria described in Table 1. Distribution of images among different fluorescence grades is documented in Table 2. Seventy-four percent of images appeared normal, with grade Ia fluorescence. Biopsy was not recommended for this grade of fluorescence images because of their unlikelihood to be associated with the neoplastic state[7] (Table 1). However, in this study, random biopsies were performed just to test whether the above proposition was true. In contrast, biopsies were advised whenever areas with high-grade fluorescence (grades IIb to IIIb) were located. The recommendation was justified, since these abnormal fluorescence patterns displayed a high likelihood ratio for disease occurrence (Table 1). Noteworthily, there were 13 out of 117 sites that were suspected

TABLE 3. PERFORMANCE OF FLUORESCENCE-GUIDED BIOPSY IN DETECTING UNKNOWN PRIMARY CANCERS

	Detection Rate (%)	
Diagnosis	*Guided Biopsy**	*Random Biopsy†*
Carcinoma	38.5 (5/13)	0 (0/38)
Dysplasia	30.8 (4/13)	5.3 (2/38)
Nonmalignancy	30.8 (4/13)	94.7 (36/38)

*Directed by high-grade fluorescence (IIb to IIIb); total guided biopsy sites = 13.

†Conducted at random on areas with low-grade fluorescence (Ia to IIa); total random biopsies = 38.

for malignancy (Table 2).

Detection of Occult Primary Cancer. The LIF imaging directed the surgeon to 5 sites of neoplasia and 4 sites of dysplasia (Table 3), but failed to locate the occult cancers in 8 cases. Misguided biopsy of normal and inflamed tissues occurred occasionally, at a rate of 30.8% (ie, 4/13). This was not considered a serious problem, since, with the aid of LIF imaging, the total of 117 random biopsies that were planned was reduced to 13. Unnecessary biopsies were reduced from 112 to 4. However, random biopsies were conducted to see whether more of the neoplastic lesions could be uncovered from areas of normal fluorescence. It happened that only 2 more dysplastic foci were discovered, while the rest of the biopsy specimens were reported as normal or showing inflammation (Table 3). Patient characteristics and findings from various investigations are summarized in Table 4. In this series, a computed tomography (CT) scan of the nasopharynx and neck disclosed no hidden malignancies, despite some false-positive findings. On the other hand, LIF imaging aided the detection of the unknown primary cancers at a rate of 38.5%, while panendoscopy with multiple biopsies detected only 15.4% of the cases. As a matter of fact, none of the white light examinations performed prior to fluorescence investigation revealed any suspicious sites to direct the biopsy. Under panendoscopy, 2 cases of primary squamous cell carcinoma were discovered by blind ipsilateral tonsillectomy rather

TABLE 4. PATIENT CHARACTERISTICS AND FINDINGS FROM DIFFERENT MEDICAL EXAMINATIONS

Patient	*Age*	*Sex*	*Cervical Node Metastasis (Histology and Location)*	*Computed Tomography Scan*	*Panendoscopy With Biopsy*	*Fluorescence Imaging*	*Guided Biopsy Finding*
1	35	F	SCC, L node	Negative	PD SCC (L tonsil)	Positive (L tonsil)	SCC
2	54	M	SCC, R node	Negative	Negative	Negative	None
3	75	F	PD SCC, R node	Not available	Negative	Positive (R pyriform sinus)	SCC (small cell type)
4	67	M	SCC, R node	Positive (granuloma at R nasopharynx)	Negative	Negative	None
5	48	M	MD SCC, L node	Negative	Negative	Positive (larynx)	Normal
6	56	F	UDC, L node	Negative	Negative	Positive (tongue base)	Normal
7	40	F	PD SCC, R node	Not available	Negative	Negative	None
8	60	F	SCC, R node	Not available	Negative	Positive 1. R tonsil 2. Tongue base	 1. Mild dysplasia 2. Moderate dysplasia
9	38	M	UDC, R node	Negative	Negative	Positive (R eustachian tube)	SCC
10	69	M	MD SCC, R node	Not available	Negative	Positive 1. Tongue base 2. L pyriform sinus	 1. Moderate dysplasia 2. Moderate dysplasia
11	81	M	PD SCC, R node	Negative	Negative	Negative	None
12	55	M	SCC, L node	Not available	PD SCC (L tonsil)	Positive 1. L tonsil 2. Tongue base	 1. SCC 2. Bacterial infection
13	36	M	PD SCC, R node	Positive (inflammation at R tongue base)	Negative	Positive 1. Nasopharynx 2. R eustachian tube	 1. Chronic inflammation 2. SCC

SCC — squamous cell carcinoma, PD — poorly differentiated, MD — moderately differentiated, UDC — undifferentiated carcinoma.

than by visual observation and punch biopsy. It was likely that the hidden primary cancers were still confined to their early states of growth and that no structural displacement or distortion was apparent for visual inspection or radiographic examination.

DISCUSSION

Although cancer of unknown origin in the head and neck is not a common mode of clinical presentation,[1,2] its occurrence poses difficult problems in both diagnosis and treatment. The patient is subjected to extensive and lengthy investigations that often fail to unveil the occult primary cancer.[2] Without knowledge of the location of cancer, the treatment usually consists of neck dissection and/or radiotherapy of the neck including the nasopharynx, tonsils, base of tongue, and pyriform sinuses.[2,3] After neck dissection alone, the primary cancer show up later in 20% to 40% of the patients.[4] Primary tumors erupt less commonly in irradiation-treated patients,[4] but normal tissue complications are considerable.[3] The most common complaint from patients is permanent xerostomia.[3] Definitely, discovery of the inapparent cancer will allow the treatment to be focused on the diseased area while sparing the normal structures.

As an alternative to panendoscopy, several radiologic imaging modalities have been attempted to further disclose hidden malignancies. Muraki et al[9] used CT scan to identify sites of occult cancers in 4 of 17 patients (23.5%). All the sites disclosed were tumors that deeply invaded structures in the nasopharynx (3 sites) and tonsil (1 site). Rege et al[10] detected sites in 2 of 4 patients (50%) by positron emission tomography (PET) using [^{18}F]-fluoro-2-deoxy-D-glucose (FDG) as a tumor marker. Despite its clinical potential, PET-FDG imaging may not be viable in terms of widespread usage, since the technology is extremely expensive. It requires not only sophisticated imaging devices but also the complicated cyclotron-based production of radiopharmaceutical for on-site use. Nevertheless, the key element that contributes to the high sensitivity of PET-FDG imaging is the exploitation of changes in the biochemistry of cancerous tissue, ie, an increase in glycolysis, as the basis of detection.[10]

In this study, we used a simple fluorescence endoscopic system. The technique of endoscopic investigation was similar to the conventional procedure that is familiar to all otolaryngologists. However, the principle of tumor detection is somewhat different. It is based on differences in tissue autofluorescence properties between normal and cancerous tissues.[11] The system has been shown to be highly sensitive in localizing cancers in the head and neck.[6,7] In searching for unknown primary cancers, we were able to locate the hidden primary sites in 5 of the 13 patients. All the lesions uncovered were squamous cell carcinomas in the tonsil, the opening of the eustachian tube, or the pyriform sinus. Noteworthily, all sites suggested by LIF imaging appeared normal under white light. In our hands, fluorescence-guided biopsy was 2.5 times more sensitive than random biopsy in diagnosis of the unknown primary cancer. Besides, the clear-cut differences between the high-grade and low-grade fluorescence images were of great merit in directing the surgeon to conduct biopsy only at the highly suspicious areas. Although misguided biopsy occurred at the rate of 30.8% (4/13), this was still considered acceptable when compared to the rate of unnecessary biopsy, ie, 95.2% (99/104), encountered in panendoscopy.

In this study, in 8 of the 13 patients, the primary cancers were undiscovered even by LIF imaging. It is likely that some tumors, such as those involving the nasopharynx, tongue base, or lingual and pharyngeal tonsils,[12] might grow beneath intact mucosa, where the blue laser could not penetrate to reach the diseased tissue.[13] Although these submucosal tumors occur rarely,[12] their existence does create difficulties in diagnosis. A CT scan was demonstrated to be effective for this clinical circumstance.[9,12] In our series, the negative CT findings might be interpreted as a system limitation in detecting those hidden lesions existing on a micrometer scale. Another possibility that might be invoked to account for part of the negative findings was a spontaneous regression of the primary cancers that represented a natural host defense mechanism.[14]

CONCLUSION

Laser-induced fluorescence imaging was an effective tool in discovering neoplastic lesions unknown to most conventional investigations. The system displayed a unique fluorescence characteristic correlating to the malignant change and thus made the task of tissue biopsy simple and reliable. Biopsies under the aid of LIF imaging would be more effective than those performed routinely and would contribute more clinically important information to the management of a patient with an unknown primary cancer in the head and neck.

REFERENCES

1. Richard JM, Micheu C. Malignant cervical adenopathies from carcinomas of unknown origin. Tumori 1973;63:249-58.

2. Jacobs C. The internist in the management of head and neck cancer. Ann Intern Med 1990;113:771-8.

3. Jacobs CD, Goffinet DR, Fee WE. Head and neck squamous cancers. Curr Probl Cancer 1992;14:1-72.

4. Greco FA, Hainsworth JD. Cancer of unknown primary site. In: DeVita VT, Hellman S, Rosenberg SA, eds. Cancer. Principles and practice of oncology. 5th ed. New York, NY: Lippincott-Raven, 1997:2423-43.

5. Lam S, MacAulay C, Hung J, LeRiche J, Profio AE, Palcic B. Detection of dysplasia and carcinoma in situ with a lung imaging endoscope device. J Thorac Cardiovasc Surg 1993;105: 1035-40.

6. Kulapaditharom B, Boonkitticharoen V. Laser-induced fluorescence imaging in localization of head and neck cancers. Ann Otol Rhinol Laryngol 1998;107:241-6.

7. Kulapaditharom B, Boonkitticharoen V. Performance characteristics of fluorescence endoscope in detection of head and neck cancers. Ann Otol Rhinol Laryngol (submitted for publication).

8. Sackett DL, Haynes RB, Guyatt GH, Tugwell P. Clinical epidemiology: a basic science for clinical medicine. 2nd ed. Boston, Mass: Little, Brown, 1991.

9. Muraki AS, Mancuso AA, Harnsberger HR. Metastatic cervical adenopathy from tumors of unknown origin: the role of CT. Radiology 1984;152:749-53.

10. Rege S, Maass A, Chaiken L, et al. Use of positron emission tomography with fluorodeoxyglucose in patients with extracranial head and neck cancers. Cancer 1994;73:3047-58.

11. Hung J, Lam S, LeRiche JC, Palcic B. Autofluorescence of normal and malignant bronchial tissue. Lasers Surg Med 1991;11:99-105.

12. Mancuso AA, Hanafee WN. Elusive head and neck carcinomas beneath intact mucosa. Laryngoscope 1983;93:133-9.

13. Jacques SL. Tissue fluorescence. In: Cortese DA, ed. 5th International Photodynamic Association Biennial Meeting. SPIE 1995;2371:2-13.

14. MacComb WS. Diagnosis and treatment of metastatic cervical cancerous nodes from an unknown primary site. Am J Surg 1972;124:441-9.

CAUTERY-ASSISTED PALATAL STIFFENING OPERATION AND NASALANCE OF SPEECH

CPT EVANNE M. HOOLSEMA, BSC, USAF

PALATINE, ILLINOIS

Velopharyngeal competence as indicated by nasalance of speech was tested in 18 men before and after a cautery-assisted palatal stiffening operation for snoring. Nasalance was measured preoperatively and postoperatively, with no significant changes noted following surgery. Although there were no objective or subjective changes in nasality of voice, these findings do not rule out all possible changes in velopharyngeal competence, since there were subjective complaints of nasal regurgitation and dysphagia.

KEY WORDS — palatal stiffening surgery, snoring, speech quality, velopharyngeal competence.

A number of surgical treatments for snoring have emerged within recent years. The most common, uvulopalatopharyngoplasty (UPPP), is performed under general anesthesia, requiring hospital admission. It prevents snoring by displacing the soft palate anteriorly to prevent occlusion of the airway, but carries a risk of morbidity and mortality.[1] Laser-assisted uvulopalatoplasty (LAUP), first introduced by Kamami in 1990,[2] is an office procedure requiring local anesthesia. A carbon dioxide (CO_2) laser is used in successive stages to reduce and reshape the uvula and soft palate. An outpatient cautery-assisted uvulopalatoplasty was introduced by Zinder and Postma,[3] in which a standard electrocautery device was used instead of a CO_2 laser. The surgery required up to 4 stages to achieve a significant reduction in snoring. Blythe et al[4] reported on a single-stage procedure using an electrocautery device to remove the uvula and a portion of the soft palate.

Finkelstein et al[5] studied results of UPPP based on 4 differing velopharyngeal valving mechanisms, which they say are due to variable anatomy. They observed nasal regurgitation, inability to withhold sneezing, and negligible speech changes, mainly in the group utilizing a coronal valving pattern (see Croft et al[6] for further description of the various velopharyngeal valving patterns). The groups utilizing valving patterns other than coronal compensated better for the limitation of movement caused by the operation. The authors suggest that the relatively greater number of changes in nonspeech versus speech activities indicates different lateral pharyngeal wall movement for these 2 types of activities.

In a later study, Finkelstein et al[7] compared anatomic changes following UPPP versus LAUP. They found very different anatomic configurations after surgery due to the difference in methods, and also each subject's individual velopharyngeal valve closure pattern. They found greater average enlargement of the oropharynx with the UPPP, while the scarring process of the LAUP caused a decrease in the enlargement. In addition, LAUP's outcome was subject to greater influence by patients' individual anatomic variations than was UPPP. The authors suggest that LAUP may cure snoring but induce or aggravate dangerous obstructive sleep apnea (OSA) by increased airway resistance following scarring, while UPPP does not aggravate OSA. Stressing the goal of reducing sleep disturbances in general, not just snoring, they conclude that UPPP is the treatment of choice.

More recent procedures have focused on palatal stiffening as opposed to palatal displacement to prevent airway occlusion and cure snoring. Ellis et al[8] introduced a palatal stiffening procedure in which a contact laser was used to remove a central longitudinal strip of mucosa from the oral surface of the soft palate. The advantages of a stiffening procedure over palatal displacement are reduced risks of palatal incompetence and fatality. Whinney et al[9] used punctate diathermy of the soft palate to achieve stiffening. Morar et al[10] used a CO_2 laser to perform mucosal-strip/uvulectomy to induce scarring and subsequent stiffening. More recently, Mair reported on the cautery-assisted palatal stiffening operation (CAPSO), in which 1.5 to 2 cm of midline soft palate mucosa is removed, along with excision of the uvula (unpublished observations). This outpatient procedure is done under local anesthesia, and reports a well over 90% success rate. Advantages of the CAPSO procedure are listed as significantly less morbidity, less expense, minimal need for anesthesia, no need for multiple staging, and technical ease

From the 48th Medical Group/Otolaryngology, Royal Air Force Lakenheath, England.

CORRESPONDENCE — Evanne M. Hoolsema, 1965 N Hicks Rd, Palatine, IL 60074.

of performance.

Because snoring surgery may reduce velopharyngeal competence through changes in velar musculature, there is concern over the effects of the surgery on speech quality and swallowing. Velopharyngeal incompetence can cause nasal regurgitation of food or liquid, and can negatively affect voice quality by altering resonance characteristics. Coleman and Sly[11] measured preoperative and postoperative voice characteristics of patients undergoing UPPP. They found no significant changes in fundamental frequency, reading rate, formants 1 and 2 for vowels, long-term average spectra, or listener judgments of preoperative and postoperative pairs. Though nasality was not formally measured, the unchanged listener judgments may indicate that there was no perceptible change in nasality. Zohar et al[12] evaluated postoperative complications of UPPP, and found that no patients had noticeable hypernasality 6 weeks after the operation. In the report of Blythe et al[4] on single-stage outpatient uvuloplasty, no patients reported symptoms associated with persistent velopharyngeal insufficiency. In the study by Prichard et al[13] of 29 patients undergoing UPPP for snoring, 35% of patients complained of mild hyponasal speech at the 6-month follow-up. Walker et al[14] listed temporary velopalatal insufficiency as a postoperative complication in patients receiving LAUP for snoring and obstructive sleep apnea. Whinney et al[9] reported no episodes of nasal regurgitation in 27 patients receiving punctate diathermy of the soft palate. Zinder and Postma[3] reported no patients with symptoms of velopharyngeal incompetence following their outpatient cautery-assisted uvulopalatoplasty. Finally, Ellis et al[8] reported no nasal regurgitation or change in sound of the voice after a palatal stiffening procedure. There are no known studies objectively measuring percentage of "nasalance" both preoperatively and postoperatively for patients undergoing snoring surgery. (Nasalance, a term first introduced by Fletcher,[15] refers to the ratio between nasal and oral acoustic energies.) This study performed objective measurements of nasalance before and after the CAPSO procedure.

METHOD

Eighteen men ranging in age from 22 to 49 years, with an average age of 33.1 years, received the CAPSO procedure for complaints of excessive snoring. Patients' speech nasalance was assessed 0 to 42 days preoperatively (average 4.7 days, median 2 days) and 60 to 276 days postoperatively (average 94.5 days, median 79 days). Mucosal healing with palatal stiffening usually takes place within 2 months; therefore, postoperative testing was done at least 2 months after surgery. Nasalance measurements were obtained with the Nasometer 6200 by Kay Elemetrics, which was calibrated according to manufacturer instructions. Although the validity of measurements of nasalance by the Nasometer has been demonstrated in the past,[16] recent questions have been raised as to variations in nasalance scores due to mismatch in microphone sensitivity,[17] suggesting caution in the use of nasalance scores involving small variations. All Nasometer testing was performed by 1 certified speech-language pathologist. Nasalance was assessed while patients read aloud 2 passages, both before and after surgery. The first passage contained 71 words and no nasal consonants (Zoo passage), and the second contained 98 words and 11.5% nasal consonants (Rainbow passage). The time axis was set at 40 seconds. Subjective comments regarding changes in nasality were obtained verbally through the following questions: "Have you experienced any changes in the sound of your speech, or in your swallowing?" "Has anyone else commented on any differences in the sound of your speech?" "Have you experienced any other changes since the surgery?"

RESULTS

A paired 2-sample *t*-test for means was used at an α level of 0.05% to test for significant differences between preoperative and postoperative nasality measurements for each passage. The average nasalance score for the Zoo passage was 11.66% preoperatively and 11.33% postoperatively. The average nasalance score for the Rainbow passage was 31.14% preoperatively and 31.47% postoperatively. No significant differences were found between preoperative and postoperative readings of either passage. There were no subjective complaints of increased nasality or other negative voice changes. Unrelated postoperative comments included the following: can't roll r's anymore (1 patient); better singing voice (1); nasal regurgitation of liquids (5); increased gag reflex (2); aspiration (2, probably due to discoordinated swallow); food tastes different (1); and still snoring (2).

DISCUSSION

The results indicate that the CAPSO does not cause a significant change in nasality, despite affecting palatal movement via stiffening. These objective results confirm anecdotal reports in previously cited studies reporting negligible or no speech and voice changes following snoring surgery. This would be important for patients with concerns about postoperative vocal quality, such as singers or professional speakers. It would have been helpful to more thoroughly assess perceptual changes in nasality through question-

naires filled out by the patient and someone familiar with the patient. Even though it appears that nasality was not significantly affected by the CAPSO operation, there still may be some question as to its effect on other aspects of velopharyngeal competence, as indicated by subjective complaints of nasal regurgitation and dysphagia. As suggested earlier by Finkelstein et al,[5] compensatory velopharyngeal valving mechanisms may be adequate to overcome changes affecting speech but not nonspeech activities. This may be due to the greater pressure required from the lateral pharyngeal wall, which the altered velopharyngeal valve has difficulty resisting, during nonspeech activities such as swallowing. The number of nonspeech subjective complaints elicited in this study warrants research to assess the long-term effects of CAPSO and similar operations versus UPPP on all aspects of velopharyngeal competence, especially OSA and swallowing symptoms of nasal regurgitation and aspiration.

REFERENCES

1. Katsantonis GP. Limitations, pitfalls, and risk management in uvulopalatopharyngoplasty. In: Fairbanks DNF, Fujita S, eds. Snoring and sleep apnea. New York, NY: Raven Press, 1994:147-62.

2. Kamami YV. Outpatient treatment of snoring with CO2 laser: laser-assisted UPPP. J Otolaryngol 1994;23:391-4.

3. Zinder DJ, Postma GN. Outpatient cautery-assisted uvulopalatoplasty. Laryngoscope 1995;105:1256-7.

4. Blythe WR, Henrich DE, Pillsbury HC. Outpatient uvuloplasty: an inexpensive, single-staged procedure for the relief of symptomatic snoring. Otolaryngol Head Neck Surg 1995; 113:1-4.

5. Finkelstein Y, Talmi Y, Zohar Y. Readaptation of the velopharyngeal valve following the uvulopalatopharyngoplasty operation. Plast Reconstr Surg 1988;82:20-7.

6. Croft CB, Shprintzen RJ, Rakoff SJ. Patterns of velopharyngeal valving in normal and cleft palate subjects: a multiview videofluoroscopic and nasendoscopic study. Laryngoscope 1981;91:265-71.

7. Finkelstein Y, Shapiro-Feinberg M, Stein G, Ophir D. Uvulopalatopharyngoplasty vs laser-assisted uvulopalatoplasty. Arch Otolaryngol Head Neck Surg 1997;123:265-76.

8. Ellis PDM, Williams JE, Shneerson JM. Surgical relief of snoring due to palatal flutter: a preliminary report. Ann R Coll Surg Engl 1993;75:286-90.

9. Whinney DJ, Williamson PG, Bicknell PG. Punctate diathermy of the soft palate: a new approach in the surgical management of snoring. J Laryngol Otol 1995;109:849-52.

10. Morar P, Nandapalan V, Lesser THJ, Swift AC. Mucosal-strip/uvulectomy by the CO2 laser as a method of treating simple snoring. Clin Otolaryngol 1995;20:308-11.

11. Coleman RF, Sly DE. Preoperative and postoperative voice analysis of uvulopalatopharyngoplasty patients. Arch Otolaryngol Head Neck Surg 1991;117:1345-9.

12. Zohar Y, Finkelstein Y, Talmi YP, Bar-Ilan Y. Uvulopalatopharyngoplasty: evaluation of postoperative complications, sequelae, and results. Laryngoscope 1991;101:775-9.

13. Prichard AJN, Marshall J, Ahmed A, Thomas RSA, Hanning CD. Uvulopalatopharyngoplasty: the Leicester experience. J Laryngol Otol 1994;108:649-52.

14. Walker RP, Grigg-Damberger MM, Gopalsami C, Totten MC. Laser-assisted uvulopalatoplasty for snoring and obstructive sleep apnea: results in 170 patients. Laryngoscope 1995;105:938-43.

15. Fletcher SG. "Nasalance" vs. listener judgment of nasality. Cleft Palate J 1976;13:31-44.

16. Dalston RM, Warren DW, Dalston ET. Use of nasometry as a diagnostic tool for identifying patients with velopharyngeal impairment. Cleft Palate Craniofac J 1991;28:184-9.

17. Zajac DJ, Lutz R, Mayo R. Microphone sensitivity as a source of variation in nasalance scores. J Speech Hear Res 1996; 39:1228-31.

Ann Otol Rhinol Laryngol 108:1999

COMPUTED TOMOGRAPHY DIAGNOSIS OF ESOPHAGEAL BONE IMPACTION: A PROSPECTIVE STUDY

RON ELIASHAR, MD
ITZHAK DANO, MD
ITZHAK BRAVERMAN, MD
ERIC DANGOOR, MB, MRCGP
JEAN-YVES SICHEL, MD
JERUSALEM, ISRAEL

A prospective study was performed on 45 patients for an assessment of the use of computed tomography (CT) in the management of a suspected esophageal fish bone or chicken bone. All patients had negative findings on laryngoscopy; therefore, pharyngeal and hypopharyngeal foreign bodies were excluded from further consideration. The patients underwent radiographic examination with plain films and a cervical CT scan without contrast material. Patients with positive findings were taken to the operating room, where they underwent rigid esophagoscopy under general anesthesia, while those with negative findings remained for observation for 24 hours. Thirty CT scans were positive for an esophageal foreign body, and in all cases but 1, a foreign body was found during the operation. Fourteen of 15 patients with normal CT scan findings managed well with no further intervention. One patient with persistent complaints underwent esophagoscopy, but no foreign body was found. Our conclusion is therefore that CT is a simple and reliable method for diagnosing esophageal bone impaction and may reduce the rate of unnecessary esophagoscopies.

KEY WORDS — bone impaction, computed tomography, esophagoscopy, foreign body.

INTRODUCTION

Foreign bodies impacted in the esophagus can be life-threatening if detection and removal are not performed in time, the most dreaded complication being esophageal perforation with resultant fatal mediastinitis. The risk of perforation is higher when sharp foreign bodies are ingested,[1] and therefore rapid and accurate diagnosis and treatment should be done. Traditional management involves a physical examination and a radiologic assessment that includes posteroanterior and lateral x-ray films of the neck and chest and, if necessary, a barium swallow study. An esophagoscopy is performed in certain suspected cases.[2,3] However, in dealing with a fish bone, which is the most commonly ingested sharp object,[4] or even a chicken bone, plain films may not be helpful.[4-7] A barium swallow study involves a large percentage of false-negative examinations and exposes the patient to some risk of aspiration.[1,7] Esophagoscopy, which is usually performed in the operating room under general anesthesia with a rigid esophagoscope,[2,8] is associated with a perforation rate of 0.15% to 0.5%.[9] It is also negative (ie, no foreign body is found) in 7% to 62% of cases.[7] Thus, current approaches to the management of fish bone or chicken bone ingestion have proved to be unsatisfactory.

A prospective nonrandomized study was conducted in order to assess the value of a computed tomography (CT) scan in the management of symptomatic patients with a history of fish bone or chicken bone ingestion, and to suggest a safe and cost-effective approach to the problem.

MATERIALS AND METHODS

During a period of 4 years (1993 to 1997), 45 patients with a history of fish bone or chicken bone ingestion underwent a CT scan of the neck. Symptoms included a sensation of a foreign body, dysphagia, odynophagia, and drooling. All patients underwent a thorough oral examination followed by indirect laryngoscopy and, in some cases, a fiberoptic laryngoscopy as well. In all cases, a pharyngeal foreign body was ruled out. Radiologic evaluation included plain films of the neck and chest and an axial 2.5-mm-wide CT scan without contrast material of the neck and the mediastinum with both soft tissue and bone windows. Patients with a positive finding on either of these examinations were taken to the operating room, where they underwent rigid esophagoscopy under general anesthesia. Patients with normal findings were observed for 24 hours and were seen again a week later at the clinic. All the patients were examined and treated by the otolaryngologist on call, and the plain films and CT scans were interpreted by him or her and by a radiologist on call (both of them residents). Plain films were interpreted as being pathological when 1 or more of the following situations occurred: 1) a foreign body was detected; 2) associated soft tissue swelling was observed; 3) abnormal gas accumulation was observed;

From the Department of Otolaryngology–Head and Neck Surgery, Hadassah University Hospital, Jerusalem, Israel.
CORRESPONDENCE — Ron Eliashar, MD, Dept of Otolaryngology–Head and Neck Surgery, Hadassah University Hospital, Jerusalem, Israel.

TABLE 1. RESULTS OF PLAIN FILMS AND CT SCANS

	Normal Plain Film	*Pathological Plain Film*	*Total*
Normal CT scan	15	0	15
Pathological CT scan	14	16	30
Total	29	16	45

CT — computed tomography.

or 4) a loss of cervical lordosis was noted. The CT scans were interpreted as being pathological if a foreign body was detected in the esophageal lumen or wall.

RESULTS

The results are summarized in Tables 1 and 2. Of 45 patients complaining of fish bone or chicken bone ingestion with no other findings on physical examination, 23 were men and 22 were women, with a mean age of 55 (range 31 to 87). Thirty-two patients (71%) complained of fish bone ingestion, and 13 patients (29%) complained of chicken bone ingestion. Twenty-nine of 45 plain films were interpreted as being normal, and 16 were pathological. Fifteen of 45 CT scans were normal, whereas on 30, a foreign body was noted.

Fifteen patients had both a normal plain film and a normal CT scan, and all of them were kept for 24 hours' observation. Only 1 patient continued to have persistent symptoms after the 24 hours. He underwent rigid esophagoscopy, but no foreign body was found. All patients were submitted to a follow-up examination in the outpatient clinic a week later and all were asymptomatic. Fourteen patients had a normal plain film but a pathological CT scan, and 16 had both a pathological plain film and a pathological CT scan. All 30 patients with pathological findings underwent immediate rigid esophagoscopy under general anesthesia, and in all cases but 1, a foreign body was found and removed. Except for 2 mucosal tears, no other complications occurred. No cases of a pathological plain film with a normal CT scan were noted.

DISCUSSION

"Knowing what you are dealing with is mandatory prior to the instrumentation of the esophagus. Death lurks here. History has proved it. There is no need to recapitulate history."[3(p2401)] With this motto in mind, we decided to conduct the current study.

Although CT is available today in almost every hospital and is easy to perform and to interpret, it has been almost entirely neglected in the evaluation of foreign body ingestion. Gamba et al[10] reported on the first case of detection of a foreign body by means of CT in 1983. A piece of bone that had escaped prior detection on a plain film, a barium swallow study, and esophagoscopy was detected by CT. Douglas and Sistrom[11] reported on a chicken bone that was seen by CT only. Braverman et al[12] evaluated 13 cases of fish bone and chicken bone ingestion by plain film and CT, and suggest that CT be used to assess patients with a suspected foreign body in the cervical esophagus and negative plain film results. The only other reference to the use of CT in the assessment of an ingested foreign body is by Mohr, who states that "on occasion, a computed tomography scan may be required to delineate the endoesophageal or exoesophageal presence of a foreign object."[3(p2401)] However, she still prefers to follow the negative plain film results of a symptomatic patient with a barium swallow study.[3]

TABLE 2. OUTCOME ACCORDING TO RESULTS OF CT SCAN

	Foreign Body Found at Endoscopy	*No Foreign Body Found at Endoscopy*	*Total*
Pathological CT scan	29 (96.7%)	1 (3.3%)	30 (100%)
	Evidence of Foreign Body Upon Observation	*No Evidence of Foreign Body Upon Observation*	*Total*
Normal CT scan	0 (0%)	15 (100%)	15 (100%)

We tend to agree with other investigators that most hypopharyngeal foreign bodies can be detected by means of a good physical examination and can be managed under local anesthesia with no necessity for any further investigation.[7] Esophageal foreign bodies, however, cannot be detected by a physical examination unless a flexible esophagoscope is used, and its use requires sedation and a skilled endoscopist. One should remember that in the Western world many people eat fish or chicken for their evening meal, and thus most cases of foreign body ingestion occur after working hours, when generally only residents are available. A reliable flexible endoscopic examination is then hard to provide. This procedure is also known to be uncomfortable for the patient.

Plain films of the neck and chest can identify radiopaque foreign bodies in the esophagus,[8] but they prove to be unsatisfactory when fish bones or thin chicken bones are encountered. Evans et al[4] found 25.3% sensitivity, 86.3% specificity, and a positive predictive value of 72.7% for the detection of impacted fish bones. They believe that routine radiography is not indicated because of the poor results. Derowe and Ophir[7] note 24% false-positive and 40% false-negative plain films. In a study by Sundgren et al,[6] the primary radiologist detected only 2 of 7 fish

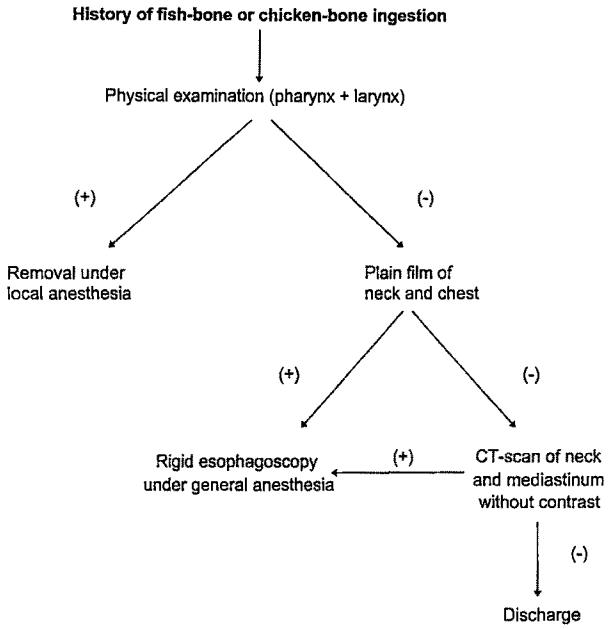

Suggested protocol for assessment of esophageal bone impaction.

bones that were found by endoscopic examinations. They conclude that patients with symptoms that started within the last 48 hours should be taken directly from oral to endoscopic examination if no suspected complication is evident. In the present study, the plain film detected only 16 of 29 bones found by endoscopy (55%). We therefore agree that plain films have a low yield in detecting foreign bodies in the esophagus.

Barium studies also seem to be ineffective in detecting an ingested fish bone or chicken bone. In the series of Derowe and Ophir,[7] 26.9% of the studies done with barium-soaked cotton were false-positive, and 40% were false-negative. Barium swallows may yield better results, but they involve a risk of aspiration. They also coat the foreign body and the esophageal mucosa, thus jeopardizing subsequent endoscopy.[1]

The reported rate of negative esophagoscopies in cases of suspected esophageal foreign bodies is 7% to 62%.[7] One may assume therefore, that many procedures can be avoided. In the present study, CT detected all the bones that were later found by endoscopy. The only case of a false-positive CT scan was probably due to calcification in the mucosa. Fourteen of the 15 patients with a negative CT scan managed quite well with no treatment whatsoever, and the esophagoscopy of the 1 patient who had persistent symptoms was negative. We may assume therefore that there were no false-negatives. It should be noted that all tests were interpreted by residents on call.

In conclusion, the present study is a result of our awareness of the high rate of negative esophagoscopies in cases of suspected esophageal bone impaction. Computed tomography, which is quite a simple examination, lowered this rate almost to zero. It proved to be very effective, with a sensitivity of 100%, a specificity of 93.7%, and a positive predictive value of 96.7%. It is done without contrast material and can be easily performed by a technician. Moreover, the patient is not exposed to any unnecessary complications. We therefore recommend performance of a CT scan in patients with a high index of suspicion of esophageal bone impaction and a negative plain film. The suggested protocol is shown in the Figure. We feel that by adopting this approach, the statement that "a certain percentage of negative esophagoscopies are inevitable"[7(p44)] will become irrelevant.

ACKNOWLEDGMENTS — The authors thank Dr Nehama Moshieff and Tamar Schwartz for their assistance in preparing the manuscript.

REFERENCES

1. Ginsberg GG. Management of ingested foreign objects and food bolus impaction. Gastrointest Endosc 1995;41:33-8.

2. Thompson JN, Browne JD. Caustic ingestion and foreign bodies in the aerodigestive tract. In: Bailey BJ, ed. Head and neck surgery–otolaryngology. Philadelphia, Pa: JB Lippincott, 1993:725-37.

3. Mohr RM. Endoscopy and foreign body removal. In: Paparella MM, Shumrick DA, Gluckman JL, Meyerhoff WL, eds. Otolaryngology. Philadelphia, Pa: WB Saunders, 1991: 2399-427.

4. Evans RM, Ahuja A, Rhys Williams S, Van Hasselt CA. The lateral neck radiograph in suspected impacted fish bones: does it have a role? Clin Radiol 1992;46:121-3.

5. Marais J, Mitchell R, Wightman AJA. The value of radiographic assessment for oropharyngeal foreign bodies. J Laryngol Otol 1995;109:452-4.

6. Sundgren PC, Burnett A, Maly PV. Value of radiography in the management of possible fishbone ingestion. Ann Otol Rhinol Laryngol 1994;103:628-31.

7. Derowe A, Ophir D. Negative findings of esophagoscopy for suspected foreign bodies. Am J Otolaryngol 1994;15:41-5.

8. Singer J, Heiken JP. Diagnostic imaging of the esophagus. In: Cummings CW, Fredrickson JM, Harker LA, Krause CJ, Schuller DE, eds. Otolaryngology–head and neck surgery. St Louis, Mo: Mosby–Year Book, 1993:2258-87.

9. Tong MC, Woo JK, Sham CL, Van Hasselt CA. Ingested foreign bodies. A contemporary management approach. J Laryngol Otol 1995;109:965-70.

10. Gamba JL, Heaston DK, Ling D, Korobkin M. CT diagnosis of an esophageal foreign body. AJR 1983;140:289-90.

11. Douglas M, Sistrom CL. Chicken-bone lodged in the upper esophagus: CT findings. Gastrointest Radiol 1991;16:11-2.

12. Braverman I, Gomori M, Polv D, Saah D. The role of CT imaging in the evaluation of cervical esophageal foreign bodies. J Otolaryngol 1993;22:311-4.

IMAGING CASE STUDY OF THE MONTH

RARE CAUSE OF BLINDNESS IN A PATIENT WITH ACQUIRED IMMUNODEFICIENCY SYNDROME

MICHAEL A. COOK, DO
NEW YORK, NEW YORK
DAVID MASINI
NEW YORK, NEW YORK
ORLANDO L. MANFREDI, MD
STATEN ISLAND, NEW YORK
JESSE J. LOPEZ, JR, DO
MOUNT PLEASANT, IOWA

The differential diagnosis of blindness in patients with acquired immunodeficiency syndrome (AIDS) includes those disorders that occur in immunocompetent patients, as well as those disorders that are peculiar to the AIDS subpopulation of immunosuppressed patients.[1] Blindness in patients with AIDS is most often due to infectious retinitis or human immunodeficiency virus (HIV) retinopathy. We present the first reported case of blindness due to lymphomatous involvement of the optic nerve secondary to maxillary sinus lymphoma in a patient with AIDS.

CASE REPORT

A 38-year-old woman with a history of AIDS and a CD4 count of 20/mm^3 (normal 500 to 1,600/mm^3) of 3 years' duration presented because of acute loss of vision in the right eye, swelling of the right lower eyelid, and nasal congestion. She denied systemic symptoms. Her past medical history was significant for genital herpes, herpes pharyngitis, oral candidiasis with esophagitis, bronchopneumonia, *Pneumocystis carinii* pneumonia, microcytic hypochromic anemia, disseminated multi–drug-resistant *Mycobacterium avium-intracellulare* infection, and hepatitis B. Her medications included zidovudine (azidothymidine; AZT), clotrimazole troches, acyclovir sodium, recombinant human erythropoietin, and aerosolized pentamidine.

The patient was alert and oriented. The physical examination revealed bilateral conjunctival edema, and mild edema and erythema of the right orbit. There was no light perception in the right eye, and there was paralysis of the right extraocular muscles. Fundoscopic examination of the right eye revealed several flame-shaped hemorrhages and exudates. The left eye was fundoscopically normal. Her temperature was 38.3°C orally. There was no peripheral adenopathy. The oral cavity was unremarkable. Radiographs of the paranasal sinuses demonstrated opacification of the maxillary, ethmoid, and sphenoid sinuses. Computed tomography revealed near-complete opacification of the right maxillary sinus, an air-fluid level in the left maxillary sinus, and opacification of the ethmoid and sphenoid sinuses. The globes were normal. The patient was treated for acute pansinusitis. She received 10 days of amoxicillin–clavulanate potassium (500 mg every 8 hours) and pseudoephedrine hydrochloride drops 0.5% (3 drops to each nostril 3 times per day). The serum cytomegalovirus IgG antibody titer was negative. The patient improved clinically, was discharged, and completed 3 weeks of oral antibiotics, following which her symptoms resolved.

Several months later, the patient returned with exophthalmos of the right eye. Computed tomography of the orbits (see Figure, A) revealed a large soft tissue mass that filled the right maxillary sinus and expanded the medial sinus wall. There was bone destruction involving the orbital floor and the medial and anterior maxillary walls. The mass penetrated into the infratemporal fossa and extended into the malar subcutaneous tissues, right ethmoid sinus, and sphenoid sinus, as well as into the optic nerve, causing proptosis. Invasion of the posterior globe was also evident (see Figure, B,C). The left maxillary sinus, ethmoid sinuses, orbit, and globe were normal.

A biopsy of the maxillary mass demonstrated a diffuse, high-grade, large cell, immunoblastic lymphoma with plasmacytoid differentiation. The patient refused chemotherapy but underwent radiotherapy

From the Department of Radiology, St Luke's–Roosevelt Hospital Center and Columbia University College of Physicians and Surgeons, New York (Cook, Masini), the Department of Radiology, St Vincent's Medical Center of Richmond, Staten Island (Manfredi), New York Medical College, Valhalla (Manfredi), New York, and Henry County Surgical Care, Mount Pleasant, Iowa (Lopez).
CORRESPONDENCE — Michael A. Cook, DO, 105 Twombly Ave, Staten Island, NY 10306-3858.

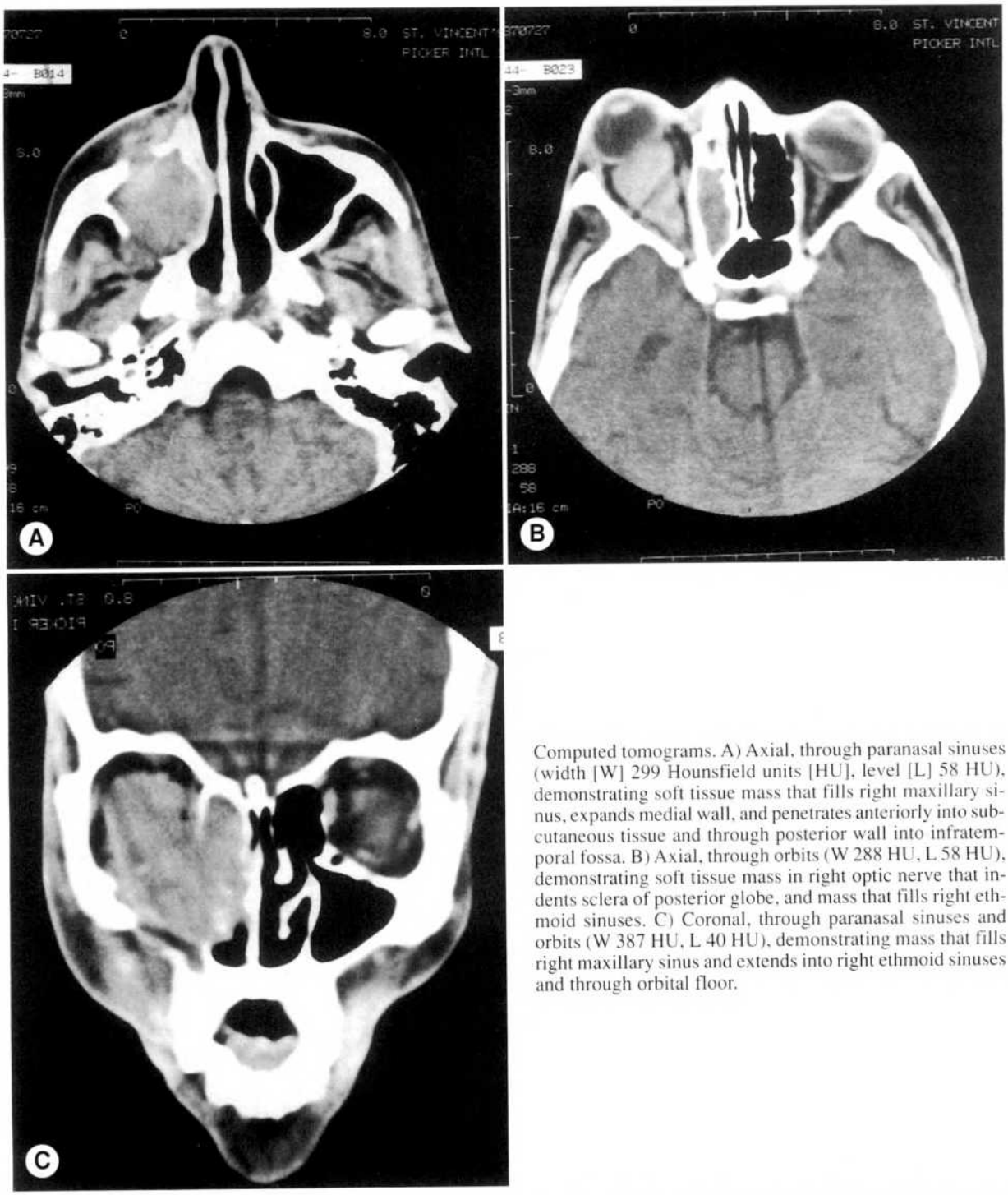

Computed tomograms. A) Axial, through paranasal sinuses (width [W] 299 Hounsfield units [HU], level [L] 58 HU), demonstrating soft tissue mass that fills right maxillary sinus, expands medial wall, and penetrates anteriorly into subcutaneous tissue and through posterior wall into infratemporal fossa. B) Axial, through orbits (W 288 HU, L 58 HU), demonstrating soft tissue mass in right optic nerve that indents sclera of posterior globe, and mass that fills right ethmoid sinuses. C) Coronal, through paranasal sinuses and orbits (W 387 HU, L 40 HU), demonstrating mass that fills right maxillary sinus and extends into right ethmoid sinuses and through orbital floor.

in the form of 2,600 cGy in 13 fractions using anterior and right lateral cobalt 60 wedge-shaped fields. The patient died 4 months following diagnosis.

DISCUSSION

Paranasal sinus lymphoma is a rare manifestation of HIV. Most cases of AIDS-related lymphoma are extranodal, are of the non-Hodgkin's variety, are derived from B-cells, and occur in the central nervous system, gastrointestinal tract, bone marrow, and oral cavity. There have only been 17 reported cases of paranasal sinus lymphoma in patients with AIDS, including the case reported here.[2-15] Of the reported cases, 12 occurred in males (71%) and 5 in females (29%). The gender of 1 patient was not specified (see Table[2-15]). Risk factors for HIV disease included homosexual intercourse in 8 patients (57%), intravenous drug use in 5 (36%), and a blood transfusion in 1 (7%). The risk factor was not reported in 3 patients. Maxillary sinus involvement was noted in all

PATIENTS WITH ACQUIRED IMMUNODEFICIENCY SYNDROME AND PARANASAL SINUS LYMPHOMA

Case	Reference	Age (y)	Sex	Risk Factor	Location of Tumor
1	2	31	M	HI	Right maxillary
2	2	34	M	HI	Left maxillary, left nostril
3	3	NR	NR	NR	Maxillary
4	4	25	M	HI	Both frontal and both maxillary, right sphenoid, left orbit
5	5	33	M	NR	Right ethmoid, right orbit
6	6	27	F	IVDU	Right maxillary, right orbit
7	7	42	M	HI	Right maxillary
8	7	43	M	HI	Maxillary
9	8	27	M	NR	Right maxillary, right orbit
10	9	64	F	BT	Left maxillary
11	10	38	F	NR	Both maxillary, ethmoid, sphenoid, left orbit
12	11	34	M	IVDU	Right maxillary, right ethmoid, right orbit
13	12	44	M	HI	Right maxillary
14	13	28	M	HI	Left maxillary, left ethmoid, left orbit
15	14	35	F	IVDU	Both maxillary, ethmoid, sphenoid, right orbit
16	14	43	M	HI	Right maxillary, right ethmoid, right sphenoid
17	15	31	M	IVDU	Right maxillary
18	TR	38	F	IVDU	Right maxillary, right ethmoid, right sphenoid, right orbit

HI — homosexual intercourse, NR — not reported, IVDU — intravenous drug use, BT — blood transfusion, TR — this report.

cases with the exception of 1. Orbital involvement was present in 8 cases. However, this is the first reported case in a patient with AIDS in which the tumor invaded the optic nerve, penetrated the globe, and resulted in blindness.

Paranasal sinus lymphoma presents with nonspecific signs and symptoms that overlap those of chronic sinusitis. Typical symptoms include rhinorrhea, nasal congestion, facial pain, maxillary toothache, periorbital edema, eye pain, ptosis, proptosis, and ophthalmoplegia.[14] Systemic symptoms such as fever and weight loss are uncommon. Because the signs and symptoms of paranasal sinus lymphoma are indistinguishable from those of chronic sinusitis, the diagnosis is frequently delayed. A high index of suspicion must be maintained in order to make a timely diagnosis.

Cross-sectional imaging is essential in the management of patients with paranasal sinus lymphoma. Computed tomography is ideal, because it is readily available and very sensitive to osseous involvement. The computed tomographic appearance can be rather subtle, such as mucoperiosteal thickening, and can simulate a benign process such as polyp formation, retention cyst, or pansinusitis. In patients with AIDS, paranasal sinus lymphoma is usually more aggressive than it is in patients without HIV infection. The typical appearance of paranasal sinus lymphoma in patients with AIDS is that of a soft tissue mass with osseous destruction. Because of the bony destruction, the tumor can invade the anterior and middle cranial fossae.

The differential diagnosis of a soft tissue mass originating in a maxillary sinus and eroding bone includes infectious and neoplastic processes such as squamous cell carcinoma, adenoid cystic carcinoma, mucoepidermoid tumors, rhabdomyosarcoma, osteosarcoma, chondrosarcoma, lymphoma, metastases, hemangiopericytoma, aspergillosis, and mucormycosis.[16] A biopsy is required to establish the diagnosis and initiate treatment.

Most patients with AIDS have disseminated disease at the time the diagnosis of paranasal sinus lymphoma is established, or develop disseminated disease soon after the diagnosis. For staging purposes, computed tomography of the chest and abdomen is indicated. Treatment options include radiotherapy with or without systemic adjuvant chemotherapy. The goals of radiotherapy are local control of the tumor and palliation of symptoms. Most chemotherapy regimens consist of cyclophosphamide, doxorubicin hydrochloride, vincristine, and prednisone with or without intrathecal methotrexate or cytosine arabinoside (cytarabine).[14] The prognosis is very poor, since the disease is usually disseminated. Death usually occurs within a few months.

Paranasal sinus lymphoma is rarely associated with HIV. Since the signs and symptoms mimic those of chronic sinusitis, the diagnosis is often established late in the course of the illness. A high index of suspicion for an early diagnosis is essential, as the disease is usually very aggressive, associated with disseminated disease, and rapidly fatal.

REFERENCES

1. Jabs DA, Green WR, Fox R, Polk BF, Bartlett JG. Ocular manifestations of acquired immunodeficiency syndrome. Ophthalmology 1989;96:1092-9.

2. Lees FR, Keffler DJ, Mickel RA. Non-Hodgkin's lymphoma of the head and neck in patients with AIDS. Arch Otolaryngol Head Neck Surg 1987;133:1104-6.

3. Quivey JM, Berson A, Wara WW. The role of radiation therapy in the treatment of AIDS related non-Hodgkin's lymphoma [Abstract]. Proc Annu Meet Am Soc Clin Oncol 1989: A22.

4. Antle CM, White VA, Horsman DE, Rothman J. Large cell orbital lymphoma in a patient with acquired immune deficiency syndrome: case report and review. Ophthalmology 1990; 97:1494-8.

5. Monsour AM. Orbital findings in acquired immunodeficiency syndrome. Am J Ophthalmol 1990;110:706-7.

6. Goldstein J, Rubin J, Becker N, Moser F, Silverstein M, Davis L. Lymphoma of the maxillary sinus in a patient infected with the human immunodeficiency virus type 1. Head Neck 1991;13:355-8.

7. Langford A, Dienemann D, Schurman D, et al. Oral manifestations of AIDS-associated non-Hodgkin's lymphomas. Int J Oral Maxillofac Surg 1991;20:136-41.

8. Desai UR, Peyman GA, Blinder KJ, Alturki WA, Paris CL, Nelson NC Jr. Orbital extension of sinus lymphoma in AIDS patient. Jpn J Ophthalmol 1992;36:205-14.

9. Rosenthal J, Katz R, DuBois DB, Morrissey A, Machicao A. Chronic maxillary sinusitis associated with the mushroom *Schizophyllum commundo* in a patient with AIDS. Clin Infect Dis 1992;14:46-8.

10. Rubin MM, Sanfilipo RJ. Lymphoma of the paranasal sinuses presenting as cavernous sinus lymphoma. J Oral Maxillofac Surg 1992;50:749-51.

11. Turok DI, Meyer DR. Orbital lymphoma associated with acquired immunodeficiency syndrome. Arch Ophthalmol 1992; 110:610-1.

12. Font RL, Laucirica R, Patrinely JR. Immunoblastic B-cell malignant lymphoma involving the orbit and maxillary sinus in a patient with acquired immunodeficiency syndrome. Ophthalmology 1993;100:966-70.

13. Park KL, Goins KM. Hodgkin's lymphoma of the orbit associated with acquired immunodeficiency syndrome. Am J Ophthalmol 1993;116:111-2.

14. Pomilla PV, Morris AB, Jaworek A. Sinonasal non-Hodgkin's lymphoma in patients infected with human immunodeficiency virus: report of three cases and review. Clin Infect Dis 1995;21:137-49.

15. Mendez Martinez MA, Perez de Oteyza C, Gomez P, et al. Linfoma de seno maxilar asociado a infeccion VIH. An Med Interna 1994;2:192-4.

16. Mafee MF. Nonepithelial tumors of the paranasal sinuses and nasal cavity: role of CT and MR imaging. Radiol Clin North Am 1993;31:75-90.

ANALYSIS OF THE FORCES AND POSITION REQUIRED FOR DIRECT LARYNGOSCOPIC EXPOSURE OF THE ANTERIOR VOCAL FOLDS

ILAN I. HOCHMAN, MD
TEL AVIV, ISRAEL

STEVEN M. ZEITELS, MD
BOSTON, MASSACHUSETTS

JAMES T. HEATON, PHD
BOSTON, MASSACHUSETTS

The sniffing position is traditionally considered optimal for direct laryngoscopic examination of the vocal folds. This study examined head and neck positions associated with ideal exposure of the anterior glottal commissure with a variety of laryngoscopes. A prospective investigation was done in 20 patients by comparing the force required to expose the anterior vocal folds by utilizing 3 head and neck positions with 3 different-sized tubular laryngoscopes. The completeness of anterior glottal exposure was rated and the force required to achieve this exposure was measured with a strain gauge. Three positions relating the atlanto-occipital and cervicothoracic vertebrae were analyzed: 1) extension-extension, 2) sniffing: extension-flexion, and 3) flexion-flexion. Head and neck position and laryngoscope size were both statistically significant factors for achieving complete anterior vocal fold exposure. Regardless of the laryngoscope, the number of patients in whom complete exposure could be achieved increased gradually when the position was changed from extension-extension to extension-flexion to flexion-flexion. Complete exposure was inversely related to larger laryngoscope size. According to the data herein, the flexion-flexion position provides the best glottal exposure for endotracheal intubation in those patients who are anatomically predisposed to difficulty in direct examination of the glottis. Because this places the laryngoscope lumen in a vertical position, this position is inappropriate for microlaryngoscopy. The study reinforced the concept that the sniffing position is the optimal position for microlaryngoscopy because it enables the use of the largest-lumened laryngoscope. This facilitates ideal exposure of the anterior vocal folds, which is necessary for phonomicrosurgery.

KEY WORDS — airway management, endotracheal anesthesia, glottis, intubation, laryngoscope, laryngoscopy, vocal cords, vocal folds.

INTRODUCTION

Despite the fact that direct laryngoscopy is frequently performed by emergency physicians, anesthesiologists, and laryngologists, there is a paucity of literature that has critically analyzed the ideal position for exposing the anterior glottis and the forces required to do so. Since Kirstein[1,2] formally introduced autoscopy (direct laryngoscopy) in 1895, the technique has developed primarily as an art and a craft, based on trial and error, rather than through scientific investigation. Although visualization of the vocal folds is typically routine and uneventful after induction of general anesthesia, failure to intubate has been reported to account for 35% of adverse respiratory events.[3] Failure to expose the entire musculomembranous vocal folds during intubation is a frequently encountered problem and can result in local injuries to the larynx, ranging from mild soft tissue trauma to arytenoid dislocation. When the direct visualization of the vocal folds is performed for microlaryngoscopic surgery, inadequate exposure can result in abortion of the procedure, incomplete surgery, and/or unnecessary trauma to the normal layered microstructure of the vocal fold.[4,5]

Green[6] described the optimal head and neck position for direct laryngoscopy prior to the origin of the field of laryngology. He placed the patient in a "sniffing" position in front of a window to utilize the sun for illumination. Czermak[7] employed the same position for indirect mirror laryngoscopy (Fig 1[5]), because this position ideally aligned the pharyngeal cavity for exposure of the larynx. Over 30 years later, Kirstein[1,2] adopted this position for sitting direct laryngoscopy (Fig 2[8]). Subsequently, Jackson[9] utilized Czermak's and Kirstein's position, but with the patient recumbent and supine (Fig 3[5,10]). This required an assistant[11] to support the head and neck; this position is now known as the Boyce-Jackson position (Fig 4). Jackson[12,13] also determined that the laryngoscope should be placed along the lateral aspect of the tongue rather than the middle of the tongue as suggested by Kirstein. However, Jackson's operative technique was compromised by the fact that the surgeon was required to maintain the laryngoscope with 1 hand while performing 1-handed surgery with the contralateral hand.[4]

From the Department of Otology and Laryngology, Harvard Medical School, and the Department of Otolaryngology, Massachusetts Eye and Ear Infirmary, Boston, Massachusetts. Dr Hochman is currently in the Department of Otolaryngology, Sourasky Medical Center, Tel Aviv University, Tel Aviv, Israel.

Presented at the meeting of the American Broncho-Esophagological Association, Palm Beach, Florida, May 11-12, 1998.

CORRESPONDENCE — Steven M. Zeitels, MD, Dept of Otolaryngology, Massachusetts Eye and Ear Infirmary, 243 Charles St, Boston, MA 02114.



Fig 1. Czermak performing mirror laryngoscopy with external laryngeal counterpressure; patient is in sniffing position. (Reprinted[5]; originally from Czermak JN. Der Kehlkopfspiegel und seine Verwerthung für Physiologia und Medizin. Leipzig: Engelman, 1858.)

Fig 2. Kirstein performing direct laryngoscopy with patient in sniffing position. (Reprinted.[8])

Killian understood the limitations of 1-handed endoscopic laryngeal surgery and designed his suspension gallows to stabilize the laryngoscope and the patient, which allowed for bimanual surgery.[4,8,14,15] Unfortunately, he employed an extension-extension position, which was ill-suited for exposing the anterior glottis.[8,16] This shortcoming in position was rectified in part when he had one of his disciples, Brunings, retrofit an external counterpressure device[8,17] (Fig 5[5,8]). The senior author (S.M.Z.) has been unable to determine why Killian never adopted Jackson's superior positioning technique and why Jackson never employed a laryngeal suspension device to free his second hand.[4,13] This is most curious, since these advantages seem self-evident and since these leaders collaborated academically on Jackson's compendium textbook, *Peroral Endoscopy and Laryngeal Surgery* (1915).[18]

Many laryngologists had difficulty performing suspension laryngoscopy with the Killian gallows. Among them were 2 of Killian's most well-known students, Brunings and Seiffert. They each modified the suspension laryngoscope system by producing a fulcrum holder. Although both devices exerted their force on the maxilla, Brunings' instrument pushed off the laryngeal cartilage (Fig 6[5]) and Seiffert's instrument[4] pushed off the chest wall. This approach applied the force for exposure to the maxilla rather than the mandible, and was hence different from the approaches of Green, Kirstein, Jackson, and Killian. In 1948, Roberts[19,20] was the first to join a fulcrum holder to a tubular laryngoscope. Subsequently, retrofitted fulcrum laryngoscope holders[21-23] were attached to C-shaped tubular laryngoscopes, and this became the prevalent approach for laryngeal exposure during endolaryngeal surgery. Many surgeons preferred to support the laryngoscope holder from a platform rather than the chest wall to avoid compression of the thoracic cavity. It was not until the 1970s[10,24] that principles of exposure espoused by Jackson and Killian[4] were combined in modern suspension gallows,[10] which could create elevated-vector suspension (Fig 7[5]). Grundfast and the Boston University group introduced this device, for which the mechanical works were a window crank.

The importance of direct laryngoscopic exposure became more crucial when endotracheal intubation[25] became a fundamental component of general anesthesia and ventilatory life support. Initially, endotracheal anesthesia developed independently from direct laryngoscopy. In 1912, Elsberg utilized Jackson's laryngoscope and technique, ushering in modern endotracheal anesthesia.[26] It is ironic that it was not until the 1960s that laryngoscopic surgery was done in conjunction with endotracheal anesthesia.[27] Prior to that time, laryngologists thought that the endotracheal tube would impair exposure of the glottal surgical field.

In this decade, the development of more precise and sophisticated phonomicrosurgical techniques[4,28-32]

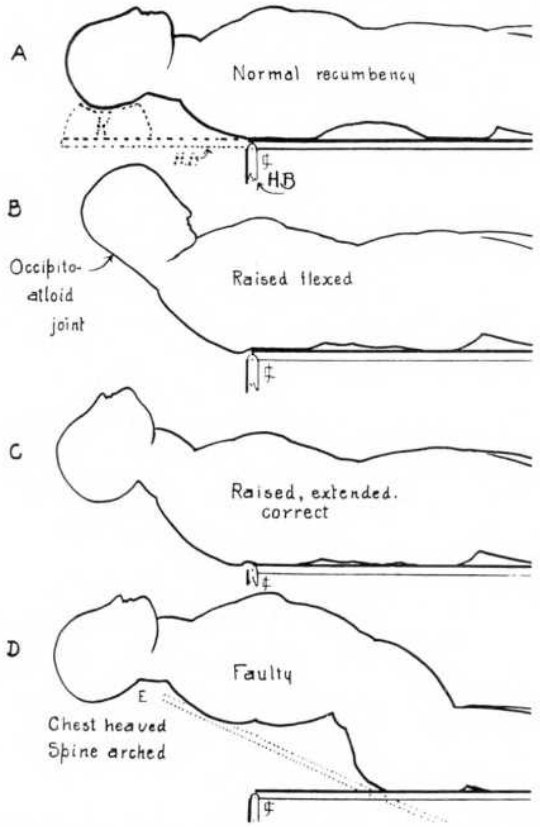

Fig 3. Jackson's image of variety of head and neck positions for supine direct laryngoscopy. Correct position for direct laryngoscopic surgery is sniffing (Boyce-Jackson) position. (Reprinted.[5,10])

has led to the need for complete and wide exposure of the anterior musculomembranous vocal folds. Placement of the widest-lumen glottiscope between the lips and the vocal folds mandates optimizing head and neck position. In considering these 2 perspectives (intubation and phonomicrosurgery), there are a number of observations that can be made about current approaches to direct endoscopic exposure of

Fig 4. Boyce-Jackson position is maintained by assistant serving to position and stabilize head and neck. (Reprinted with permission from Jackson C, Jackson CL. Diseases of the nose, throat and ear. Philadelphia, Pa: WB Saunders, 1945:435. Reprinted with permission.)

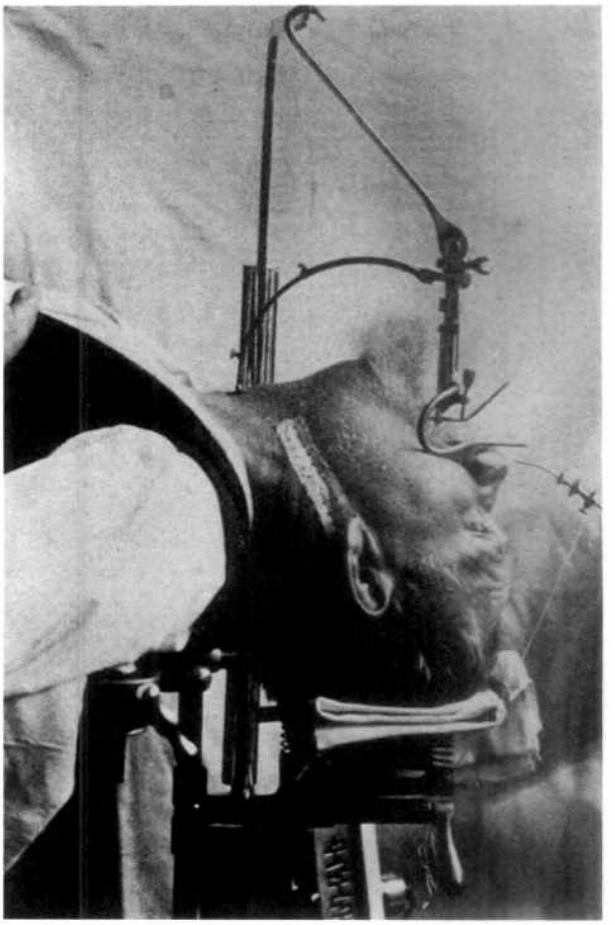

Fig 5. Killian suspension laryngoscope with Brunings external counterpressure device. Patient is in extension-extension position, which is not ideal for adequate exposure. (Reprinted.[8])

the larynx.

1. Most laryngologists use a fulcrum laryngoscope holder, which utilizes the chest wall or a stand as a stable base from which to exert its force on the maxilla. This has been the predominant approach and has been reasonably successful.

2. The laryngoscope that provides the *widest* exposure of the laryngeal surgical field will optimally facilitate the operative procedure by facilitating full stereoscopic visualization, angulation of hand instrumentation proximally, and room for tissue retraction distally.[5]

3. During endolaryngeal surgery, laryngologists routinely place a smaller laryngoscope in the patient when the anterior musculomembranous vocal folds are not visualized through their usual instrument.

4. The sniffing (Boyce-Jackson) position is universally quoted as the ideal position to expose the vocal folds for both intubation and microlaryngeal surgery.

5. During intubation or phonomicrosurgery, the

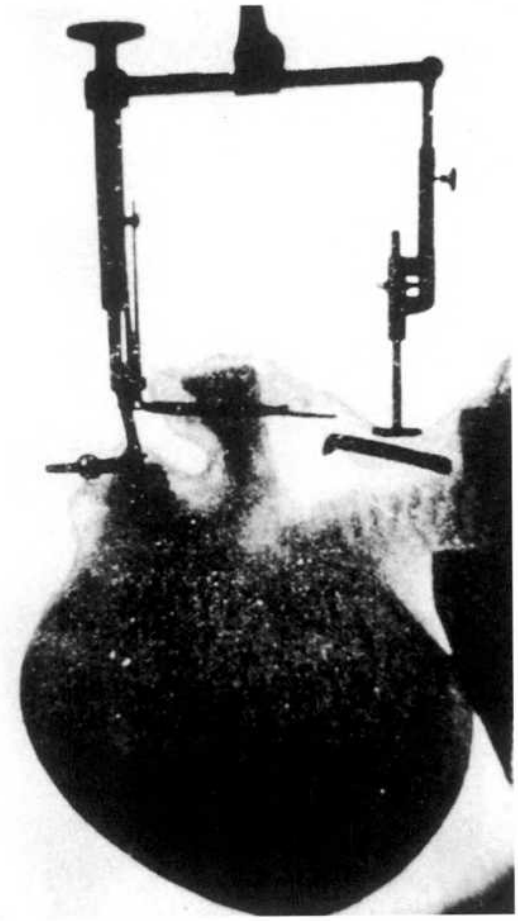

Fig 6. Brunings external counterpressure suspension laryngoscope in position in cadaver. Depression of larynx is observed with dilating stent in place. (Reprinted.[5])

sniffing position is typically achieved by placing a support under the occiput and/or shoulders, such as a pillow.[18,19]

6. A number of unusual laryngoscopes have been designed and patented to facilitate difficult intuba-

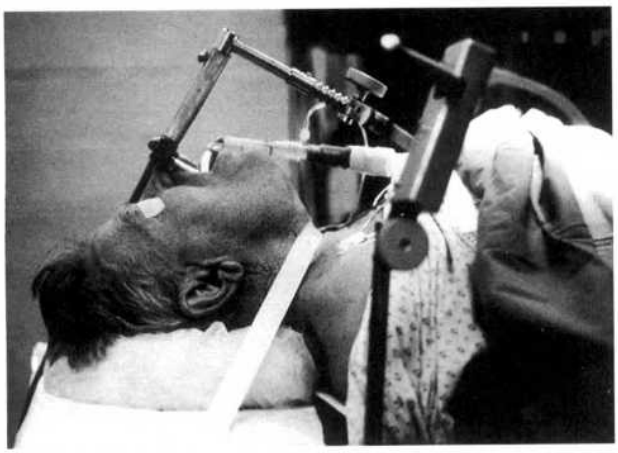

Fig 7. Current patient, who is maintained in elevated vector suspension by Boston University Gallows (Pilling Co). External counterpressure is applied with silk tape. (Reprinted.[5])

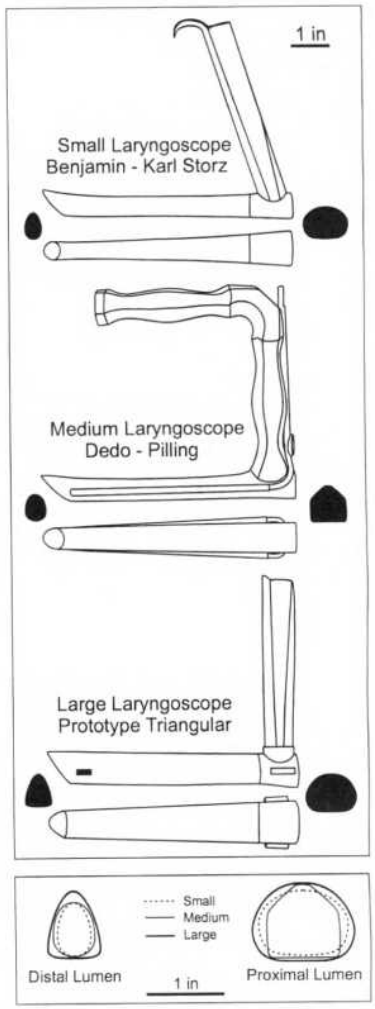

Fig 8. Three laryngoscopes, varying in size, used to assess exposure. Small is Benjamin (Storz Co); medium is Dedo (Pilling Co); and large is prototype Vaughan.[33]

tions. Fiberoptic-controlled intubation has become the most frequent solution to the problem of difficult intubation. However, that equipment is not always available at the moment it becomes necessary.

7. Many laryngologists employ rigid telescopes through the lumen of the laryngoscope to enhance visualization of the anterior glottis, especially when complete exposure is not achieved.

Review of the literature reveals that direct exposure of the larynx has developed primarily as an art and a craft without sophisticated scientific investigations based on anatomic principles. We could not identify a single study that compared the exposure of the glottis with different laryngoscopes in different positions while measuring the forces required to achieve the exposure. This seemed quite surprising, considering a number of facts: 1) the art of direct laryngoscopy has been practiced for over a century; 2) there is a large body of academic and patent literature describing instrumentation; 3) direct laryngo-

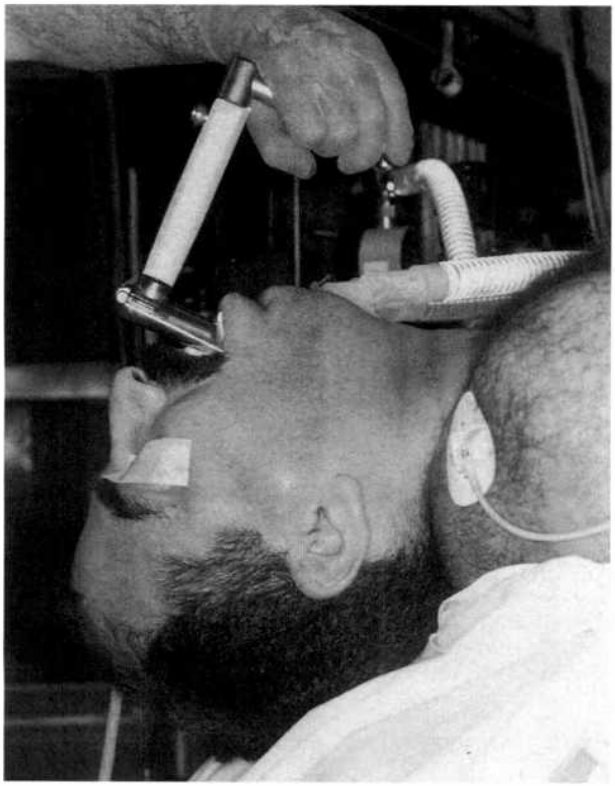

Fig 9. Extension of neck with relation to chest and extension of head with relation to neck at atlanto-occipital joint.

scopic exposure of the vocal folds for intubation is a fundamental component of artificial life support in hospitalized patients; and 4) direct laryngoscopic exposure of the vocal folds for intubation is a skill that all physicians should learn, especially as a component of cardiopulmonary resuscitation courses.

The aforementioned observations led to a number of questions:

1. What is the ideal head and neck position to expose the vocal folds and to intubate the patient with normal anatomy and the patient with a difficult airway?

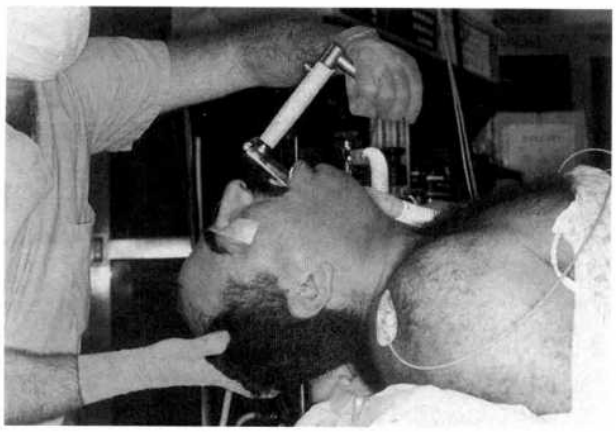

Fig 10. Flexion of neck with relation to chest and extension of head with relation to neck at atlanto-occipital joint; sniffing or Boyce-Jackson position.

Fig 11. Flexion of neck with relation to chest and flexion of head with relation to neck at atlanto-occipital joint.

2. What are the anatomic factors that lead to difficulty in direct exposure of the larynx?

3. Does the size of the laryngoscope alter the ability to expose the vocal folds?

4. What are the anatomic characteristics of patients who are difficult to expose?

5. What is the ideal head and neck position to expose the vocal folds for microlaryngeal surgery in the patient with normal anatomy and the patient with a difficult airway?

6. What is meant by the term "anterior larynx"?

7. If the vector forces generated by a laryngoscope

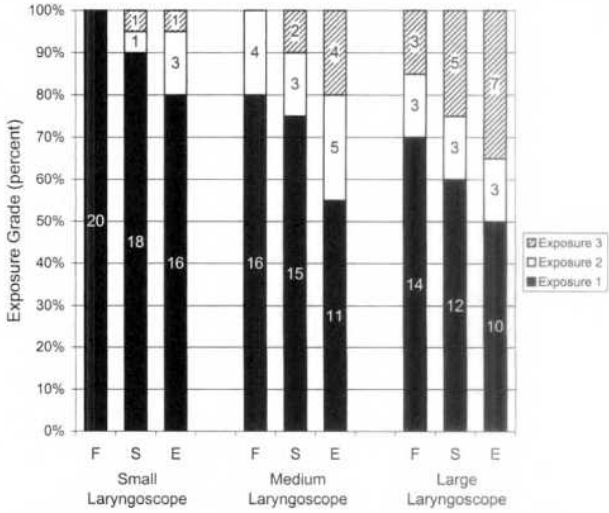

Fig 12. Exposure as function of head and neck position for small, medium, and large laryngoscopes. Both head and neck position and laryngoscope size significantly affected exposure ($p < .05$), as shown by frequency of grade 1 exposure (in black) attained with smallest laryngoscope and flexion position across all laryngoscopes. F — flexion position, S — sniffing position, E — extension position.

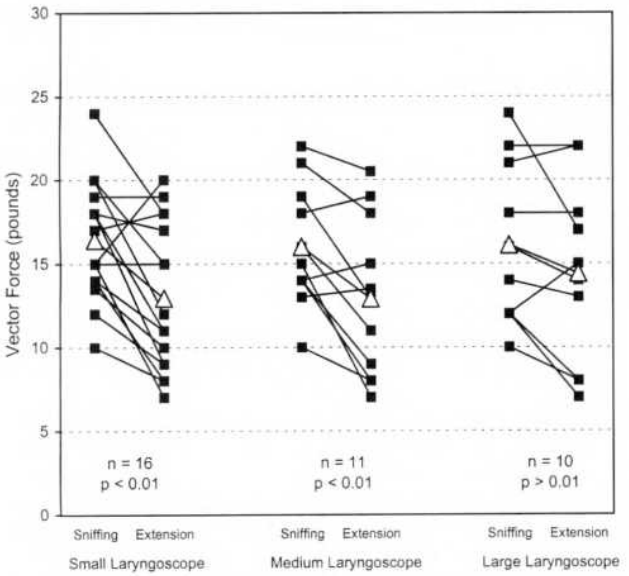

Fig 13. Comparison of suspension vector forces applied during complete (grade 1) exposures in sniffing and extension positions for small, medium, and large laryngoscopes. Individual data points are given for each patient as connected black boxes, averages are shown as connected triangles, and results of paired *t*-tests for position effect are given below each data set.

holder do not create optimal force vectors for laryngeal exposure, why can most larynges be exposed by this instrumentation?

These observations and unanswered questions led to this investigation. This study was constructed to perform an initial scientific analysis of the laryngoscopic technique for vocal fold exposure. It was hoped that the information would provide explanations for current laryngoscopic methods, as well as provide valuable insights for future improvements in direct laryngoscopic technique and instrumentation.

MATERIALS AND METHODS

Institutional human studies committee approval was obtained, and 20 patients undergoing suspension microlaryngoscopy for various indications were entered into the study. After induction of anesthesia, intubation, and complete paralysis, 3 tubed laryngoscopes (Fig 8[33]) were used to expose the vocal folds in 3 positions (Figs 9-11). The 3 positions were based on the relationship of the neck to the chest and the head to the neck. "Extension-extension" was achieved by placing the occiput below the horizontal plane of the shoulders. "Flexion-extension" (classic sniffing or Boyce-Jackson position) and "flexion-flexion" (chin to chest) were achieved initially with an assistant supporting the head. Subsequently, the suspension force measurements were obtained with a strain gauge attached to a handle extension (without support of the head). During the initial trial, the assistant lightly supported and balanced the patient's head to maintain stability in the flexion-flexion position. This technique led to incorrect decreased force figures, and so this was abandoned. A handle extension[10] is necessary to measure the vector force at the distal lumen of the laryngoscope, just above the vocal folds. Once the optimal exposure was obtained, the force measurements were recorded. Typically, each position with each laryngoscope was measured twice. If there was a discrepancy, a third measurement was obtained. The degree of vocal fold exposure was rated on a 3-point scale: 1) complete, including the anterior commissure, 2) incomplete, including the posterior musculomembranous vocal folds, and 3) incomplete, comprising only the arytenoid region.

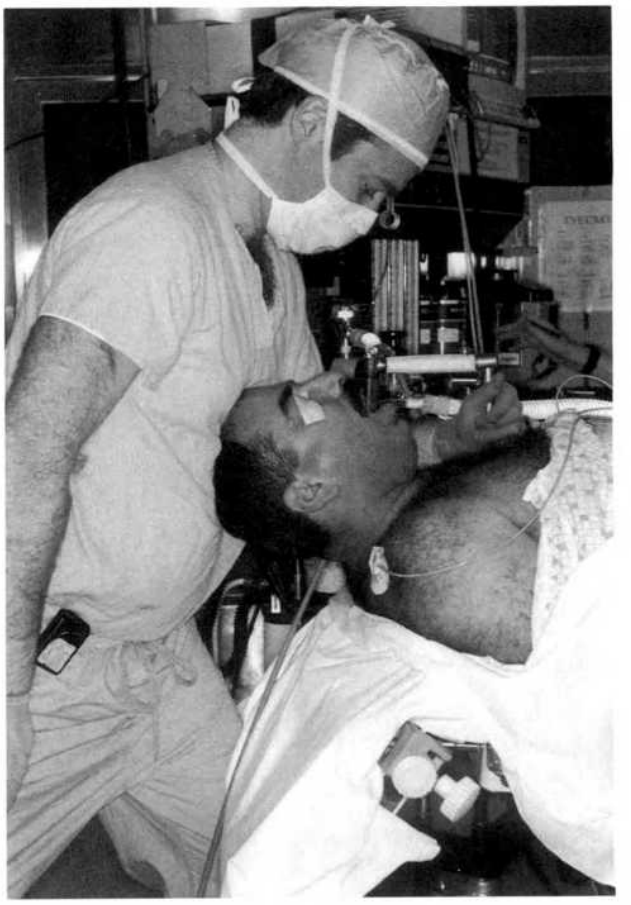

Fig 14. Flexion-flexion position demonstrating placement of occiput of patient on surgeon's chest to stabilize head and neck for direct laryngoscopic examination and/or intubation.

The frequency of occurrence for complete and incomplete exposures in the 3 head and neck positions using the 3 laryngoscope sizes was statistically examined with a Pearson χ^2 test. In addition, vector force measurements for extension-extension versus sniffing positions were statistically compared for each of the 3 laryngoscope sizes with 3 paired *t*-tests. A Bonferroni adjustment of the α level for these multiple

Fig 15. Early 20th-century photograph demonstrating Killian's flexion-flexion position for examining patient by means of mirror laryngoscopy. (Reprinted.[35])

t-tests was performed to combat α inflation. The starting α level of 0.05 (2-tailed) was adjusted to 0.016 (0.05/3) for rejecting the null hypothesis.

RESULTS

Head and neck position and laryngoscope size were both significant ($p < .05$) factors for achieving complete exposure of the anterior glottal commissure. Figure 12 demonstrates that complete glottal exposure could be achieved in all patients only when the smallest laryngoscope was used in a flexion-flexion position. Furthermore, exposure of the musculomembranous vocal folds deteriorated with the larger-lumen laryngoscopes and with extension of the head and/or neck. It was remarkable that the anterior commissure of the glottis was visible in only 50% of patients with the largest laryngoscope.

The suspension vector forces required to obtain complete exposure for each patient were similar, on average, across the small, medium, and large laryngoscopes regardless of head and neck position (16.4, 17.5, and 17.5 pounds, respectively; Fig 13). However, for instances in which complete exposures were

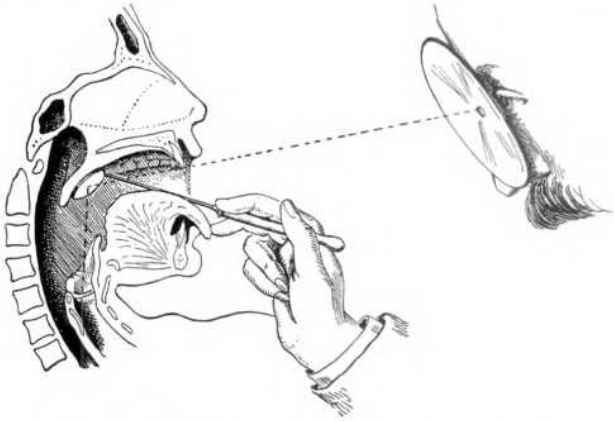

Fig 16. Early 20th-century diagram demonstrating Killian's flexion-flexion position for examining patient by means of mirror laryngoscopy. This position aligns oral and pharyngeal cavities to facilitate examination of vocal folds. (Reprinted.[35])

achieved, the extension position required significantly less suspension vector force than the sniffing position for the small and medium laryngoscopes ($p < .01$), with a similar trend for the large laryngoscope ($p > .01$; Fig 13). If complete exposure could not be achieved, the vector forces were not consistently lower in the extension position, as they were for complete exposures. Due to the small number of incomplete exposures, this observation could not be analyzed statistically.

DISCUSSION

The results confirmed a number of commonly accepted clinical observations and revealed a few surprising observations, which have important clinical implications. The findings explained why glottic exposure is not problematic in most patients, despite the lack of optimal positioning. The findings also suggest that we must reexamine the ideal head and neck position for direct laryngoscopy in the patient who is difficult to expose.

Most patients can be intubated without difficulty with the occiput on a flat operating table, and can be exposed for microlaryngeal surgery with a fulcrum laryngoscope holder (without the use of a true suspension gallows). These observations are supported by the finding that all patients could be exposed in the region of the arytenoids, which is the requirement for intubation. Further, the anterior commissure could be exposed (in extension-extension position) in 16 of the 20 patients with the small-tubed laryngoscope, which is commensurate in size to a standard straight-spatula intubation laryngoscope. Most phonomicrosurgical patients can be exposed with a fulcrum laryngoscope holder, because most individuals have favorable anatomy and because the surgeon has the option to place a smaller laryngoscope. In the majority

of patients, the force required for laryngeal exposure using a small laryngoscope relates to the distraction of pliable oral, pharyngeal, and supraglottal tissues and is not related to lifting the head and neck off the operating table. This is demonstrated by the drop in pressure required for complete exposure between the sniffing and extension-extension positions (Fig 13). Further, once the patient required lifting for optimal exposure, the force related primarily to the weight of the head and neck (gravity).

Phonomicrosurgery is optimized and facilitated by placing the widest-lumen appropriately shaped laryngoscope between the lips and the glottis. The widest laryngoscope lumen provides the optimal distal surgical field for visualization and tissue retraction, as well as the ability to angulate hand instrumentation. These factors ultimately influence precision.[4,5] It is routine for laryngologists to place a smaller laryngoscope in patients in whom exposure of vocal fold lesion(s) is incomplete. This study documented that more complete exposure is obtained in more patients with the smallest laryngoscope. However, the smaller laryngoscope results in limitations in precise tissue manipulation of the vocal folds' layered microstructure. The data also revealed that improved direct laryngoscopic exposure was obtained in the sniffing position as compared with extension-extension, regardless of the laryngoscope (Fig 12). This reinforced observations by Green,[6] Kirstein,[2] and Jackson,[9] as well as by Vaughan[33] and Zeitels and Vaughan.[5]

Although the flexion-flexion head and neck position is excellent for exposure of the anterior glottis, the associated position of the laryngoscope is not conducive to microlaryngoscopic bimanual surgery (Fig 14). Therefore, the sniffing position is ideal to fit the largest-lumen laryngoscope for phonomicrosurgery. Regardless of the placement of a pillow under the head and neck, fulcrum laryngoscope holders produce exposure of the anterior glottis by exerting force on the maxilla to distract supraglottal and pharyngeal tissues. This has long been noted to be inefficient and potentially leads to oral[1,18,34] and cervical spine trauma[4] if the exposure is difficult.

From the exposure results herein, flexion of both the head and neck (chin to chest) seems to be the ideal position to intubate the patient whose glottis is difficult to observe by means of routine positions. The problematic aspect of this position is that the endoscopist must lean over the patient in a way that can be uncomfortable (Fig 14). However, for the purpose of establishing an airway in an emergency situation or for elective surgery, this discomfort is not significantly burdensome. The flexion-flexion position for intubation is contrary to standard teaching in anesthesia textbooks and is not done typically. This is because the advantages of the flexion-flexion position are seldom recognized and because it can be slightly awkward to lean over the patient. The use of Killian's flexion-flexion position for indirect laryngoscopy[35] is similarly awkward for the examiner (Figs 15[35] and 16[35]). In 1913, Johnson[36] noted that the flexion-flexion position during sitting direct laryngoscopy improved visualization of the anterior glottis when exposure was difficult. We would suggest, moreover, that the flexion-flexion position can be utilized effectively for difficult intubations, either by placing the occiput of the patient on the examiner's lower chest (Fig 14) or by having an assistant support the patient's head as Jackson did.

We believe that the reason that the flexion-flexion position is preferable to the sniffing position in a difficult glottal exposure is that the extension of the head at the atlanto-occipital joint leads to retrodisplacement of the tongue base into the airway, which opposes the anterior distraction forces of the pharyngeal tissues required for exposure of the glottis. This factor became evident in several patients who were retrognathic. We further believe that the concept of the "anterior larynx" is unsound, since it is difficult to imagine how a larynx can be displaced too anteriorly in the neck.[26] Further, the laryngeal cartilaginous framework is less defined under the cervical skin of obese retrognathic patients, who are difficult to intubate. In patients who have normally mobile cervical spines and nonirradiated and nonburned cervical soft tissues, the primary factors that probably influence laryngeal exposure are the length of the oral-pharyngeal-laryngeal cavity; the size, contour, and opening of the mandible; and the size of the tongue.[26,37,38]

The difficulty in intubating and exposing the glottis in retrognathic patients most probably relates to the short distance between the mandibular symphysis, the hyoid bone, and the thyroid cartilage, as well as the mass of the oral and tongue base tissues. The flexion-flexion position allows for more effective anterior distraction of oral and tongue base tissues, because the applied vector force of the laryngoscope is in the direction of the anteriorly displaced mandible and tongue base. In the sniffing position, extension of the atlanto-occipital joint rotates the mandible backward to oppose the anterior distraction forces of the laryngoscope. Killian's work (Fig 16) demonstrated that the flexion-flexion position aligns the pharyngeal cavity well for visualizing the glottis.

Although the aforementioned descriptions provide explanations for the unexpected finding that the flexion-flexion (chin to chest) position provided the optimal exposure of the anterior glottis, this investiga-

tion did not critically analyze patient factors that led to this observation. Along with the character of dentition and jaw opening, the flexibility of the spine and soft tissues of the neck is an important variable for direct laryngoscopic glottal exposure.[26,37,38] Additionally, the inner diameter of the mandible can restrict the placement of a wide-lumened laryngoscope.

This study did not evaluate the effect of external counterpressure[17] on the quality of exposure and the resultant forces created by it. Manual pressure to the lower laryngeal framework is frequently applied during difficult intubations and is utilized routinely during microlaryngeal surgery by some surgeons.[5]

CONCLUSIONS

1. Extension-extension requires the least amount of force to expose the glottis when using smaller laryngoscopes and in easily exposed patients. In these circumstances, distraction of soft tissues is solely required, rather than lifting the weight of the head and neck of the patient off the operating table.

2. Once the head and neck are lifted off the table for exposure, tissue distraction resistance becomes negligible as compared with gravity.

3. The flexion-flexion (chin to chest) position of the head and neck is ideally suited to achieve optimal glottal exposure in the greatest number of patients. Therefore, this position is suggested for the difficult direct laryngoscopic intubation.

4. Most patients can be intubated with the occiput resting on the operating table and without the sniffing or flexion-flexion position, because the pliable soft tissues of the oral cavity and pharynx can be distracted easily.

5. The flexion-flexion (chin to chest) position is not suitable for microlaryngoscopic surgery, because the proximal lumen of the laryngoscope is directed toward the ceiling.

6. A narrow-lumen laryngoscope is advantageous in those patients in whom it is difficult to achieve glottal exposure.

7. Laryngoscope holders provide adequate exposure of the glottal surgical field, because the majority of patients can be visualized by simple distraction of soft tissues and because few surgeons use extremely wide-lumened laryngoscopes.

REFERENCES

1. Kirstein A. Autoskopie des Larynx und der Trachea (Laryngoscopie direkta, Euthyskopie, Besichtigung ohne Spiegel). Arch Laryngol Rhinol 1895;3:156-64.

2. Kirstein A. Autoscopy of the larynx and trachea (direct examination without mirror). Philadelphia, Pa: FA Davis, 1897.

3. Caplan RA, Posner KL, Ward RJ, Cheney FW. Adverse respiratory events in anesthesia: a closed claims analysis. Anesthesiology 1990;72:828-33.

4. Zeitels SM. Premalignant epithelium and microinvasive cancer of the vocal fold: the evolution of phonomicrosurgical management. Laryngoscope 1995;105(suppl 67).

5. Zeitels SM, Vaughan CW. "External counterpressure" and "internal distention" for optimal laryngoscopic exposure of the anterior glottal commissure. Ann Otol Rhinol Laryngol 1994; 103:669-75.

6. Green H. Morbid growths within the larynx. New York, NY: GP Putnam, 1852.

7. Czermak JN. Uber den Kehlkopfspiegel. Wien Med Wochenschr 1858;8:196-8.

8. Killian G. Suspension laryngoscopy. In: Jackson C, ed. Peroral endoscopy and laryngeal surgery. St Louis, Mo: Laryngoscope Co, 1915:133-54.

9. Jackson C. Position of the patient for peroral endoscopy. In: Jackson C, ed. Peroral endoscopy and laryngeal surgery. St Louis, Mo: Laryngoscope Co, 1915:77-88.

10. Grundfast KM, Vaughan CW, Strong MS, de Vos P. Suspension microlaryngoscopy in the Boyce position with a new suspension gallows. Ann Otol Rhinol Laryngol 1978;87:560-6.

11. Boyce JW. Duties of the second assistant in endoscopy per os. In: Jackson C, ed. Tracheobronchoscopy, esophagoscopy and gastroscopy. St Louis, Mo: Laryngoscope Co, 1907:145-7.

12. Jackson C. Direct laryngoscopy by lateral and oblique methods. In: Jackson C, ed. Peroral endoscopy and laryngeal surgery. St Louis, Mo: Laryngoscope Co, 1915:101-3.

13. Zeitels SM. Chevalier Jackson's contributions to direct laryngoscopy. J Voice 1993;12:1-6.

14. Killian G. Die Schwebelaryngoscopie. Arch Laryngol Rhinol 1912;26:277-317.

15. Killian G. Suspension laryngoscopy and its practical use. J Laryngol Otol 1914;24:337-60.

16. Killian G. Die Schwebelaryngoscopie und ihre praktische. Vienna: Verwertung, Urban & Schwarzenberg, 1920.

17. Brunings W. Direct laryngoscopy, bronchoscopy, and esophagoscopy. London: Bailliere, Tindall, & Cox, 1912:110-5.

18. Jackson C, ed. Peroral endoscopy and laryngeal surgery. St Louis, Mo: Laryngoscope Co, 1915.

19. Roberts S, Forman FS. Direct laryngoscopy — a simplified technique. An aid to the early detection of laryngeal cancer. Ann Otol Rhinol Laryngol 1948;57:245-56.

20. Roberts SE. A self retaining dual distal lighted laryngoscope with screw driven fulcrum lift. Laryngoscope 1952;62: 215-21.

21. King NE. Direct laryngoscopy aided by a new laryngoscope "stabilizer." Arch Otolaryngol 1951;53:89-92.

22. Sommers KE. Direct laryngoscopy and description of a self-retaining attachment for the laryngoscope. Arch Otolaryngol 1952;55:484-8.

23. Lewy RE. Suspension fixation gear power laryngoscopy (with motion pictures). Laryngoscope 1954;64:693-5.

24. Thomas J, Olsen KD, Neel HB, DeSanto LW, Suman VJ.

Recurrences after endoscopic management of early (T1) glottic cancer. Laryngoscope 1994;104:1099-104.

25. Elsberg CA. Clinical experiences with intratracheal insufflation (Meltzer), with remarks upon the value of the method for thoracic surgery. Ann Surg 1910;52:23-9.

26. Berry FA. Anesthetic management of difficult and routine pediatric patients. New York, NY: Churchill Livingstone, 1990:167-98.

27. Priest RE, Wesolowski S. Direct laryngoscopy under general anesthesia. Trans Am Acad Ophthalmol Otolaryngol 1960; 64:639-48.

28. Zeitels SM, Vaughan CW. A submucosal vocal fold infusion needle. Otolaryngol Head Neck Surg 1991;105:478-9.

29. Zeitels SM, Hillman RE, Bunting GW, Vaughn T. Reinke's edema: phonatory mechanisms and management strategies. Ann Otol Rhinol Laryngol 1997;106:533-43.

30. Zeitels SM. Phonomicrosurgical treatment of early glottic cancer and carcinoma in situ. Am J Surg 1996;172:704-9.

31. Zeitels SM. Phonomicrosurgical techniques. In: Sataloff R, ed. Professional voice: the science and the art of clinical care. San Diego, Calif: Singular, 1997:647-58.

32. Sataloff R, Spiegel JR, Heuer RJ, et al. Laryngeal mini-microflap: a new technique and reassessment of the microflap saga. J Voice 1995;9:198-204.

33. Vaughan CW. Vocal fold exposure in phonosurgery. J Voice 1993;7:189-94.

34. Jackson C, Jackson CL. Cancer of the larynx. Philadelphia, Pa: WB Saunders, 1939:10-29.

35. Bruck A. Diseases of the nose, mouth, pharynx, and larynx. New York, NY: Rebman, 1910:375-6.

36. Johnson R. Some original endoscopic methods. Laryngoscope 1913;23:607-17.

37. White A, Kander PL. Anatomic factors in difficult direct laryngoscopy. Br J Anaesth 1978;47:468-73.

38. Cormack RS, Lehane J. Difficult tracheal intubation in obstetrics. Anesthesia 1984;39:1105-11.

EUROPEAN SOCIETY OF PEDIATRIC ORL

The Vth International Conference of the European Society of Pediatric ORL will be held July 9-13, 2000, in Graz, Austria. For more information, contact Claire Zwerina, Secretary to Prof Stammberger, ENT-Department, University Hospital, Auenbruggerplatz 20, A-8036 Graz, Austria; fax ++43/316/385/3425.

LARYNGOPHARYNGEAL SENSORY DISCRIMINATION TESTING AND THE LARYNGEAL ADDUCTOR REFLEX

JONATHAN E. AVIV, MD
JOHN H. MARTIN, PHD
TED KIM, MD
RALPH L. SACCO, MD, MS
JEANNE E. THOMSON, MS
BEVERLY DIAMOND, PHD
LANNY G. CLOSE, MD
NEW YORK, NEW YORK

Laryngopharyngeal sensory capacity has been determined by endoscopically administering air pulse stimuli to the mucosa innervated by the superior laryngeal nerve and asking the patient if he or she feels the stimulus. A potential shortcoming of this psychophysical testing (PT) procedure is that it is a subjective test, and patients with impaired cognition may not be able to perform the required task. In the search for an objective measure of laryngeal sensory function, we have observed that the laryngeal adductor reflex (LAR) is evoked at stimulus intensities similar to those capable of eliciting the psychophysical, or perceptual, response. The purpose of this study is to determine if the threshold for eliciting the LAR is the same as that of the sensory threshold. A specially designed endoscope was used to present air pulse stimuli (range 0.0 to 10 mm Hg) to the laryngopharynx in 20 healthy subjects and in 80 patients with dysphagia, using both PT and the LAR. The patients had a variety of underlying diagnoses, with stroke and chronic neurologic disease predominating (n = 65). In the control group and in the group of patients with dysphagia, there was no statistically significant difference between the median laryngopharyngeal sensory thresholds whether we used PT or the LAR ($p > .05$, Wilcoxon signed-rank test). The intraclass correlation for the total sample was .999 (U = .999, L = .998). Since psychophysical and sensorimotor reflex thresholds were not statistically significantly different and the intraclass correlation was close to a perfect correlation, we conclude that the LAR can be used as an objective and accurate clinical method of endoscopically assessing laryngopharyngeal sensory capacity.

KEY WORDS — dysphagia, endoscopy, laryngopharyngeal sensation, swallowing.

INTRODUCTION

In previous work, we determined that the sensory capacity of the laryngopharynx can be determined by endoscopically delivering discrete air pulse stimuli to the mucosa innervated by the internal branch of the superior laryngeal nerve.[1,2] We determined sensory thresholds using psychophysical techniques. We varied the air pulse over a range of pressures and determined the lowest value at which the patient felt the stimulus. A potential shortcoming of this technique is that the patient may misunderstand task directions. Of particular concern is that patients with cognitive or neurologic impairments might not indicate that they felt the stimulus at threshold, but only at some higher value that would lead to nonsystematic bias of this subjective measurement.

Stimulation of the mucosa innervated by the superior laryngeal nerve is well known to elicit the laryngeal adductor reflex (LAR), which is a brief closure of the true vocal folds.[3,4] Electromyographic studies by Ludlow et al[5,6] in humans have demonstrated 2 responses in the thyroarytenoid muscle (R1 and R2) during the LAR. The R1 response is ipsilateral and has an average latency of 18 milliseconds (ms). The R2 response is bilateral and has an average latency of 68 ms. It is felt that the R2 response is what is observed clinically upon stimulation of the internal branch of the superior laryngeal nerve.[5] Since the LAR is an involuntary reflex,[7,8] it does not require conscious control by the patient. In preliminary investigations using air pulse stimulation of the laryngopharyngeal mucosa, we noted that the LAR was typically elicited. The purpose of this study was to determine if the thresholds for detecting the air pulse stimulus perceptually and evoking the LAR reflexively were the same. If so, then the LAR could be used as a more objective measure of the sensory capacity of the laryngopharynx that does not require a conscious, controlled response.

MATERIALS AND METHODS

A specially designed endoscope was used to pre-

From the Department of Otolaryngology–Head and Neck Surgery (Aviv, Kim, Thomson, Close), the Center for Neurobiology and Behavior, Department of Psychiatry (Martin), the Departments of Neurology and Public Health (Epidemiology) in the Sergievsky Center (Sacco), and the Irving Center for Clinical Research (Diamond), The New York Presbyterian Hospital, College of Physicians and Surgeons, Columbia University, New York, New York. This work is supported by National Institutes of Health grant RR 00645, the Florence Irving Professorship, and the New York Presbyterian Hospital Office of Clinical Trials.

Presented at the meeting of the American Broncho-Esophagological Association, Palm Beach, Florida, May 11-12, 1998.

CORRESPONDENCE — Jonathan E. Aviv, MD, Box 21, Dept of Otolaryngology–Head and Neck Surgery, The New York Presbyterian Hospital, 630 W 168th St, New York, NY 10032.

sent air pulse stimuli to the laryngopharynx in 20 healthy subjects and in 80 patients with dysphagia, for both psychophysical testing (PT) and the LAR. The control subjects were 20 healthy individuals selected from outpatient volunteers who were on regular diets and had no history of dysphagia and no history of stroke or chronic neurologic disease. The 80 patients with dysphagia had a variety of underlying diagnoses and conditions, including stroke, chronic neurologic disease (Parkinson's disease, multiple sclerosis), bronchiectasis, pneumonia, dementia, and dysphagia subsequent to open heart surgery and/or prolonged intubation. Stroke and chronic neurologic disease predominated (n = 65). For this analysis we selected patients who could perform the psychophysical test. Dysphagia was defined as any subjective or objective patient complaint of difficulty swallowing solid or liquid food, or the presence of coughing or choking while swallowing. Informed consent was obtained on all subjects in the study.

Stimulus Delivery. The following equipment was used to perform laryngopharyngeal air pulse stimulation: an endoscope, a light source, a sensory stimulator that was attached to the endoscope, a television monitor, a video printer, and a videocassette recorder.[9,10]

To measure the supraglottic and pharyngeal sensory thresholds and the LAR, a pressure- and duration-controlled pulse of air was delivered along the aryepiglottic folds, just anterior to the arytenoids. The air pulse, 50 ms in duration, was varied in intensity from 0 to 10 mm Hg. It was delivered via an internal port located within a flexible fiberoptic telescope made for this purpose (Pentax Precision Instrument Corporation, Orangeburg, NY). The air pulse was obtained from a laryngopharyngeal air pulse sensory stimulator also developed for this purpose (Pentax Precision Instrument Corporation).[1] The flexible laryngoscope was inserted into the nasal passage, and the distal tip of the scope was advanced, under direct vision, until it was approximately 2 mm from the test site. No topical local anesthesia was utilized. The patient was then given a 1-minute rest period to adapt to the laryngoscope and prepare for testing. A masking sound was used to prevent the patient from using auditory cues to determine the presence of a stimulus.

Psychophysical Testing. To obtain sensory thresholds, we used the ascending-descending method of limits while the duration of the air pulse was held constant at 50 ms. Prior to sensory testing, the patient was first provided a detailed description of the apparatus and the psychophysical procedure. Next, air pulse stimuli were delivered to the cheek to demonstrate to the patient the phasic nature of the stimulus and the tapping or touchlike sensation that it evokes. The scope was then inserted as described above. To orient the subject to pharyngeal and laryngeal stimulation, we initially presented a suprathreshold stimulus to the test site in the laryngopharynx, whose duration was 1 second rather than the brief 50-ms stimulus used for testing. This long-duration stimulus was easily detected by all subjects. The stimuli were presented in discrete trials. Each trial lasted for approximately 10 seconds, with a 10-second intertrial interval. The air pulse was administered after a verbal announcement of the beginning of the trial, at a random time from 2 to 8 seconds within the 10-second trial interval. Patients were instructed to raise their hands within 2 seconds of stimulus presentation if they felt the air pulse. Stimulus trials were presented in blocks, during which stimulus intensity either began at a subliminal value and increased by 1 mm Hg with each trial until detection occurred (ascending block) or began at a supraliminal value and decreased by 1–mm Hg steps until no detection occurred (descending block). Three blocks of ascending pressure stimulus presentations and 3 blocks of descending pressure stimulus presentations were randomly ordered for each subject. A 30-second rest period separated the blocks. The mean of the lowest detected pressures from the 6 blocks was used as that subject's sensory threshold.

Two modifications to the ascending-descending method of limits were used to ensure accurate threshold determinations. First, catch trials were introduced in which a stimulus was not presented. This was accomplished by reducing the stimulus intensity to zero but continuing to ask the patient if he or she felt the air pulse. The absence of a patient's response on these trials verified that he or she was responding to the air pulse stimulus and not to an extraneous cue such as the masking sound. Second, stimuli were presented in a single-blind procedure in which the examiner did not have knowledge of the stimulus intensity. This was accomplished by having an associate working with the examiner set the stimulus intensity. In this way, the examiner did not know the starting subliminal stimulus intensity, the intensity of the largest supraliminal stimulus used, or on which trials the stimulus was not presented (catch trials). Moreover, the examiner did not know in advance if the stimulation block consisted of air pulses presented in ascending or descending order. Both the right and left sides of the laryngopharynx were studied in each patient and control.

Laryngeal Adductor Reflex. The fiberoptic telescope was inserted into the nose and, unlike for PT,

TABLE 1. LARYNGOPHARYNGEAL SENSORY DISCRIMINATION TESTING (LPSDT) FORM

Medical Record Number _____ **Date of interview** _____ (mmddyy)

LPSDT

+ = positive response, – = negative response, C = catch trial, LC = laryngeal closure, S = swallow

Data (mm Hg)

Right	**Left**
_____	_____
_____	_____
_____	_____
_____	_____
_____	_____
_____	_____
Threshold _____	Threshold _____

(Normal = <4.0 mm Hg, moderate deficit = 4.0 to 6.0 mm Hg, severe deficit = >6.0 mm Hg)

Laryngopharyngeal sensation

Right _____ Left _____

(0 = normal, 1 = moderate deficit, 2 = severe deficit)

Safety

Airway compromise _____ 0 = no 1 = yes

Epistaxis _____ 0 = no 1 = yes

Patient discomfort _____ 0 = none, 1 = mild, 2 = moderate, 3 = severe

If your physician advised that you repeat this test, would you repeat this test? _____ 0 = no 1 = yes

Reprinted from Aviv et al.[11]

no verbal announcement of the beginning of a testing trial was made. Instead, we gave the previously described 3 blocks of ascending and 3 blocks of descending air pulse stimulus presentations, noting at what stimulation pressure the LAR was elicited. The vocal fold adduction of the LAR was determined by direct visualization of vocal fold movement on a video monitor receiving a real-time image from the fiberoptic telescope. When the reflex is absent, the vocal folds fail to close after stimulation in this region. The type of vocal fold closure taking place in response to air pulse stimulation was a brief, rapid, nonrhythmic, bilateral vocal fold adduction that was clearly distinguishable from the rhythmic bilateral vocal fold movement seen during normal respiration.[3,5] The mean of the lowest pressures from the 6 blocks that elicited brief laryngeal adduction was recorded as that subject's LAR threshold. The entire sensory testing examination was recorded on videotape and on a sensory testing form (Table 1[11]).

The safety of sensory testing with the LAR was assessed by noting the presence or absence of airway compromise and epistaxis. In addition, patients were asked to rate the level of discomfort of the procedure on a scale ranging from none to mild to moderate to severe discomfort. The safety information was recorded on the aforementioned sensory testing form (Table 1).

Statistical Analysis. Within each group (healthy controls and patients with dysphagia), the Wilcoxon signed-rank test was used to assess differences in sensory thresholds between the PT and the LAR. In addition, a cross-comparison between PT and LAR for each patient was tabulated.

Intraclass correlations (ICCs) were run in order to directly compare the thresholds elicited by PT and LAR. The ICCs were computed for the total sample and for each deficit level. The range of ICCs is from 0 to 1, with 1 being a perfect correlation.[12]

RESULTS

The 20 control subjects were 12 men and 8 women with a mean age of 47 ± 20 years. For PT the median sensory threshold was 2.84 ± 0.64 mm Hg. The median threshold for eliciting the LAR in the control group was 2.97 ± 0.78 mm Hg. The PT and LAR thresholds were not significantly different ($p > .05$, Wilcoxon signed-rank test). The ability to elicit the LAR did not differ when stimulation was at any location along the aryepiglottic folds.

In the control group, 100% of healthy controls responded to air pulse stimulation of either side of the laryngopharynx (either feeling the air pulse or having elicitation of the LAR) at air pulses less than 4.0 mm Hg air pulse pressure. The patients with dysphagia, if they responded at all to the air pulse stimulus, did so at stimulus intensities greater than 4.0 mm Hg air pulse pressure, which is a statistically significantly higher threshold. As in previous studies, laryngopharyngeal sensory discrimination thresholds in

TABLE 2. MEDIAN SENSORY THRESHOLDS IN PATIENTS WITH DYSPHAGIA

Laryngopharyngeal Sensation (n = 72)	*Psychophysical Threshold (mm Hg)*	*Laryngeal Adductor Reflex (mm Hg)*
Bilateral normal (n = 12)	3.27 ± 0.67	3.44 ± 0.86 (p > .05)
Bilateral severe (n = 30)	10.40 ± 2.31	10.60 ± 2.44 (p > .05)
Unilateral severe (n = 20)	10.10 ± 2.22	10.30 ± 2.56 (p > .05)
Bilateral moderate (n = 4)	5.40 ± 1.54	5.82 ± 1.68 (p > .05)
Unilateral moderate (n = 6)	5.48 ± 1.77	5.61 ± 1.87 (p > .05)

Data are mean ± SD. Data for unilateral deficits are from affected side. Contralateral-side data are normal and are not presented. Eight patients with severe deficits in whom sensory threshold could not be obtained are not included in this analysis.

this study were defined as either normal (<4.0 mm Hg air pulse pressure), moderately impaired (4.0 to 6.0 mm Hg air pulse pressure), or severely impaired (>6.0 mm Hg air pulse pressure).[9]

As air pulse pressures were increased to suprathreshold levels in the control group, it was consistently noted that suprathreshold stimulation of the laryngopharynx, in addition to eliciting the LAR, also elicited a cough and a swallow.

The dysphagic group consisted of 48 men and 32 women with a mean age of 67 ± 16 years. The sensory testing results of the 80 patients with dysphagia were divided into 5 groups: bilateral normal, bilateral severe, unilateral severe, bilateral moderate, and unilateral moderate (Table 2). In comparing thresholds for each group, there was no statistically significant difference between the median sensory thresholds for PT versus LAR (p > .05, Wilcoxon signed-rank test). In patients with unilateral deficits, the normal-side sensory thresholds were not significantly different from those of the control group (p > .05, Wilcoxon signed-rank test). Whether patients showed unilateral or bilateral deficits on PT, the pattern of the LAR was the same. Furthermore, as in the control group, suprathreshold stimulation on the normal or moderately deficient sides resulted in a cough and a swallow. None of the patients tested had a vocal fold paralysis.

The ICC for the total sample was .999 (upper confidence limit [U] = .999, lower confidence limit [L] = .998). The ICCs for each of the 5 groups were .992 (U = .995, L = .938) for bilateral normal, .998 (U = .998, L = .965) for bilateral severe, .982 (U = .999, L = .760) for unilateral severe, .990 (U = .995, L = .979) for bilateral moderate, and .982 (U = .997, L = .878) for unilateral moderate.

TABLE 3. CROSS-TABULATION OF NUMBER OF DYSPHAGIC PATIENTS WITH SENSORY DEFICITS SHOWN ON EITHER PSYCHOPHYSICAL TESTING OR LAR TESTING (N = 80)

	Psychophysical Testing		
LAR Test Result	*<4.0 (Normal)*	*4.0-6.0 (Moderate Deficit)*	*>6.0 (Severe Deficit)*
<4.0 (Normal)	12	0	0
4.0-6.0 (Moderate deficit)	0	10	0
>6.0 (Severe deficit)	0	0	58

"Moderate" and "severe" deficits refer to either unilateral or bilateral sensory deficit; 4.0, 6.0, etc are air pulse pressure in millimeters of mercury.

LAR — laryngeal adductor reflex.

A cross-comparison between PT and LAR for each dysphagic patient revealed 100% concordance between PT and LAR (Table 3).

There were no instances of airway compromise or epistaxis. All controls and patients said that they would have the test again if their physician advised them to do so. The level of discomfort of the procedure was rated by the control group as follows: 2 (10%) rated no discomfort, 12 (60%) rated mild discomfort, 4 (20%) rated moderate discomfort, and 2 (10%) rated severe discomfort. In the patient group, 3 (3.8%) patients rated no discomfort, 64 (80%) rated mild discomfort, 12 (15%) rated moderate discomfort, and 1 (1.2%) rated severe discomfort.

There was a subgroup of 8 patients with bilateral severe sensory deficits who did not react with either PT or LAR at the maximum deliverable air pulse pressure of 12 mm Hg. Because an actual sensory threshold could not be obtained on this group of patients, they are not included in the overall analysis between PT and LAR for dysphagic patients.

DISCUSSION

To devise a form of laryngopharyngeal sensory discrimination testing that is more objective than PT alone, we have implemented a method that takes advantage of the LAR, thereby eliminating the need for a conscious and informed response by the patient. With this modification, it is now possible to test patients with a variety of cognitive deficits, thus potentially widely increasing the number of test subjects who could participate in, and benefit from, sensory testing. The new modification of the testing procedure uses the same air pulse stimuli as has been described; however, in this modification, air pulse stimulation of the mucosa innervated by the superior laryngeal nerve is used to elicit the LAR.

Sensory testing of the laryngopharyngeal mucosa was developed to obtain objective and reproducible

clinical information regarding the role of afferent information important for organizing the swallow. The 2 basic techniques that have been in widespread use to assess swallowing — modified barium swallow study and endoscopic evaluation of swallowing — while outstanding and comprehensive tests, do not directly assess sensory capacity in the laryngopharynx. Unrecognized, or insufficiently recognized, sensory deficits in the laryngopharynx can lead to dysphagia and aspiration. Studies have shown that if one cannot sense food and secretions in the laryngopharynx, normal laryngopharyngeal airway protective reflexes will not be properly initiated.[13,14] This can result in secretions and debris descending not only into the esophagus but also into the tracheobronchial tree. The importance of sensory assessment of the laryngopharynx in patients with dysphagia was previously addressed by Kidd et al,[15] who demonstrated that the presence of laryngopharyngeal sensory deficits, along with severity of stroke, is statistically significantly related to the development of aspiration pneumonia after stroke. Kidd et al assessed laryngopharyngeal sensation with the tip of a long stick applied once to each side of the hypopharynx. Patients were asked to compare the 2 stimuli, and the presence or absence of sensation was noted. Kidd et al were not assessing the gag reflex; they placed the stick into the hypopharynx, an area innervated by the 10th nerve. A shortcoming of the long stick technique is that it is a relatively crude and difficult-to-reproduce method of sensory assessment.

As greater experience and expertise with endoscopic swallowing evaluations have been obtained, recent work has demonstrated that endoscopy can give the clinician information comparable to that provided by the modified barium swallow study.[16,17] The combination of laryngopharyngeal sensory testing with endoscopic swallowing evaluations, which has been termed flexible endoscopic evaluation of swallowing with sensory testing (FEESST), provides a comprehensive bedside motor and sensory assessment of swallowing.[11,18] A prospective study comparing modified barium swallow study and laryngopharyngeal sensory discrimination testing as predictors of aspiration pneumonia risk in stroke patients with dysphagia found that sensory testing, when used in conjunction with a modified barium swallow study, decreased the false-negative rate of the modified barium swallow study in predicting aspiration pneumonia from 40% (when used alone) to 0%.[19]

The implication of the results of this study is that an involuntary reflex, the LAR, can be used to assess laryngopharyngeal sensory capacity in patients with cognitive impairment who are unable or unwilling to respond to psychophysical stimuli.

CONCLUSION

We have demonstrated that assessment of the LAR by air pulse stimulation of the laryngopharyngeal mucosa can be used to assess sensory capacity in the laryngopharynx. It is hoped that this technique can eventually be applied to more precisely guide the dietary and behavioral management of patients with dysphagia in the acute and postacute settings.

REFERENCES

1. Aviv JE, Martin JH, Keen MS, Debell M, Blitzer A. Air pulse quantification of supraglottic and pharyngeal sensation: a new technique. Ann Otol Rhinol Laryngol 1993;102:777-80.

2. Aviv JE, Martin JH, Jones ME, et al. Age-related changes in pharyngeal and supraglottic sensation. Ann Otol Rhinol Laryngol 1994;103:749-52.

3. Murakami Y, Kirchner JA. Mechanical and physiological properties of reflex laryngeal closure. Ann Otol Rhinol Laryngol 1972;81:59-71.

4. Boushey HA. The response of laryngeal afferent fibers to mechanical and chemical stimuli. J Physiol (Lond) 1974;240: 153-75.

5. Ludlow CL, Van Pelt F, Koda J. Characteristics of late responses to superior laryngeal nerve stimulation in humans. Ann Otol Rhinol Laryngol 1992;101:127-34.

6. Ludlow CL, Schulz GM, Yamashita T, Deleyiannis FW-B. Abnormalities in long latency responses to superior laryngeal nerve stimulation in adductor spasmodic dysphonia. Ann Otol Rhinol Laryngol 1995;104:928-35.

7. Korpas J, Tomori Z. Cough and other respiratory reflexes. In: Herzog H, ed. Progress in respiration research. Vol 12. Basel, Switzerland: S Karger, 1979:251-63.

8. Wyke B. Effects of anesthesia upon intrinsic laryngeal reflexes: an experimental study. J Laryngol Otol 1968;82:603-12.

9. Aviv JE, Martin JH, Sacco RL, et al. Supraglottic and pharyngeal sensory abnormalities in stroke patients with dysphagia. Ann Otol Rhinol Laryngol 1996;105:92-7.

10. Aviv JE, Sacco RL, Thomson J, et al. Silent laryngopharyngeal sensory deficits after stroke. Ann Otol Rhinol Laryngol 1997;106:87-93.

11. Aviv JE, Kim T, Sacco RL, et al. FEESST: a new bedside endoscopic test of the motor and sensory components of swallowing. Ann Otol Rhinol Laryngol 1998;107:378-87.

12. Shrout P, Fleiss J. Intraclass correlations: uses in assessing rater reliability. Psychol Bull 1979;86:420-8.

13. Linden P, Siebens A. Dysphagia: predicting laryngeal penetration. Arch Phys Med Rehabil 1983;64:281-3.

14. Logemann J, Bytell D. Swallowing disorders in three types of head and neck surgical patients. Cancer 1979;44:1095-105.

15. Kidd D, Lawson J, MacMahon J. Aspiration in acute stroke: a clinical study with videofluoroscopy. Q J Med 1993;86: 825-9.

16. Wu C-H, Hsiao T-Y, Chen J-C, Chang Y-C, Lee S-Y. Evaluation of swallowing safety with fiberoptic endoscope: comparison with videofluoroscopic technique. Laryngoscope 1997;107:396-401.

17. Kidder TM, Langmore SE, Martin BJW. Indications and techniques of endoscopy in evaluation of cervical dysphagia: comparison with radiographic techniques. Dysphagia 1994;9: 256-61.

18. Aviv JE, Kim T, Thomson JE, Sunshine S, Kaplan S, Close LG. Fiberoptic endoscopic evaluation of swallowing with sensory testing (FEESST) in healthy controls. Dysphagia 1998; 13:87-92.

19. Aviv JE, Sacco RL, Mohr JP, et al. Laryngopharyngeal sensory testing with modified barium swallow as predictors of aspiration pneumonia after stroke. Laryngoscope 1997;107: 1254-60.

≈

MIDDLE EAR MECHANICS

The Second International Symposium on Middle Ear Mechanics in Research and Otosurgery will be held October 21-24, 1999, in Boston, Massachusetts. For information, contact Harvard MED-CME, PO Box 825, Boston, MA 02117; telephone (617) 432-1525; web site http://www.med.harvard.edu/conted/.

SEVERE PHARYNGEAL STENOSIS TREATED WITH INFERIORLY BASED STERNOCLEIDOMASTOID MYOCUTANEOUS FLAP

JEFFREY R. HALLER, MD STEVEN D. GRAY, MD

SALT LAKE CITY, UTAH

Severe pharyngeal stenosis is a debilitating condition associated with apnea and dysphagia. Treatment options include local flaps and free mucosal grafts. We present 2 cases of severe stenosis, apparently from adenotonsillectomy, that failed more conservative repairs. Both were treated successfully with a sternocleidomastoid myocutaneous flap rotated in through a lateral pharyngotomy. No further treatment has been required. Technical considerations and operative planning are discussed.

KEY WORDS — pharyngeal stenosis, sternocleidomastoid flap.

INTRODUCTION

Pharyngeal stenosis is a circumferential contracture of the pharynx decreasing the normal communication from the nose and oral cavity to the trachea and esophagus, respectively. Acquired pharyngeal stenosis is uncommon. In current times it is most often a complication of surgical trauma.[1] Prior to antibiotics, the majority of reported cases of pharyngeal stenosis were related to infection. While syphilis was the cause in the majority of the infected cases, rhinoscleroma, lupus, diphtheria, and tuberculosis have all been reported.[2] Other reported causes of pharyngeal stenosis include acid burns and external trauma.[3] Surgical causes of pharyngeal stenosis can involve adenotonsillectomy, uvulopalatopharyngoplasty, and corrections of velopharyngeal insufficiencies. Likely factors leading to stenosis include excessive destruction of mucosa, either with aggressive removal of tissue or by cauterization. Keloid or hypertrophic scar formation can additionally play a role.[4,5]

Acquired pharyngeal stenosis secondary to surgical trauma generally will involve the nasopharynx and the oropharynx. A typical view may include the fusion of the soft palate and the anterior tonsillar pillars to the posterior pharyngeal wall. The uvula often appears plastered to the posterior pharyngeal wall. Scarring and the formation of adhesions of the anterior tonsillar pillar down to the base of the tongue can significantly narrow the oropharyngeal aperture. The obstruction may vary from a thin membrane to a thick circumferential scar.[6]

The most prominent symptom of pharyngeal stenosis is nasal obstruction, usually associated with anterior nasal discharge.[7] Additional symptoms include absent nasal speech resonance, rhinorrhea, dysphagia, and obstructive sleep apnea. As the oropharynx becomes more involved, both breathing and swallowing may be significantly disrupted. This is often difficult to treat. Simple dilation has been reported as successful in selected cases, but is only useful in the mildest deformities.[7] Division of the scar and rotation of local mucosal flaps has been described. McDonald et al[8] describe a unilateral palatal flap. Cotton[1] reports successfully employing a laterally based flap consisting of most of the posterior pharyngeal wall. McLaughlin et al[6] report successful intervention through a variety of techniques, including steroid injections, lysis of adhesions, and rotational and advancement mucosal flaps. In a severe case refractory to more conservative methods of treatment, they report placing a jejunal free flap. They emphasized the importance of individualizing the repair or treatment on the basis of the defects. Depending on the severity of the stenosis, more radical reconstruction methods may be necessary.

MATERIALS AND METHODS

Two patients were found to have severe pharyngeal stenosis at Primary Children's Medical Center and the University of Utah. The patients' ages at the time of presentation were 5 years old and 62 years old. Both patients had experienced a previous adenotonsillectomy. Follow-up for the child is 2 years and for the adult is 11 months.

Case 1. A 5-year-old boy underwent an adenotonsillectomy in 1995. Following his tonsillectomy he

From the Division of Otolaryngology–Head and Neck Surgery, University of Utah School of Medicine, Primary Children's Medical Center, Salt Lake City, Utah.

Presented at the meeting of the American Broncho-Esophagological Association, Palm Beach, Florida, May 11-12, 1998.

CORRESPONDENCE — Jeffrey R. Haller, MD, Dept of Otolaryngology–Head and Neck Surgery, University of Utah School of Medicine, Room 3C120, Salt Lake City, UT 84132.

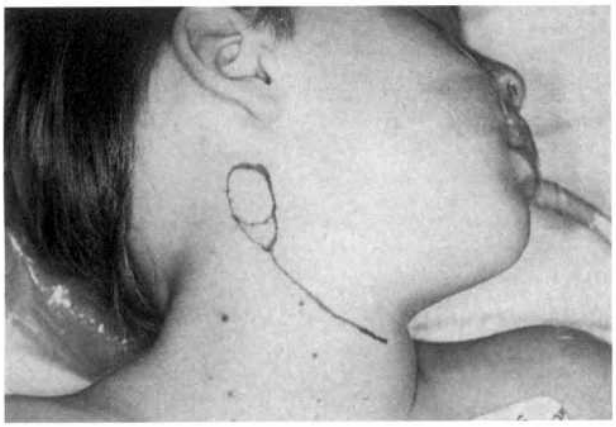

Fig 1. (Case 1) Inferiorly based sternocleidomastoid flap is designed with skin paddle lying over superior portion of muscle.

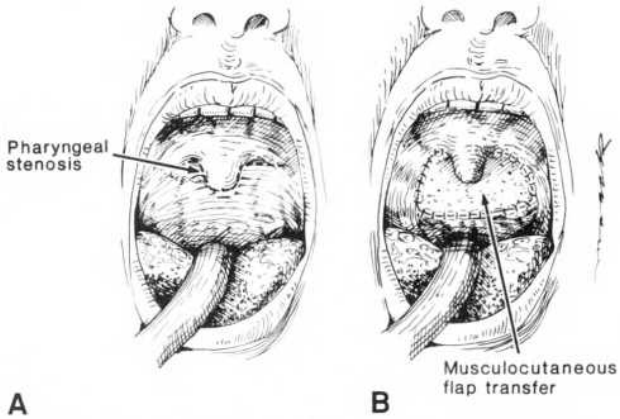

Fig 2. Surgical technique. A) Severe pharyngeal stenosis with dotted line depicting superior incision where scar was released. B) Myocutaneous transfer of sternocleidomastoid flap through lateral pharyngotomy into posterior and lateral pharyngeal walls after release of scar.

developed progressively severe dysphagia, and pharyngeal stenosis at the level of the inferior poles of the tonsillar fossa was diagnosed. His dysphagia progressed until he was only taking liquids and was losing weight. He had severe velopharyngeal incompetence because his soft palate was scarred inferiorly and could not retract. He had a nasometer score of 60 (normal being 18 to 25). He also had dyspnea on exertion and heroic snoring while sleeping. He underwent dilation and injection to the scar with steroids on 2 occasions. He underwent pharyngoplasty with a scar release and rotation of mucosal flaps. All treatments were unsuccessful in relieving his pharyngeal stenosis. In an attempt to bring in outside tissue, an inferiorly based sternocleidomastoid myocutaneous flap was elevated from his right neck (Fig 1). This was tunneled through his lateral pharyngeal wall into his oropharynx. His pharyngeal scar was released on the right and posteriorly. The flap was interposed posteriorly where the scar had been removed and the tissue released. It was sewn across the entirety of the posterior pharyngeal wall (Fig 2). The scar was also released from the soft palate. The flap remained viable with no loss of skin. The child noticed a significant improvement in his swallowing. He is able to maintain his weight and eat a regular diet. He had no further airway obstruction with exertion, and his velopharyngeal speech was completely corrected. The child's nasometer score was returned to normal. Additionally, his parents report that he no longer snores and has no symptoms suggestive of sleep apnea. Two years after his procedure, he continues to do well (Fig 3).

Case 2. A 62-year-old man was referred from the sleep disorders clinic. He had undergone an adenotonsillectomy as a small child more than 50 years earlier. He had developed a severe pharyngeal stenosis at the level of the soft palate and was unable to breathe through his nose. Approximately 15 years earlier, a surgeon placed a tube through his nasopharynx and forced an opening that remained. It measured approximately 3 mm in diameter. The patient otherwise had a complete scarring of his soft palate to his posterior and lateral pharyngeal walls. He un-

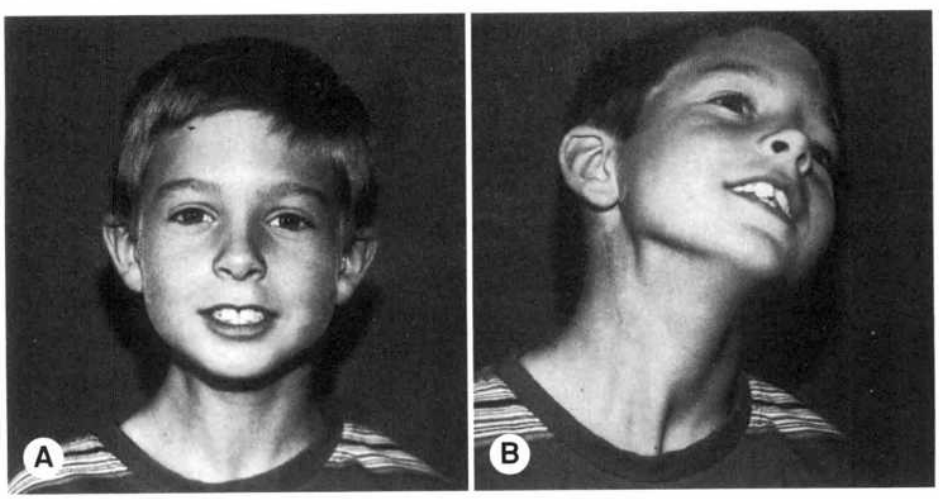

Fig 3. (Case 1) A,B) Two years after rotation of sternocleidomastoid myocutaneous flap. Patient shows no functional neck changes and minimal cosmetic changes.

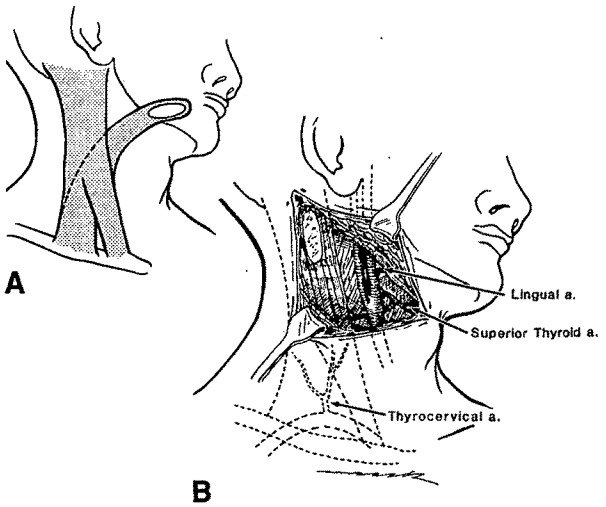

Fig 4. A) When using inferiorly based sternocleidomastoid myocutaneous flap, skin paddle is placed over superior portion of muscle. B) Blood supply to flap comes from thyrocervical trunk and branches off either superior thyroid or inferior thyroid artery.

derwent polysomnography and was noted to have moderately severe sleep apnea. He attempted use of continuous positive airway pressure (CPAP), but had significant difficulties secondary to his pharyngeal stenosis. He was referred for possible surgical correction. Initially, he underwent a pharyngoplasty with a laterally based, posterior pharyngeal wall advancement and rotational flap reconstruction. There was such extensive scarring of this area that surgery was technically difficult. The scar was released and the flap was rotated into place. Within a 3-month period, he completely scarred again and was unable to tolerate his CPAP. A right inferiorly based sternocleidomastoid myocutaneous flap elevation was performed. The flap was tunneled through the right lateral wall. The scar was completely excised on the right. The flap was sewn into place along the posterior and lateral pharyngeal walls. There was a 50% loss of skin from the flap; however, the muscle remained viable and healed nicely into place. The patient has maintained a nasopharyngeal opening and is tolerating his CPAP well. His sleep apnea is controlled with CPAP. This patient is 11 months postsurgery and continues to do well.

SURGICAL TECHNIQUE

The sternocleidomastoid muscle is outlined externally on the neck skin. A cutaneous skin paddle is designed to reconstruct the desired defect. It is located over the superior portion of the sternocleidomastoid muscle (Fig 4). An incision is designed incorporating the skin paddle and following relaxed skin tension lines. Subplatysmal flaps are elevated superiorly and inferiorly. The sternocleidomastoid muscle is skeletonized circumferentially. The spinal accessory nerve is identified and preserved. Care is taken to protect the blood supply to the middle and inferior portions of the flap. The majority of the blood supply comes from inferiorly, from the thyrocervical trunk. A second branch comes off the superior thyroid artery. Once the flap is elevated, a tunnel is then created by dissecting to the lateral pharyngeal wall. Once the lateral pharyngeal wall is reached, a pharyngotomy is used for exposure and to deliver the flap into the desired area of the pharynx. The scars have been released transorally, and a specific bed for the flap has been created. The flap is then sewn into place by incorporating sutures both through the skin and muscle. The skin is then closed externally, and very little defect is noted in the normal neck contour.

DISCUSSION

Several papers have been written describing the anatomy, causes, and symptoms associated with pharyngeal stenosis. A variety of methods for reconstruction have been described, including local, rotational, and advancement flaps from the pharyngeal walls and palate. MacKenty[9] in 1927 described a procedure with a superiorly based mucosal flap from the oral surface of the soft palate. The flap was then doubled over so that the mucosa of the flaps faced the posterior pharyngeal and nasopharyngeal walls.[10] A second group reported a series of 16 cases with a similar method of reconstruction. Others have gone further for their local tissue and recruited tissue from the retromolar trigone. The retromolar trigone was then covered with buccal advancement flaps.[11]

For thin, shelflike obstructions, Woolf and Broadbent[2] were able to use a Z-plasty to correct the obstruction. More recently, Cotton[1] reported a series of 7 children, all with pharyngeal stenosis, in whom he was able to use a laterally based posterior pharyngeal flap. The original plan with his procedure was to perform a 2-stage repair involving flaps from both sides. Only 1 patient required a 2-part reconstruction. The first free flap reported for repair of pharyngeal stenosis was in 1993. A radial forearm free flap was inserted posteriorly to cover a denuded surface in a patient who had undergone multiple local attempts at reconstruction.[12] Most recently, McLaughlin et al[6] reported 8 cases with various degrees of pharyngeal stenosis and associated symptoms. They performed a variety of reconstructions based on the severity of the obstruction. These included Z-plasty, laterally based mucosal flaps, simple incision, injection with steroids, and a jejunal free flap. Treatment was reported to be successful in all of their patients.

In our 2 patients, attempts had been made at simple

local reconstruction. It was clearly evident in both patients that further reconstruction with local tissue was impossible. Considerations for reconstruction included lateral arm and radial forearm free flaps and regional myocutaneous or fasciocutaneous flaps. We elected to use the sternocleidomastoid flap because of its proximity to the reconstruction and our ability to leave the muscle generally in place, giving good cosmesis for the neck.

The sternocleidomastoid myocutaneous flap has been widely studied as both a superiorly and inferiorly based flap. The dominant blood supply to the sternocleidomastoid muscle comes off the occipital artery, favoring the superiorly based flap. Minor blood supply includes branches from the superior thyroid artery and the thyrocervical trunk. Although the superior-based flap has the dominant blood supply, the skin of the inferior portion of the sternocleidomastoid muscle is more reliable, since the vascular perforators do not have to pass through the platysma muscle in the upper one third of the neck, as they do in the lower two thirds. This may favor the inferiorly based flap when a cutaneous paddle is warranted. With either, saving the branches from the superior thyroid artery and vein adds to the reliability of this flap.[13]

The maximum surface area of a sternocleidomastoid myocutaneous flap depends on the size of the muscle and how far from the donor site the muscle is to be transferred. The entire muscle and skin overlying the muscle can be incorporated in the flap. However, the blood supply must be maintained, and the arc of rotation is limited by the ability to free the vascular supply. The flap has been shown to be useful for regional reconstruction including the upper aerodigestive tract, the lower lip, and the parotid bed.[14-16] It has also been used for facial reanimation by preserving the spinal accessory neural branches to the sternocleidomastoid muscle. With either the superior-based or inferior-based flap, saving the branches from the superior thyroid artery and vein is important. Even when maintaining these, in our experience we found no difficulties in rotating an inferiorly based flap into the oropharynx and nasopharynx.

Criticism of the flap includes the safety of preserving the muscle on oncological grounds. This pertains to malignancies of the upper aerodigestive tract and preserving the muscle when there are regional lymphatic metastases. The flap has also been criticized for its unreliable skin paddle and contour deformity in the neck following flap transfer.[17] In 1 of our patients we had partial skin loss, but the flap quickly mucosalized and the healing in the muscle prevented a fistula. The inferiorly based flap in our patients caused minimal changes in the contour of their necks.

The sternocleidomastoid myocutaneous flap can be a reliable flap in nonirradiated patients when the blood supply is carefully preserved. In both our cases the treatment was successful and there was no donor site morbidity. We therefore advocate the inferiorly based sternocleidomastoid muscle for its potential role in reconstruction of the most severe pharyngeal stenosis cases.

REFERENCES

1. Cotton RT. Nasopharyngeal stenosis. Arch Otolaryngol 1985;111:146-8.

2. Woolf RM, Broadbent TR. Nasopharyngeal stenosis following tonsillectomy and adenoidectomy. Plast Reconstr Surg 1970;45:352-5.

3. Lehmann WB, Pope TH, Hudson WR. Nasopharyngeal stenosis. Laryngoscope 1968;78:371-85.

4. Bennhoff DF. Current management of nasopharyngeal stenosis: indications for Z-plasty. Laryngoscope 1979;89:1585-92.

5. Guggenheim P. Cicatricial stenosis of the nasopharyngeal isthmus. Arch Otolaryngol 1963;77:13-8.

6. McLaughlin KE, Jacobs IN, Todd NW, Gussack GS, Carlson G. Management of nasopharyngeal and oropharyngeal stenosis in children. Laryngoscope 1997;107:1322-31.

7. Pratt LW. Acquired nasopharyngeal stenosis. Laryngoscope 1974;84:707-13.

8. McDonald T, Devine K, Hayles A. Nasopharyngeal stenosis following tonsillectomy and adenoidectomy. Arch Otolaryngol 1973;98:38-41.

9. MacKenty JE. Nasopharyngeal atresia. Arch Otolaryngol 1927;6:1-27.

10. Kazanjian VH, Holmes EM. Stenosis of the nasopharynx and its correction. Arch Otolaryngol 1946;44:261-73.

11. Kazanjian VH. Stenosis of the oropharynx. J Oral Surg 1945;3:164-9.

12. Stepnick DW. Management of total nasopharyngeal stenosis following UPPP. Ear Throat Nose J 1993;72:86-90.

13. Urken ML, Biller HF. Atlas of regional and free flaps for head and neck reconstruction. New York, NY: Raven Press, 1996:49-64.

14. Ariyan S. One stage reconstruction for defects of the mouth using a sternomastoid myocutaneous flap. Plast Reconstr Surg 1979;63:618-25.

15. Bugis S, Young J, Archibald SD. Sternocleidomastoid flap following parotidectomy. Head Neck 1990;12:430-5.

16. O'Brien B. A muscle-skin pedicle for total reconstruction of the lower lip: case report. Plast Reconstr Surg 1970;45:395-9.

17. Larson DL, Goepfert H. Limitations of the sternocleidomastoid musculocutaneous flap in head and neck cancer reconstruction. Plast Reconstr Surg 1982;70:328-35.

PREVENTION OF AIRWAY COMPLICATIONS IN THYROPLASTY PATIENTS REQUIRING ENDOTRACHEAL INTUBATION

PAUL FRIEDLANDER, MD
NEW ORLEANS, LOUISIANA

ERDINE AYGENE, MD
NEW YORK, NEW YORK

DENNIS H. KRAUS, MD
NEW YORK, NEW YORK

Patients who have undergone silicone vocal cord medialization and require additional surgery are at risk for airway complications. There is a narrowed glottic aperture that may be prone to develop postoperative laryngeal edema and prosthesis extrusion. This study was designed to assess the management of this difficult airway and to determine the frequency of postintubation complications. We identified 82 patients who had undergone vocal cord medialization with silicone implants between 1991 and 1995. Seventeen of these patients underwent additional surgical procedures requiring general anesthesia. A retrospective review of these patients' charts was performed to determine the management of the airway and the incidence of postintubation complications. There were no postintubation complications in the 17 patients who were studied. The duration of surgery ranged from 40 minutes to 4 hours 15 minutes. Two patients were ventilated via bronchoscope, and 15 patients were intubated orally. The endotracheal tubes ranged from size 6 to size 9 (median size 8). None of the patients required perioperative steroids. All patients were successfully extubated in the recovery room. No patients required intubation or tracheotomy, and there were no implant extrusions. In this study, the incidence of postintubation airway complications in patients who had undergone previous thyroplasty was minimal. Nevertheless, the potential for airway compromise exists. We recommend preoperative discussion with the anesthesiologist, atraumatic intubation with a small endotracheal tube, and diligent observation for airway compromise.

KEY WORDS — airway complications, endotracheal intubation, medialization, silicone, thyroplasty.

INTRODUCTION

Patients with intrathoracic malignancies are at risk for unilateral vocal cord paralysis as a consequence of involvement of the vagus or recurrent laryngeal nerve in its intrathoracic course or resection of the nerve as part of surgical management of their disease. Patients with lung or esophageal cancer, or metastatic disease to the lung or mediastinum, are especially prone to develop this condition. These patients may suffer from hoarseness, dysphagia, chronic aspiration, ineffective cough, and impaired respiration. Type I thyroplasty in the form of silicone medialization and/or arytenoid adduction assists in obviating these symptoms. In our institution this procedure is performed under local anesthesia and is instrumental in improving voice and swallowing and providing an effective cough. Immediate benefit may be seen in terms of pulmonary toilet and ultimately results in improvement in patients' quality of life.

Unfortunately, a large proportion of these patients may develop recurrence of their cancer or conditions requiring additional surgery. Patients who have undergone medialization procedures are theoretically at an increased risk for airway complications secondary to endotracheal intubation. They have a narrowed glottic aperture that places them at risk for the development of laryngeal edema. Traumatic intubation could be associated with prosthesis extrusion. Currently, there are no data in the literature addressing the issue of airway management in patients undergoing intubation who have undergone previous medialization procedures. We have performed a retrospective study to assess the incidence of airway and postanesthesia complications in patients requiring intubation who have undergone type I thyroplasty.

MATERIALS AND METHODS

At the Memorial Sloan-Kettering Cancer Center, 82 patients with preexisting neoplastic conditions underwent vocal cord medialization with or without arytenoid adduction between 1991 and 1995. Seventeen patients (21%) were identified who underwent subsequent surgical procedures requiring general anesthesia. A retrospective chart review was performed to determine management of the airway at the time of surgery and the incidence of postintubation complications. Factors that were evaluated included the type of surgery, duration of intubation, size of endotracheal tube (including the use of double lumen tubes for intrathoracic surgery), and use of perioperative steroids to prevent laryngeal edema. We specifically addressed the incidence of airway insufficiency ne-

From the Head and Neck Service, Department of Surgery, Memorial Sloan-Kettering Cancer Center, New York, New York. Dr Friedlander is currently in the Department of Otolaryngology and Biocommunication, Louisiana State University Medical Center, New Orleans, Louisiana.

Presented at the meeting of the American Broncho-Esophagological Association, Palm Beach, Florida, May 11-12, 1998.

CORRESPONDENCE — Dennis H. Kraus, MD, Memorial Sloan-Kettering Cancer Center, Box 285, 1275 York Ave, New York, NY 10021.

CHARACTERISTICS OF PATIENTS WHO UNDERWENT INTUBATION AFTER SILICONE MEDIALIZATION PROCEDURE

Pt No.	*Date of Medialization*	*Date of Second Surgery*	*Type of Second Surgery*	*Size of Tube*	*Length of Surgery (min)*
1	Jul 15, 1993	Aug 17, 1998	Bronchoscopy	8	45
2	Aug 16, 1994	Aug 8, 1996	Bronchoscopy	N/A	60
3	Feb 16, 1995	Feb 22, 1995	Bronchoscopy	8	120
4	Apr 1, 1992	Apr 19, 1992	Bronchoscopy	N/A	60
5	Oct 8, 1992	May 17, 1996	Closure of abdominal wound	8	150
6	Aug 3, 1993	Jan 26, 1994	Cricopharyngeal myotomy	8	90
7	Jan 25, 1995	Jul 18, 1996	Lumbar spine fusion	7	180
8	Jun 10, 1993	Oct 19, 1995	Lung lobectomy	8	130
9	Mar 12, 1992	Jun 17, 1993	Neck dissection	7	180
10	Jul 6, 1994	Jul 19, 1995	Neck dissection	6	165
11	Oct 14, 1993	May 2, 1996	Endoscopy	8	85
12	Apr 16, 1996	Apr 24, 1996	Small bowel resection	6	120
13	Apr 21, 1993	May 24, 1993	Esophagoscopy and removal of foreign body	6	135
14	Jan 26, 1995	Sep 1, 1995	Thyroidectomy	6	150
15	Apr 21, 1994	Jun 3, 1994	Wide local excision of flank tumor	8	40
16*	Nov 15, 1995	Feb 13, 1997	Bronchoscopy	9	185
17*	Nov 8, 1995	Dec 26, 1995	Open reduction with internal fixation of femur	8	255

N/A — not applicable (bronchoscope).
*Also had arytenoid adduction.

cessitating reintubation or performance of tracheostomy or causing implant extrusion or impairment of voice, swallowing, or respiration postoperatively.

RESULTS

Seventeen patients (21%) were identified who required additional surgical procedures after having undergone a type I thyroplasty. Fifteen patients had silicone medialization alone, and 2 patients had combination silicone medialization and arytenoid adduction. The mean length of time between the medialization and the secondary surgery was 1 year (range 6 days to 5 years). Two patients were ventilated via a bronchoscope, and 15 patients were intubated orally. The patients who were ventilated via the bronchoscope underwent high-dose brachytherapy of bronchial lesions. The mean size of the endotracheal tube was 8 (range 6 to 9). The mean duration of the surgical procedure was 2 hours 6 minutes (range 40 minutes to 4 hours 15 minutes). The surgical interventions are listed in the Table.

In this experience, there were no episodes of airway complications. All of the patients were successfully ventilated during the course of the procedure. No patients required steroid therapy perioperatively. There was no utilization of tracheostomy for airway management at any time during or after the surgery. Postoperatively, all patients had subjective return of their voice within 1 week of the procedure, compatible with their preoperative vocal function. Similarly, no patients had clinical worsening of swallowing, and there were no episodes of documented aspiration or pneumonia. No patient suffered from pulmonary impairment related to the surgical procedure.

DISCUSSION

Cancer patients form a unique but significant set of patients with unilateral vocal cord paralysis. In a meta-analysis of 1,019 patients with unilateral vocal cord paralysis, 36% were noted to have an underlying malignancy. Approximately one half of these patients had lung cancer.[1] These patients tended to be quite debilitated from their underlying disease. This weakened state exacerbates deficiencies associated with vocal cord paralysis. These patients typically suffer from significant hoarseness, aspiration, dysphagia, and ineffective cough. At our institution, we have reported that medialization procedures may favorably affect the outcome of this patient population. Kraus et al[2] reported on a series of 63 patients with intrathoracic malignancies and unilateral vocal cord paralysis. Fifty-seven patients (90%) were noted to have significant improvements in hoarseness, dysphagia, dyspnea, aspiration, pneumonia, and nutritional status after undergoing medialization procedures. The complication rate was 17%.[2] Only 2 patients had major complications related to surgery, 1 of which was an implant extrusion at the time of attempted medialization. This complication rate is comparable to that reported by Tucker et al,[3] and both are higher than the rate reported by Netterville et al.[4]

Cancer patients with unilateral vocal cord paraly-

sis have a lower survival rate than noncancer patients. Gardner et al[5] evaluated 56 patients with unilateral vocal cord paralysis. They found that the survival for patients with malignancies was much lower than that for patients with benign disease. The mean survival of patients with malignancies was 24 months, and this figure decreased to only 5 months in patients with lung primaries. In addition to a low survival rate, we have found that a significant proportion of these patients will require additional surgery, largely because of their cancer diagnosis. Between 1991 and 1995, 17 of 82 patients (21%) who had undergone medialization for unilateral vocal cord paralysis at Memorial Sloan-Kettering Cancer Center required additional surgical procedures. These procedures were performed as early as 6 days after medialization. The surgical procedures ranged from relatively limited interventions necessitating bronchoscopy for the purpose of brachytherapy of a bronchial lesion to more complicated procedures such as open reduction and an internal fixation of a pathological hip fracture necessitating a prolonged anesthetic. The variety and complexity of the operations was responsible for the variable time of general anesthesia and intubation.

In this series there were no complications. All patients had successful initial management of their airway. As previously noted, 2 patients were ventilated via bronchoscope, and the remainder were intubated via a peroral approach. The endotracheal tube sizes ranged from 6 to 9. In patients undergoing thoracotomy, rather than employ a large double lumen tube, we elected to perform single lung ventilation by employing a bronchial blocker. A critical factor is the atraumatic placement of the endotracheal tube. This is performed by one of our senior anesthesiologists, with the surgeon who performed the medialization being present in the operating room. We have found this cooperation to be beneficial in prevention of implant dislodgement and management of the patient in the perioperative period. We did not employ postoperative steroids, as there was no significant laryngeal edema after intubation. Despite the lack of complications encountered in the series, the potential for airway problems exists. Patients who have undergone silicone medialization have a foreign body present in the larynx. Appropriate placement of the implant deep to the vocalis muscle and ligament limits the risk of extrusion. We also make every effort to preserve the inner perichondrium, which in our opinion further decreases the risk of implant extrusion. Placement of the implant, and particularly arytenoid adduction, results in some narrowing of the laryngeal airway, specifically at the posterior commissure. These patients remain at risk for airway edema and prosthesis extrusion when undergoing airway manipulation.

Utilization of a standardized approach for intubation of the type I thyroplasty patient results in decreased risk of airway complications. Preoperative fiberoptic assessment of vocal cord position alerts the surgeon and anesthesiologist to a potentially dangerous situation. The routine use of atraumatic intubation performed either under direct vision or assisted by a fiberoptic endoscope is critical in this situation. Communication among the operating surgeon, the anesthesiologist, and the laryngologist who performed the medialization procedure is critical. Although a small endotracheal tube was not routinely employed, we recommend a small tube when there is no anesthetic contraindication. Postoperatively, these patients are closely monitored either in the postanesthesia care unit or in a thoracic step-down unit. Patients are closely monitored for signs of laryngeal edema or airway obstruction. Although we did not employ steroids, they may be utilized in the immediate postoperative period. Careful observation allows for assessment and management of postoperative laryngeal edema.

CONCLUSION

In this study, there was no incidence of postintubation complications in patients who had undergone previous thyroplasty. Nevertheless, the potential for complications exists. Complications in this population can be life-endangering. On the basis of our experience, we recommend preoperative fiberoptic evaluation of the airway, coordination of intubation among the anesthesiologist, operative surgeon, and laryngologist, atraumatic intubation with a small endotracheal tube, and diligent observation in the postoperative period.

REFERENCES

1. Terris DJ, Arnstein DP, Nguyen HH. Contemporary evaluation of unilateral vocal cord paralysis. Otolaryngol Head Neck Surg 1992;107:84-90.

2. Kraus DH, Ali MK, Ginsberg RJ, et al. Vocal cord medialization for unilateral paralysis associated with intrathoracic malignancies. J Thorac Cardiovasc Surg 1996;111:334-41.

3. Tucker HM, Wanamaker J, Trott M, Hicks D. Complications of laryngeal framework surgery (phonosurgery). Laryngoscope 1993;103:525-8.

4. Netterville JL, Stone RE, Luken ES, Civantos FJ, Ossoff RH. Silastic medialization and arytenoid adduction: the Vanderbilt experience. A review of 116 phonosurgical procedures. Ann Otol Rhinol Laryngol 1993;102:413-24.

5. Gardner GM, Shaari CM, Parnes SM. Long-term morbidity and mortality in patients undergoing surgery for unilateral vocal cord paralysis. Laryngoscope 1992;102:501-8.

FAT IMPLANTATION INTO REINKE'S SPACE: A HISTOLOGIC AND STROBOSCOPIC STUDY IN THE CANINE

PEAK WOO, MD
NEW YORK, NEW YORK

REZA RAHBAR, MD, DMD
BOSTON, MASSACHUSETTS

ZHI WANG, MD
BOSTON, MASSACHUSETTS

The scarred vocal fold is a cause of persistent dysphonia after laryngeal trauma, microsurgery, and tumor resection. The loss of Reinke's space with scar and stiffness is the primary cause. This study explores the technical aspects of endoscopic implantation of fat as an autologous implant for restoring the bulk and pliability of the vocal folds. Fat from the buccal area was harvested and prepared in 6 dogs. A mucosal flap submucosal pocket was prepared by means of microlaryngoscopy instrumentation. The fat implant was placed into the submucosal pocket. The mucosal flap was sutured endoscopically. Six weeks later, the larynx was harvested and mounted, and vocal fold oscillation was studied while driven by a humidified flow source. The vibratory patterns were studied by stroboscopy. Histologic sections of the vocal folds were made in the coronal plane. All 6 specimens had histologic evidence of viable implanted fat and/or fibrous tissue at the implant site. The site of implantation was in the superior aspect of the vocal fold, but contributed to mass in vocal fold bulk. This increase in bulk histologically corresponded to stroboscopic evidence of increased mass. On stroboscopy, the implant side continued to demonstrate good vibratory function. The study shows that fat implantation can be carried out as an endoscopic procedure. Fat implantation may be useful as a surgical procedure for restoration of Reinke's space. It may be applicable in patients with scars, sulcus vocalis, or vocal fold atrophy.

KEY WORDS — dysphonia, fat implantation, Reinke's space, scarred vocal fold, stroboscopy.

INTRODUCTION

The vibratory function of pliable vocal folds is important in the production of a clear sound. Structural abnormalities remaining after microlaryngeal surgery, trauma, and tumor resection often contribute to residual dysphonia. Scarring and fibrosis of the vocal folds are the principal causes of postoperative dysphonia.[1] The body-cover theory of vocal cord vibration has been demonstrated in histologic detail by Hirano and Kakita.[2] Histologic examination of the human vocal folds has demonstrated the unique layered structure of the vocal fold cover. When scar and vocal fold stiffness is the cause of persistent dysphonia, the resultant vocal fold oscillation demonstrates loss of mucosal amplitude and wave secondary to disruption or loss of Reinke's space. The operative options in patients with scarred vocal folds are limited. The use of collagen injection for glottal incompetencies has been advocated by Ford.[3] Recently, there has been interest in the use of fat as an injectable material in the augmentation of the vocal folds. This has been used in patients with glottal incompetencies due to vocal fold paralysis, as well as other causes.[4,5] Fat injection into the vocalis muscle, as augmentation material, does not answer the quest for a more pliable material to substitute for the superficial layer of the lamina propria in the vocal fold. Injection of fat into a scar is often difficult to perform. Some data suggest that the resorption rate of fat injected into the vocal fold is high.[6] Although the success of fat as a permanent injectable augmentation alternative to Teflon has not been fully demonstrated, fat has many advantages. The viscoelastic properties of fat are close to those of the superficial layer of the lamina propria. Fat is softer than Teflon, collagen, or Gelfoam. It is readily available as an autologous tissue. Experience with fat over time has been well researched.[7] The use of fat as an implant rather than in the injected form has theoretical and practical advantages. Fat implantation is the placement of fat into a surgically created pocket. By dissection of a pocket to receive the fat implant, the fat may be placed into the defect in a precisely measured amount.

Fat implantation into the vocal folds has been studied in animal models by previous authors. In 1989, Wexler et al[8] studied the fate of fat in a canine scarring model. They showed conclusively that the scarred canine larynx may be rehabilitated by thy-

From the Department of Otolaryngology–Head and Neck Surgery, Tufts University School of Medicine and New England Medical Center, Boston, Massachusetts. This study was performed in accordance with the PHS Policy on Humane Care and Use of Laboratory Animals, the NIH *Guide for the Care and Use of Laboratory Animals*, and the Animal Welfare Act (7 U.S.C. et seq.); the animal use protocol was approved by the Institutional Animal Care and Use Committee (IACUC) of New England Medical Center.

Presented at the meeting of the American Broncho-Esophagological Association, Orlando, Florida, May 6-7, 1996.

CORRESPONDENCE — Peak Woo, MD, Dept of Otolaryngology–Head and Neck Surgery, Mount Sinai Medical Center, Box 1191, 5 E 98th St, New York, NY 10029.

rotomy, submucosal fat implantation into Reinke's layer, and suture closure of the wound. The fat implant survived and restored vocal fold vibration. Histologic examination showed viable fat in Reinke's space. In another study, the same group showed the vibratory capabilities of the fat-implanted vocal fold to be superior to those of the scarred vocal fold model.[9] Their surgical approach, however, requires open thyrotomy and tracheostomy. The possibility of improved vocal function with fat implantation propelled the search for a better surgical alternative for performing fat implantation than open thyrotomy and tracheostomy. One possibility is endoscopic fat implantation. With improved instrumentation and endoscopic suturing techniques, endoscopic fat implantation may be possible. It would retain the advantages of fat implantation without the need for tracheostomy or laryngofissure. The purpose of this study was to explore the limits of an endoscopic approach to fat implantation in the vocal fold in a canine model. In addition, the fate of the fat implant and the effect of the fat implant on the vibratory function were tested after surgery by stroboscopy and histologic examination.

MATERIAL AND METHODS

Animal Surgery. Six adult conditioned laboratory dogs were used for this study. The body weights ranged from 14 to 20 kg. All animal surgery and care procedures were carried out in accordance with institutional policies on care of animals. In each experiment, the left vocal fold served as the control side, and the right side served as the experimental side. The animals were anesthetized with Nembutal and maintained under a state of anesthesia with spontaneous ventilation by periodic intravenous maintenance of Nembutal. A buccal fat pad measuring $3 \times 10 \times 5$ mm was harvested through a buccal incision. The fat donor site was closed with a 3-0 chromic suture. The fat pad was preserved in saline gauze for later implantation. The adult Jako laryngoscope (Pilling, Ft Washington, Pa) was placed into position, and suspension microlaryngoscopy was carried out. With standard microlaryngeal instrumentation and operative magnification, the endoscopic procedure to create a pocket for fat implantation commenced. A submucosal pocket was created by making a 1-cm incision on the superior surface of the right true vocal fold. The incision was expanded by blunt and sharp dissection to create a submucosal pocket along the medial edge of the vocal fold. With a cup forceps, the mucosal flap was retracted medially. The microdissector and microscissors were used to create a pocket medially and inferiorly along the contour of the vocal fold. Care was taken to stay in the submucosal plane and avoid vocal ligament injury. Once the submucosal pocket had been created, adrenaline-soaked (1:1,000) cotton pads were placed into the pocket to achieve hemostasis. The autogenous fat was shaped into a $6 \times 4 \times 2$-mm implant and fashioned to fit into the submucosal pocket. The fat was placed into the submucosal pocket with cup forceps. The mucosal flap was placed into position. To prevent fat dehiscence from the incision and to obtain complete edge-to-edge approximation of the mucosal edge, one 4-0 chromic suture was placed endoscopically to suture the edges of the vocal folds.[10]

Endoscopic Evaluation and Excised Larynx Preparation. The animals were examined at 6 weeks after endoscopic surgery under general anesthesia. The larynx was harvested after euthanasia. Excess soft tissue was trimmed from the larynx, and the larynx was mounted in a Plexiglas larynx holder. The vocal folds were approximated by a suture across the vocal process. The excised larynx phonation model is fashioned after Baer.[11] The laryngeal holder has pressure taps for subglottic pressure, flow metering, and adjustment of flow. A heated, humidified airflow source (Bird heater humidifier controller) was used to drive the vocal folds. The air temperature was set at 36°C at 100% humidification. The subglottic pressure necessary to initiate the onset of steady vocal fold oscillation was recorded. During sustained vocal fold oscillation, a stroboscopic light source and video camera were used to record vocal fold vibratory behavior (Power Instrumentation, Skokie, Ill). Stroboscopic endoscopy examination was used to compare the vibratory behavior of the control side with that of the experimental side as to vibratory capability, amplitude, mass, and mucosal wave.

Histology. After the studies of vibratory behavior were completed, the larynx was fixed in 10% formalin, dehydrated, and processed for histology. The larynx was mounted and cut in the coronal plane. Sections were made in 10-μm increments. Histologic sections were obtained at the same level for both the control (left) and experimental (right) vocal folds through the membranous vocal folds. The slides were stained by hematoxylin and eosin. The laryngeal sections were examined. Comparison was made between the experimental side and the control side for 1) evidence of the fat implant, 2) the existence of inflammation, and 3) the thickness of the submucosal layer. Qualitative histologic changes in Reinke's space were recorded.

RESULTS

Operative and Postoperative Findings. All the animals tolerated the procedure without difficulty. The operation lasted from 30 to 60 minutes. The

SUMMARY OF SUBGLOTTIC PRESSURE AND FLOW RATE AT THRESHOLD OF PERIODIC VOCAL FOLD OSCILLATION

Specimen	*Subglottic Pressure (cm H2O)*	*Flow Rate (mL/s)*	*Vibration of Vocal Fold*
1	8	240	Yes
2	12	300	Yes
3	10	310	Yes
4	10	220	Yes
5	9	250	Yes
6	14	350	Partial decrease

wide-bore operating laryngoscope gave good binocular vision for creating the mucosal flap. Although the superior aspect of the submucosal pocket was easy to create, operating on the undersurface of the vocal fold was more arduous and required blunt probes and dissectors. A submucosal pocket was, however, made in each experiment without difficulty. The fat implant could be placed easily into the submucosal pocket to add bulk to the vocal fold. After the fat was implanted, there was a visible bulge of the vocal folds medially. A suture was necessary to keep the fat from herniating through the incision. The endoscopically placed sutures were positioned on the superior surface of the vocal folds. Bleeding was minimal. The dissection in the submucosal plane was able to be used to create submucosal pockets of various sizes. In all the specimens, Reinke's space was easily found. Endoscopic fat implantation could be performed with existing microinstruments.

The postoperative courses were uncomplicated. None of the animals had difficulty with the airway or deglutition. All the animals were noted to have voice after the procedure. Because of the technical difficulty of recording voice in the animal shelter, only qualitative impressions of the voice could be taken. There was minimal voice change compared to the preoperative state after the first week.

Videostroboscopy Findings. Videostroboscopy recordings were generated from the excised canine preparation. Stable vibration was seen in all the specimens. The subglottic pressure threshold necessary for stable oscillation ranged from 8 to 14 cm H2O (see Table). Prior experience (unpublished data) using the same experimental setup in normal canine larynges showed thresholds of oscillation at 5 to 10 cm H2O. The induced vocal fold vibration showed a vibratory pattern that was remarkably similar to that of normal vocal folds. The implanted side showed good mucosal amplitude and an intact mucosal wave. The implanted side appeared to be slightly thicker than the control side, giving the impression of greater mass. All the specimens were capable of stable periodic oscillations. The operated sides had the appearance of greater mass, but were equal in amplitude, mucosal wave, and vibratory capability to the control sides. Phase differences were occasionally noted between the two sides. The operated side, being greater in mass, appeared to have a delay in the phase of vocal fold vibration compared to the opposite side. In all the preparations, the vocal fold amplitude was rated as the same as or greater than that of the nonoperated side. However, the degree to which apparent mass was added to the vocal folds showed considerable variation, which could not be accounted for by the size of the surgical implant placed into the pocket. Figure 1 is a series of videostroboscopy images for specimen 2. The glottal cycle shows a good vibratory amplitude, a symmetric phase of vibration, and an intact mucosal wave on both the control and implanted sides. The implanted side (right) has a slightly greater mass than the control side. The increased mass of the vocal fold may account for the increased subglottic pressure thresh-

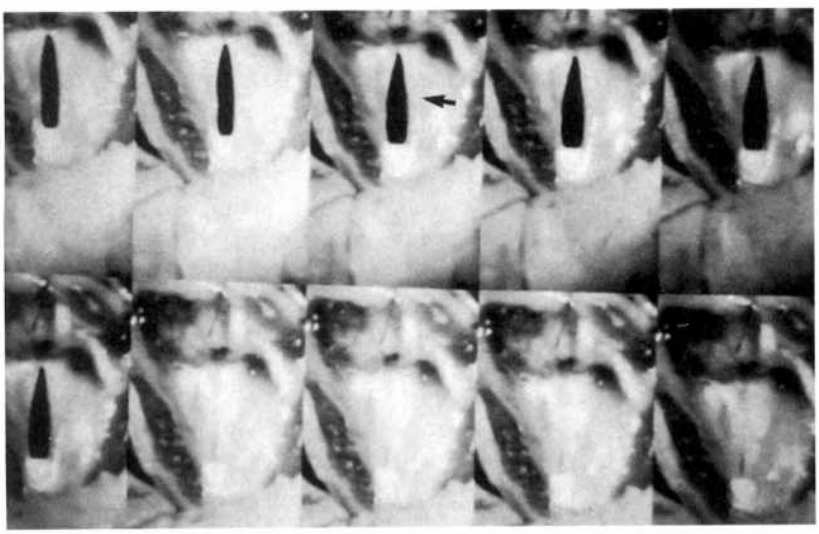

Fig 1. (Specimen 2) Stroboscopic sequences. Flow rate was 300 mL/s, subglottic pressure was 12 cm H2O, and frequency was 82 Hz. Implanted side (arrow) has vibratory amplitude and wave, with some increase in mass.

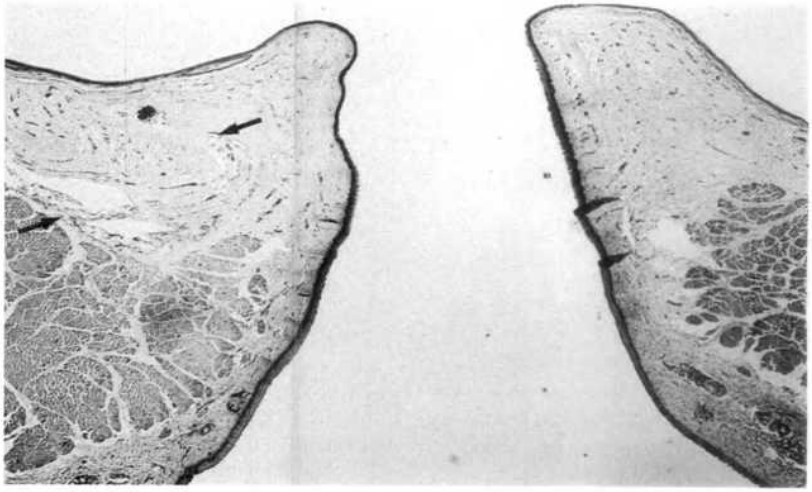

Fig 2. (Specimen 1) Low-power midmembranous views of both vocal folds. Implanted tissue is combination of fat and fibrous tissue between arrows. Site of implant is on superior aspect of vocal fold. Increase in bulk compared to control side is seen on this low-power view.

old compared to normal canine larynges.

Histologic Findings. In all 6 specimens, clearly identifiable fat cells or fibrous tissue could be identified in the submucosal pocket. The fat component was present along the superior surface to the vocal fold edge. Figure 2 is a histologic section of both the right and left vocal folds in specimen 1. A close-up of the viable fat cells in the superior surface of the vocal fold is seen on Fig 3. The increase in bulk compared to the control side is evident. The finding of fat placement on the superior aspect of the vocal fold was consistent in all specimens. The amounts of fat and fibrous tissue were variable. Figure 4 is a close-up view of another specimen showing viable fat cells in the submucosal plane. The added fat cells are between the vocalis muscle and the vocal fold epithelium, increasing the thickness of Reinke's space.

DISCUSSION

The use of fat as a soft tissue implant in the larynx adds an exciting prospect in the rehabilitation of the scarred larynx. Fat augmentation in soft tissue reconstruction has a long history. Use of fat in the vocal fold as an autologous substitute for soft tissue has been proposed.[4-6] The initial experience of fat injection was the use of fat as an augmentation substitute for Teflon in the rehabilitation of the paralyzed vocal fold. Wetmore[7] studied fat injection in the rabbit model and compared it to fat implantation. He showed reabsorption of injected fat over the first year. Although viable fat was shown histologically, the amount was variable. Histologic examination of injected fat showed cyst formation indicative of fat cell degeneration. In a study of human patients undergoing fat injection for vocal fold paralysis, Zaretsky et al[6] supported the findings of retained viable fat, but pointed to the rapid absorption of fat over the first 6 months after surgery. Fat is believed to be absorbed principally because of the processing technique used to prepare fat for injection. Fat implantation may obviate the need for fat processing and cell necrosis. The use of fat implantation has a long history of use in facial plastic surgery. Fat implantation has less absorption than fat injection. Fat injection versus fat implantation was submitted to volumetric and histo-

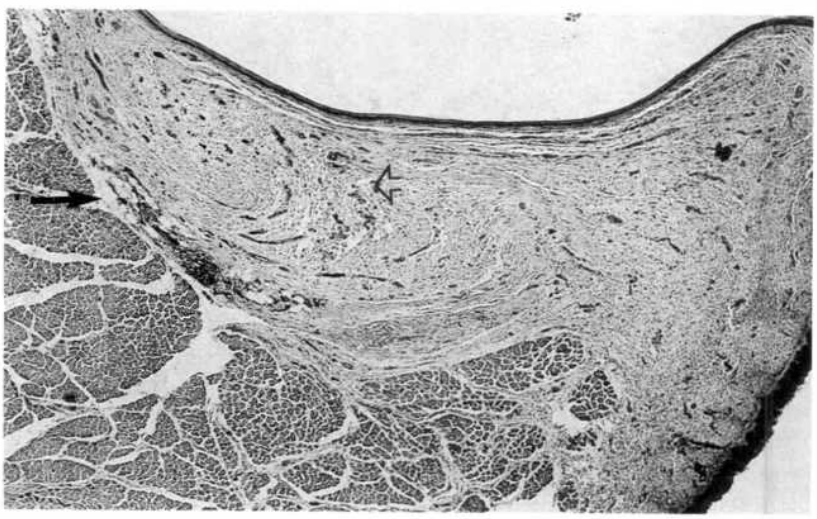

Fig 3. (Specimen 1) Close-up view. Collagen (open arrow) and fibrous tissue sit above fat layer (closed arrow). Buccal fat pad in dog has variable fibrous and fatty tissue, which may explain mixed picture.

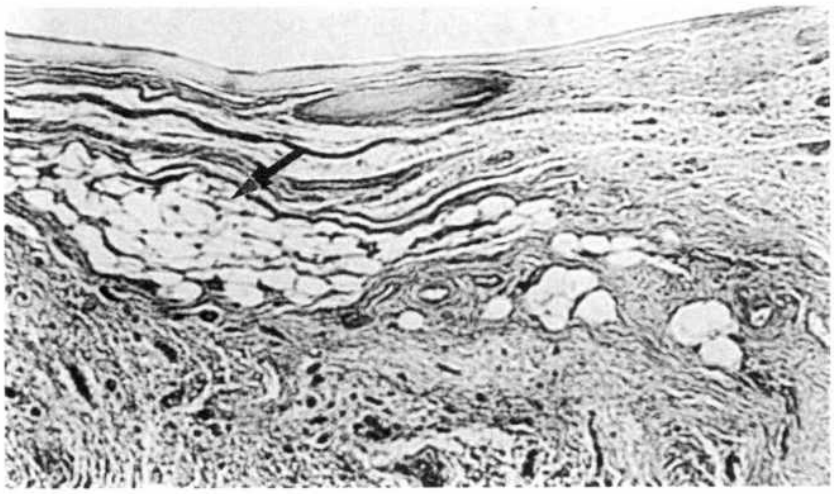

Fig 4. High-power view of viable fat cells (arrow) in Reinke's space.

logic study in the rabbit by Kononas et al,[12] who found that less reabsorption occurs with implantation.

In rehabilitation of the scarred vocal fold, the stiff submucosal plane is devoid of the fluidlike layer in Reinke's space. This stiff layer reduces vocal cord vibration and is responsible for the nonvibratory segment seen in patients with scarred vocal folds. The scar does not participate in vocal fold oscillation. In rehabilitation of such a problem, the surgeon has few choices at present. Isshiki[13] describes surgical mucosal grafting in patients who have no vibratory capacity by thyrotomy, mucosal grafting, tracheostomy, and endolaryngeal stenting. Ford[3] has treated patients with vocal fold scarring by collagen injection to correct glottic deficiencies. The use of fat as an injected material was evaluated by Mikus et al[4] in a canine study. They were able to show the presence of viable fat in the submucosal plane in dogs after fat injection. However, in the clinical situation, fat injection into the submucosal plane is complicated by the scarred bed.

In patients with vocal fold scars, fibrosis would make injection of fat into the submucosal layer a difficult procedure. Attempted injection of fat into a stiff vocal fold may result in fat's being deposited with little predictability: deep into the muscle, into the vocal fold ligament, or in other unwanted areas. A more predictable solution would be the surgical creation of a submucosal pocket by scar lysis followed by surgical implantation of fat to recreate the viscoelastic properties of the vocal fold. Our technical study evaluated an endoscopic approach for fat implantation into the canine vocal fold.

In a search for better autologous substances that simulate the viscoelastic properties of the human vocal fold, many substances have been tried. Theoretically, the material should be biocompatible and simulate the viscoelastic properties of the multilayered vocal folds. It should also be readily available. Fat is a natural substance that is readily available for transplantation. Fat is an autologous implant with little to no donor site morbidity. It has a long history of relative safety in facial plastic and reconstructive surgery. The viscoelastic properties of fat are closer to those of the fluidlike superficial layers of the vocal fold than are those of collagen or Teflon.

Endoscopic fat implantation in the vocal fold has not been done in humans. Wexler et al,[8] in a study of vocal fold scarring in the dog, showed conclusively that the scarred vocal fold failed to vibrate with the same subglottic pressure threshold and the same vibratory characteristics as in control animal models. The vibration was characterized by aperiodicity, high subglottic pressure, and reduced glottic efficiency. Further, the researchers showed that fat implanted into the vocal folds was able to reduce the subglottic pressure needed to set the vocal folds into stable periodic oscillation. The fat survival in Reinke's layer was carefully documented.

The advantages of fat implantation over fat injection are threefold. First, creation of a pocket allows the surgeon to lyse the scar and precisely place the implant where it is most needed, ie, near the vocal fold edge, rather than deep into the vocalis or vocal ligament. Second, the fat can be harvested and placed as a single implant without needing to be crushed. This should reduce fat cell lysis and necrosis. Third, the single implant should be able to create a single-layer, pliable fat cushion that is softer than the original scar, yet is a complete, uniform layer. A single, uniform layer of fat should be better than multiple droplets of fat cells injected into the area.

The disadvantages of fat implantation by the open laryngotomy approach are its technical difficulty and the need for thyrotomy. Open procedures require

tracheostomy, laryngofissure, and prolonged hospitalization. Many of these disadvantages may be obviated by an endoscopic approach, as attempted in this study.

This study, using endoscopic techniques, resulted in findings similar to those of Wexler et al.[8] The implanted fat added bulk and mass to the vocal fold, but continued to be pliable and participate in vocal fold oscillation. The conclusions from this study are 1) fat and fibrous tissue can be successfully placed into the Reinke's layer by an endoscopic technique, 2) survival of the fat and fibrous tissue was documented at 6 weeks after surgery on histologic section, 3) stroboscopic findings after fat implantation show improved tissue bulk, and 4) the vibratory capabilities of the vocal folds augmented by fat implants were comparable to those of the control side. If the goal of surgery for vocal fold scarring is the restoration of compliant vocal folds capable of oscillation, the use of fat implanted in the vocal fold cover should satisfy this need.

This study of fat survival after endoscopic fat implantation should be considered preliminary. The technical aspects of endoscopic fat implantation have been addressed only partially by this study. The presence of fat survival at 6 weeks is encouraging. However, whether fat survival will persist and continue to augment the vocal fold cover after the initial 6 weeks is not clear. Longer survival studies should be done. The presence of fibrosis in the histologic specimens suggests that either the buccal fat pad in the dog is not a good source for fat, or there is some fat absorption in the implant site, with fat being converted into autologous collagen. The animal model used was not a scarred laryngeal model. Because of the technical aspects of developing new techniques for fat implantation, no attempt was made to simulate scarred vocal fold conditions as done by Wexler et al.[8]

The technical aspects of creation of an optimal flap to receive the fat have not been addressed. In the canine experiments, the fat was limited to the superior and medial edges of the vocal fold. The undersurface of the vocal folds did not receive the implants. Where the fat should be placed to achieve optimal vibration is not clear. Whether the fat should be placed on the undersurface, the free vocal fold edge, the superior edge, or a combination of all is not certain. This will need to be further studied. This study did not quantify the amount of fat absorption after implantation, because of the variations in specimen size and the difficulty of volumetric studies. A statistical analysis based on volumetric studies from serial sections would be ideal.

Despite these limitations, the further development of a practical endoscopic approach to the scarred vocal fold should allow the phonosurgeon more options in the treatment of the postoperatively dysphonic patient. Fat implantation, mucosal grafting, and scar revision, if it can be done endoscopically, should advance the current treatment options for the scarred vocal fold. The histologic and stroboscopic results from this preliminary study are encouraging. Although further work is needed to determine the optimal site of fat implantation, we believe fat implantation into the lamina propria of the vocal folds is a feasible approach. Further studies are needed to document the surgical validity of fat in a scarred animal model.

In summary, we have used an endoscopic approach for fat implantation and augmentation of the canine vocal fold. Endoscopic evaluation, stroboscopic assessment of vibratory function, and histologic examination show retention of bulk and vibratory behavior. The placement of fat into Reinke's space serves as an autologous implant for restoration of Reinke's layer. These encouraging results suggest that fat implantation via the endoscopic approach may be feasible in the human for rehabilitation of the scarred vocal fold.

REFERENCES

1. Woo P, Casper J, Colton R, Brewer D. Diagnosis and treatment of persistent dysphonia after laryngeal surgery: a retrospective analysis of 62 patients. Laryngoscope 1994;104:1084-91.

2. Hirano M, Kakita Y. Cover-body theory of vocal cord vibration. In: Daniloff RG, ed. Speech science. San Diego, Calif: College Hill Press, 1985:1-46.

3. Ford C. Laryngeal injection techniques in phono surgery. In: Ford CN, Bless DM, eds. Assessment and surgical management of voice disorders. New York, NY: Raven Press, 1991:123-41.

4. Mikus JL, Koufman JA, Kilpatrick SE. Fate of liposuctioned and purified autologous fat injections in the canine vocal fold. Laryngoscope 1995;105:17-22.

5. Brandenberg JH, Kirkham W, Koschkee D. Vocal cord augmentation with autogenous fat. Laryngoscope 1992;102:495-500.

6. Zaretsky LS, Shindo ML, deTar M, Rice DH. Autologous fat injection for vocal fold paralysis: long-term histologic evaluation. Ann Otol Rhinol Laryngol 1995;104:1-4.

7. Wetmore SJ. Injection of fat for soft tissue augmentation. Laryngoscope 1989;99:50-7.

8. Wexler DB, Jiang J, Gray SD, Titze IR. Phonosurgical studies: fat-graft reconstruction of injured canine vocal cords. Ann Otol Rhinol Laryngol 1989;98:668-73.

9. Jiang JJ, Titze IR, Wexler DB, Gray SD. Fundamental frequency and amplitude perturbation in reconstructed canine

vocal folds. Ann Otol Rhinol Laryngol 1994;103:145-8.

10. Woo P, Casper J, Griffin B, Colton R, Brewer D. Endoscopic microsuture repair of vocal fold defects. J Voice 1995; 9:332-9.

11. Baer T. Investigation of phonation using excised larynges [Dissertation]. Cambridge, Mass: Massachusetts Institute of Technology, 1975.

12. Kononas TC, Bucky LP, Hurley C, May JW. The fate of suctioned and surgically removed fat after implantation for soft tissue augmentation: a volumetric and histologic study in rabbit. Plast Reconstr Surg 1993;91:763-6.

13. Isshiki N. Surgical management of scar of the vocal cord in phonosurgery: theory and practice. Berlin, Germany: Springer Verlag, 1989:175-9.

≈

INTERNATIONAL CONFERENCE ON NEWBORN HEARING SCREENING DIAGNOSIS AND INTERVENTION

The International Conference on Newborn Hearing Screening Diagnosis and Intervention will be held in Milan, Italy, October 12-14, 2000. In Europe, contact Dr Ferdinando Grandori, Center of Biomedical Engineering, Polytechnic of Milan, piazza Leonardo da Vinci 32, I-20133 Milan, Italy; fax +39.02.2399.3360; e-mail NHS2000@biomed.polimi.it. In the United States, contact Dr Deborah Hayes, The Children's Hospital, 1056 E 19th Ave, B030, Denver, CO 80218; telephone (303) 861-6424; fax (303) 764-8220; e-mail Hayes.deborah@tchden.org.

INNER EAR DAMAGE IN TORP-OPERATED EARS: EXPERIMENTAL STUDY ON DANGER FROM ENVIRONMENTAL AIR PRESSURE CHANGES

HANS WILHELM PAU, MD

ROSTOCK, GERMANY

In some cases of sudden inner ear hearing loss in ears with a total ossicular replacement prosthesis, the prosthesis has been found to be penetrating the footplate. Some authors have assumed an external pressure increase for this event. In this study I tried to estimate experimentally the pressure needed for perforating a normal footplate in a temporal bone model. From the data I concluded that "cracking" the footplate can hardly be due to 1 major event of increased pressure. On the other hand, different mechanisms making the footplate a "weak spot" must be discussed and further investigated. In those cases, secondary to thinned or even perforated footplates, environmental pressure changes may be dangerous.

KEY WORDS — external pressure, footplate perforation, inner ear damage, total ossicular replacement prosthesis.

INTRODUCTION

Like some other ear surgeons[1,2] (also D. Plester, unpublished observations), I have seen penetrations of total ossicular replacement prostheses (TORPs) through the stapes footplate into the vestibulum as a cause of severe inner ear hearing loss. Fortunately, these events are very rare. Among others, Fisch[1] postulated poor eustachian tube function to be responsible. In this theory, environmental pressure changes cannot be equalized, or negative pressures in the middle ear due to impaired tube function "press" the tip of the prosthesis against the footplate and finally break it.

This danger, if real, would be important in advising the patient how to behave after surgery — hence, the focus of the present study. Do pressure changes mean a danger for the footplate in an operated ear with a TORP?

For estimating pressures needed to break the footplate, experiments were performed in fresh human temporal bones. From former investigations,[3] I knew that environmental pressure changes are much more easily conducted toward the footplate in "TORP ears" than in normal ears (by more than a factor of 10). This is not only due to the smaller connection area between the TORP and the footplate, compared to the normal stapes. In a normal ear, changes in the "static" pressure with inward and outward displacement of the tympanic membrane are not totally conducted to the footplate, but are damped by movements in the malleo-incudal joint.[4,5] In TORP ears, this damping mechanism is missing. The experiments were designed with these facts in mind.

MATERIAL AND METHODS

Studies were carried out on 15 fresh human temporal bones. In 10 of them, I removed the middle and inner ear to a degree that the stapes footplate was exposed from both sides (Figs 1 and 2). A "TORP-like" piston (Fig 2; 0.56 mm^2 in dimension) could be moved by pressure in a smooth-moving glass syringe, which was connected to a pump. Simultaneously, pressure was registered (Figs 2 and 3). The TORP just touched the footplate when pressure was increased. Perforation of the footplate could either be visualized directly (Fig 4) or registered as a sudden loss of pressure on a time-pressure diagram (Fig 3A). In another 5 specimens only the tympanic membranes and ossicular chains were removed (stapes

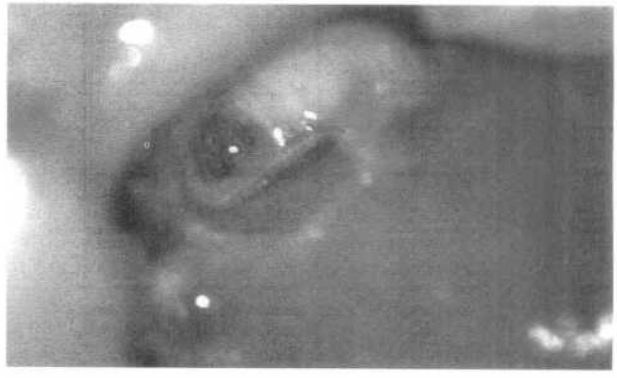

Fig 1. Stapes footplate exposed from vestibular side of temporal bone.

From the Department of Otorhinolaryngology, Medical School, University of Rostock, Rostock, Germany.

CORRESPONDENCE — Hans Wilhelm Pau, MD, Dept of Otorhinolaryngology, Medical School, University of Rostock, Doberaner Str 137, 18057 Rostock, Germany.



Fig 2. Experimental setup for estimating pressures needed to break exposed footplate.

superstructure cut with crurotomy scissors). After the specimen was placed straight on a digital balance, a TORP (Richards; centered TORP with 0.84-mm-diameter shaft) was gently pushed toward the inner ear (Fig 5). Of course, the Figures only demonstrate the principle. In actuality, the TORP was introduced with an operating microscope and tympanoplasty instruments were used to apply pressure on the footplate. Correct placement of the TORP and breaking of the footplate could thus be watched (Fig 6). The corresponding weight was recorded, from which force and pressure could be calculated.

RESULTS

Figure 3B demonstrates the measured pressures needed for breaking the footplate in our first series. The pressure seemed to be very high (factor 10^5 decapascals [daPa]), only because of the small area of force application. Corresponding weights were calculated to be in a range of about 100 g.

Characteristically, the footplate always broke in a straight line crosswise to its largest diameter. The

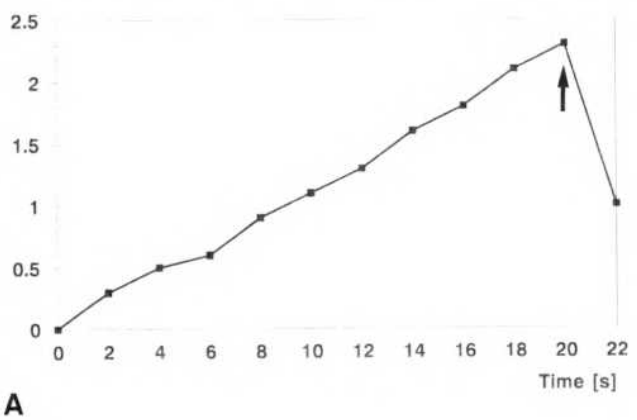

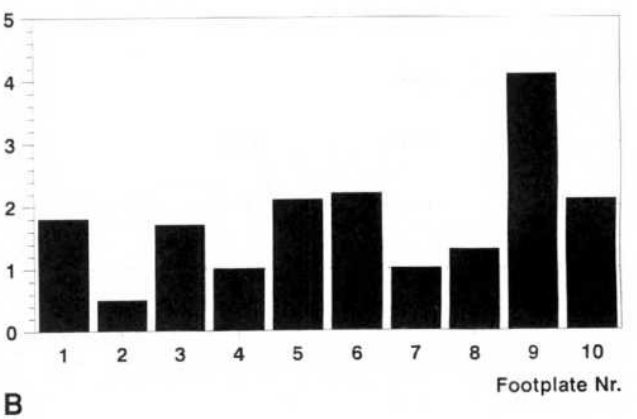

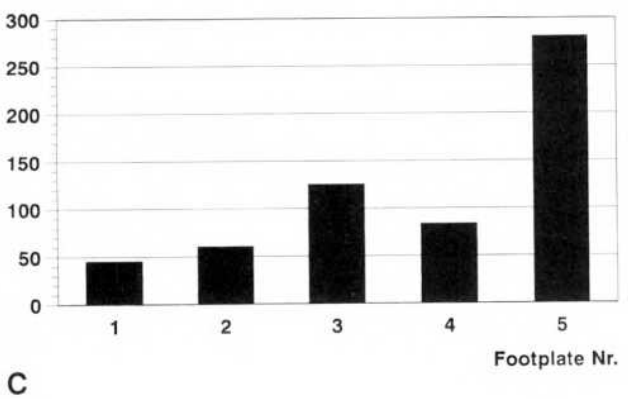

Fig 3. Diagrams of pressure (daPa × 10^5) and weight (g). A) Increasing pressure on TORP head until breaking of footplate (arrow). B) Pressures for breaking footplate in series 1. C) Weight for breaking footplate in series 2.

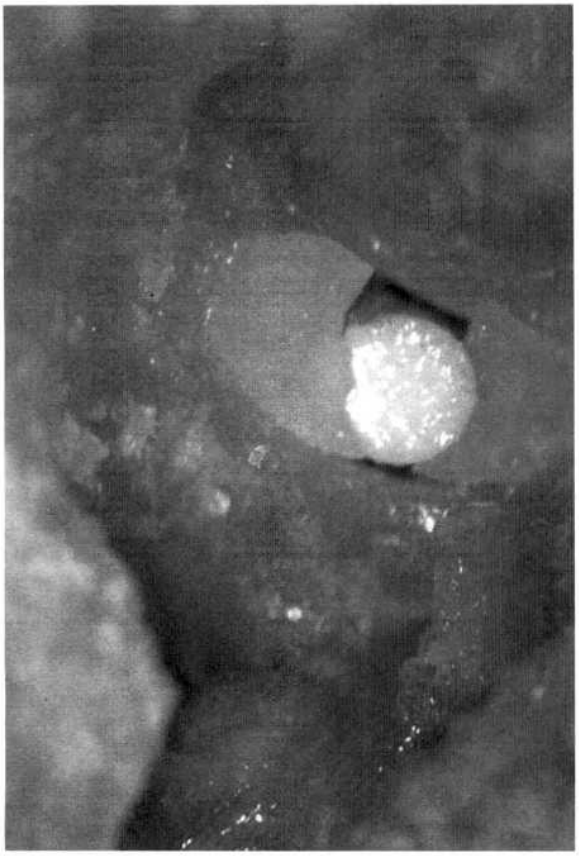

Fig 4. TORP breaking footplate.

second series (Fig 3C) confirmed the calculations of the first series by only measuring the weight on the digital balance: about 100 g.

DISCUSSION

Every ear surgeon doing stapedotomies may have an idea about the force he or she would need to use to push a TORP through a footplate. In this experiment I wanted to obtain data in normal ears. The pressure at first view seems to be very high. I did 2 experimental series with different designs (even with the different diameters of the TORPs), because at first I thought the pressures of the initial series were too high. The second series, however, confirmed these results, even with the increased diameter of the TORP. The calculated weight put on the prosthesis head in the first series was no more than about 100 g. This could very easily be proven with the second experimental design, when the actual weight on the balance was registered.

That 100 g could easily be reached if the tympanic membrane (with the TORP) performed an inward-outward movement like a piston. Actually, the membrane does not. Flisberg et al[6] found that if environmental pressure is raised to 130 daPa, about 60% of the possibility of inward movement is reached. In former experiments[3] we had measured the pressure at the tip of the TORP in correlation to the steadily increased pressure in the external ear canal. Some of the results of those experiments are as follows. With the pressure increase at the TORP's tip while raising the external pressure from 0 to 100 daPa considered as 1, between 100 and 200 daPa, it is only 0.6, between 200 and 300 daPa it is 0.5, and between 300 and 400 daPa it is only 0.1. There is clear evidence that above 400 or 500 daPa the tympanic membrane becomes stiffer and does not transduce static pressures any more until it ruptures. This means that the tympanic membrane protects the inner ear from ex-

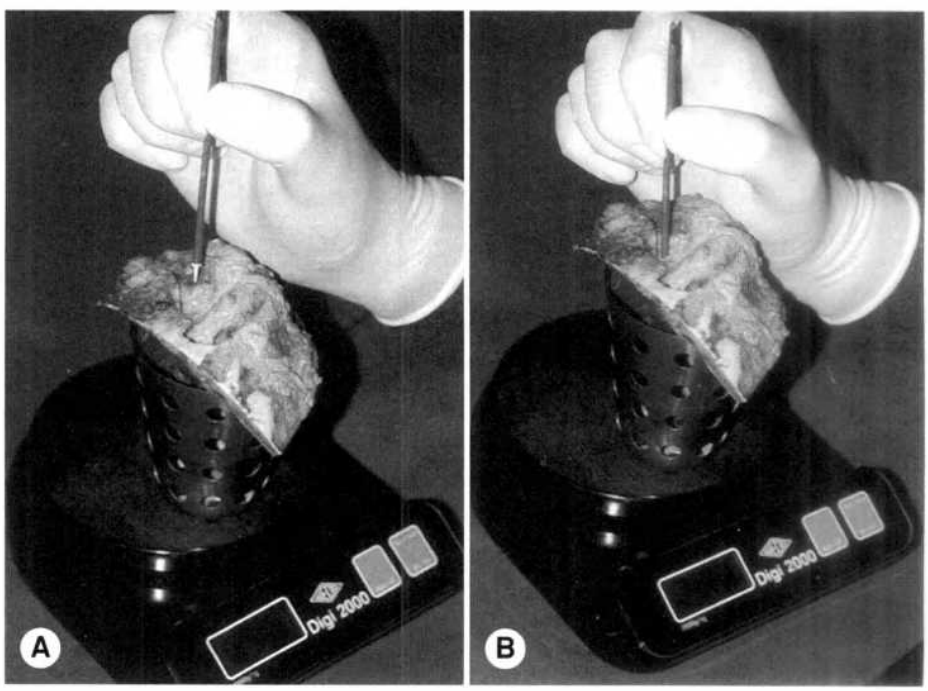

Fig 5. Principle of second device for estimating weight on footplate. Temporal bone is mounted on digital balance. A) Placing TORP on footplate. B) Breaking footplate by pushing TORP inward.

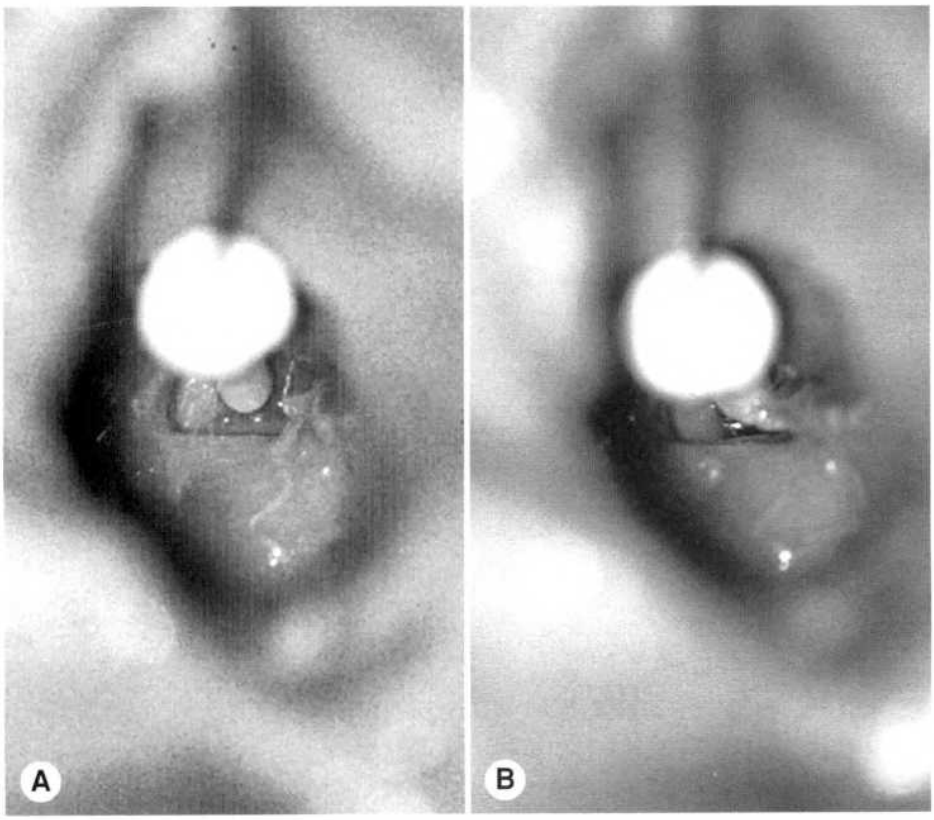

Fig 6. TORP on footplate, seen through operating microscope. A) Needle pushing on TORP's head. B) TORP perforating footplate.

cessively high pressures such as those transduced by a TORP. Thus, breaking of the footplate by 1 pressure-dependent event is very unlikely.

Another indication is the shape of the perforation. In contrast to the experimental cracks within the footplate, the perforations found in vivo are round. This indicates a different origin.

Of course, long-lasting low pressure may cause structural changes within the middle ear. The tympanic membrane may be thinned, either by negative pressure itself or by resulting effusions. In middle ear effusions, very often high concentrations of proteinases can be found, destroying the collagen fibers of the tympanic membrane[7] or even the ossicles. In particular, the long process of the incus may be thinned or be lost. In atelectatic ears, almost all parts of the middle ear can be thinned, eroded, or weakened. Why not the footplate?

The answer is not easy. It is well known that this part — embryologically derived from Reichert's cartilage — reacts somewhat differently. There are many similarities to reactions of the otic capsule. The footplate seems to be more resistant to infection or destruction by, for example, cholesteatomas. In our studies in Wittmaack's temporal bone collection in Hamburg,[8] we very often saw completely intact footplates, even in cases of entirely destroyed ossicular chains. There may be a broad layer of connective tissue, but never a perforation or even thinning of this structure. The behavior similar to the otic capsule is stressed by the fact that both bony parts do not form a callus after breaking. Those lines are only closed by connective tissue. So, actually, the stapes footplate is something special within the ossicular chain (most parts of which are embryologically derived from Meckel's cartilage).

Although I consider it unlikely, the effect of continuous mechanical irritation could be discussed. One could think of the prosthesis "hammering" against the footplate, causing bone resorption and making it into a "weak spot." On the other hand, pressures are extremely low, and — more important — experiments have shown connective tissue at the TORP-footplate interface.[9,10]

To me, it seems more likely that foreign body reactions may be a rare but existing problem, at least in some materials[11] used for modeling a TORP. It may be that in an unknown number of patients, "weak spots" in the footplace or even perforations sealed by connective tissue mucosa or endosteum already exist. Supposing this theory, changes of environmental pressure or negative middle ear pressure due to tube dysfunction might achieve a more important role in the "perforation theory," causing inner ear damage.

From the present theory I would recommend that patients with a TORP should avoid highly pressure-increasing situations like diving and flying (especially during upper airway infections).

In most airplanes, cabin pressure during flight is kept in a range of about that at 2,000 m above sea level. Assuming a totally closed middle ear with no pressure equalization via the eustachian tube, while landing, theoretically more than –2,000 daPa could result. The same is true for diving 2 m deep. Actually, the pressure difference is diminished by an inward movement of the tympanic membrane, thickening of the mucous lining by vascular dilation, or a change in middle ear gas composition (rapid diffusion of carbon dioxide into the middle ear cavities[12]). However, if negative pressure exceeds –1,300 to –19,500 daPa, the tympanic membrane will rupture — of course, depending on the condition of the membrane. In any case, as long as "weak spots" of the footplate cannot totally be excluded, high-pressure–increasing situations should be avoided.

The future may show how often inner ear damage occurs and how an ideal prosthesis should be configured. In order to increase our knowledge about morphology in such cases, further studies are being conducted on animal models, mainly minipigs.

REFERENCES

1. Fisch U. Tympanoplasty and stapedectomy. Stuttgart, Germany: Thieme, 1980.

2. Jahnke K, Schrader M, Silberzahn J. Osseo-integrated implants in otorhinolaryngology. In: Heimke G, ed. Osseointegrated implants II. Boca Raton, Fla: CRC Press, 1990:287-332.

3. Pau HW, Hüttenbrink KB. Experimental studies in reconstructed middle ears — with special regard to static pressure on the footplate. Laryngol Rhinol Otol (Stuttg) 1988;67:331-4.

4. Marquet J. The incudo-malleal joint. J Laryngol Otol 1981;95:541.

5. Hüttenbrink KB. The mechanics of the middle-ear at static air pressure. Acta Otolaryngol [Suppl] (Stockh) 1988(suppl 451).

6. Flisberg KS, Ingelstädt S, Örtegren V. On the function of middle ear and eustachian tube. Acta Otolaryngol [Suppl] (Stockh) 1963(suppl 18).

7. Hartwein J, Messing G, Schaeg G, Pau HW. EM studies of the collagen fibre structure of the human tympanic membrane in adhesive process cases. Laryngol Rhinol Otol (Stuttg) 1990;69:333-6.

8. Pau HW, Peimann CJ, Ußmüller J. Wittmaack's temporal bone collection. A new approach. HNO 1993;41:512-8.

9. Reide W, Dost N, Mißfeldt N, Heine J, Jahnke K. Reconstruction of the stapes superstructure with bioactive ceramics. HNO 1993;41:131-4.

10. Yamamoto E. Long-term observations on ceramic ossicular replacement prostheses. Laryngoscope 1988;98:402-4.

11. Austin DF. Columellar tympanoplasty. In: Grote JJ, ed. Biomaterials in otology. Amsterdam, the Netherlands: Martinus Nijhoff, 1984:119-26.

12. Pau HW. Physiology of middle ear ventilation. Otorhinolaryngol Nova 1991;1:2-8.

UC OTOLARYNGOLOGY UPDATE: 1999

The UC Otolaryngology Update: 1999 will be held November 4-6, 1999, in San Francisco, California. For information, contact Office of Continuing Medical Education, Registration Office, Office of CME, UCSF Box 0742, LH-450, University of California, San Francisco, CA 94143-0742; telephone (415) 476-5808; fax (415) 502-1795; web site http://cme.ucsf.edu.

MASTOID BUFFERING PROPERTIES: I. GAS PARTIAL PRESSURES

EYAL RAVEH, MD
TEL-AVIV, ISRAEL
HAYA MOVER-LEV, PHD
TEL-AVIV, ISRAEL
JACOB SADÉ, MD
TEL-AVIV, ISRAEL
SELCUK GUNEY, MD
ISTANBUL, TURKEY

Differences in the gas partial pressures between the middle ear (ME) cavity and the blood are an important factor in ME gas economy. Differences in gas partial pressures between various regions of the ME–mastoid air cell system (ME-MACS) could play a role as well. To determine whether gas partial pressure differences do occur between various compartments in the ME, we measured the rate of gas diffusion from one compartment to another in both an artificial model and in the ME-MACS of human temporal bones. The rate of gas diffusion between various areas of the ME and the mastoid tip was found to be rapid, with a half-life on the order of 2 minutes (range 0.8 to 5.3 minutes). We suggest that this high diffusion rate prevents the buildup of significant differences in gas composition in the ME-MACS system, which can therefore be regarded as a homogeneous gas pocket.

KEY WORDS — chronic otitis media, diffusion of gases, mastoid, middle ear gases, middle ear pressure, partial pressure.

INTRODUCTION

Our current understanding of gas pressure dynamics in the middle ear (ME)–mastoid air cell system (MACS) includes an assumption that under normal physiological conditions there is continuous absorption of gas, mainly nitrogen (N_2) and oxygen (O_2), from this cavity into the blood. The opening of the eustachian tube that occurs during swallowing, yawning, etc, compensates for this loss by introducing gas from the nasopharynx into the ME cavity.[1-3]

The impetus for gas exchange between the ME and the blood is the difference in the partial pressures of gases between these 2 locations.[4-6] The total pressure is the sum of the gas partial pressures; differences in gas partial pressures between the ME and the MACS may influence gas exchange rates, and consequently affect the total pressures of the system. Since the mastoid is a labyrinth, its internal cellular structure might be expected to attenuate the rate of diffusion and redistribution of gases in the ME-MACS after a compositional upset in one region. A lag in gas diffusion and redistribution could cause pressure differentials in the system that may possibly be clinically significant. To determine whether gas partial pressure differences do occur between various compartments in the ME-MACS, we measured the rate of gas diffusion from one compartment to another, in both an artificial model and in human temporal bones.

MATERIALS AND METHODS

Artificial Model. To examine gas diffusion rates in a model, a 20-mL plastic syringe was divided into 2 cells by a partition (Fig 1). A 4-mm opening in the partition could be closed and opened by means of a metallic cover operated by an external magnet. Two 50-mm lengths of polyethylene tubing, 1 mm in inner diameter, permitted the introduction of a gas mixture into cell I. Probes were connected to cell II for measurement of pressure, temperature, and gas concentrations.

Initially, cell II contained room air, while cell I was filled with a mixture resembling the steady-state composition of gas in the ME: 81.39% N_2, 9.37%

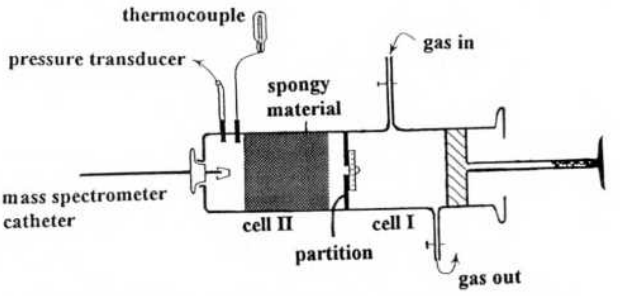

Fig 1. Model for gas diffusion. Twenty-milliliter syringe was divided into 2 cells by partition. Gas mixture was introduced into cell I through polyethylene inlet and outlet tubes. Cellular material was contained in cell II, which was connected to mass spectrometer, thermocouple, and pressure transducer. Partition had opening closed with metallic cover that could be opened with external magnet.

From the Ear Research Laboratory, Department of Bioengineering, Faculty of Engineering and Sackler School of Medicine, Tel-Aviv University, Tel-Aviv (all authors), and the Department of Otolaryngology–Head and Neck Surgery, Rabin Medical Center, Beilinson Campus, Petah-Tikva (Raveh), Israel.

Presented at the Third Extraordinary International Symposium on Recent Advances in Otitis Media, Copenhagen, Denmark, June 1-5, 1997.

CORRESPONDENCE — Jacob Sadé, MD, Ear Research Laboratory, Bioengineering, Wolfson Building, Tel-Aviv University, Tel-Aviv 69978, Israel.

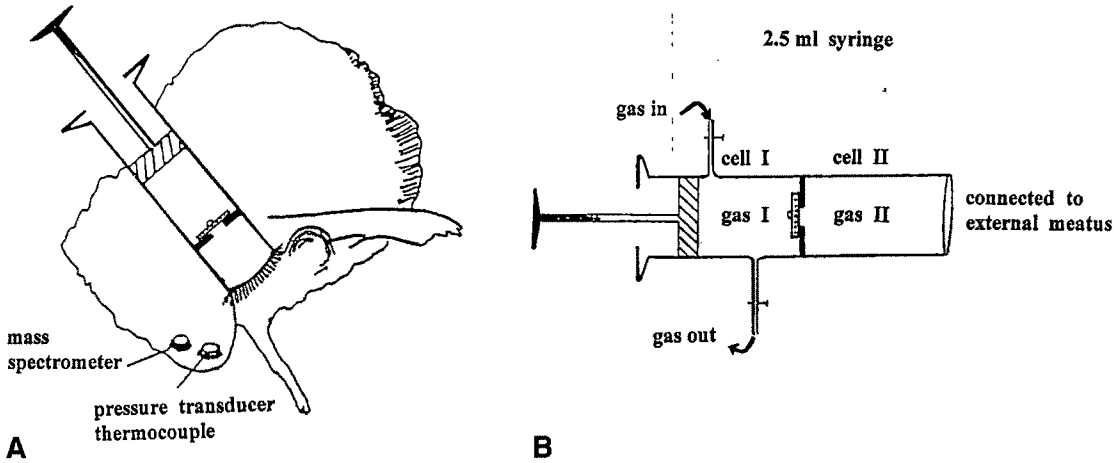

Fig 2. Gas diffusion measurements in mastoid bone. A) Bone with 2.5-mL syringe connected to external auditory canal. There were 2 openings in mastoid tip, 1 for mass spectrometer and other for pressure transducer and thermocouple. B) Syringe (2.5 mL) served as chamber for introduction of gas mixture into middle ear. Like that in Fig 1, it was divided into 2 cells by partition; metallic cover over opening between cells could be opened with external magnet. Cell II was hollow cylinder connected to external auditory canal. Cell I was used for introduction of another gas mixture via polyethylene inlet and outlet tubes.

carbon dioxide (CO_2), 8.17% O_2, and 1.07% argon (Ar). After a 7-minute wash with this gas mixture, all air in cell I was considered to have been replaced, and both tube inlets were sealed. The partition separating the 2 cells was then opened. The changes in gas composition in the combined cells over time were recorded until the mass spectrometer indicated that a steady state had been reached. Diffusion time was defined as the period elapsed between the opening of the partition and the first reading of a gas composition that remained constant. These measurements were repeated at volumes of 5, 10, and 15 mL.

To simulate the internal structure of the MACS, the experiment was also done with cellular material filling cell II. Organic and synthetic types of sponge were used: the dried skeleton of a marine sponge, and a flexible polyurethane spongy material, respectively. Both of these had an interconnected open cellular network, with cell sizes ranging from 0.5 to 3 mm. Gas partial pressure changes recorded with either spongy material in the syringe were compared with those recorded in their absence.

The model served as a control for the system response time, and was used as a baseline against which the temporal bone results could be evaluated.

Bone Selection and Preparation. In view of the difficulty of performing such a study in vivo, we used 8 human temporal bones in various stages of preservation, categorized as dry, wet, or fresh, as described below. The structure of the MACS (aerated, diploic, or sclerotic) of each bone was analyzed with a Schuller position radiograph.

The 6 *dry* bones had been preserved in formaldehyde solution. Their soft tissues were removed with hypochloric sodium solution, and they were dried by being washed with alcohol. The external surfaces of these bones were then sealed with a coat of lacquer (collodion). Certain areas were also sealed with epoxy resin. Sealing was repeated until no leakage between the mastoid-ME cavity and the atmosphere could be detected. Leakage was tested by raising the pressure inside the bone and looking for a drift in pressure with time.

One *wet* bone, still lined with its internal mucous membrane, was used as a "pilot" for the fresh bone measurements, also taken under wet conditions. Free fluid was drained from a preserved bone, which was then sealed with a coating of silicone RTV (room temperature vulcanization).

One *fresh* temporal bone was taken from a cadaver 3 hours after death. (Access to human bones for research is very limited in Israel.) This bone was also sealed externally with silicone RTV, with no other treatment.

Bone Setup. A 2.5-mL syringe was connected to the external auditory canal (Fig 2) for the introduction of gas mixtures into the ME. Like the model, this syringe was also divided into 2 cells by a rigid partition, which had a relatively wide (5 mm) opening in it. Cell I (1 mL), distal to the bone, was set up similarly to that in the artificial model. Cell II was connected directly to the external auditory canal, with a wide (8 to 9 mm) opening. Therefore, when the partition was opened, cell I and the ME effectively became a single cavity. Thus, we regarded the diffusion rate between cell I and the tip of the mastoid as the same as that expected to occur between the ME and the mastoid.

TABLE 1. GAS DIFFUSION RATE CONSTANTS IN MODEL

Volume of Model	Without Cellular Material k (min^{-1})	Without Cellular Material $T_{1/2}$ (min)	With Cellular Material k (min^{-1})	With Cellular Material $T_{1/2}$ (min)
5 mL	0.42	1.6	0.41	1.6
10 mL	0.45	1.5	0.44	1.6
15 mL	0.46	1.5	0.49	1.4

Data are averages of 3 readings.
k — diffusion rate constant; $T_{1/2}$ — diffusion half-life.

Two openings 2 mm in diameter were drilled into the cortical bone adjacent to the mastoid tip (Fig 2A), through which the measuring probes of the mass spectrometer, the thermocouple, and the pressure transducer were inserted. Before each run, we checked the system for leakage by looking for pressure drift.

Diffusion Rate Measurement. The experiment was started by filling the mastoid, the ME, and cell II with gas, either N_2 or Ar. The partition between the cells in the syringe was then closed. Cell I was then flushed with O_2 (if cell II held N_2) or N_2 (if cell II contained Ar), following which the tubes were closed. At this stage, we had a closed system with 2 separate cavities: cell I with one gas; and the mastoid, ME, and cell II with another gas (O_2-N_2 or N_2-Ar). The next step was to use a magnet to open the partition between the cells, and record the rate and pattern of the gas composition changes with time. The diffusion process was followed from the opening of the partition until the gas concentrations reached a steady state, as measured at the tip of the mastoid.

The 2 gas combinations (O_2-N_2 and N_2-Ar) were chosen so that at the end of the diffusion process, the gas components would resemble those in the ME under normal conditions, and would be similar to the calibration gas concentrations — to increase the accuracy of readings of gas partial pressures.

In the O_2-N_2 combination, partial pressures of both gases were recorded. Therefore, data presented for O_2 are of its diffusion rate into N_2 and vice versa. In the N_2-Ar experiment, for technical reasons the mass spectrometer was calibrated only with Ar; therefore, only Ar concentrations were recorded.

Two other processes were used as controls. One was the response time of our measuring system. The probe of the spectrometer was inserted into a vessel of known gas composition (calibration gas), and partial pressure changes from room air levels were recorded until a plateau of calibrating gas composition had been reached. The second reference process, as mentioned, was the diffusion rate of gas in the artificial model.

Measuring Techniques. An Amis 2000 mass spectrometer (Innovision, Odense, Denmark) was used for gas composition measurements, at a sampling rate of 2×10^{-6} mL/s. The response time reported by the manufacturer is 20 to 40 seconds. The mass spectrometer was calibrated before and after each experiment.

Pressure and temperature readings were taken continuously. Pressure measurements were made with a Validyne DP-103 pressure transducer (accuracy 0.02%) and confirmed with a U-tube water manometer. Temperature was monitored with a copper-constantan thermocouple (Ellab, Copenhagen, Denmark; accurate to ±0.1°C).

Data Evaluation. The change of gas concentration with time had an exponential pattern, best described by a monoexponential equation: $C = C_\infty(1 - e^{kt}) + C_0$ where C is the concentration of the gas at a given time (t, in minutes), e is the natural logarithm, and k is the rate constant (in $minutes^{-1}$) in which we are interested. The half-life of this diffusion process, $T_{1/2}$, can be calculated as ln2/k.

The correlation r^2 between the measured data and the exponential fitted line was calculated with SIMFIT software (courtesy of Dr Bardeley, University of Manchester, England). Correlations of the rate constants of the different gases and the different types of bones were calculated by the Kruskal-Wallis nonparametric technique, using SAS software (SAS Institute, Inc, Cary, NC). A p value of <.05 was considered significant.

RESULTS

Gas Diffusion Rates in Model. The average gas diffusion rate constant (k) between the 2 cells in the model was 0.45 min^{-1} for all gases (Table 1). The average $T_{1/2}$ was 1.5 minutes. Neither varying the volume of the model nor the presence or absence of spongy material had any significant effect on the rate of equalization of gas composition.

Gas Diffusion Rates in Temporal Bones. Figure 3 shows the typical exponential shape of a recording of gas diffusion between the mastoid and the ME. The correlation constant, r^2, between measured data and those calculated from the exponential fitted line was .96 to .99 in the O_2-N_2 experiments and .92 to .99 in the N_2-Ar measurements (Table 2).

In the O_2-N_2 experiments, the gas diffusion rate constant for *oxygen* (k_{O_2}) in the 6 dry bones varied from 0.31 to 0.60 min^{-1}, with an average (±1 SD) of 0.40 ± 0.1 min^{-1} (Table 2). This gives an average $T_{1/2}$ of 1.80 ± 0.4 minutes, with a range of 1.1 to 2.2 minutes. The diffusion rate of the wet bone ($T_{1/2}$,

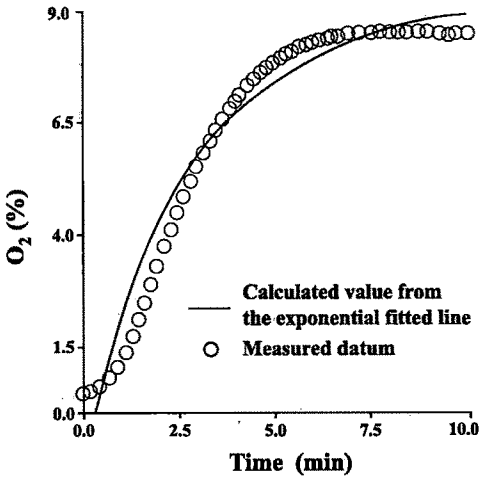

Fig 3. Diffusion rate. Typical recording, with exponential shape, of gas diffusion (oxygen, in this case) between middle ear and mastoid.

5.3 minutes), though somewhat slower, was not significantly different from that of the fresh or dry bones ($p > .05$).

With the exception of that for the fresh bone, the diffusion rate constants calculated for *nitrogen* were similar to those for O_2 in all O_2-N_2 experiments ($p > .05$). The slower N_2 diffusion rate constants of the wet ($T_{1/2}$, 4.1 minutes) and fresh ($T_{1/2}$, 2.8 minutes) bones did not differ significantly from the rates of the dry bones (average $T_{1/2}$, 1.95 ± 0.4 minutes; $p > .05$).

In the experiment of *argon* diffusing into N_2, k_{Ar} values were similar to those of O_2 into N_2. In the fresh bone, however, Ar, like N_2, had a slower diffusion rate, with a $T_{1/2}$ of 3.1 (2.8 for N_2), compared to 1.4 minutes for O_2.

Two of the dry bones had a sclerotic type of mastoid, whereas all 6 of the other bones had a well-developed MACS. This was demonstrated by imaging and verified when we drilled the openings in the bones for the measuring probes. One of the 2 sclerotic bones (No. 1) exhibited the fastest diffusion rates (Table 2).

No significant statistical difference was found between the k values of the dry aerated, dry sclerotic, wet, or fresh bones ($p > .05$), nor between k values of the various gases (O_2, N_2, and Ar).

Correction of the results for variations in temperature resulted in only minor changes, on the order of 0.1% or less.

Control Rates. The $T_{1/2}$ of the calibration measurements was 0.5 to 1.2 minutes, and averaged 1.5 minutes in the model.

DISCUSSION

The role of the MACS is not well understood. Possible functions include physical defense for the inner ear and the brain[7] and a resonance box for specific frequencies.[8] It is accepted that an association exists between a small MACS and the chronic otitis media syndrome,[9-12] and that there is a linkage between these various disease entities and negative pressure development in the ME-MACS.[1,5,10] Diffusion of gas between the ME cavity and the blood, like the introduction of gas through the eustachian tube, is a major factor in the pressure dynamics of the ME.[4-6,13]

We studied partial pressure distribution within the ME-MACS by measuring the rate at which gases diffuse between these 2 compartments. The question posed was, how will a change of partial pressure in one location affect that in a nearby location? For example, would a change in the diffusion proper-

TABLE 2. GAS DIFFUSION RATE CONSTANTS IN MIDDLE EAR–MASTOID AIR CELL SYSTEM

	Oxygen			*Nitrogen*			*Argon*		
	k (min^{-1})	$T_{1/2}$ (*min*)	r^2	*k* (min^{-1})	$T_{1/2}$ (*min*)	r^2	*k* (min^{-1})	$T_{1/2}$ (*min*)	r^2
Dry bones									
1*	0.60	1.1	.98	0.49	1.4	.96	0.80	0.8	.92
2	0.32	2.1	.97	0.32	2.1	.96	0.45	1.5	.99
3*	0.36	1.9	.98	0.34	2.0	.97	0.30	2.3	.96
4	0.36	1.9	.98	0.41	1.7	.97	0.32	2.1	.94
5	0.42	1.6	.98	0.37	1.9	.98	0.36	1.9	.98
6	0.31	2.2	.99	0.26	2.6	.97	0.24	2.8	.99
Average	0.40	1.80		0.37	1.95		0.41	1.90	
SD	0.1	0.4		0.1	0.4		0.2	0.6	
Wet bone	0.13	5.3	.99	0.17	4.1	.99	0.17	4.1	.99
Fresh bone	0.56	1.4	.99	0.25	2.8	.98	0.22	3.1	.99

Data are averages of 2 readings.

k — diffusion rate constant; $T_{1/2}$ — diffusion half-life; r^2 — correlation coefficient.

*Bones 1 and 3 were sclerotic; all others had aerated structure.

ties of the ME mucosal linings during infection affect the partial pressure in the mastoid? Our working hypothesis was that if a rapid diffusion rate were to be found, partial pressures throughout the ME-MACS would equalize rapidly after an upset in one part, resulting in the rapid reestablishment of a uniform gas composition throughout the system.

In the 6 dry bones, the $T_{1/2}$ for the diffusion of O_2 between the ME and the MACS ranged from 1.1 to 2.2 minutes. The $T_{1/2}$ for N_2 and Ar were similar (N_2, 1.4 to 2.6 minutes; Ar, 0.8 to 2.8 minutes). The wet bone had a slower diffusion rate ($T_{1/2}$, 5.3 minutes for O_2, 4.1 minutes for both N_2 and Ar). The fresh bone had a $T_{1/2}$ of 1.4, 2.8, and 3.1 minutes for O_2, N_2, and Ar, respectively. The slower rate in the wet bone can be explained by the solubility of these gases in water, which would slow the gas mixing process in the cavity (a chromatography-like effect). Even though the diffusion process in the wet bones was slower than in the dry bones, this difference was not statistically significant, and the overall picture is of a diffusion process with a $T_{1/2}$ on the order of only 2 to 3 minutes. Because of the small number of bones available to us, no conclusions could be drawn about the extent to which diffusion rates are affected by the volume or morphology of the bone.

Do the diffusion rates we have found hold any physiological or clinical significance? Of our 2 control measurements taken for comparison with the temporal bone results, the $T_{1/2}$ values ranged from 0.5 to 1.2 minutes (the response time of our measuring system) or averaged 1.5 minutes (the diffusion rate in the model). The averages of the $T_{1/2}$ values measured within the human ME-MACS were of a similar order.

On the basis of these results, it can be concluded that the diffusion process between the ME and the MACS is quick and within the range of the response time of our measuring system. Thus, no significant gas pressure differences are likely to build up between the ME and the MACS, and this system can therefore be regarded as 1 chamber with a homogeneous gas concentration.

Several conditions could produce a differential in gas partial pressures in various regions of the ME-MACS complex. These include inflammatory conditions, which may influence the rate of gas exchange between the ME cavity and the blood or partially obstruct the aditus, isolating the mastoid. A perforation in the tympanic membrane, either in cases of chronic otitis media or in the presence of a ventilating tube,[14] is another possibility. However, we could find no data in the literature indicating that differences in partial pressures of the gases in the ME-MACS occur. In view of the fast diffusion rates between the ME and the MACS that we found, we propose that if compositional differences in the gases within these cavities do occur, they can be expected to be transient and therefore have little or no clinical significance.

In our study, 6 of the 8 bones had no mucosal lining. Under physiological conditions, in the presence of a mucosal lining, the connections between the mastoid cells might be narrower and the diffusion rate slower. As the diffusion rates of fresh bones with intact mucosal membranes were not significantly slower than those of the dry bones, we suggest that the ME-MACS complex under in vivo conditions also has a uniform profile of gas partial pressures. However, because of the very limited number of fresh bones available to us, this point warrants further examination.

ACKNOWLEDGMENT — This paper was prepared with the assistance of Editorial Services, The Hospital for Sick Children, Toronto, Canada.

REFERENCES

1. Sadé J. The correlation of middle ear aeration with mastoid pneumatization. The mastoid as a pressure buffer. Eur Arch Otorhinolaryngol 1992;249:301-4.

2. Proud GO, Odoi H, Toledo PS. Bullar pressure changes in eustachian tube dysfunction. Ann Otol Rhinol Laryngol 1971; 80:835-7.

3. Andreasson L, Ivarsson A, Tjernström O. Eustachian tube function and pneumatization. Cholesteatoma and mastoid surgery. Proceedings 11th International Conference. Amsterdam, the Netherlands: Kugler Publications, 1982:201-9.

4. Buckingham RA, Stuart DR, Girgis SJ, Geick MR, McGee TJ. Experimental evidence against middle ear oxygen absorption. Laryngoscope 1985;95:435-42.

5. Richards SH, O'Neill G, Wilson F. Middle ear pressure variations during general anesthesia. J Laryngol Otol 1982;96: 883-92.

6. Hergils L, Magnuson B. Morning pressure in the middle ear. Arch Otolaryngol 1985;111:86-9.

7. Diamant M, Rubensohn G, Walander A. Otosalpingitis and mastoid pneumatisation. Acta Otolaryngol (Stockh) 1958; 49:381-8.

8. Tumarkin A. On the nature and vicissitudes of accessory air spaces of the middle ear. J Laryngol Otol 1957;71:65-99.

9. Flisberg K, Ingelstedt S, Ortegren U. The relationship of middle ear disease to mastoid hypocellularity. Acta Otolaryngol [Suppl] (Stockh) 1963(suppl 182):1-4.

10. Flisberg K, Zsigmond M. The size of the mastoid air cell system. Acta Otolaryngol (Stockh) 1964;60:23-9.

11. Lindeman P, Shea J. Size of the mastoid air cell system in children with middle ear effusion. Laryngoscope 1980;90: 1840-4.

12. Sederberg-Olsen JF, Sederberg-Olsen AM, Jensen AM. The prognostic significance of the air volume in the middle ear

for the tendency to recurrence of secretory middle ear condition. Int J Pediatr Otorhinolaryngol 1983;5:179-87.

13. Tideholm B, Jonsson S, Carlborg B, Welinder R, Grenner J. Continuous 24-hour measurement of middle ear pressure. Acta Otolaryngol (Stockh) 1996;116:581-8.

14. Felding JU, Rasmussen JB, Lildholt T. Gas composition of the normal and ventilated middle ear cavity. Scand J Clin Lab Invest Suppl 1987(suppl 186):31-41.

≈

XVI IBERO-AMERICAN CONGRESS OF NEUROLOGY

The XVI Ibero-American Congress of Neurology will be held in Rosario, Argentina, April 16-19, 2000. For information, contact Soledad Piuma, Congresos Internacionales, Moreno 584, 9P, Buenos Aires, Argentina; fax 54 11 3310223; e-mail spiuma@congresosint.com.ar.

INFLAMMATORY RESPONSE TO CHRONIC OTITIS MEDIA IN DiGEORGE SYNDROME: A CASE STUDY USING IMMUNOHISTOCHEMISTRY ON ARCHIVAL TEMPORAL BONE SECTIONS

TETSUYA GANBO, MD, DMSc
TOKYO, JAPAN

ISAMU SANDO, MD, DMSc
PITTSBURGH, PENNSYLVANIA

CAREY D. BALABAN, PhD
PITTSBURGH, PENNSYLVANIA

CHIAKI SUZUKI, MD, DMSc
PITTSBURGH, PENNSYLVANIA

MIWA KITAGAWA, MD
PITTSBURGH, PENNSYLVANIA

Immunohistochemical analyses were conducted on archival celloidin-embedded human temporal bone sections from an 8-month-old boy with chronic otitis media and DiGeorge syndrome. We employed antigen retrieval methods with saturated sodium hydroxide–methanol solution, microwave incubation, and proteolytic treatment to demonstrate the distribution of T-lymphocytes, B-lymphocytes, macrophages, and intercellular adhesion molecule 1 (ICAM-1) expression in the middle ear. B-lymphocytes and macrophages were observed predominantly within the middle ear mucosa. T-lymphocytes were rare. Further, ICAM-1 was expressed in the vascular endothelium of the lamina propria, as well as infiltrating mononuclear cells. This suggests that the expression of ICAM-1 can be induced in the middle ear with otitis media, even if T-lymphocytes are depressed in a cell-mediated immunodeficiency disorder such as DiGeorge syndrome.

KEY WORDS — DiGeorge syndrome, inflammation, intercellular adhesion molecule 1, lymphocyte, macrophage, otitis media.

INTRODUCTION

DiGeorge syndrome (also termed pharyngeal pouch syndrome or thymic aplasia or hypoplasia) is a congenital developmental anomaly of the third and fourth pharyngeal pouches. Recent evidence suggests that these developmental malformations are associated with microdeletion of a 250 kilobase critical region of 22q11, N25 (in the vicinity of D22S75)[1]; deletions of 10p (at the 10p13/10p14 boundary) have also been implicated in these individuals.[2] DiGeorge syndrome is characterized by hypoplasia or aplasia of the thymus and parathyroid glands, and is often associated with malformations of the great vessels, congenital heart disease, and esophageal atresia.[3,4] In addition, there is also a tendency for hypertelorism, a short philtrum, an antimongoloid slant of the eyes, a bifid uvula, and low-set, often notched ears.[5-7] The degree of immunodeficiency and the susceptibility to hypocalcemic seizures appear to reflect the degree of thymic and parathyroid hypoplasia in each patient.[3,4] Further, temporal bone histopathologic studies have revealed cochlear malformations, which were observed in the present case (Fig 1), and vestibular system anomalies, as well as an anomalous facial nerve course.[8-12]

We recently described the distribution of T-lymphocytes, B-lymphocytes, and macrophages in the middle ear of a patient with normal immune function and acute otitis media.[13] Patients with DiGeorge syndrome, though, are susceptible to viral and bac-

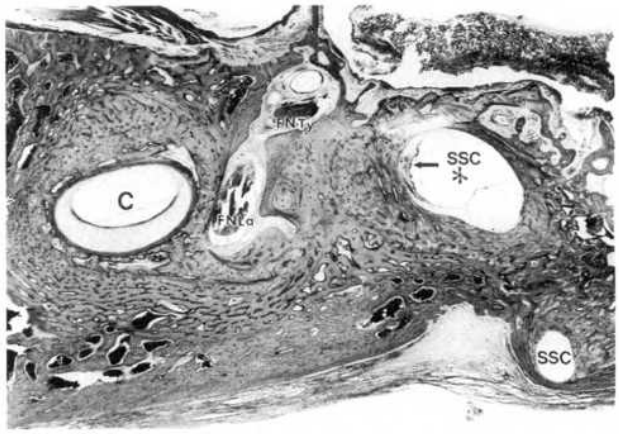

Fig 1. Right temporal bone demonstrating hypoplastic cristae and ampulla of superior semicircular canal. Also note obtuse angle formed by first genu portion of facial nerve. C — cochlea, FNLa — labyrinthine portion of facial nerve, FNTy — tympanic portion of facial nerve, SSC — superior semicircular canal, asterisk — enlarged ampulla, arrow — dislocated and distorted crista.

From the Elizabeth McCullough Knowles Otopathology Laboratory, Division of Otopathology, Department of Otolaryngology, University of Pittsburgh School of Medicine, Pittsburgh, Pennsylvania. Dr Ganbo is currently at 3-22-17, Shibakubo, Tanashi, Tokyo 188-0014, Japan.

CORRESPONDENCE — Isamu Sando, MD, DMSc, University of Pittsburgh School of Medicine, Dept of Otolaryngology, Eye and Ear Institute Building, 203 Lothrop St, Room 153, Pittsburgh, PA 15213.

HEMATOLOGY

		Normal Reference Values
Basic blood		
Red blood cells ($\times 10^{12}$/L)	5.90	3.60-5.20
White blood cells ($\times 10^{9}$/L)	11.0	5.5-18.0
Neutrophils (%)	45	20-46
Lymphocytes (%)	37	41-71
Monocytes (%)	12	3-9
Eosinophils (%)	0	0-3
Basophils (%)	0	0-2
Atypical lymphocytes (%)	6	0-2
Histocompatibility		
T-lymphocytes (T cells) (%)	<27	53-83
Suppressor T cells (CD8) (%)	19	17-41
Helper T cells (CD4) (%)	18	26-58
Helper/suppressor ratio	0.95	0.80-3.00
B-lymphocytes (%)	>53	3-22
Natural killer cells (%)	20	

On phytohemagglutinin test, T-lymphocyte function was remarkably reduced.

terial infections, because the contribution of T-lymphocytes to immune responses is depressed. Although the number of peripheral white blood cells is within normal limits, there is a decreased number of T-lymphocytes (with a normal ratio of helper to suppressor cells) and an increased number of B-lymphocytes.[6,7] This study examined the response of T-lymphocytes, B-lymphocytes, macrophages, and intercellular adhesion molecule 1 (ICAM-1) expression in the middle ear mucosa of a patient with otitis media and DiGeorge syndrome.

MATERIALS AND METHODS

Temporal Bone Sections. We used sections from the temporal bones of an 8-month-old boy with DiGeorge syndrome who had a hypoplastic inner ear and an abnormal course of the facial nerve (Fig 1), and had been suffering from otitis media when he died of congenital cardiac disease. The hematologic data are presented in the Table. The temporal bone specimens were obtained 5 hours after death. They were fixed in 10% formalin, decalcified by 5% trichloroacetic acid treatment, embedded in celloidin, and sectioned at 30 μm in thickness as described previously by Sando et al.[14] Every 10th temporal bone section (TBS) was stained by hematoxylin and eosin (H & E). Archival unstained TBSs preserved in 80% ethanol for 4 years were used for this immunohistochemical study.

Primary Antibodies. The rabbit polyclonal antibody against human CD3 (T-lymphocyte) and mouse monoclonal antibodies against human CD20 (B-lymphocyte, clone L26) and CD68 (macrophage-monocyte, PG-M1) were obtained from Dako (Carpinteria, Calif). Primary antibodies were diluted to 1:50 with phosphate-buffered saline (PBS) including 1% bovine serum albumin (BSA) and 0.1% Triton X-100 (Sigma, St Louis, Mo). A mouse monoclonal antibody specific for human CD54 (ICAM-1; clone MAB2130, Chemicon International Inc, Temecula, Calif) was used at a dilution of 1:20 in the PBS-BSA–Triton X-100 solution.

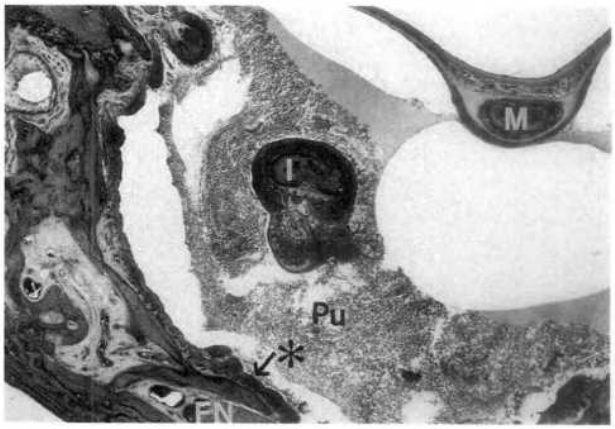

Fig 2. Horizontal section of left temporal bone (H & E, original ×23). Purulent effusion (Pu) was present in tympanic cavity. Mucosa was also thickened and invaded by inflammatory mononuclear cells. Asterisk — area referred to in Fig 4A, Pu — purulent effusion, M — malleus, I — incus, FN — facial nerve.

Antigen Retrieval. The TBSs were soaked in distilled water for 60 minutes and then mounted on gelatin-coated glass slides. They were incubated in the antigen retrieval solution (saturated sodium hydroxide–methanol solution in methanol at a ratio of 1:3) for 30 minutes at room temperature,[15] and then rinsed twice in methanol, 70% methanol, and PBS, respectively. Microwave antigen recovery was also used for CD3 and CD54. The TBSs were incubated with 1-mmol/L ethylenediaminetetraacetic acid (pH 6.0, Sigma) in a microwave oven (H2500, Energy Beam Science, Agawan, Mass) at 60°C for 5 minutes. Proteolytic treatment with 0.1% trypsin (pH 7.8, Sigma) containing 0.1% calcium chloride (Sigma) was also performed for identifying CD68.[13]

IMMUNOHISTOCHEMISTRY

Endogenous peroxidase was inactivated by incubation with 3% hydrogen peroxide for 20 minutes. Nonspecific antigen binding was also inhibited by incubation with blocking solution containing 2% nonfat dry milk, 2% normal horse or goat serum, and 0.1% Triton X-100 (Sigma) for 30 minutes at room temperature. The sections were first incubated with the primary antibody at 4°C overnight, and then with the secondary antibody for 1 hour at room temperature. Biotinylated secondary antibody (horse anti-mouse for detecting monoclonal primary anti-

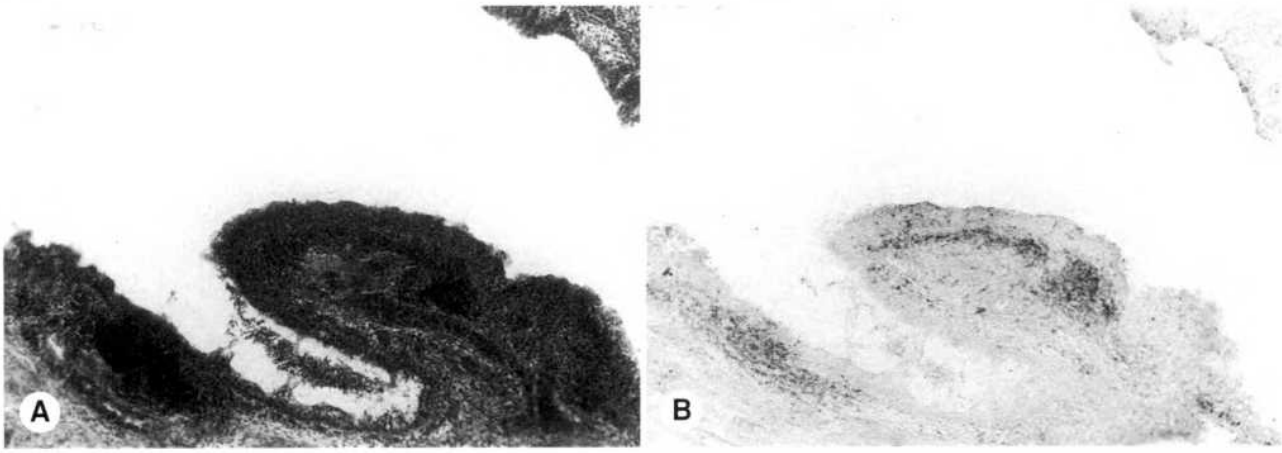

Fig 3. Inflammation of middle ear mucosa. A) Mucosa near tympanic sinus (H & E, original ×115). Large number of inflammatory mononuclear cells was observed within thickened mucosa. B) CD20-positive cells in section adjacent to A (original ×115). These cells lie within accumulation of infiltrating mononuclear cells in A.

body or goat anti-rabbit for detecting polyclonal primary antibody; Vector Laboratories Inc, Burlingame, Calif) was used at a dilution of 1:200 secondary antibody–PBS including 1% BSA. After rinsing in PBS, the tissue was incubated with avidin-biotin-peroxidase complex (Vectastain Elite ABC, Vector Laboratories Inc) for 45 minutes at room temperature and then reacted with 0.02% 3,3'-diaminobenzidine · 4-hydrochloric acid in 4% sodium acetate, plus 0.003% hydrogen peroxide. Sections were dehydrated in a graded series of 70%, 95%, and 100% ethanol, cleaned in xylene, and coverslipped with Permount.

Normal goat and horse sera were substituted for primary antibodies as negative controls, and paraffin-embedded tonsil sections served as positive controls.

RESULTS

Purulent effusion was present in the eustachian tube lumen, tympanic cavity (Fig 2), and mastoid air cells. The effusion contained predominantly neutrophils with a lesser contribution of lymphocytes and macrophages. A cell-poor, amorphous component was also present.

The mucosa of the tympanic cavity (Figs 2, 3A, and 4A) and the eustachian tube was thickened. The mucosa showed evidence of a prominent mononuclear cell infiltration, which contained many CD20-immunoreactive (Figs 3B and 4B) and very few CD3-immunoreactive (Fig 4C) lymphocytes. In addition, triangular CD68-immunopositive cells were distributed diffusely within the mucosa of the tympanic cavity (Fig 5), as well as the eustachian tube and mastoid. A few round cells were also positive for CD68. Although the mucosa of the mastoid air cells was edematous, it contained fewer inflammatory cells than the other regions of the middle ear cavity.

The lamina propria of the eustachian tube and tympanic cavity also contained cells that displayed CD54 immunoreactivity; the vascular endothelium (Fig 6A, B) showed prominent CD54 immunostaining, and CD54-immunoreactive mononuclear cells were also observed (Fig 6C). Negative controls showed no CD54 reaction (Fig 6D).

DISCUSSION

Palva et al[16] reported that the infiltrating mononuclear cells in the middle ear mucosa of chronic otitis media with effusion are predominantly T-lymphocytes in patients with normal immune function. This also appears to be true in acute otitis media.[13] This patient with DiGeorge syndrome had slightly reduced lymphocyte counts in the peripheral blood. However, the number of T-lymphocytes was depressed significantly, and the number of B-lymphocytes was elevated considerably. Further, a phytohemagglutinin test demonstrated that T-lymphocyte function was reduced markedly (see Table). The distribution of infiltrating lymphocytes in the middle ear mucosa was consistent with hematologic test results. There was an invasion of predominantly CD20-positive cells (putative B-lymphocytes) in the mucosa of the middle ear. Only scattered CD3-positive cells (putative T-lymphocytes) were present. This is in stark contrast to the dominant T-lymphocyte response in cases of both acute and chronic otitis media.[13,16] Moreover, a large number of triangular CD68-positive cells (putative macrophages) were also observed in the effusion and in the mucosa of the eustachian tube, tympanic cavity, and mastoid air cells. Thus, it is possible that an enhanced infiltration of B-lymphocytes and macrophages into the mucosa compensates for reduced immunity mediated by T-lymphocytes.

Adhesion molecules, particularly ICAM-1, play

Fig 4. Inflammation in mucosa near tympanic portion of facial canal. A) High-magnification view of mucosa near facial canal noted by asterisk in Fig 2 (H & E, original ×230). B) CD20-positive cells within mucosa in section adjacent to A (original ×230). C) CD3-positive cells (arrows) scattered within mucosa in section adjacent to A (original ×460).

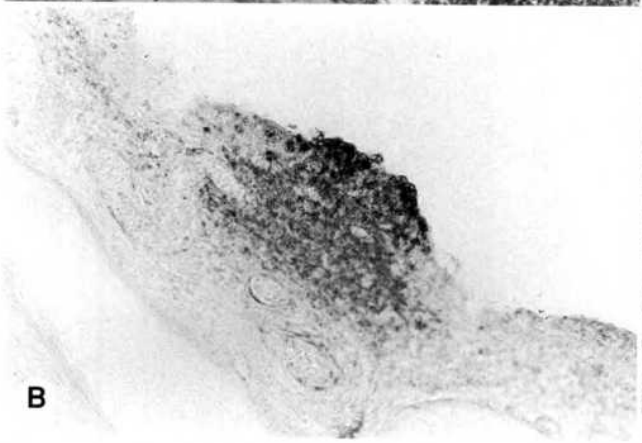

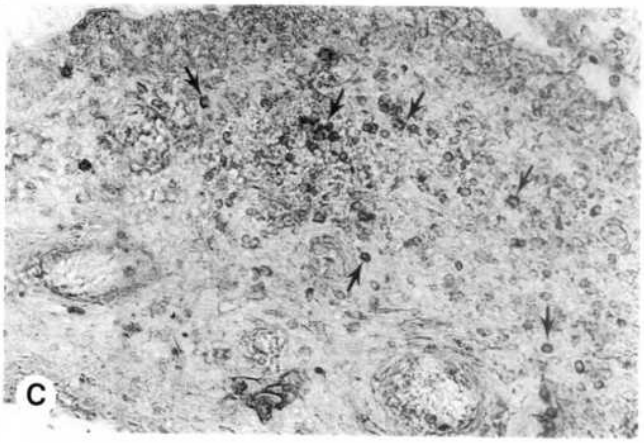

important roles in intercellular interactions when leukocytes adhere and transmigrate to an inflammatory focus. Intercellular adhesion molecule 1 belongs to the immunoglobulin supergene family and acts as a ligand for leukocyte function–associated antigen 1 (LFA-1) and integrin corresponding to the b2 group (Mac-1).[17] Both Himi et al[18] and Ganbo et al[19] have detected soluble ICAM-1 in the effusion of human otitis media cases. Okamoto et al[20] also found messenger RNA for ICAM-1 in human middle ear mucosal organ culture infected in vitro with respiratory syncytial virus. However, our case is the first demonstration that ICAM-1 is distributed in the vascular endothelium and the infiltrating mononuclear cells in the middle ear mucosa of a patient with otitis media.

The cellular pattern of ICAM-1 in this case with DiGeorge syndrome was similar to the pattern in a preliminary study of 2 control cases with otitis me-

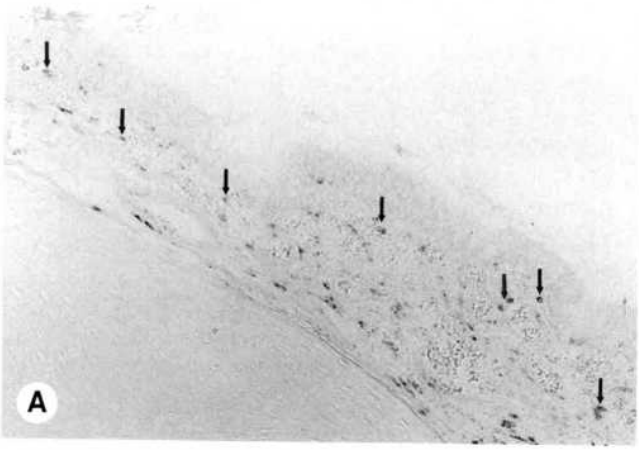

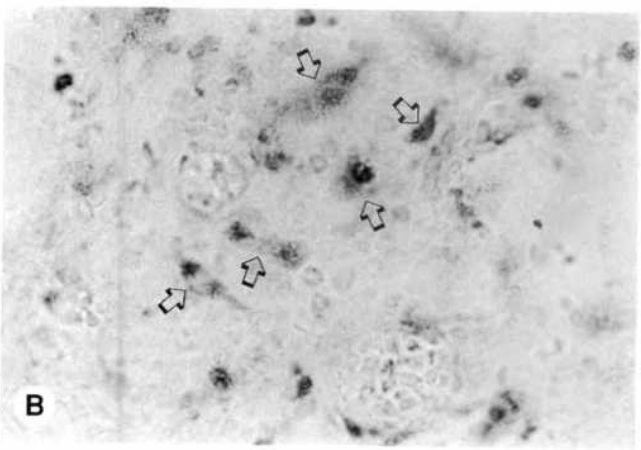

Fig 5. Inflammation in mucosa of tympanic cavity. A) CD68-positive cells (arrows) are distinguished diffusely within mucosa in section adjacent to Fig 4A (original ×230). B) High-magnification view of CD68-positive cells (original ×607). Many cells show characteristic morphology of macrophages (arrows).

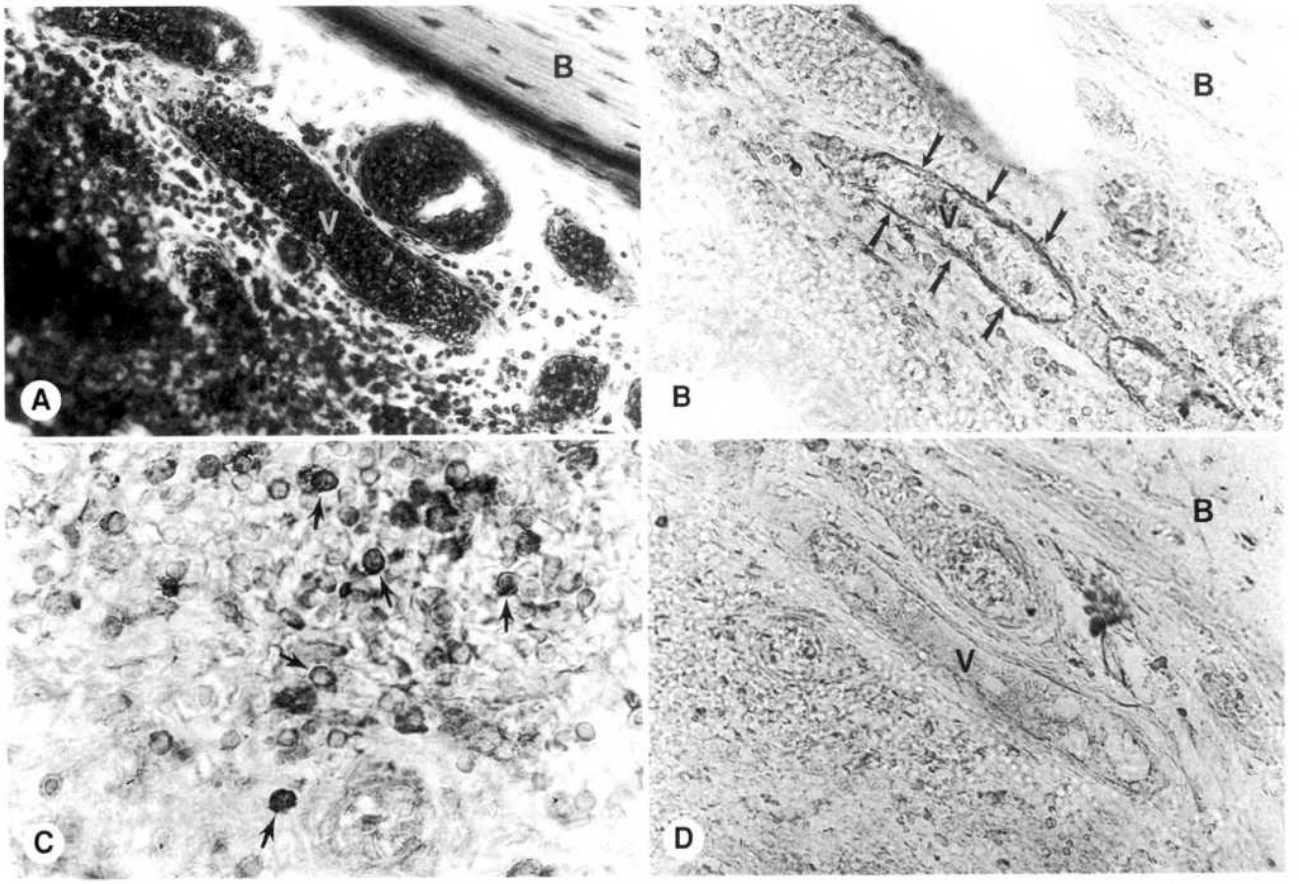

Fig 6. Vessels (V) in middle ear mucosa. A) Vessel with infiltrating mononuclear cells in lamina propria of tympanic cavity mucosa (H & E, original ×460). B — bone. B) CD54-immunopositive reaction was observed in endothelium of vessel (arrows) in section adjacent to A (original ×460). C) High-power view of B (original ×1,150). Inflammatory mononuclear cells (arrows) in lamina propria around blood vessel showed CD54-positive reactions. D) Negative control section to compare to B (original ×460). Note absence of CD54 immunoreactivity in vascular endothelium.

dia but normal immune function (7-month-old and 1-year-old girls). In these cases, both the vascular endothelium of the lamina propria and infiltrating monocytes showed CD54-positive reactions. Unlike in the DiGeorge syndrome case, the majority of these infiltrating monocytes appeared to be CD3-positive. Thus, the cellular distribution of ICAM-1 in chronic otitis media appeared to be independent of the relative proportions of CD3- and CD20-immunopositive lymphocytes within the middle ear mucosa.

A plethora of potential mechanisms could interact to produce a common pattern of ICAM-1 expression during otitis media in control specimens and DiGeorge syndrome. Previous immunohistochemical studies indicate that ICAM-1 can be expressed by a variety of cell types, including endothelial and epithelial cells, lymphocytes, macrophages, fibroblast-like cells, and follicular dendritic cells. Expression of ICAM-1 by these cell types is regulated by factors that include tumor necrosis factor α (TNFα), interferon-γ (INF-γ), interleukin-1, thrombin, and endothelins 1-3. Hence, it is plausible that ICAM-1 expression could be regulated in the lamina propria during otitis media by mechanisms that include 1) T-lymphocyte production of IFN-γ,[21] 2) macrophage production of IFN-γ, TNFα, and interleukin-1,[22,23] and 3) B cell secretion of interleukin-1.[24] Our observation suggests that these types of mechanisms are sufficient to produce the normal pattern of ICAM-1 expression in the middle ear mucosa of a patient with DiGeorge syndrome.

ACKNOWLEDGMENTS — The authors express deep gratitude to Eugene N. Myers, MD, Professor and Chairman, Charles D. Bluestone, MD, Professor and Director of Pediatric Otolaryngology, and Jonas Johnson, MD, Professor and Vice-Chairman, Department of Otolaryngology, University of Pittsburgh School of Medicine, for their encouragement to study this subject.

REFERENCES

1. Gong W, Emanuel BS, Collins J, et al. A transcriptional map of the DiGeorge and velo-cardio-facial syndrome minimal critical region on 22q11. Hum Mol Genet 1996;5:789-800.

2. Daw SC, Taylor C, Kraman M, et al. A common region of 10p deleted in DiGeorge and velocardiofacial syndromes. Nat Genet 1996;13:458-60.

3. DiGeorge AM. Discussion of Cooper MD, Peterson RDA, Good RA. A new concept of the cellular basis of immunity. J

Pediatr 1965;67:907-8.

4. Harvey JC, Dungan WT, Elders MJ, Hughes ER. Third and fourth pharyngeal pouch syndrome, associated vascular anomalies and hypocalcemic seizures. Clin Pediatr (Phila) 1970; 9:496-9.

5. Kretschmer R, Say B, Brown D, Rosen FS. Congenital aplasia of the thymus gland (DiGeorge's syndrome). N Engl J Med 1968;279:1295-301.

6. Cooper MD, Buckley RH. Developmental immunology and the immunodeficiency diseases. JAMA 1982;248:2658-69.

7. Buckley RH. Immunodeficiency. J Allergy Clin Immunol 1983;72:627-41.

8. Adkins WY, Gussen R. Temporal bone findings in the third and fourth pharyngeal pouch (DiGeorge) syndrome. Arch Otolaryngol 1974;100:206-8.

9. Black FO, Spanier SS, Kohut RI. Aural abnormalities in partial DiGeorge syndrome. Arch Otolaryngol 1975;101:129-34.

10. Weinberg AG. Stapedial hypoplasia in partial DiGeorge's syndrome. Am J Dis Child 1978;132:815-6.

11. Schuknecht HF. Mondini dysplasia. A clinical and pathological study. Ann Otol Rhinol Laryngol Suppl 1980;89(suppl 65).

12. Ohtani I, Schuknecht HF. Temporal bone pathology in DiGeorge's syndrome. Ann Otol Rhinol Laryngol 1984;93:220-4.

13. Ganbo T, Sando I, Balaban CD, Suzuki C, Sudo M. Immunohistochemistry of lymphocytes and macrophages in human cellodin-embedded temporal bone sections with acute otitis media. Ann Otol Rhinol Laryngol 1997;106:662-8.

14. Sando I, Doyle WJ, Okuno H, Takahara T, Kitajiri M, Coury WJ III. A method for the histopathological analysis of the temporal bone and the eustachian tube and its accessory structures. Ann Otol Rhinol Laryngol 1986;95:267-74.

15. Shi S, Cot ÄC, Kalra KL, Taylor CR, Tandon AK. A technique for retrieving antigens in formalin-fixed, routinely acid-decalcified, celloidin-embedded human temporal bone sections for immunohistochemistry. J Histochem Cytochem 1992;40: 787-92.

16. Palva T, Taskinen E, Hayry P, Bernstein JM. Inflammatory cell subpopulations in secretory otitis media. In: Bernstein JM, Ogra PL, eds. Immunology of the ear. New York, NY: Raven Press, 1987:301-17.

17. Carlos TM, Harlan JM. Leukocyte-endothelial adhesion molecules. Blood 1994;84:2068-101.

18. Himi T, Kamimura M, Kataura A, Imai K. Quantitative analysis of soluble cell adhesion molecule in otitis media with effusion. Acta Otolaryngol (Stockh) 1994;114:285-8.

19. Ganbo T, Hisamatsu K, Inoue H, Kikushima K, Mizukoshi A, Murakami Y. Detection of soluble interleukin-2 receptor and soluble intercellular adhesion molecule–1 in the effusion of otitis media with effusion. Mediators Inflamm 1995;4: 350-4.

20. Okamoto Y, Kudo K, Ishikawa K, et al. Presence of respiratory syncytial virus genomic sequences in middle ear fluid and its relationship to expression of cytokines and cell adhesion molecules. J Infect Dis 1993;168:1277-81.

21. Gifford GE, Lohmann-Matthes ML. Gamma interferon priming of mouse and human macrophages for induction of tumor necrosis factor production by bacterial lipopolysaccharide. J Natl Cancer Inst 1987;78:121-4.

22. Burchett SK, Weaver WM, Westall JA, Larsen A, Kronheim S, Wilson CB. Regulation of tumor necrosis factor/cachectin and IL-1 secretion in human mononuclear phagocytes. J Immunol 1988;140:3473-81.

23. Fleit HB, Rabinovitch M. Interferon induction in marrow-derived macrophages: regulation by L cell conditioned medium. J Cell Physiol 1981;108:347-52.

24. Bonnefoy J, Denoroy M, Guillot O, Martens CL, Banchereau J. Activation of normal human B cells through their antigen receptor induces membrane expression of IL-1α and secretion of IL-1ß. J Immunol 1989;143:864-9.

MUCIN GENE EXPRESSION IN THE RAT MIDDLE EAR: AN IMPROVED METHOD FOR RNA HARVEST

JIZHEN LIN, MD

SAMUEL HO, MD
LAURIE SHEKELS, PHD
MICHAEL M. PAPARELLA, MD
YOUNGKI KIM, MD

MINNEAPOLIS, MINNESOTA

Mucins are heavily glycosylated proteins characterized by high molecular weight and heterogeneous structure. Mucin genes are expressed in a tissue- or epithelium-specific manner. Although mucins are known to be important structural components of the mucociliary transport system that protects epithelium against invading microorganisms, very little is known about mucin gene expression unique to the middle ear. This study demonstrated that middle ear messenger RNA specifically hybridized with rat MUC2 and human MUC2 (SMUC-41) complementary DNA probes. MUC3 and MUC5AC mucin genes, dominantly expressed in rodent intestine and trachea, were not detected in the rat middle ears in this study. The middle ear MUC2 messenger RNA harvested by lavage was characterized by a single transcript — unlike its counterpart in intestine and airways, which is characterized by polydispersity — suggestive of a better method for RNA analysis. It was concluded that rat middle ears possess a MUC2 mucin gene or homologue of human MUC2 (SMUC-41).

KEY WORDS — middle ear epithelial cells, MUC2 mucin gene, Sprague-Dawley rats.

INTRODUCTION

Mucins, which line the cell surfaces of the mucosa of the respiratory, gastrointestinal, and urogenital tracts, are capable of protecting epithelia due to their unique biological structure.[1] In the middle ear, mucins are important structural components of the mucociliary transport system, which is responsible for clearance of invading microorganisms, air-borne substances, and middle ear debris. Since mucins are able to bind to proteins in the outer membrane of bacteria,[2,3] they play an essential role in the defense of the epithelium against invading pathogens.

Mucins are large, heterogeneous, and highly glycosylated proteins whose approximate mass (molecular weight) ranges from 200 to 400 kd. One of the characteristic features of mucin is its abundance of oligosaccharides. The oligosaccharides, which selectively attach to serine and threonine residues of mucin backbone (apomucin), are involved in cell-cell recognition, interaction, and adhesion.[4,5] Biochemical analysis of mucins has demonstrated heterogeneity of molecules from various sources of epithelia,[6,7] suggestive of the existence of multiple mucin proteins. To date, at least 9 distinct mucin genes that encode various mucin proteins of the body have been identified and designated as MUC1, MUC2, MUC3, MUC4, MUC5AC, MUC5B, MUC6, MUC7, and MUC8.[1,8-13] All MUCs are secreted or soluble mucins, except for MUC1 and MUC3.

Characteristic of all mucin proteins are the repetitive units in the central region of the molecule, called tandem repeats (Fig 1[1]). The length and sequence of the tandem repeat is unique to each mucin, a molecular marker that distinguishes one mucin from another. Tandem repeats contain a high percentage of serine and threonine residues that serve as scaffolds for the attachment of carbohydrate side chains. Linkage between amino acid residues and carbohydrate side chains occurs at the hydroxyl group of serines and/or threonines, biochemically termed *O*-glycosylation. Mucins are so heavily glycosylated at the tandem repeat units that carbohydrates outweigh proteins (dry weight) at an approximate ratio of 3 to 1. This extreme glycosylation shields the mucin backbone, enhancing its resistance to enzymatic digestion.

A distinct feature of soluble mucins, unlike membrane-bound mucin protein, is the end-to-end linkage by disulfide bonds between mucin monomers (Fig 2). Oligomerization of mucin proteins creates huge–molecular weight proteins that are viscous in

From the University of Minnesota Otitis Media Research Center, Departments of Otolaryngology (Lin, Paparella) and Pediatrics (Kim), University of Minnesota School of Medicine, and the Department of Medicine, Veterans Administration Medical Center (Ho, Shekels), Minneapolis, Minnesota. Supported in part by grant P01 DC00133 from the National Institutes of Health/National Institute on Deafness and Other Communication Disorders, and by the Vikings Children's Fund. This study was performed in accordance with the PHS Policy on Humane Care and Use of Laboratory Animals, the NIH *Guide for the Care and Use of Laboratory Animals*, and the Animal Welfare Act (7 U.S.C. et seq.); the animal use protocol was approved by the Institutional Animal Care and Use Committee (IACUC) of the University of Minnesota.

CORRESPONDENCE — Jizhen Lin, MD, Lions Research Building, Room 212, 2001 Sixth Street SE, Dept of Otolaryngology, University of Minnesota, Minneapolis, MN 55455.

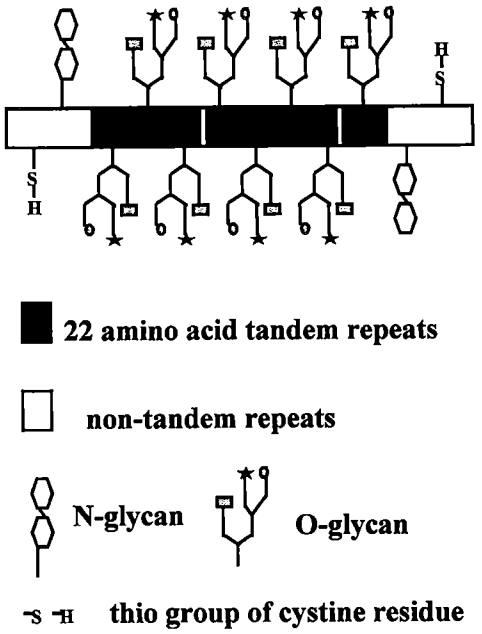

Fig 1. Molecular model of biological structure of rat MUC2 mucin, based on literature.[1] Tandem repeat units (22 amino acids per unit), flanked by nontandem repeat regions at both ends, are rich in threonine, serine, and proline residues that provide scaffolds for attachment of *O*-glycans. Nontandem repeat areas contain cysteine residues, which provide thio groups for formation of disulfide bonds linked end-to-end between MUC2 mucin monomers. Nontandem repeat areas are believed to contain *N*-glycans. Glycans, especially *O*-glycans, are involved in cell-cell recognition, adherence, and interaction.

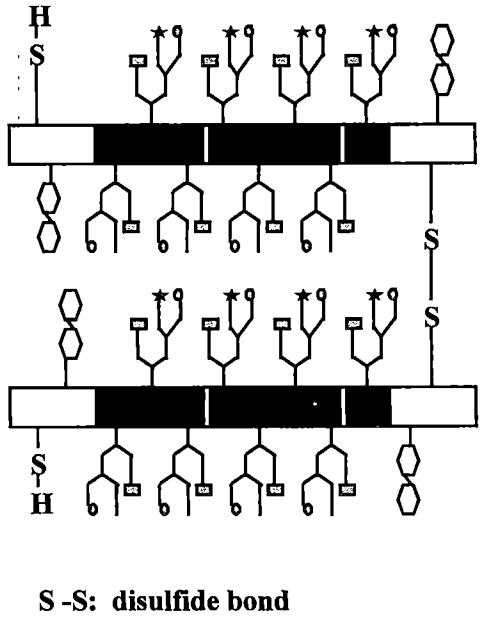

Fig 2. Biological model of rat MUC2 mucin polymers. MUC2 mucin monomers, linked by disulfide bonds in end-to-end manner, form mucin polymers of high molecular weight that are highly viscous in nature and facilitate entrapment of microorganisms and other substances.

nature. The linkage occurs between the thio groups of cysteine residues located within the carboxyl and amino terminals of the molecule. Formation of the disulfide bond is believed to occur in the rough endoplasmic reticulum.[14]

Due to the variability in the glycosylation process and polymerization pattern, mucins are polymorphic and heterogeneous.[15,16] Due to organ- or epithelium-specific activation and inactivation of redundant mucin genomic genes, the pattern of mucin expression within a given epithelium is unique. In other words, each type of epithelium possesses its own set of mucins. For example, in rodents, gastric epithelium expresses MUC5AC and MUC6. Intestinal epithelium expresses MUC2 and MUC3, while tracheal epithelium expresses MUC5AC and MUC2.

The expression of mucin gene(s) unique to the middle ear is unknown at the present time. Because mucin is known to play a role in the mucociliary transport system and is important in the protection of middle ear epithelium, identification of the mucin(s) in the middle ear would provide a molecular basis for study of mucin metabolism. Understanding mucin metabolism under physiological conditions and how it is altered under pathological circumstances is key to understanding middle ear diseases characterized by disturbances in the mucin metabolism. This study was conducted to characterize mucin gene expression in the middle ear of the rat by using known mucin nucleic acid probes MUC2,[1,8] MUC3,[11] and MUC5AC,[9] the major mucins of the airway and gastrointestinal tract of rodents.

MATERIALS AND METHODS

Harvest of Middle Ear Mucosa by Lavage. Sprague-Dawley rats were used as donors for middle ear epithelial cells. Ten specific germ–free rats weighing 200 to 250 g were used for this study. After anesthesia with ketamine hydrochloride (40 mg/kg), the tympanic membranes of the rats were examined under the operating microscope to confirm that the middle ears were free of infection. Bullae were removed immediately after sacrifice by decapitation. An opening was made at the bottom of the bulla to allow access to the middle ear cavity. The middle ear mucosa was washed 3 times with an ice-cold RNase inhibitor solution (40 U/mL) to prevent RNA degradation in vitro. Fifty to 75 μL of ice-cold 4-mol/L guanidinium isothiocyanate (Promega, Madison, Wis) was then inoculated into the middle ear cavity for 10 seconds to lyse the middle ear epithelial cells. This was repeated 3 times before the lysate was aspirated, pooled, and placed on ice. After harvest of the middle ear epithelial cells, total RNA was isolated by the 1-step method of Chomczynski and Sacchi.[17] Fifty microliters of 3-mol/L ice-cold sodium

acetate (pH 5.2) was added. Five hundred microliters of the lysate and 500 μL of ice-cold phenol/chloroform/ethanol (245:49:1) mixture were added to the lysate for 15 minutes on ice, and then the mixture was centrifuged at 11,900*g* for 20 minutes. The aqueous phase was transferred to a new microtube, 500 μL of isopropyl alcohol was added, and the mixture was allowed to precipitate at –20°C overnight. For positive controls, rat intestinal and tracheal tissues (approximately 300 mg) were harvested and total RNA was isolated by the conventional method.[17] Cultured fibroblasts from human skin were used as negative controls.

Northern Analysis of Steady-State mRNA. To study mucin gene expression in the middle ear epithelial cells of rats, we performed Northern analysis of steady-state messenger RNA (mRNA) as described by Sambrook et al.[18] Briefly, total RNA was quantitated by spectrophotometry at 260 nm. Rat middle ear, intestine, trachea, and human skin fibroblast total RNAs (20 μg each) were loaded onto a 1.0% agarose gel containing 2.2-mol/L formaldehyde, and size-separated by electrophoresis at 100 V for 3.5 hours. Following electrophoresis, 28S and 18S RNA bands were stained with ethidium bromide (0.5 μg/mL) and photographed to verify the integrity of the RNA samples. All RNAs on the gel were transferred onto a nylon membrane with 10 × SSC (sodium chloride and sodium citrate, pH 7.0) buffer on a pressure blotter (Stratagene, La Jolla, Calif). Following transfer, blots were immobilized by cross-linking under ultraviolet light.

Blots were hybridized at 65°C for 2 hours with hybridization buffer containing ^{32}P-radiolabeled rat MUC2 mucin complementary DNA (cDNA) probes with a radioactivity of 2×10^6 cpm/mL and washed under stringent conditions (1 × SSC and 0.1% sodium dodecyl sulfate [SDS] at 65°C for 15 minutes, followed by 0.2 × SSC and 0.1% SDS at 65°C for another 15 minutes) to eliminate nonspecific hybridization signals. The blots were exposed to Kodak XAR film at –80°C for 2 days. The film was developed to show hybridization signals. The blots were stripped with 0.1% SDS solution at 95°C for 30 minutes and reprobed with human MUC2 (SMUC-41) cDNA probes. This procedure was repeated until the blots were probed with mouse MUC3, mouse MUC-5AC, and human β-actin cDNA or RNA probes, respectively.

Reverse Transcription–Polymerase Chain Reaction. To confirm the presence of rat MUC2 mRNA in the middle ear epithelium, we performed reverse transcription–polymerase chain reaction (RT-PCR) with 2 sets of specific sense-antisense primers at both the amino[19] and carboxyl terminal[20] regions of the rat MUC2 mRNA. Primers (sense, bases 2,033 to 2,054, 5'-GCT CAA TCT CAG AAG GCG ACAC-3'; antisense, bases 2,886 to 2,905, 5'-CCA GAT AAC AAT GAT GCC AGA GC-3') were used to amplify a cDNA fragment of 875 base pairs (bp; including primers) from the rat MUC2 mRNA sequences between bases 2,033 and 2,907 at the amino terminal area. Primers (sense, bases 362 to 381, 5'-GCC TCA AAC CCG TGC GTG TC-3'; antisense, bases 931 to 950, 5'-TCA TTC ACC AAC CAC TCA TC-3') were used to amplify a cDNA fragment of 589 bp (including primers) from the rat MUC2 mRNA sequences between bases 362 and 950 at the carboxyl terminal area. Primers (sense, bases 333 to 352, 5'-GCT GGT GCT GAG TAT GTC GT-3'; antisense, bases 921 to 940, 5'-GAA TGG GAG TTG CTG TTG AA-3') were used to amplify a cDNA fragment of 608 bp from the rat GAPDH (glyceraldehyde-3-phosphate-dehydrogenase) mRNA[21] sequences between bases 333 and 940 for loading controls.

Two micrograms of total RNA from the middle ear samples was added to 20 μL of reverse transcription mixture that contained 5-mmol/L magnesium chloride, 1 × PCR buffer II, 1-mmol/L deoxyguanosine triphosphate, 1-mmol/L deoxyadenosine triphosphate, 1-mmol/L deoxythymidine triphosphate, 1-mmol/L deoxycytidine triphosphate, 1 U/μL RNase inhibitor, 2.5 U/μL MuLV (murine leukemia virus) reverse transcriptase, and 2.5-μmol/L random hexamers (RT-PCR kit, Perkin Elmer, Foster City, Calif). This mixture was incubated at 42°C for 1 hour. Eighty microliters of PCR mixture containing a final concentration of 2-mmol/L magnesium chloride, 1 × PCR buffer II, 2.5 U/100 μL Ampli*Taq* DNA polymerase, 25 pmol sense primer, and 25 pmol antisense primer was added to the above mixture. Defined cDNA was then amplified with the GeneAmp 9600 instrument system (Perkin Elmer; denaturing temperature 94°C for 1 minute, optimal annealing temperature 60°C for 1 minute, and extension temperature 72°C for 2 minutes, 35 cycles). The cDNA products were size-separated by running on 2% agarose gel.

RESULTS

The quality of the total RNA isolated from the rat middle ears by the lavage method is presented in Fig 3. Ethidium bromide staining showed good-quality 28S and 18S RNAs.

Northern blot demonstrated that middle ear RNA hybridized with the rat MUC2 cDNA probe (Fig 4A, first upper panel, lane 3). It also hybridized with the human MUC2 (SMUC-41) cDNA probe, and showed the exact same pattern (Fig 4A, second upper panel,

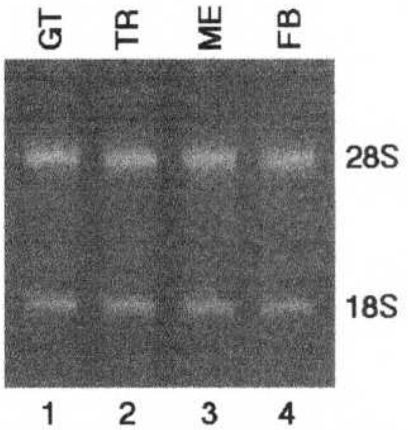

Fig 3. Ethidium bromide staining of gel prior to transfer, used to assess equal sample loading and sample messenger RNA molecule integrity. Lanes 1 to 4 represent rat gut (GT), rat trachea (TR), rat middle ear (ME), and human skin fibroblasts (FB), respectively.

lane 3), but it did not hybridize with the mouse MUC3 and MUC5AC cDNA probes. The size of the RNA was approximately 13.5 kb (Fig 4A, lane 3). The hybridizing signal band of the middle ear RNA was clear-cut, indicative of its single MUC2 mucin mRNA transcript. Intestinal RNA hybridized with rat MUC2 (Fig 4A, first upper panel, lane 1), human MUC2 (second upper panel, lane 1), and mouse MUC3 (Fig 4B, first upper panel, lane 1) cDNA probes, but not with mouse MUC5AC (Fig 4B, second upper panel, lane 1). Airway RNA hybridized with rat MUC2 (Fig 4A, first upper panel, lane 2), human MUC2 (Fig 4A, second upper panel, lane 2), and mouse MUC5AC (Fig 4B, second upper panel, lane 2) cDNA probes, but not with mouse MUC3 (Fig 4B, first upper panel, lane 2). As expected, the negative control (ie, human skin fibroblasts) RNA did not hybridize with any mucin cDNA probes (Fig 4, lane 4 of first and second panels), indicating specificity of the hybridization. Note that hybridizing signal bands from airway and intestine were polydisperse (ranging from 13 to 1.4 kb), suggestive of multiple mucin mRNA transcripts or fragments of MUC2 mRNA due to rapid turnover. The β-actin signal bands of all samples (Fig 4, lower panels) were sharp and clear, indicative of intact RNAs. The intensities of the β-actin bands were similar, suggestive of equal loading of total RNA.

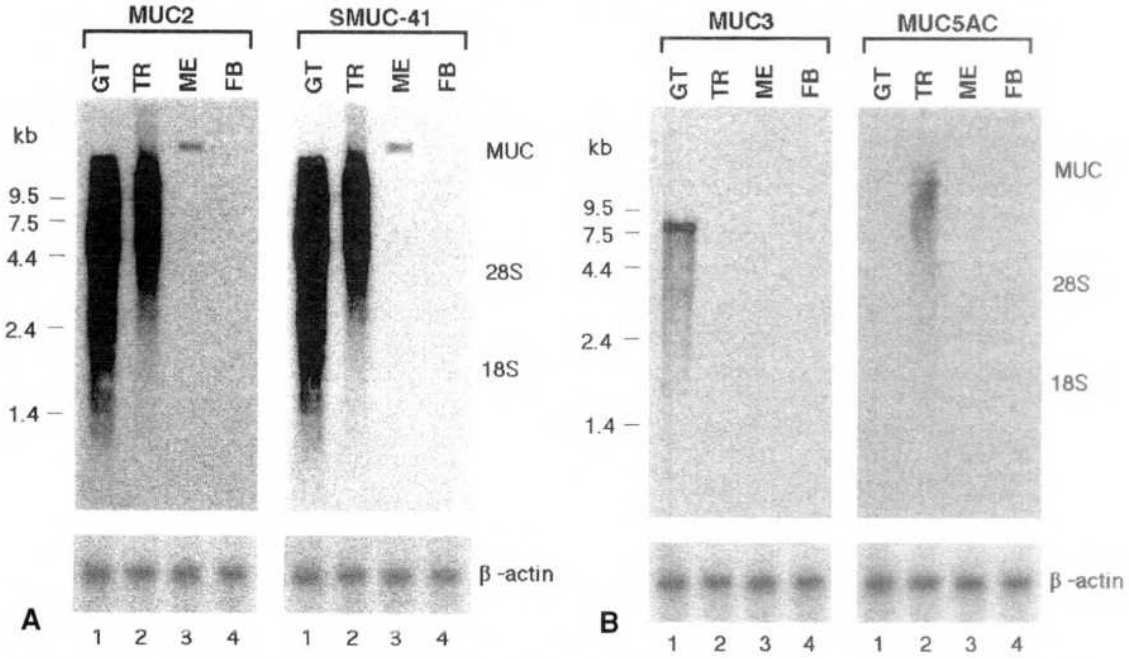

Fig 4. Northern blots. A) Northern blot hybridized with rat MUC2 and SMUC-41 complementary DNA (cDNA) probes (upper panels) and β-actin cDNA probe (lower panels). In upper panels, lanes 1 to 4 represent rat gut (GT), trachea (TR), middle ear (ME), and human skin fibroblasts (FB) hybridized with rat MUC2 or SMUC-41 cDNA probes. Rat gut and trachea showed polydisperse signal ranging from 13 to 1.4 kb, while rat middle ear expressed clear-cut signal band of approximately 13.5 kb. Human fibroblast tissue did not hybridize with rat MUC2 or SMUC-41 cDNA probes. Markers along left side indicate size in kilobase pair. Markers along right side indicate positions of 28S and 18S ribosomal RNA (rRNA), as well as MUC and β-actin signal bands. B) Northern blot hybridized with mouse MUC3 RNA and MUC5AC cDNA probes (upper panels) and β-actin cDNA probe (lower panels). In first upper panel, lanes 1 to 4 represent rat gut, trachea, middle ear, and human skin fibroblasts hybridized with mouse MUC3 cDNA probe. Rat gut showed polydisperse signal, while rat trachea, middle ear, and human fibroblasts were negative. In second upper panel, lanes 1 to 4 represent rat gut, trachea, middle ear, and human skin fibroblasts hybridized with mouse MUC5AC cDNA probe. Rat trachea expressed faint signal, while rat gut and middle ear did not. Markers along left side indicate size in kilobase pair. Markers along right side indicate positions of 28S and 18S rRNA, as well as MUC and β-actin signal bands.

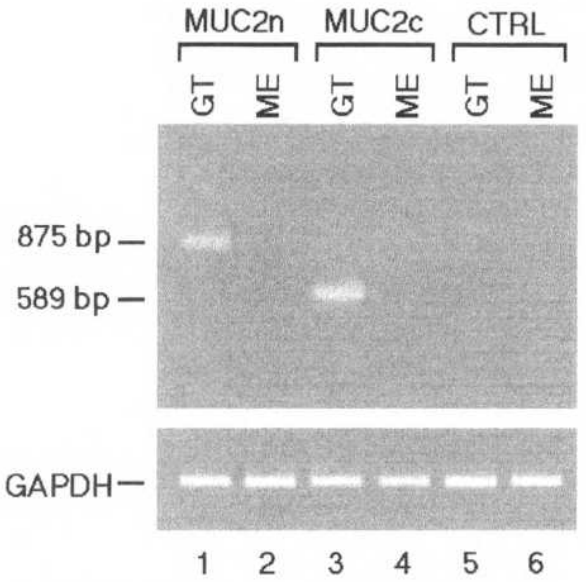

Fig 5. cDNA fragments of rat MUC2 mucin gene at both carboxyl and amino terminals (MUC2c and MUC2n), amplified by reverse transcription–polymerase chain reaction. cDNA (875 bp) from amino terminal was amplified in gut (GT) epithelium (upper panel, lane 1) but not in middle ear (ME) epithelium (upper panel, lane 2). cDNA (589 bp) from carboxyl terminal was amplified in intestinal messenger RNA (mRNA; upper panel, lane 3) but not in middle ear mRNA (upper panel, lane 4). Lanes 5 and 6 represent negative controls (CTRL). GAPDH (glyceraldehyde-3-phosphate-dehydrogenase) gene expression (housekeeping gene) was seen in intestinal and middle ear mRNA (lower panel), suggestive of equal loading of total RNA. Markers along left side indicate size in kilobase pair.

The RT-PCR demonstrated that a fragment of cDNA (875 bp) from the intestinal epithelium (positive control) was amplified at the amino terminal area. Complementary DNA from middle ear epithelium or tracheal tissue was not amplified at the same area (Fig 5, upper panel). A fragment of cDNA (589 bp) from the intestinal mRNA was amplified at the carboxyl terminal area, while middle ear cDNA was not amplified at that same area. Since RT-PCR controls showed no cDNA bands, and GAPDH gene expression (the housekeeping gene) was evident in intestine, trachea, and middle ear epithelia (Fig 5, lower panel), indicative of equal loading of total RNA, this variance in amplification at the amino and carboxyl terminal areas is suggestive of sequence differences in the MUC2 mRNA of intestine, airway, and middle ear epithelia.

DISCUSSION

Rapid harvest of middle ear mucosa from the bony bullae is key to preservation of intact RNA. In this study, lavage of the middle ear mucosa with guanidinium isothiocyanate solution proved to be a simple, rapid, and efficient alternative method for harvesting RNA. It replaced the time-consuming and difficult — due to the extremely thin nature of the middle ear mucosa — process of opening the bullae and scraping mucosa under the microscope. The lavage method lyses middle ear epithelial cells directly and does not require homogenization of tissue, thus avoiding shearing (mucin mRNA is one of the huge–molecular weight mRNAs susceptible to physical shearing). An advantage of harvest by middle ear lavage is that lysate is derived from the epithelial layer and not from bone or other connective tissue layers that tend to dilute the epithelium-derived RNA. This is important because the number of mucin-producing cells in the normal middle ear is very limited.[22] To our knowledge, harvest of epithelium from the bony bullae and isolation of RNA for Northern analysis has not been reported previously.

The RNA analysis demonstrated that normal middle ear epithelial cells of specific germ–free rats expressed the MUC2 mucin gene, indicating that this gene is intrinsic to middle ear epithelial cells and expressed on a regular basis under normal conditions. Unlike airway MUC2 mucin,[23] the middle ear MUC2 mucin gene does not have to be induced. Intrinsic MUC2 expression indicates baseline production of mucin in the middle ear of specific germ–free rats as a function of the mucociliary transport system. Consistent with this finding, other studies have shown that normal rat middle ear mucosa contains a small number of goblet and ciliated cells in the tympanic orifice and transitional zone,[22] the so-called mucociliated tract. Studies have also demonstrated that intestinal MUC2 mRNA is expressed by goblet cells,[24] suggestive of an origin of MUC2 mRNA. Rat middle ear mucin MUC2 mRNA appears to share sequences with human MUC2 (SMUC-41), since the hybridization pattern of the rat MUC2 cDNA probe is identical to that of SMUC-41. Other studies have shown rat MUC2 mRNA to be 80% homologous to human MUC2 mRNA.[19]

The MUC2 mucin is characterized by its unique 23 amino acid sequence tandem repeats, rich in threonine and proline residues.[8] The threonine residues provide scaffolds for attachment of oligosaccharides. The attachment of oligosaccharides to the mucin backbone (apomucin) greatly increases its molecular weight and protects it against degradation by enzymes secreted from microorganisms. Middle ear mucin has been shown to be resistant to chondroitinase ABC[25] and papain.[26]

The nontandem repeat regions at both ends of the MUC2 mucin monomer are highly conserved domains of the mucin molecule, rich in cysteine residues. The cysteine residues provide the molecular

basis for formation of disulfide bonds, as indicated in the von Willebrand factor.[27] Many investigators have reported that mucin monomers become polymerized through disulfide bonds.[27,28] End-to-end linkage between mucin monomers is known to be related to the property of mucin viscosity (gel formation). Carrie et al[29] and Majima et al[30] demonstrated that mucins contribute to the viscosity of middle ear fluid. This gel-forming ability is thought to be an important function of mucin proteins, forming a barrier (mucociliary blanket) on the surface of the epithelium and trapping invading microorganisms and foreign particles.[2,3] Loss of the disulfide bond between mucin proteins by reduction or carboxymethylation leads to loss of viscosity.[6]

It should be noted that in the current study, the rat middle ear MUC2 mRNA transcript differed from that of rat intestinal and tracheal tissues. The signal band from middle ear MUC2 mRNA retrieved by lavage demonstrated a clear-cut band, approximately 13.5 kb in size, representing a single transcript of MUC2 mRNA. The signal band from intestinal or tracheal MUC2 mRNA derived by the conventional method was polydisperse in size, ranging from 13 to 1.4 kb, representing various lengths of mucin mRNAs that reflect breakdown of a single MUC2 mRNA, or multiple transcripts of MUC2 mRNA. Debailleul et al[31] recently demonstrated an improved method for preparing mucin RNAs that exhibited a signal band close to that of a single transcript. It is highly plausible that the discrepancies found between single bands from middle ear and intestinal or tracheal tissues may be related to shearing of the mucin mRNA that occurs as a result of a preparation technique that requires homogenization of tissues. It is not clear at the present time whether goblet cells of the middle ear express exactly the same MUC2 transcript as do those from the intestine and trachea, for 2 reasons: 1) RT-PCR data demonstrated that primers derived from both ends of intestinal MUC2 cDNA do not work with their counterpart in the middle ear; and 2) the size of middle ear MUC2 mRNA (about 13.5 kb) differs from that of intestine or trachea (about 13 kb).

The length of the mucin gene, in general, is characterized as polymorphic. For example, MUC1 has a wide range of phenotypes.[32] The size differences among alleles reflect a variable number of tandem repeats within the transcribed and translated part of the gene. The number of tandem repeats in MUC1 ranges from 21 to 125, with 41 and 85 repeats being the most frequent.[33] Similarly, MUC2 alleles also differ in their number of tandem repeats.[1,34] The mechanism of polymorphism is poorly understood. It may be due to its χ-like sequences (tandem repeat sequences). These sequences, originally found in *Escherichia coli* and bacteriophage λ, are thought to function as signals for homologous recombination.[35,36] χ-Like sequences, also found in the eukaryotic genome, may promote the generation of tandem repeats in DNA.

CONCLUSIONS

Lavage of the middle ear mucosa with guanidinium isothiocyanate solution appeared to be an efficient alternative method for harvesting epithelium-derived RNA in this study. Screening of RNA with MUC2, MUC3, and MUC5AC mucin probes demonstrated that normal middle ear epithelial cells from specific germ–free rats expressed the MUC2 mucin gene, but not MUC3 or MUC5AC. A tentative conclusion, therefore, could be made that the middle ear secretory epithelium of the rat expresses the MUC2 mucin gene under normal or specific germ–free conditions. Evidence obtained in this study also adds support to the notion that rat middle ear MUC2 is one of the polymorphic MUC2 mucin mRNA transcripts or a homologue of the human MUC2 mucin gene (SMUC-41).

ACKNOWLEDGMENTS — We express our appreciation to Carol Basbaum for her kind gift of the rat MUC2 mucin probe, and to JoAnn Knox for editing the manuscript.

REFERENCES

1. Toribara NW, Gum JR, Culhane PJ, et al. MUC-2 human small intestinal mucin gene structure. J Clin Invest 1991; 88:1005-13.

2. Reddy MS, Murphy TF, Faden HS, Bernstein JM. Middle ear mucin glycoprotein: purification and interaction with nontypeable *Haemophilus influenzae* and *Moraxella catarrhalis*. Otolaryngol Head Neck Surg 1997;116:175-80.

3. Carnoy C, Scharfman A, Van Brussel E, Lamblin G, Ramphal R, Roussel P. *Pseudomonas aeruginosa* outer membrane adhesins for human respiratory mucus glycoproteins. Infect Immun 1994;62:1896-900.

4. Florman HM, Wassarman PM. *O*-linked oligosaccharides of mouse ZP3 account for its sperm receptor activity. Cell 1985; 41:313-24.

5. Rosen SD. Cell surface lectins in the immune system. Semin Immunol 1993;5:237-47.

6. Dekker J, Aelmans PH, Strous GJ. The oligomeric structure of rat and human gastric mucins. Biochem J 1991;277: 423-7.

7. Wesley A, Mantle M, Man D, Qureshi R, Forstner G, Forstner J. Neutral and acidic species of human intestinal mucin: evidence for different core peptides. J Biol Chem 1985;260: 7955-9.

8. Gum JR, Byrd JC, Hicks JW, Toribara NW, Lamport DT, Kim YS. Molecular cloning of human intestinal mucin cDNA: sequence analysis and evidence for genetic polymorphism. J

Biol Chem 1989;264:6480-7.

9. Shekels LL, Lyftogt C, Kieliszewski M, Filie JD, Kozak CA, Ho SB. Mouse gastric mucin: cloning and chromosomal location. Biochem J 1995;311:775-85.

10. Gendler SJ, Spicer AP. Epithelial mucin genes. Annu Rev Physiol 1995;57:607-34.

11. Shekels LL, Hunninghake DA, Tisdale AS, et al. Cloning and characterization of mouse intestine MUC3 mucin: 3' sequence containing EGF domain. Biochem J 1998;330:1301-8.

12. Shankar V, Pichan P, Eddy RL Jr, et al. Chromosomal location of a human mucin gene (MUC8) and cloning of the cDNA corresponding to the carboxy terminus. Am J Respir Cell Mol Biol 1997;16:232-41.

13. Bobek LA, Tsai H, Biesbrock AR, Levine MJ. Molecular cloning, sequence and specificity of expression of the gene encoding the low molecular weight human salivary mucin (MUC7). J Biol Chem 1993;268:20563-9.

14. Dekker J, Strous GL. Covalent oligomerization of rat gastric mucin occurs in the rough endoplasmic reticulum, is N-glycosylation-dependent, and precedes initial *O*-glycosylation. J Biol Chem 1990;265:18116-22.

15. Carlstedt I, Herrmann A, Hovenberg H, et al. "Soluble" and "insoluble" mucins — identification of distinct populations. Biochem Soc Trans 1995;23:845-51.

16. Sheehan JK, Thornton DJ, Howard M, Carlstedt I, Corfield AP, Paraskeva C. Biosynthesis of the MUC2 mucin: evidence for a slow assembly of fully glycosylated units. Biochem J 1996;315:1055-60.

17. Chomczynski P, Sacchi N. Single-step method of RNA isolation by acid guanidinium thiocyanate-phenol-chloroform extraction. Anal Biochem 1987;162:156-9.

18. Sambrook J, Fritsch EF, Maniatis T. Molecular cloning: a laboratory manual. 2nd ed. Cold Spring Harbor, NY: Cold Spring Harbor Press, 1989.

19. Ohmori H, Dohrman AF, Gallup M, et al. Molecular cloning of the amino-terminal region of a rat MUC2 mucin gene homologue. Evidence for expression in both intestine and airway. J Biol Chem 1994;269:17833-40.

20. Xu G, Huan L-J, Khatri I, et al. cDNA for the carboxyl terminal region of a rat intestinal mucin-like peptide. J Biol Chem 1992;267:5401-7.

21. Tso JY, Sun XH, Kao TH, Reece KS, Wu R. Isolation and characterization of rat and human glyceraldehyde-3-phosphate dehydrogenase cDNAs: genomic complexity and molecular evolution of the gene. Nucleic Acids Res 1985;13:2485-502.

22. Lim DJ. Normal and pathological mucosa of the middle ear and eustachian tube. Clin Otolaryngol 1979;4:213-32.

23. Jany B, Gallup M, Tsuda T, Basbaum C. Mucin gene expression in rat airways following infection and irritation. Biochem Biophys Res Commun 1991;181:1-8.

24. Audie JP, Janin A, Porchet N, Copin MC, Gosselin B, Aubert JP. Expression of human mucin genes in respiratory, digestive, and reproductive tracts ascertained by in situ hybridization. J Histochem Cytochem 1993;41:1479-85.

25. Lin J, Kim Y, Juhn SK. Increase of mucous glycoprotein secretion by tumor necrosis factor alpha via a protein kinase C–dependent mechanism in cultured chinchilla middle ear epithelial cells. Ann Otol Rhinol Laryngol 1998;107:213-9.

26. FitzGerald JE, Green GG, Stafford FW, Birchall JP, Pearson JP. Characterization of human middle ear mucus glycoprotein in chronic secretory otitis media (CSOM). Clin Chim Acta 1987;169:281-97.

27. Wise RJ, Pittman DD, Handin RI, Kaufman RJ, Orkin SH. The propeptide of von Willebrand factor independently mediates the assembly of von Willebrand multimers. Cell 1988;52: 229-36.

28. Journet AM, Saffaripour S, Wagner DD. Requirement for both D domains of the propolypeptide in von Willebrand factor multimerization and storage. Thromb Haemost 1993;70: 1053-7.

29. Carrie S, Hutton DA, Birchall JP, Green GG, Pearson JP. Otitis media with effusion: components which contribute to the viscous properties. Acta Otolaryngol (Stockh) 1992;112: 504-11.

30. Majima Y, Jin CS, Takeuchi K, Hamaguchi Y, Sakakura Y, Juhn SK. Rheological properties of middle ear mucus in relation to goblet cell population in cat. Acta Otolaryngol [Suppl] (Stockh) 1991(suppl 483):11-6.

31. Debailleul V, Laine A, Huet G, et al. Human mucin genes MUC2, MUC3, MUC4, MUC5AC, MUC5B, and MUC6 express stable and extremely large mRNAs and exhibit a variable length polymorphism. J Biol Chem 1998;273:881-90.

32. Swallow DM, Gendler S, Griffiths B, Corney G, Taylor-Papadimitriou J, Bramwell ME. The human tumor-associated epithelial mucins are coded by an expressed hypervariable gene locus PUM. Nature 1987;328:82-4.

33. Gendler SJ, Lancaster CA, Taylor-Papadimitriou J, et al. Molecular cloning and expression of human tumor-associated polymorphic epithelial mucin. J Biol Chem 1990;265:15286-93.

34. Griffiths B, Matthews DJ, West L, et al. Assignment of the polymorphic intestinal mucin gene (MUC2) to chromosome-11p15. Ann Hum Genet 1990;54:277-85.

35. Jeffreys AJ, Wilson V, Thein SL. Hypervariable "minisatellite" regions in human DNA. Nature 1985;314:67-73.

36. Jarman AP, Wells RA. Hypervariable minisatellite: recombinators or innocent bystanders? Trends Genet 1989;5:367-71.

IMMUNOHISTOCHEMICAL DISTRIBUTION OF EXTRACELLULAR MATRIX COMPONENTS AND KERATIN IN EXPERIMENTALLY INDUCED OTITIS MEDIA

TERUHIKO HARADA, MD
TSU, JAPAN
YOUNGKI KIM, MD
MINNEAPOLIS, MINNESOTA
STEVEN K. JUHN, MD
MINNEAPOLIS, MINNESOTA
YASUO SAKAKURA, MD
TSU, JAPAN

The distribution of collagen types I, III, and IV and of laminin, fibronectin, and keratin was studied in otitis media experimentally induced by *Streptococcus pneumoniae* in the chinchilla. The expression of interstitial collagen types I and III and of fibronectin was increased in the subepithelial space that was thickened by inflammation in the acute period of infection. The expression of collagen type IV in the subepithelial space could be seen in the early period. The epithelial cells in the middle ear changed from flat cuboidal to pseudostratified columnar in pneumococcus-inoculated ears, and the number of keratin-positive epithelial cells in the middle ear increased remarkably after infection. These results indicate that changes in epithelial cell differentiation effected by the extracellular matrix correlate with changes in expression of keratin. It is proposed that the extracellular matrix may contribute to tissue repair in the middle ear after bacterial infection by interfering with cell proliferation of epithelial cells and fibroblasts.

KEY WORDS — extracellular matrix, immunohistochemistry, keratin, otitis media, *Streptococcus pneumoniae*.

INTRODUCTION

The middle ear mucosa forms the first line in the defense system of the middle ear during bacterial and viral infection. This barrier consists of the epithelial layer, involving the mucociliary transport system and the subepithelial space. Otitis media is an inflammatory condition of the middle ear cavity that may result from various causes. The exact chronology of otitis media in the human is not known; however, in experimental animals with untreated otitis media hyperemia, edema, polymorphonuclear leukocyte infiltration, and focal hemorrhage in the subepithelial space occur within 3 days of direct middle ear inoculation with *Streptococcus pneumoniae*.[1] By 5 days, granulation tissue can be identified and the epithelium has changed from flat cuboidal to pseudostratified columnar with goblet cells predominating. Monomorphonuclear leukocytes and osteoneogenesis are present by 2 weeks.

Cellular interaction with the extracellular matrix (ECM) plays an important role in many biological processes, including embryonic development, homeostasis, immune responses, wound healing, and malignant transformation.[2] Although the ECM components are the most important structural constituents in the subepithelial space, little is known about those in the middle ear mucosa. Only a few investigators have reported the distribution of some ECM components in the middle ear.[3-5]

Keratin is one of the predominant filaments in mammalian epithelial cells. The function of keratin in epithelial cells is unknown, but it apparently plays a role in the differentiation and maturation of the epithelial tissue.[6,7] The overall pattern of keratin expression by diverse epithelia is thought to reflect specific location and differentiated cellular function.[8] Studies have demonstrated that the state of differentiation of epithelial cells is influenced by the ECM on which they are cultured in vitro.[9]

The molecular composition of the middle ear mucosa, including the epithelial cells, the basement membrane, and the submucosal tissue, is poorly understood. The present study describes the distribution of collagen types I, III, and IV and of laminin, fibronectin, and keratin in middle ear mucosa from normal chinchillas and from chinchillas with otitis media induced by *S pneumoniae* with the aim of better understanding the molecular composition of the middle ear mucosa.

From the University of Minnesota Otitis Media Center, Departments of Otolaryngology (Harada, Juhn) and Pediatrics (Kim), University of Minnesota, Minneapolis, Minnesota, and the Department of Otorhinolaryngology, Mie University School of Medicine, Tsu, Japan (Harada, Sakakura). Supported by program project 8P50-DC-00133 from the National Institutes of Health/National Institute on Deafness and Other Communication Disorders. This study was performed in accordance with the PHS Policy on Humane Care and Use of Laboratory Animals, the NIH *Guide for the Care and Use of Laboratory Animals*, and the Animal Welfare Act (7 U.S.C. et seq.); the animal use protocol was approved by the Institutional Animal Care and Use Committee (IACUC) of the University of Minnesota.

CORRESPONDENCE — Teruhiko Harada, MD, Dept of Otorhinolaryngology, Mie University School of Medicine, 2-174 Edobashi, Tsu, Mie 514-8507, Japan.

TABLE 1. PRIMARY AND SECONDARY ANTIBODIES FOR IMMUNOHISTOCHEMISTRY

Primary Antibody	*Source*	*Dilution*	*Secondary Antibody*	*Source*	*Dilution*
Collagen type I	SB	1:32	FITC-RAGG	Cappel	1:10
Collagen type III	SB	1:64	FITC-RAGG	Cappel	1:10
Collagen type IV	SB	1:64	FITC-RAGG	Cappel	1:10
Laminin 86-9	MN	1:128	FITC-GARG	Cappel	1:32
Fibronectin	SB	1:32	FITC-GARG	Cappel	1:32
Keratin	Miles	1:32	FITC-GAGPG	Cappel	1:16

SB — Southern Biotechnology Associates, Inc, Birmingham, Ala; MN — provided by the Dept of Pediatrics, University of Minnesota; Miles — Miles Laboratories, Inc, Naperville, Ill; FITC — fluorescein-isothiocyanate; RAGG — rabbit anti–guinea pig IgG antiserum; GARG — goat anti-rabbit IgG antiserum; GAGPG — goat anti–guinea pig IgG antiserum; Cappel — Cappel, Organon on Teknika Corporation, West Chester, Pa.

MATERIALS AND METHODS

Animals. Healthy 1- to 2-year-old chinchillas were used in this study. Eleven normal ears from chinchillas and 12 infected ears were used. Purulent otitis media was induced by inoculation of type 7F *S pneumoniae* (20 colony-forming units per ear) into the bulla. This pneumococcus is an encapsulated strain (American type 51) that has been used exclusively in modeling pneumococcal otitis media in chinchillas.[10] Pneumococci were grown to log-phase in Todd Hewitt broth (BBL Microbiology Systems, Cockeysville, Md) enriched with 35% bovine serum albumin (Sigma, St Louis, Mo). Purulent otitis media was produced by direct inoculation of *S pneumoniae* into the superior bulla of the chinchillas.

Six ears were used as "acute period mucosa" that was taken 3 to 5 days after bacterial inoculation. Six ears were used as "convalescent period mucosa" that was taken 3 to 6 months after bacterial inoculation.

Fresh Preparations and Immunohistochemistry. After the animals were killed painlessly, bullae were opened with sharpened picks and the mucosa was carefully separated from the bone with an elevator for ear surgery. The mucosa was taken from the superior bulla, the inferior bulla, and the eustachian tube. Tissue was snap frozen in isopentane precooled in liquid nitrogen and sectioned at 4 μm in a Lipshaw cryostat (Lipshaw Manufacturing Co, Detroit, Mich).

An indirect immunohistochemical method was used as previously described.[11] In brief, after air-drying, sections were fixed with acetone for 10 minutes, washed 3 times with phosphate-buffered saline, and overlaid with approximately 20 μL of an appropriate dilution of primary antiserum. Goat anti-collagen antibodies specifically react with human collagens, but they also react with collagens from most other species. Anti-keratin antiserum specifically stains networks of tonofilaments. Each secondary antiserum was absorbed with chinchilla serum before use. Primary and secondary antibodies are shown in Table 1. Primary antibodies were reacted with chinchilla plasma–absorbed fluorescein-isothiocyanate–conjugated secondary antibodies (Table 1). Sections were examined with a Zeiss phase contrast microscope with epifluorescence illumination. Hematoxylin and eosin staining sections were also prepared.

Two immunohistochemical controls were performed. First, chinchilla kidney, external ear skin, and ear cartilage were used to serve as a positive control and to determine whether the antibodies cross-react with chinchilla tissues. These tissues were processed identically to the fixed chinchilla middle ear mucosa. Second, as a negative control, tissue sections were incubated only in the secondary antibody. The distribution and intensity of immunofluorescence was scored on a semiquantitative scale of none (–), moderate (+), strong (++), and very strong (+++) fluorescence by 2 observers (T.H. and Y.K.).

RESULTS

Cross-reactivity of Primary Antibodies. Although the primary antibodies used in this study were raised against human ECM components and keratin, these can also react with chinchilla ECM components and keratin, not only in the middle ear mucosa but also in other organs (kidney and external ear skin). The distribution pattern of ECM components and keratin in chinchillas was almost the same as in humans.

Normal Middle Ear Mucosa. The reactivity patterns of the different ECM antibodies and the keratin antibody on normal middle ear are summarized in Table 2 and depicted in Figs 1 and 2.

Collagen types I and III were present throughout the submucosal layer (Fig 1A,B). Antibodies to collagen type IV and laminin localized exclusively in the basement membranes of normal chinchilla middle ear mucosa and capillaries (Fig 1C,D). Fibronectin was also present in the submucosal layer of normal chinchilla middle ear mucosa (Fig 1E). Squamous cells predominated in this area (Fig 1F).

Antibodies to keratin localized in the nasal mucosa (Fig 2A), the eustachian tube (Fig 2B), the tympanic orifice of the eustachian tube (Fig 2C), and the

TABLE 2. DISTRIBUTION OF EXTRACELLULAR MATRIX COMPONENTS AND KERATIN IN MIDDLE EAR MUCOSA OF CHINCHILLA

	Collagen Type I	*Collagen Type III*	*Collagen Type IV*	*Laminin*	*Fibronectin*	*Keratin*
Normal middle ear mucosa (n = 11)						
Epithelial cells	–	–	–	–	–	– to +
Basement membrane	–	–	++*	++	–	–
Subepithelial layer	++	++	–	–	++	–
Infected middle ear mucosa (acute period; n = 6)						
Epithelial cells†	–	–	–	–	– to +§	+++
Basement membrane	–	–	+++	++	– to +	–
Subepithelial layer	+++	+++	+ to ++	– to +	+++	–
Infected middle ear mucosa (convalescent period; n = 6)						
Epithelial cells	–	–	–	–	–	– to ++
Basement membrane	–	–	++	++	–	–
Subepithelial layer	++	++	–	–	++	–

Immunofluorescence was scored as follows: – — none; + — moderate; ++ — strong; +++ — very strong. When scores of 2 observers differed, result is given as range.

*Collagen type IV and laminin are distributed in not only basement membrane of epithelium but also that of capillaries in subepithelial layer.

†Epithelial cells changed from flat cuboidal to pseudostratified columnar with goblet cells predominating.

§Deposition of fibronectin in mucous blanket was seen in acute period of infection.

superior bulla (Fig 2D) of normal chinchillas. In particular, basal cells of the epithelial layer in the eustachian tube and tympanic orifice of the eustachian tube were stained strongly with these antibodies. On the other hand, antibodies to keratin generally did not localize in the superior bulla mucosa (Fig 2D). The epithelial cells in the superior bulla mucosa occasionally exhibited reactivity. However, decoration of epithelial cells with antikeratin antibodies was more common at the tympanic orifice of the eustachian tube (Fig 2C). Squamous cells predominated in the superior bulla (Fig 2F), whereas ciliated and secretory cells could be seen in the transitional zone of the middle ear mucosa (Fig 2E).

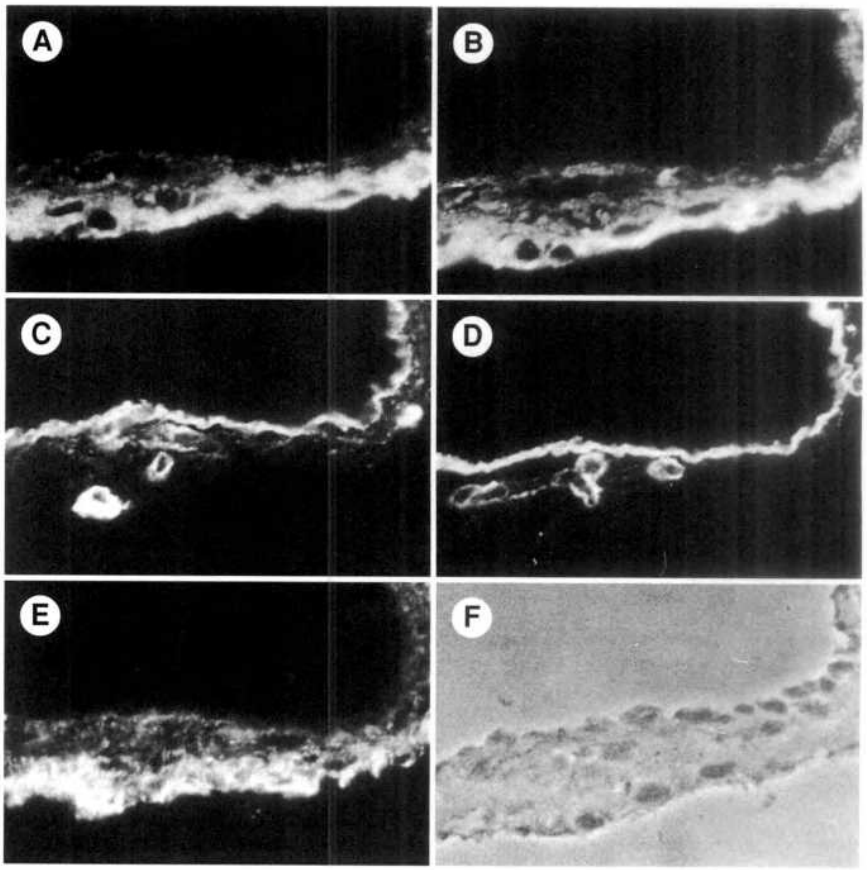

Fig 1. A-E) Immunofluorescence of A) collagen type I, B) collagen type III, C) collagen type IV, D) laminin, and E) fibronectin in normal chinchilla middle ear mucosa. F) Phase-contrast microscopic picture of same region.

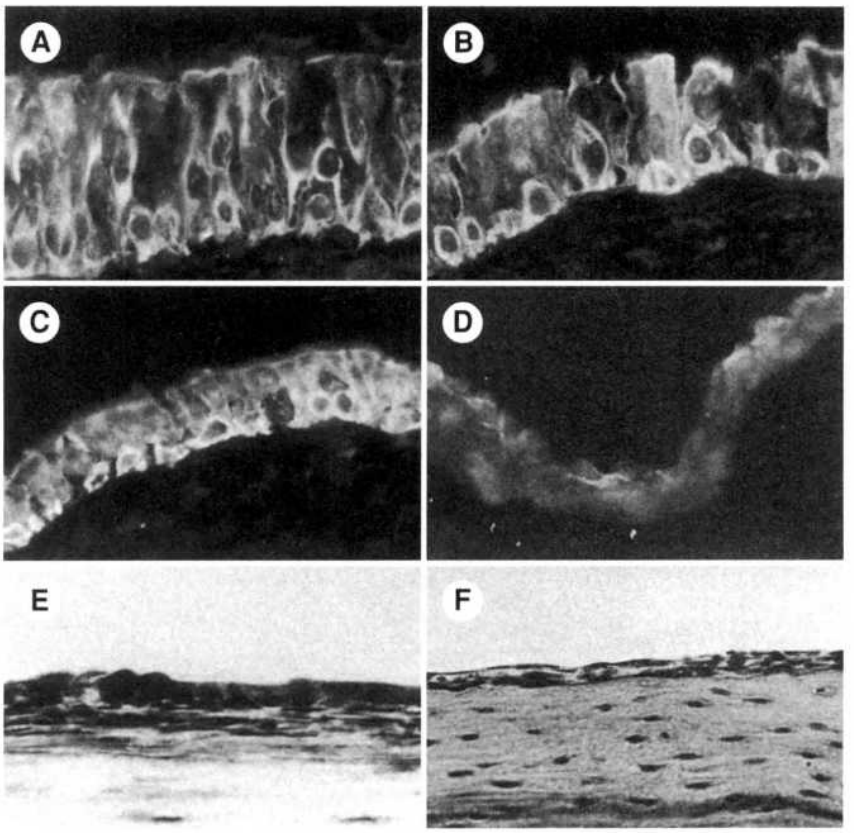

Fig 2. A-D) Immunofluorescence of keratin in normal chinchilla A) nasal mucosa, B) eustachian tube, C) inferior bulla, and D) superior bulla. E,F) Histologic characteristics of normal chinchilla middle ear mucosa from E) inferior bulla and F) superior bulla with hematoxylin-eosin.

Infected Middle Ear Mucosa. The reactivity patterns of the different ECM antibodies and the keratin antibody on infected middle ear are summarized in Table 2 and depicted in Figs 3 and 4.

The deposition of collagens type I and III increased in the submucosal layer that was thickened by inflammation due to pneumococcal infection in the middle ear cavity (Fig 3A,B). The expression of collagen type IV remarkably increased in the subepithelial layer in the acute period (Fig 3C), whereas that of laminin showed no apparent change (Fig 3D). Numerous small blood vessels, which had strong collagen type IV expression, were also found in the thickened subepithelial space in the acute period of infection. The deposition of fibronectin increased in the submucosal layer and in the mucus blanket in the acute period (Fig 3E). Not only the epithelial cells in the inferior bulla mucosa, but also those in the superior bulla, showed strong immunofluorescence of keratin in the acute period (Fig 3F). The mucosa in both superior and inferior bullae was thickened remarkably with pneumococcal infection in the acute period. There was focal cuboidal and columnar metaplasia of the lining of the mucous membrane (Fig 3H).

Cuboidal and columnar metaplasia of the lining of the mucous membrane, as well as striking edema of the subepithelial layer with a mononuclear cell infiltrate, could be seen in the middle ear cavity. The middle ear cavity was filled with an acute inflammatory exudate in the acute period (Fig 4C). The expression of keratin in the epithelial cells remarkably increased in the acute period of pneumococcal infection (Fig 4A). The expression pattern of keratin and the shape of the middle ear epithelium were similar to those in the nose and eustachian tube of normal chinchillas.

In the convalescent period, the expression of ECM components returned to almost the same as that in normal middle ear mucosa. The epithelial cells in the superior bulla, however, still showed immunofluorescence of keratin (Fig 4B). Although squamous cells predominated in the middle ear in the convalescent period, ciliated cells and secretory cells were occasionally observed in small patches (Fig 4D). No subepithelial glands were found in the middle ear mucosa.

DISCUSSION

The considerable size of the ECM components suggests that each genetic type has specific functions. Although information is available on the composition of most ECM components, their function remains poorly defined. To begin to understand the functions of the individual ECM components, their histopathologic features, relations, and interactions in vivo must be defined. Therefore, we decided to study the distribution of interstitial collagen types I

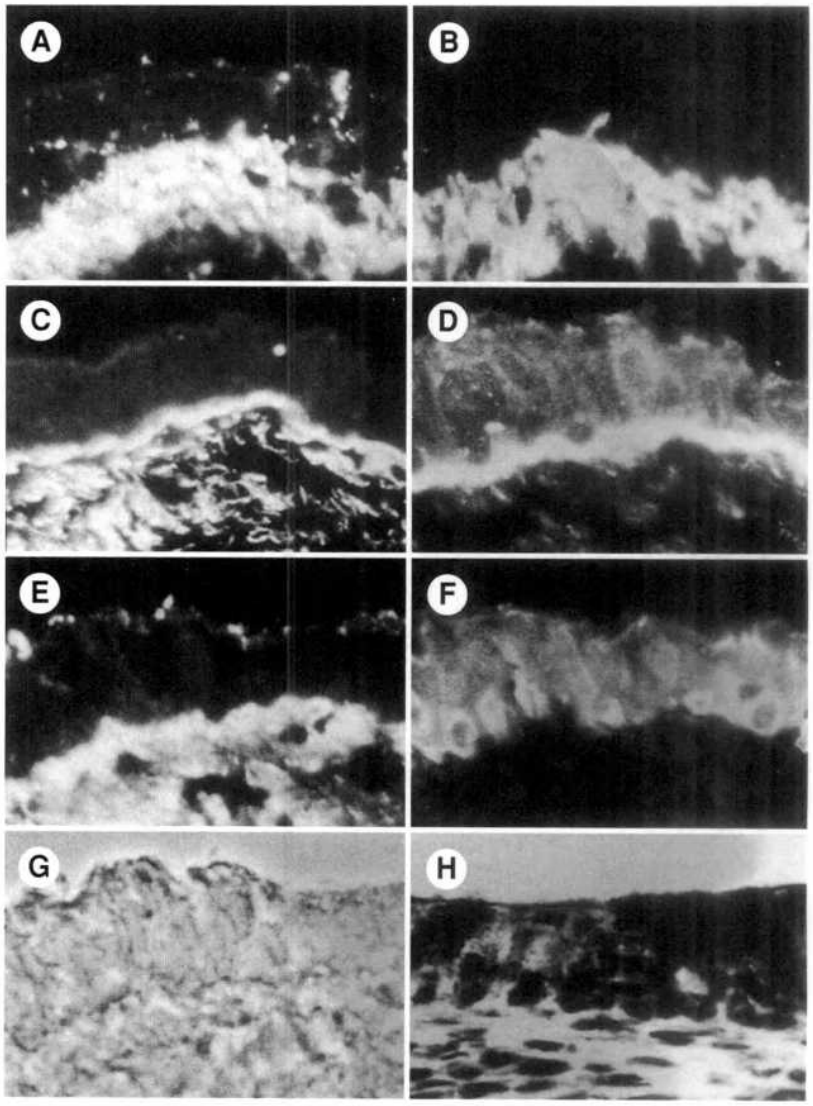

Fig 3. A-F) Immunofluorescence of A) collagen type I, B) collagen type III, C) collagen type IV, D) laminin, E) fibronectin, and F) keratin in acute phase of otitis media induced by *Streptococcus pneumoniae* in chinchillas. G) Phase-contrast microscopic picture and H) hematoxylin-eosin staining of same region.

and III, of fibronectin, and of the intrinsic basement membrane components collagen type IV and laminin in normal and pneumococcal-infected chinchilla otitis media.

Epithelial cell keratins are a complex group of intermediate filament proteins.[12] The overall pattern of keratin expression by diverse epithelia is thought to reflect specific location and differentiated cellular function.[8]

In this study, we have localized the ECM components and keratin by immunohistochemistry using an indirect immunofluorescence technique. Collagen types I and III were localized in the subepithelial space, collagen type IV and laminin in the basement membranes, fibronectin in the submucosal layer, and keratin in the epithelial cells of normal middle ear mucosa of chinchillas. The distribution of collagen type I was similar to that reported in normal human middle ear mucosa.[3] Collagen type III was also restricted to the interstitium in normal chinchilla middle ear mucosa. The distribution of collagen types I and III was similar to that reported in human tympanosclerosis.[5]

After the introduction of a sufficient bacterial inoculum into the middle ear cavity, an acute inflammatory reaction could be established. The 3 layers of the middle ear mucosa were quickly altered with an acute infiltrate of leukocytes in the subepithelial space, massive inflammatory cell infiltration into the middle ear cavity, and enzymatic responses such as increases in lysozyme, proteases, and protease inhibitors.[13] The epithelial cells changed from flat cuboidal to pseudostratified columnar with goblet cells predominating. A middle ear effusion accompanied these changes, and it appeared to be in part a transudate from the mucosal vasculature, accompanied by leukocyte migration from both vascular and tissue sources. We have already reported that the vascular permeability of the middle ear mucosa of chinchillas was significantly increased after *S pneumoniae*

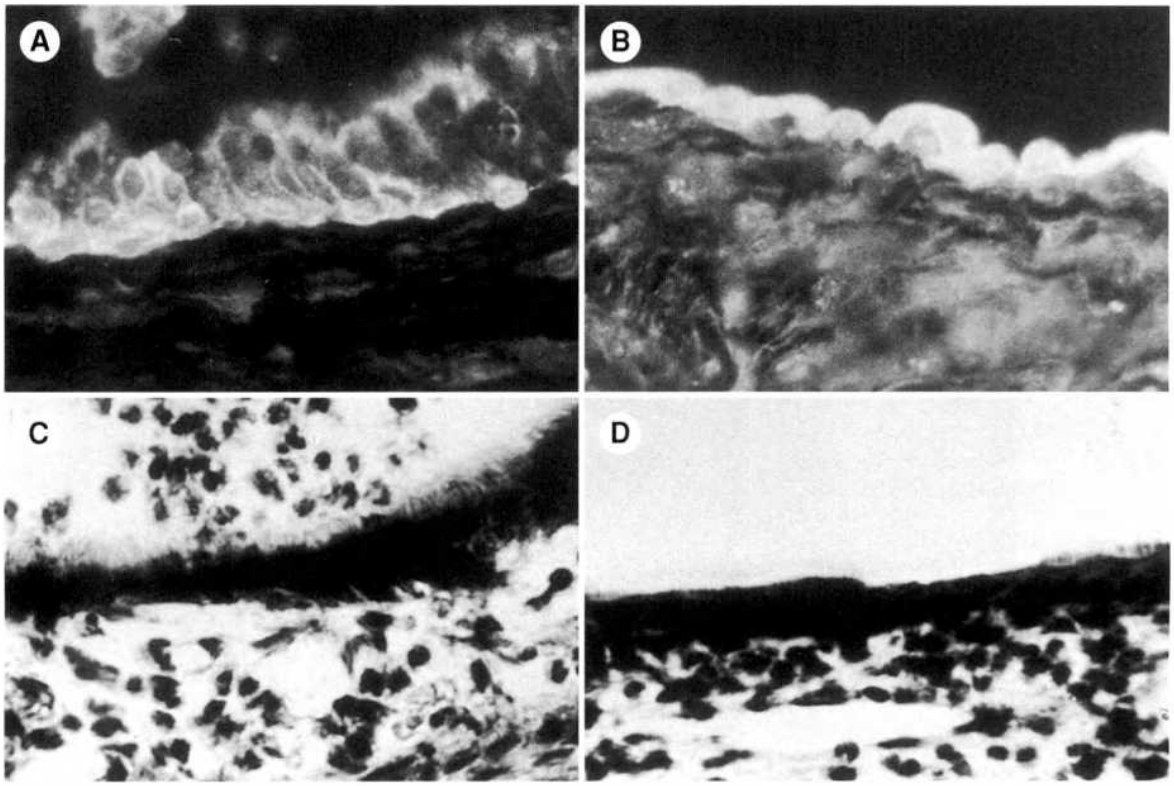

Fig 4. A,B) Immunofluorescence of keratin in pathological states of distal part of chinchilla bulla: A) acute stage of inflammation and B) convalescent stage. C,D) Histologic characteristics (hematoxylin-eosin staining) of corresponding stages: C) acute and D) convalescent.

inoculation into the middle ear cavity.[14] As pneumococci are the most frequent causative agents in human otitis media, we studied the consecutive events that take place in the middle ear cavity after inoculation of *S pneumoniae*.

The expression of collagen types I and III increased in the submucosal layer that was thickened by inflammation in the acute period of infection. Others reported that collagen types I and III deposition was found in an inflammatory state. The role of collagen deposition in wound healing is well established in the skin.[15] The formation of a dermal scar is accompanied by an increase in collagen synthesis that may last 6 months or more in the guinea pig. Collagen type III is found in higher concentrations in early scar tissue than in surrounding dermis. A number of biochemical abnormalities have been reported in pathological scars (hypertrophic scars and keloids) and granulation, including a prolonged high rate of collagen synthesis, an increased glycosaminoglycan content, high polyhydroxylase levels, and increased amounts of an unusual polyfunctional lysyl-derived cross-link, pyridinoline. Although the biochemical defect responsible for these abnormalities is not known, it is of interest that the high proportion of collagen type III found in the early phase of wound healing persists in pathological scars long after the pattern of collagen expression in normal scars has reverted to that seen in normal dermis.

The expression of fibronectin increased in the subepithelial space and in the mucus blanket. The increase in deposition of fibronectin in the mucus blanket may be explained as a result of increased plasma fibronectin permeability due to inflammation after inoculation of *S pneumoniae* into the middle ear cavity of the chinchillas. It is reported that fibronectin mediates the attachment and spreading of cells on a variety of substrates and influences their migration, growth, and differentiation.[16] Fibronectin functions as a primary matrix for organization of collagenous connective tissue during the tissue repair process.[17] One may speculate that increased fibronectin in the submucosal layer promotes modulation of epithelial cells and development and growth of the vascular system in the middle ear mucosa. Two types of fibronectin have been reported.[18] Cell surface or cellular fibronectin is synthesized by a variety of cells, including fibroblasts, myoblasts, and certain epithelial cells. Plasma fibronectin is a dimer of 2 disulfide-bonded polypeptides, whereas cellular fibronectin occurs as dimers and multimers. Most antisera to the 2 forms of fibronectin cross-react. The antiserum that we used in this study also cross-reacted. The primary function of cellular fibronectin is to me-

diate the adhesion of cells to the ECM and to other cells.[19] The most obvious role for fibronectin in the middle ear may be to provide structural support for the collagen fibers while allowing for the permeability of certain ions to and from the middle ear cavity. Although fibronectin is not known as a mitogen for epithelial cells in the middle ear, it has been reported to affect epithelial cell proliferation by mediating their anchorage.[20]

Few keratin-positive epithelial cells were detected in the superior bulla, whereas keratin-positive epithelial cells were common in the eustachian tube mucosa and in the nasal mucosa. The number of keratin-positive cells in the bulla mucosa remarkably increased after *S pneumoniae* inoculation in the middle ear cavity, and these keratin-positive cells still remained in the convalescent period. Although epithelial cells and their transformed derivatives share the common characteristic of expressing keratin intermediate filaments, keratin filaments in some cell types undergo cell-cycle–specific changes in organization.[21] The phenomenon of "antigenic masking" can potentially lead to incorrect interpretation of negative immunofluorescence data. Normal superior bulla mucosa of chinchillas showed negative immunoreactivity in this study, whereas normal nasal and eustachian tube mucosae were immunologically positive for keratin. One might speculate from these results that the epithelial cells in the bulla have the potential to undergo a molecular transformation to a state characteristic of hyperproliferative cells, and that the cells in eustachian tube mucosa or nasal mucosa produce more keratin because of stimulation by microorganisms or by chemical irritants in the air. We will confirm negative immunoreactivity by immunoblotting data in the future, because the absence of staining must be interpreted as inconclusive. Moreover, the keratins are a highly heterogeneous group of proteins that represent a class of intermediate-size filaments in almost all vertebrate epithelia, but are not usually detectable in nonepithelial tissues such as fibroblasts, muscles, and nerves. The availability of monoclonal antikeratin antibodies has provided a tool for investigating both the presence and differential expression of the keratins.[8] The particular keratin composition of the epithelia varies with the cell type, growth environment, stage of differentiation, and disease state. Studies have demonstrated that the state of differentiation of epithelial cells in vitro is influenced by the ECM on which they are cultured.[22,23] Our next goal is to determine the relationship between keratin subtypes and the ECM components in otitis media.

The present findings emphasize the important role that the composition and organization of the ECM may play in the modulation of middle ear mucosal behavior in otitis media. The results in this study also indicate that synthesis of keratin may be the result of cell injury and suggest that keratin has an active regulatory role in the process of epithelial cell differentiation in the middle ear. The mechanisms operating in such cell-matrix interactions, and their potential role in tissue remodeling in diseased middle ear mucosa and in the pathogenesis of otitis media, remain to be delineated further.

ACKNOWLEDGMENTS — The authors thank Crystal Blocker and Kathy Divine for their excellent technical assistance.

REFERENCES

1. Meyerhoff WL, Shea D, Giebink GS. Experimental pneumococcal otitis media: a histopathological study. Otolaryngol Head Neck Surg 1980;88:606-12.

2. Hay ED, ed. Cell biology of extracellular matrix. 2nd ed. New York, NY: Plenum, 1991.

3. Birchall JP, Pearman K, Dawes JDK. The collagens of middle ear structures and tympanosclerotic plaques. J Laryngol Otol 1982;96:797-800.

4. Yoo TJ, Tomoda K. Type II collagen distribution in the external and middle ears. In: Lim, DJ, ed. Abstracts of the Sixth Midwinter Meeting, Association for Research in Otolaryngology, Clearwater, Fla, 1983:111.

5. Hussl B, Timpl R, Lim DJ, Ginzel M, Wick GG. Immunohistochemical analysis of connective tissue components in tympanosclerosis. In: Lim D, Bluestone CD, Klein JO, Nelson JD, eds. Recent advances in otitis media. Philadelphia, Pa: BC Decker, 1988:402-6.

6. Fuchs E, Green H. Changes in keratin gene expression during terminal differentiation of the keratinocyte. Cell 1980;19: 1033-42.

7. Sun TT, Eichner R, Schermer A, Cooper D, Nelson WG, Weiss RA. Classification, expression, and possible mechanisms of evolution of mammalian epithelial keratins: a unifying model. Cancer Cells 1984;1:169-76.

8. Tseng SCG, Jarvinen M, Nelson WG, Huang J-W, Woodcock-Mitchell J, Sun T-T. Correlation of specific keratins with different types of epithelial differentiation: monoclonal antibody studies. Cell 1982;30:361-72.

9. Chiquet-Ehrismann R, Mackie EJ, Pearson CA, Sakakura T. Tenascin: an extracellular matrix protein involved in tissue interactions during fetal development and oncogenesis. Cell 1986;47:131-9.

10. Giebink GS, Berzins IK, Schiffman G, Quie PG. Experimental otitis media following nasal colonization with type 7F *Streptococcus pneumoniae*: prevention after vaccination with pneumococcal capsular polysaccharide. J Infect Dis 1979;140: 716-23.

11. Kim Y, Kleppel MM, Butkowski R, Mauer SM, Wieslander J, Michael AF. Differential expression of basement membrane collagen chains in diabetic nephropathy. Am J Pathol 1991;138:413-20.

12. Anderton BH. Intermediate filaments: a family of homologous structures. J Muscle Res Cell Motil 1981;2:141-66.

13. Nonomura N, Giebink GS, Juhn SK, Harada T, Aeppli D. Pathophysiology of *Streptococcus pneumoniae* otitis media: kinetics of the middle ear biochemical and cytologic host responses. Ann Otol Rhinol Laryngol 1991;100:236-43.

14. Sakagami M, Harada T, Juhn SK, Duvall AJ III. Morphologic and biochemical study of vascular permeability of the middle ear mucosa in experimental otitis media. Ann Otol Rhinol Laryngol 1990;99:654-9.

15. Bornstein P. Structurally distinct collagen types. Annu Rev Biochem 1980;49:957-1003.

16. Hynes RO. Molecular biology of fibronectin. Annu Rev Cell Biol 1985;1:67-90.

17. Kurkinen M, Vaheri A, Roberts PJ, Stenman S. Sequential appearance of fibronectin and collagen in experimental granulation tissue. Lab Invest 1980;43:47-51.

18. Yamada KM, Akiyama SK, Hasegawa T, et al. Recent advances in research on fibronectin and other attachment proteins. J Cell Biochem 1985;28:79-97.

19. Hay ED. Extracellular matrix. J Cell Biol 1981;91:205s-223s.

20. Sun TT, Green H. Cultured epithelial cells of cornea, conjunctiva and skin: absence of marked intrinsic divergence of their differentiated states. Nature 1994;269:489-93.

21. O'Guin WM, Schermer A, Sun T-T. Immunofluorescence staining of keratin filaments in cultured epithelial cells. J Tissue Cult Methods 1985;9:123-8.

22. Gospodarowicz D, Delgado D, Vlodavsky I. Permissive effect of the extracellular matrix on cell proliferation in vitro. Proc Natl Acad Sci USA 1980;77:4094-8.

23. Woodcock-Mitchell J, Rannels SR, Mitchell J, Rannels DE, Low RB. Modulation of keratin expression in type II pneumocytes by the extracellular matrix. Am Rev Respir Dis 1989; 139:343-51.

PHONOSURGERY

The European Laryngological Society's Workshop 1999: Phonosurgery will be held, in English, October 9-10, 1999, in Graz, Austria. For more information, contact Prof Dr G. Friedrich, Department of ENT, University of Graz, Medical School, Auenbruggerplatz 20, Graz, Austria; telephone ++43/316/385-2579; fax ++43/316/385-3549; e-mail gerhard.friedrich@kfunigraz.ac.at.

ANKLE-ARM INDEX AS A SCREENING EXAMINATION FOR FIBULA FREE TISSUE TRANSFER

NEAL D. FUTRAN, MD, DMD
SEATTLE, WASHINGTON

BRENDAN C. STACK, JR, MD
ST LOUIS, MISSOURI

AJAY P. ZACHARIAH
SEATTLE, WASHINGTON

The frequent use of the fibula free flap for mandibular reconstruction has served as an impetus to develop a screening test for this flap. This would detect lower leg vascular disease that could jeopardize the flap or donor extremity. Data would allow a decision whether to pursue further lower leg imaging versus consideration of an alternative donor site. The ankle-arm index (AAI) was determined on a prospective series of 62 patients being considered for fibula free flap transfer. An AAI of less than 1.0 was found to be predictive of a high rate of lower leg vascular disease (by color flow Doppler imaging) that would jeopardize the flap or donor extremity. The AAI did not detect anomalous vasculature of the lower leg (N = 2). If the AAI is less than 1, an alternative donor site to the fibula should be considered, and if it is greater than 1, a color flow Doppler examination of the donor extremity is recommended.

KEY WORDS — ankle-arm index, color flow Doppler, fibula free flap.

INTRODUCTION

Fibula osseocutaneous free tissue transfer is widely used for oromandibular reconstruction following oncological resections or trauma, and is an emerging choice for maxillary reconstruction. Fibula flap harvest requires sacrifice of the peroneal artery. Donor site ischemia secondary to peripheral arterial occlusive disease (PAOD) or lower leg vascular anomalies may result from flap harvest. Anticipation of this problem preoperatively allows for the selection of an alternative donor site.

Preoperative vascular imaging allows for diagnosis of PAOD or anomalous lower extremity vascular supply. Traditionally, this has taken the form of angiography.[1,2] This technique has limitations due to its expense and potential complications of hematoma, thrombosis, embolus, stroke, or contrast-induced anaphylaxis. Alternative methods of vascular imaging that are noninvasive have been described, including magnetic resonance angiography[2] and color flow Doppler imaging (CFD).[3-6] Although CFD is quick, noninvasive, economical, and well accepted by patients, it is another step and expense in the preoperative process.

Allen's test is an office screening procedure that can be used in the selection of candidates for a radial forearm free flap.[7] Its use is recommended because of a significant incidence (10%) of anomalous palmar arch circulation (radial artery dominance). Allen's test involves the simultaneous compression of the radial and ulnar arteries at the wrist while the patient repeatedly opens and closes the hand to remove the venous blood. The radial and ulnar arteries are selectively released, and the palmar skin is examined for a capillary blush.[7] Allen's test offers a quick and reliable means by which a surgeon can preoperatively, and in a noninvasive manner, exclude those patients in whom the sacrifice of the radial artery required for radial forearm free flap harvest would jeopardize the remaining circulation to the hand. Inspired by Allen's test, and in an effort to use resources more efficiently, we contemplated the role of an office screening procedure that would determine the need of vascular imaging of the lower leg versus the consideration of another flap donor site (iliac crest or scapula).

The ankle-arm index (AAI) is a simple test that can be used in a fashion similar to Allen's test to screen the lower extremities for their suitability as donor sites for fibula free flaps. Although each artery of the lower leg cannot be selectively occluded and released to determine patency, the AAI can assess the global arterial sufficiency of the lower leg and foot. A low AAI would indicate arterial insufficiency of the lower leg that would negatively impact on fibula flap or donor extremity survival regardless of the specific arteries involved. Even a single ar-

From the Department of Otolaryngology–Head and Neck Surgery (Futran) and the Vascular Diagnostics Laboratory, Section of Vascular Surgery, Department of Surgery (Zachariah), University of Washington School of Medicine, Seattle, Washington, and the Department of Otolaryngology–Head and Neck Surgery, St Louis University School of Medicine, St Louis, Missouri (Stack).

CORRESPONDENCE — Neal D. Futran, MD, DMD, Dept of Otolaryngology–Head and Neck Surgery, University of Washington School of Medicine, 1959 NE Pacific St, Box 356515, Seattle, WA 98195-6515.

TABLE 1. CHARACTERISTICS OF COLOR FLOW DOPPLER STUDY POPULATION

No. of patients	62
Mean age	63.4
Male-female ratio	40/22
Incidence of peripheral arterial occlusive disease	6 (9.7%)
Arterial anomalies	1 (1.6%)*
No. of extremities	124
Ankle-arm index >1.0	112 (2 anomalies)
Ankle-arm index <1.0	12 (10 peroneal and 12 AT and/or PT disease)
Fibula flap success	98%
Donor site complications	4%

AT — anterior tibial artery, PT — posterior tibial artery.
*Arterial anomalies in 1 patient in both lower extremities.

tery of the lower leg involved with disease would result in either pedicle artery (peroneal) insufficiency or a single donor extremity arterial supply following flap harvest. Either scenario places an unacceptable risk on the patient that can easily be avoided by preoperative assessment and selection of an alternative donor site.

A prospective series of fibula flap patients underwent preoperative AAI in conjunction with a CFD examination of the lower extremities. The AAI results were correlated to CFD findings, and this report will discuss clinical decision-making regarding flap donor site selection. A matched control group of vascular patients with preoperative AAIs and angiograms was analyzed and compared to the study population to demonstrate the usefulness of the AAI as a screening tool for lower leg vascular disease.

METHODS

Sixty-two patients being considered for fibula osseocutaneous free tissue transfer for reconstruction of oromandibular defects were evaluated at the University of Washington Medical Center between October 1, 1995, and March 1, 1998. A protocol was approved by the University of Washington Human Subjects Committee for preoperative lower extremity vascular examinations prior to fibula free flap surgery. All patients were informed regarding the study and the importance of preoperative lower extremity vascular evaluation, including alternative methods, and they consented to participate.

The AAI and CFD evaluations of the lower extremity were performed by a registered vascular technologist. Initially, the AAIs were taken. This was performed by taking the ankle cuff pressures required to compress the anterior tibial, posterior tibial, and peroneal arteries and dividing them by the highest brachial systolic pressure obtained in either of the upper extremities. The arterial pulse was located and monitored by an ultrasound transducer. The anterior tibial pulse was monitored on the dorsum of the foot at the ankle, the posterior tibial pulse was found behind the medial malleolus of the tibia, and the peroneal pulse was located superior and posterior to the lateral malleolus. By means of an ATL-HDI scanner with a linear transducer (Advanced Technology Laboratories, Bothell, Wash), a CFD examination was then performed. A 5-MHz transducer was used while the subject was in the supine position. The popliteal, tibioperoneal trunk, peroneal, and proximal posterior tibial arteries were often best visualized while the patient was in a lateral recumbent position. The examination started at the superficial femoral artery and continued with inspection of the vessels of the popliteal fossa and the tibioperoneal trunk. The proximal anterior tibial, posterior tibial, and peroneal arteries were then traced distally to the foot in a sequential fashion. Diameter measurements were made for the peroneal artery at its origin, at midleg, and at its distal extent. Cutaneous perforators from the peroneal artery to the lateral leg skin were identified, tabulated, and marked with indelible ink for operative reference. A venous study was also performed to rule out deep venous thrombosis and to document the anatomy of the venae comitantes of the peroneal artery. A videotape of each examination was made. The average time required for examination was 60 minutes. Specific instruments, settings, and guidelines for lower extremity examination are detailed by Hatsukami et al.[8]

An age- and sex-matched group of patients seen at the University of Washington Medical Center Vascular Diagnostics Laboratory for evaluation of PAOD from January 1995 to March 1997 was also studied. This group contained patients with signs, symptoms, and/or risk factors for PAOD referred for CFD evaluation of their lower extremities. A total of 61 charts were reviewed from our vascular laboratory database. Only patients who received lower extremity angiography and had documented AAIs were included (N = 40). Patients whose vessels were noncompressible (indicative of severe diabetic arterial disease) were excluded from our review.

RESULTS

Six of 62 patients undergoing CFD prior to fibula free flap harvest were found to have significant PAOD, and each also had an AAI of less than 1. Eight extremities had significant anterior and posterior tibial artery disease (Table 1). All of these patients had significant involvement of the peroneal artery with disease by CFD that would have interfered with microvascular anastomosis to the recipient vessels and/

TABLE 2. CONTROL GROUP OF VASCULAR LABORATORY PATIENTS

No. of patients	40
No. of extremities	61
Male-female ratio	26/14
Mean age	63.4
AAI <1.0 and peroneal artery disease	27/54 (50%)
AAI >1.0 and peroneal artery disease	0/4 (0%)
AAI <1.0 and AT and/or PT arterial disease	39/46 (85%)
AAI >1.0 and AT and/or PT arterial disease	7/13 (54%)

AAI — ankle-arm index, AT — anterior tibia, PT — posterior tibia.

or subsequent flap perfusion. Four of the 6 patients with PAOD had significant superficial femoral artery disease. The other arteries of the lower leg might have been incapable of providing adequate perfusion to the donor extremity following flap harvest. In these patients, an alternative flap donor site was selected.

All patients with normal findings on CFD had AAIs of greater than 1, and 98% of these patients proceeded to successful fibula free tissue transfer unless the head and neck recipient site contraindicated it. In cases of vascular anomalies detected (N = 2), the AAIs were greater than 1. The 2 anomalies were found in 1 patient and resulted in the selection of another donor site. The anomalies were bilateral absence of posterior tibial vessels.

Review of the vascular laboratory comparison group revealed a strong predictive value of AAI for lower leg vascular disease (Table 2). All patients with either peroneal or other lower leg PAOD found on angiography that would contradict fibula flap harvest had an AAI of less than 1. All those with an AAI of greater than 1 had no significant disease of the peroneal artery. Other lower leg vascular disease (anterior and posterior tibial arteries) was found at a rate of 54% in this group, but all these patients had a history of vascular disease. Since our control group consisted of patients being evaluated for PAOD, the numbers of AAIs greater than 1 are limited due to this bias.

DISCUSSION

The need for preoperative vascular assessment of the lower extremity when considering free fibula transfer is a controversial issue.[3] Large series of cases performed without the benefit of preoperative vascular assessment of any kind exist, and the authors reported no adverse sequelae.[1] Others have stressed the need for evaluation to anticipate difficulties with flap harvest due to PAOD or anomalous vessels.[2,3,7]

Head and neck oncology patients who might require a fibula free flap share risk factors with the PAOD patient population. Most head and neck patients are male, in their fifth to seventh decades of life, and are heavy smokers. It is not infrequent to encounter PAOD comorbidities of hypertension and atherosclerotic coronary artery disease in the head and neck cancer population as well. Ten percent of our fibula flap population had significant PAOD of the lower leg that resulted in a change of donor sites. For this reason, a comparison group of PAOD patients was selected.

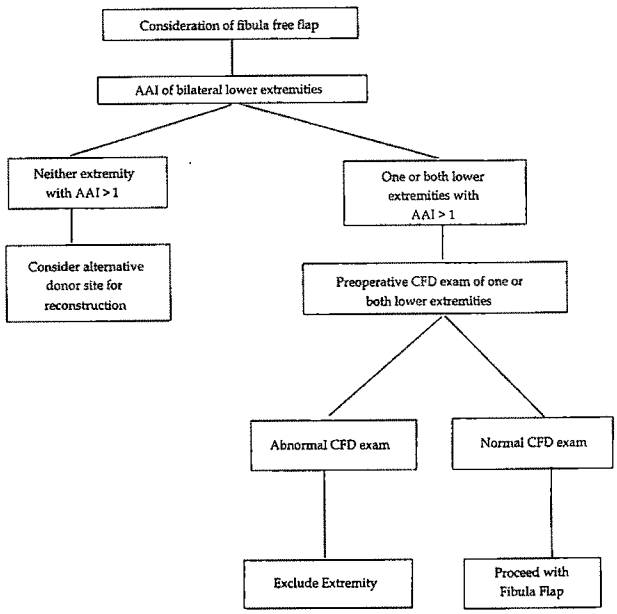

Suggested algorithm for decision-making for fibula free flap selection. AAI — ankle-arm index, CFD — color flow Doppler.

The AAI has been a long-standing test used in vascular diagnosis. It has been extensively studied and correlated to other evaluation techniques for PAOD as well as clinical and operative findings of the disease.[9] The AAI has been endorsed as a screening test for vascular disease by the American Heart Association.[10] The AAI is greater than 1.0 in normal subjects. It decreases in proportion to the severity of arterial obstruction. A single anatomic level of vascular disease is usually seen in patients with an AAI greater than 0.5, whereas patients with multilevel disease have an AAI of less than 0.5.[11] The AAI is inversely correlated with extent of coronary artery disease in adults,[12] carotid intima media thickness,[13] and death in elderly women.[9] The only exception to the AAI threshold of less than 1 are those patients with severe *diabetic* vascular disease, who may have AAIs greater than 1 because their vessels are difficult to compress or noncompressible (up to 300 mm Hg). These patients often have historical data or clinical findings that facilitate their identification preoperatively. Not only is the AAI a validated instrument for screening the lower extremity vasculature,[14] but it is a global assessment for all types of vascular disease.

Our experience demonstrates that the AAI may be a useful screening test for fibula free flap selection. Our recommendations for its use are outlined in the Figure. The AAI is a quick, inexpensive, and noninvasive[9,14] means to exclude patients from fibula flap selection who suffer from significant lower leg vascular disease. This simple procedure allows the surgeon to consider other flap options preoperatively and avoid potential fibula flap or donor extremity complications. In those patients with an AAI of less than 1, a more costly procedure to evaluate the lower-extremity vasculature may be avoided.

One patient in our series had bilateral posterior tibial arterial agenesis; both of her AAIs were greater than 1. Anomalous arterial anatomy alone may not affect the AAI. In the case of anomalous lower leg vasculature, distal extremity blood supply may originate from branches off the peroneal artery, and sacrifice of the same may result in compromised arterial supply for the donor extremity.[1] This creates a high risk of catastrophic ischemic sequelae of fibula flap harvest, which can only be prevented by preoperative imaging.

We recommend evaluation of the lower extremity vasculature with CFD in all fibula flap candidates with an AAI of greater than 1. This test allows for the direct visualization of the pedicle vessels and other extremity vessels to exclude anomalous circulation. Our findings and those of others indicate a significant incidence of these anomalies that justifies preoperative imaging.[1] Furthermore, CFD allows for visualization of cutaneous perforators from the peroneal artery that can be marked and used in designing the skin paddle portion of the flap.[15] Using this approach to fibula flap reconstruction has resulted in minimal flap loss or donor site complications in our experience (Table 1).

The AAI and CFD offer an economical and efficient means to evaluate the vasculature of the lower extremity. An abnormal AAI saves the cost of further lower-extremity evaluation and allows for consideration of alternative flaps. A normal AAI is confirmed with a CFD that excludes anomalous circulation and allows for flap design planning. The information from the AAI is an excellent augmentation to the clinical database required for free flap selection and reconstruction. We feel that these studies have made a positive impact on our reconstructive decision-making process, as well as our outcomes.

REFERENCES

1. Carroll WR, Esclamado R. Preoperative vascular imaging for the fibular osteocutaneous flap. Arch Otolaryngol Head Neck Surg 1996;122:708-12.

2. Urken ML, Sullivan MJ. Fibular osteocutaneous free flaps. In: Urken ML, Cheney ML, Sullivan MJ, Biller HF, eds. Atlas of regional and free flaps for head and neck reconstruction. New York, NY: Raven Press, 1995:291-306.

3. Futran ND, Stack BC, Payne LP. Color flow Doppler use for preoperative assessment in fibula osteoseptocutaneous free tissue transfers. Otolaryngol Head Neck Surg 1997;117:660-3.

4. Amerhauser A, Moelleken BRW, Mathes SJ, et al. Color flow ultrasound for delineating microsurgical vessels. Ann Plast Surg 1993;30:193-203.

5. Jones NF, Monstrey S, Gambier BA. Reliability of the fibular osteocutaneous flap for mandible reconstruction. Plast Reconstr Surg 1996;97:707-16.

6. Miller JR, Potparic Z, Colen LB, Sorrell K, Carraway JH. The accuracy of duplex ultrasonography in planning skin flaps in the lower extremity. Plast Reconstr Surg 1995;95: 1221-7.

7. Urken ML, Sullivan MJ. Radial forearm flap. In: Urken ML, Cheney ML, Sullivan MJ, Biller HF, eds. Atlas of regional and free flaps for head and neck reconstruction. New York, NY: Raven Press, 1995:149-68.

8. Hatsukami TS, Primozich JF, Zierler RE, Harley JD, Strandness DE Jr. Color Doppler imaging of infrainguinal arterial occlusive disease. J Vasc Surg 1992;16:527-33.

9. Vogt MT, Cauley JA, Newman AB, Kuller LH, Hulley SB. Decreased ankle/arm blood pressure index and mortality in elderly women. JAMA 1993;270:465-9.

10. Prineas RJ, Harland WR, Janzon L, Kannel W. Recommendations for use of noninvasive methods to detect atherosclerotic peripheral arterial disease in population studies. Circulation 1982;65:1561A-1566A.

11. Zierler RE. Doppler techniques for lower extremity arterial diagnosis. Herz 1989;14:126-33.

12. Newman AB, Siscovich DS, Manolio TA, et al. Ankle-arm index as a marker of atherosclerosis in the cardiovascular health study. Circulation 1993;88:837-45.

13. Bots ML, Hoffman A, Grobbee DE. Common carotid intima-media thickness. Arterioscler Thromb Vasc Biol 1994;14: 1885-91.

14. Applegate WB. Ankle/arm blood pressure index. A useful tool for clinical practice? JAMA 1993;270:497-8.

15. Futran ND, Stack BC Jr, Zaccardi M. Color flow Doppler use for preoperative assessment in fibula osteoseptocutaneous free tissue transfers. Ann Vasc Surg 1998;12:445-50.

NITRIC OXIDE SYNTHASE TYPE 3 IS INCREASED IN SQUAMOUS HYPERPLASIA, DYSPLASIA, AND SQUAMOUS CELL CARCINOMA OF THE HEAD AND NECK

BRANDON G. BENTZ, MD
G. KENNETH HAINES III, MD
MARK W. LINGEN, DDS, PHD
HAROLD J. PELZER, DDS, MD
DAVID G. HANSON, MD
JAMES A. RADOSEVICH, PHD
CHICAGO, ILLINOIS

The implication of nitric oxide (NO·) in the multistep process of carcinogenesis prompted us to examine the expression of endothelial constitutive nitric oxide synthase (NOS3) in head and neck squamous cell carcinoma (HNSCCa). Eleven paraffin-embedded samples of normal oral mucosa, 3 reactive oral lesions, 13 samples of squamous dysplasia, and 120 specimens of HNSCCa were immunostained with an anti-NOS3 monoclonal antibody and graded on a 0 to 4+ scale of intensity. Normal squamous mucosa demonstrated very little NOS3 expression. Areas of normal mucosa, reactive mucosa, and dysplastic lesions associated with inflammation tended to demonstrate regional expression of NOS3. Reactive mucosal lesions, squamous dysplasia, and HNSCCa demonstrated a significant ($p < .0001$) increase in global expression of NOS3. Therefore, NOS3 is expressed very little in histologically normal squamous mucosa, while squamous hyperplasia, dysplasia, and HNSCCa express significantly more NOS3. Regional variation in NOS3 expression appears to be associated with perilesional inflammation.

KEY WORDS — immunohistochemistry, monoclonal antibody, neoplasms, nitric oxide, squamous cell carcinoma.

INTRODUCTION

It is commonly held that a myriad of cellular interactions influence the development and growth of neoplastic disease. Within the past decade, significant effort has focused on various mutagenic insults hypothesized to contribute to the multistep process of carcinogenesis.[1] These mutational events may promote tumor growth through sequential activation or inactivation of various genes within a cell, leading to increased expression of oncogene proteins, escape from cell cycle regulatory mechanisms, or escape from immune surveillance. This multistep process has been most extensively studied in colonic carcinoma.[2] Within head and neck cancers, certain mutational "hot spots" are believed to contribute to dysplastic and eventual neoplastic changes seen in mucosal tissues.[3] Yet, the molecular mechanisms of the mutational events leading to head and neck squamous cell carcinoma (HNSCCa) remain to be completely elucidated.

A short-lived, arginine-derived nitrogen radical species, nitric oxide (NO·), has gained much attention, being found in a multitude of seemingly diverse cellular populations. It apparently affects a wide range of cellular functions such as cell-to-cell interactions, cytotoxicity and cytostasis, homeostatic mechanisms, and numerous other physiological roles.[4] Mounting evidence implicates NO· in antimicrobial activity.[5] Gram-positive organisms are among the growing list of microbial species that demonstrate susceptibility to NO·.[6] Furthermore, low levels of NO· production have been implicated in cellular proliferation.[7]

Confusing the picture, NO· production has been proposed to represent a "double-edged sword," with many potential pathophysiological roles being hypothesized, including carcinogenesis.[8] It is known that NO· interacts with such species as oxygen, superoxide, transition metals, and thiols preferentially, before reacting with DNA nucleophiles.[9] Chronic low-level production of NO· may deplete the intracellular pool of scavenger molecules, leading to an increased likelihood of nucleophile interactions.

The NO· synthase (NOS) enzyme family is responsible for NO· production, and contains 3 isoforms.[10] The endothelial constitutive isoform of NOS (ecNOS or NOS3) represents a low-output NO· pathway that is predominantly involved in homeostatic processes.[4,10] Nevertheless, NOS3 is increasingly being found in numerous other cellular systems. To date, we are unaware of any studies linking NOS3 expression with head and neck squamous cell carcinogen-

From the Departments of Otolaryngology–Head and Neck Surgery (Bentz, Pelzer, Hanson, Radosevich) and Pathology (Haines, Lingen), Northwestern University and the Robert H. Lurie Cancer Center, and the Veterans Administration/Chicago Health System (Haines, Pelzer, Radosevich), Chicago, Illinois. This research was supported in part by a National Institutes of Health Research Training Grant in Neuroscience (T32-DC00015-14; D.G.H.) and a Department of Veterans Affairs Merit Review Grant (J.A.R.).

Presented in part at the 4th International Meeting on the Biology of Nitric Oxide, Amelia Island, Florida, September 17-21, 1995.

CORRESPONDENCE — James A. Radosevich, PhD, Dept of Otolaryngology–Head and Neck Surgery, Searle Building 12-561, 303 E Chicago Ave, Chicago, IL 60611-3008.

esis. In light of this lack of information, this study was designed to determine the pattern and intensity of expression of NOS3 in normal squamous mucosa, reactive oral lesions, squamous dysplasia, and HNSCCa.

MATERIALS AND METHODS

Patient Data. One hundred twenty consecutive specimens of HNSCCa from 60 patients were selected from the archival pathology files of the VA Lakeside Hospital/Northwestern University Medical Center. Criteria for exclusion included the lack of pathology records, inadequate formalin-fixed–paraffin-embedded tissue, and/or lack of available patient data. Patient charts were reviewed and data were recorded on size of primary, TNM staging, grade, and follow-up when available. Additionally, a series of 11 normal oral mucosa specimens, obtained from uvulopalatoplasty and tonsillectomy specimens, 3 samples of reactive oral lesions, and 12 samples of various stages of squamous dysplasia were stained with the anti-NOS3 monoclonal antibody (Mab).

Anti-NOS3 Monoclonal Antibody. A Mab commercially available from Transduction Laboratories (Lexington, Ky) that has demonstrated specific activity against human NOS3[11,12] was used for immunohistochemical analysis. Tissue specimens were formalin-fixed and paraffin-embedded, and hematoxylin and eosin–stained sections were reviewed for histopathologic diagnosis. A single paraffin block was selected for each specimen, and 7-μm sections were cut. Individual sections were sequentially deparaffinized through a series of xylene, graded alcohol, and water immersion steps. Endogenous peroxidase activity was neutralized with 3% hydrogen peroxide. Slides were subsequently treated with normal horse serum in 1% bovine serum albumin in phosphate buffered saline. Immunostaining was performed with NOS3 Mab and the avidin-biotin complex (ABC) method (Vector Laboratories, Burlingame, Calif) as previously described.[13] All incubation steps were carried out for 15 minutes at 37°C. The chromogen used was 3'-3 diaminobenzidine tetrahydrochloride. Slides were lightly counterstained with Harris's hematoxylin for 1 minute, dehydrated, and coverslipped.

Immunohistochemical Interpretation. Slides were subsequently reviewed in a blinded fashion by the study pathologist (G.K.H.). Each slide was evaluated for intensity of immunohistochemical staining reaction on a 0 to 4+ scale. The overall intensity of the staining reaction was scored, with 0 indicating no staining, 1+ weak staining, 2+ mild staining, 3+ moderate staining, and 4+ strong staining.

Statistical Analysis. Statistical evaluation was performed with the SigmaStat statistical program (Jandel Scientific Software, San Rafael, Calif). A Kruskal-Wallis analysis of variance (ANOVA) on ranks, Student's *t*-test, and Mann-Whitney rank sums were performed where appropriate. A p value of <.05 was considered significant. Survival was evaluated by the method of Kaplan and Meier.[14] Values listed represent mean ± standard deviation unless otherwise indicated.

RESULTS

We first examined the NOS3 pattern and intensity of expression in a group of normal oral mucosa samples (n = 11) obtained from 2 uvulopalatoplasty and 9 tonsillectomy samples. It was found that very little staining for this protein was obtained. The mean NOS3 staining intensity was found to be 0.9 ± 0.7. Of the 2 cases that demonstrated histologic evidence of inflammation, the mean intensity was 1.5 ± 0.5, whereas those samples that lacked inflammation (n = 9) demonstrated a staining intensity of 0.6 ± 0.7.

It was noted that 71% of those samples of normal oral mucosa that demonstrated any staining (≥1+ staining), and both samples demonstrating histologic evidence of an inflammatory response, demonstrated regional variation in NOS3 staining intensity. The characteristics of this regional variation tended to demonstrate high NOS3 staining intensity in basal and parabasal regions of the normal mucosa, with less staining found in the lower and middle spinosa layers. The intensity of NOS3 staining either remained low or significantly increased in the upper spinosa and stratum corneum. Neither histologic evidence of inflammation nor the presence of this pattern of regional NOS3 staining correlated with a history of smoking.

We also examined various samples of reactive mucosa (n = 3) and dysplastic squamous epithelium (n = 12) obtained from diagnostic biopsies of oral lesions. Reactive lesions included 1 fibroepithelial hyperplasia and 2 hyperkeratoses. Dysplastic samples included 5 samples of moderate dysplasia, 6 samples of severe dysplasia or carcinoma in situ, and 1 microinvasive squamous cell carcinoma. The sites of origin included 6 sites that were not specified in the pathology records, 4 tongue lesions, 2 samples from the floor of the mouth, and 1 specimen each from the buccal mucosa, soft palate, and labial gingiva. The mean staining intensity for NOS3 in reactive lesions was found to be 2.7 ± 0.6, while the mean NOS3 expression in dysplastic lesions was found to be 2.3 ± 0.9. These were significantly different from the staining of normal mucosal samples ($p < .0001$; Table 1). Furthermore, individual subcategories of reactive lesions and dysplastic mucosa that contained

TABLE 1. NOS3 EXPRESSION FOR NORMAL MUCOSA VERSUS REACTIVE AND DYSPLASTIC LESIONS

	NOS3 Staining Intensity	
Normal mucosa (n = 11)		0.9 ± 0.7*†§
No inflammation (n = 9)	0.6 ± 0.7	
Inflammation (n = 2)	1.5 ± 0.5	
Reactive mucosa (n = 3)		2.7 ± 0.6*§
Fibroepithelial hyperplasia (n = 1)	2.0 ± 0.0	
Hyperkeratosis/hyperparakeratosis (n = 2)	3.0 ± 0.0†§	
Dysplastic mucosa (n = 12)		2.3 ± 0.9*§
Moderate dysplasia (n = 5)	2.4 ± 1.1†§	
Severe dysplasia/carcinoma in situ (n = 6)	2.3 ± 0.8†§	
Microinvasive squamous cell carcinoma (n = 1)	2.0 ± 0.0	
Squamous cell carcinoma (n = 120)		2.6 ± 1.1*§

Data are mean ± SD. 0 — no staining; 1+ — weak staining; 2+ — mild staining; 3+ — moderate staining; 4+ — strong staining.

NOS3 — nitric oxide synthase type 3.

*$p < .0001$ by ANOVA on ranks: power of performance = 0.993 ($\alpha = 0.05$).

†$p < .0009$ by ANOVA on ranks: power of performance = 0.965 ($\alpha = 0.05$).

§$p < .05$ by Dunn's method of multiple comparisons.

enough samples to warrant statistical evaluation (ie, hyperkeratosis or hyperparakeratosis, moderate dysplasia, and severe dysplasia or carcinoma in situ) also differed significantly in mean NOS3 staining intensity when compared with normal mucosa ($p < .0009$; Table 1). By Dunn's method of multiple comparisons, all individual categories examined were found to be significantly different from normal mucosal staining intensity ($p < .05$; Table 1). Examples of staining characteristics for normal squamous mucosa and for squamous dysplasia are shown in the Figure.

The typical pattern of regional variation of NOS3 expression was found in 60% of dysplastic lesions (n = 9). This regional variation tended to be present in more severely dysplastic lesions, in which 6 of 9 lesions with regional variation were found in severe dysplasia (carcinoma in situ) and/or microinvasive squamous cell carcinoma. The other 3 lesions demonstrating this regional variation were found in samples of fibroepithelial hyperplasia, hyperkeratosis, and moderate dysplasia. No data were available regarding whether these patients went on to develop HNSCCa. The 2 lesions demonstrating only mild staining for NOS3 (ie, 1+ staining intensity) lacked either histologic evidence of inflammation or regional variation in expression of NOS3. A trend was noted toward increased staining intensity in those lesions demonstrating histologic evidence of inflammation (n = 6; mean staining intensity 2.7 + 0.8) when compared with lesions that did not demonstrate histologic evidence of an inflammatory reaction (n = 9; mean intensity 2.2 ± 0.8).

These data were compared to areas of dysplastic mucosal changes found within a sample of HNSCCa. Strong NOS3 staining intensity was found in normal skeletal muscle, endothelium, respiratory epithelium, and large salivary duct epithelium within the peritumor tissue, demonstrating no histologic evidence of neoplastic changes. Histologically normal squamous mucosa surrounding dysplastic tissue samples (ie, lacking histologic evidence of dysplastic or neoplastic changes) again demonstrated the typical specific regional variation of NOS3 expression that was seen in all areas of mucosa examined (see Figure). Intense focal staining for NOS3 was again found in the basal and parabasal areas, which was lost in the lower and middle layers of the stratum spinosum. The expression of NOS3 was again found to either decrease or significantly increase in the upper spinous and stratum corneum layers. Dysplastic mucosa that surrounded these tumor samples demonstrated intense global staining for NOS3 that lost regional variation (see Figure).

Our tumor panel represented primary lesions from a variety of upper aerodigestive tract sites. Included were oropharyngeal (n = 27), oral cavity (n = 16), hypopharyngeal (n = 10), nasopharyngeal (n = 2), and laryngeal (n = 5) samples. Most of our specimens were from advanced-stage lesions, with the vast majority being stage IV disease (n = 42), fewer stage III disease (n = 15), and much less fewer stage II disease (n = 3; Table 2). Neoplastic lesions had a wide range of NOS3 expression without regional variation, with 22.8% demonstrating 1+ staining intensity; 20.2% demonstrating 2+; 30.7% demonstrating 3+; and 26.3% demonstrating 4+. The overall staining intensity of the samples of HNSCCa demonstrated significantly increased staining intensity for NOS3 ($p < .0001$) when compared to normal mucosal samples (Table 1). Staining characteristics did not significantly correlate with TNM staging, grade (Table 3), location of the primary, recurrence, final patient status, disease-free survival, or total survival.

DISCUSSION

Nitric oxide is a multifunctional molecule that is implicated in a wide array of physiological and pathophysiological processes. Immunohistochemical analysis, in addition to other means of investigation, is revealing the vast diversity of tissues that express the NOS isoenzymes. Accordingly, the identification of a constitutive, cytosolic, calcium/calmodulin-de-

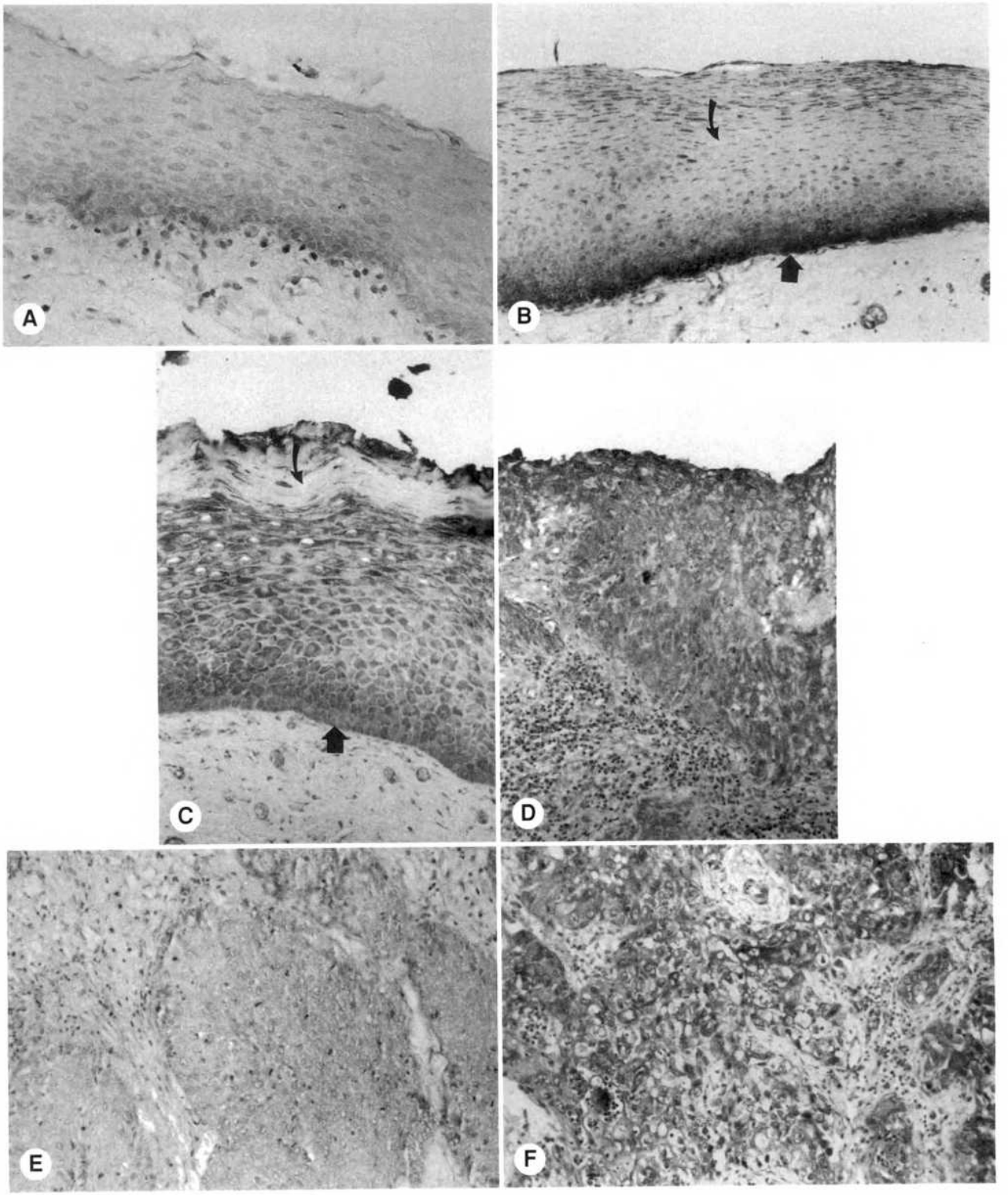

Squamous mucosa samples (original ×200). A) Normal squamous mucosa without inflammation, demonstrating no staining for nitric oxide synthase type 3 (NOS3). B) Normal surrounding squamous mucosa demonstrating regional variation in expression of NOS3. Basal and parabasal areas (thick arrow) demonstrate expression of NOS3, whereas middle spinous and stratum corneum areas (curved arrow) do not express NOS3. C) Squamous dysplasia demonstrating regional variation in expression of NOS3. Again, basal and parabasal areas (thick arrow) demonstrate expression of NOS3, whereas middle spinous and stratum corneum areas (curved arrow) do not express NOS3. D) Peritumor squamous dysplasia demonstrating intense global staining for NOS3. E) Squamous cell carcinoma demonstrating 1+ global staining intensity for NOS3. F) Squamous cell carcinoma demonstrating 4+ global staining intensity for NOS3.

TABLE 2. NOS3 EXPRESSION BY TNM STAGING

TNM Staging Criteria	*NOS3 Staining Intensity*
Tumor	
T1 (n = 1)	3.0 ± 0.0
T2 (n = 10)	2.6 ± 1.1
T3 (n = 21)	2.5 ± 1.0
T4 (n = 29)	2.3 ± 1.1
Nodes	
N0 (n = 14)	2.4 ± 1.1
N1 (n = 15)	2.6 ± 0.8
N2 (n = 13)	2.2 ± 1.2
N3 (n = 20)	2.6 ± 1.1
Metastases	
M0 (n = 57)	2.4 ± 1.1
M1 (n = 3)	2.7 ± 1.2
Stage	
Stage II (n = 2)	2.0 ± 1.4
Stage III (n = 15)	2.7 ± 0.8
Stage IV (n = 46)	2.4 ± 1.1

Data are mean ± SD. 0 — no staining; 1+ — weak staining; 2+ — mild staining; 3+ — moderate staining; 4+ — strong staining.

TABLE 3. NOS3 EXPRESSION BY GRADE

Grade	*NOS3 Staining Intensity*
Well differentiated (n = 22)	2.5 ± 1.1
Moderately well differentiated (n = 70)	2.4 ± 1.1
Poorly differentiated (n = 20)	2.7 ± 1.1

Data are mean ± SD. 0 — no staining; 1+ — weak staining; 2+ — mild staining; 3+ — moderate staining; 4+ — strong staining.

pendent NOS activity within human keratinocytes has been reported.[15] Our immunohistochemical data revealed that NOS3 was strongly expressed in normal skeletal muscle, endothelium, respiratory epithelium, and large salivary duct epithelium. Additionally, in normal squamous mucosa not demonstrating evidence of inflammation, little expression of NOS3 was found. The demonstration of NOS3 activity in keratinocytes may represent an up-regulation of NOS3 in proliferating cultured keratinocytes, and not the true expression pattern seen in vivo.

Under "normal" physiological conditions, the expression of NO· appears to be tightly controlled in numerous cellular populations. Within the cellular system we have studied, one could hypothesize that the expression of NOS3 may represent an antimicrobial barrier within an environment of high microbial colonization, nonspecific response to mucosal inflammation, or involvement in the initial steps of squamous cell proliferation or differentiation. Although NO· has been reported to inhibit cell growth in response to NO·-generating vasodilators,[16] there is evidence that the expression of NOS3 messenger RNA, protein, and activity is correlated with proliferating endothelial cells as opposed to cells in growth arrest.[7] It was found that these cells, upon reaching confluence, demonstrated a precipitous drop in their NOS3 messenger RNA levels, which was followed by a similar drop in protein and NOS3 activity. It may be hypothesized that NOS3-dependent synthesis of NO· is an essential step in the process of squamous stem cell proliferation and/or squamous cell differentiation, but that it may also be a result of cellular differentiation.

It is now becoming increasingly evident that NO· represents a "double-edged sword" with overproduction or aberrant production having deleterious effects, as opposed to its beneficial effects when appropriately produced.[17] Either NO· or its metabolic byproducts may contribute to mutational events that lead to the development of cancer.[18] Although typically found in low concentrations under physiological conditions, NO· can induce cytotoxic and mutagenic effects. It reacts with superoxide (O·2) to form peroxynitrite (ONOO·). Peroxynitrite is a highly cytotoxic and mutagenic radical,[19] but it can further decompose to a toxic hydroxyl radical (OH·) and nitrogen dioxide (NO_2).[20] Peroxynitrite can further oxidize sulfhydryl groups, subsequently inducing membrane lipid peroxidation.[21] Alternatively, NO· can be directly oxidized to NO_2, which may induce DNA damage.[22] In addition, reaction of NO· with hydrogen peroxide has been shown to produce potentially cytotoxic singlet oxygen species.[23] Furthermore, metabolism in an acidic environment converts nitrite to nitrous acid (HNO_2), which can yield N_2O_3 or H_2NO_2 reacting with amines and amides to form N-nitroso compounds (NOC). In a neutral pH environment, bacteria can convert nitrite to N_2O_3 and N_2O_4, again forming NOC. These NOC have been implicated in the carcinogenesis of numerous organs.[18] In fact, it has been suggested that distant organs may be affected by these processes, either through NOC or peroxynitrite, which might diffuse a considerable distance before reacting with cellular nucleophiles.[24] Moreover, in certain neoplastic diseases, carcinogenesis has been associated with aberrant expression of NOS.[25] Interestingly, NOC appear to be associated with A:T→G:C transitions found in p53 mutational "hot spots."[18] Furthermore, recent evidence implicates NO· in conformational and functional modifications in wild-type p53 seen in chronically inflamed tissues.[26] Conversely, wild-type p53 has been shown to decrease the expression of the inducible NOS isoenzyme (iNOS or NOS2).[27] Furthermore, NO· has been implicated in the inhibition of DNA repair,[28] but whether NO·, NOC, or other redox species are responsible is a matter of debate.[19]

Few studies have explored the contribution of in-

dividual isoenzymes to this mutagenic potential. All 3 NOS species were examined in a small group of HNSCCa patients by means of immunohistochemical techniques.[29] The data indicated that NOS3 and the inducible isoform (NOS2) are present within the microenvironment of HNSCCa. Nevertheless, little characterization of the staining pattern of the NOS3 isoenzyme was reported. The study found NOS activity in 80% of the tumor samples (with an anti-citrulline and anti-iNOS antibody) with staining, being found throughout the tumor thickness, and most intensely around keratin pearls. On the other hand, NOS3 (e-NOS) was only found to have variable staining in vascular endothelium in 40% of their samples. In that report, no NOS3 staining characterization was done in histologically normal surrounding structures or surrounding squamous mucosa. The lack of evidence of NOS3 in surrounding mucosal keratinocytes differs from the results herein and previously reported.[15] This may represent differences in fixation of the antigen being examined, or differences in the antibody sensitivity or specificity.

Our data do not demonstrate an apparent correlation between the expression of NOS3 and such clinically relevant factors as TNM stage, grade, primary site, disease-free or total survival, or final patient status. This finding is in agreement with previously reported results. Nevertheless, we did find changes in the expression pattern of NOS3 as the mucosa undergoes a transition from inflammation to dysplasia and finally to frank carcinoma. The appearance of an inflammatory reaction brought about a regionally specific expression pattern of NOS3. This regionality of NOS3 expression was preserved in dysplastic lesions, but was lost in peritumor dysplasia and neoplasia. Dysplastic lesions surrounding tumor foci and neoplastic disease of the oral mucosa demonstrated global expression of NOS3 without regional variation. Additionally, dysplasia demonstrated intense global staining, while carcinoma was found to have a spectrum of global staining.

These data suggest a progressive change in NOS3 expression that may be evident before histologic signs of dysplasia appear. Social behaviors contributing to "field cancerization" of the upper aerodigestive tract in these patients may induce numerous mutational events long before becoming evident morphologically. In agreement with our data, normal squamous mucosa from 5 tonsillectomy and uvulopalatoplasty patients in a previous report showed very little mucosal staining for NOS3.[19] No risk factor history was reported for these controls.

The dysplastic areas surrounding our HNSCCa samples were found to have a global increase in NOS3 expression. One could hypothesize this to be a result of mutational events in inhibitory pathways of expression of NOS3. These inhibitory pathways may contain mutational "hot spots" like those found in the p53 tumor suppressor gene. The increased expression of NOS3 may increase concentrations of potential mutagenic species within a dysplastic and already tenuous microenvironment. The wide variation of NOS3 within HNSCCa may reflect continuing genomic insults in promoter or inhibitor regions of NOS3 expression, or in the gene for NOS3 itself. Alternatively, this variation in expression may reflect the evolution of a heterogeneous cellular population. Current studies are directed at exploring the contributions of both NOS3 and NOS2 isoenzymes in mutational events leading to head and neck squamous cell carcinogenesis.

REFERENCES

1. Yuspa SH, Dlugosz AA, Cheng CK, et al. Role of oncogenes and tumor suppressor genes in multistage carcinogenesis. J Invest Dermatol 1994;103(suppl 5):90S-95S.

2. Fearon ER, Vogelstein B. A genetic model for colorectal tumorigenesis. Cell 1990;61:759-67.

3. Field JK. Oncogenes and tumor-suppressor genes in squamous cell carcinoma of the head and neck. Eur J Cancer 1992; 28B:67-76.

4. Schmidt HH, Walter U. NO at work. Cell 1994;78:919-25.

5. Nathan CF, Hibbs JB. Role of nitric oxide in macrophage antimicrobial activity. Curr Opin Immunol 1991;3:65-70.

6. Kengatharan KM, De Kimpe S, Robson C, Foster SJ, Thiemermann C. Mechanism of gram-positive shock: identification of peptidoglycan and lipoteichoic acid moieties essential in the induction of nitric oxide synthase, shock, and multiple organ failure. J Exp Med 1998;188:305-15.

7. Arnal J-F, Yamin J, Dockery S, Harrison DG. Regulation of endothelial nitric oxide synthase mRNA, protein, and activity during cell growth. Am J Physiol 1994;267:C1381-C1388.

8. Ohshima H, Bartsch H. Chronic infections and inflammatory processes as cancer risk factors: possible role of nitric oxide in carcinogenesis. Mutat Res 1994;305:253-64.

9. Stamler JS. Redox signaling: nitrosylation and related target interactions of nitric oxide. Cell 1994;78:931-6.

10. Nathan C, Xie QW. Nitric oxide synthases: roles, tolls and controls. Cell 1994;78:915-8.

11. Dinerman JL, Dawson TM, Schell MJ, Snowman A, Snyder SH. Endothelial nitric oxide synthase localized to the hippocampal pyramidal cells: implications for synaptic plasticity. Proc Natl Acad Sci USA 1994;91:4214-8.

12. Lundberg JO, Farkas-Szallasi T, Weitberg E, et al. High nitric oxide production in human paranasal sinuses. Nat Med 1995;1:370-3.

13. Hsu SM, Raine L, Fanger H. The use of avidin-biotin-

peroxidase complex (ABC) in immunoperoxidase techniques: a comparison between ABC and unlabelled antibody (PAP procedures). J Histochem Cytochem 1981;29:577-81.

14. Kaplan EL, Meier P. Non-parametric estimation from incomplete observations. J Am Stat Assoc 1958;53:457-81.

15. Baudouin JE, Tachon P. Constitutive nitric oxide synthase is present in normal human keratinocytes. J Invest Dermatol 1996;106:428-31.

16. Garg UC, Hassid A. Nitric oxide–generating vasodilators inhibit mitogenesis and proliferation of BALB/C 3T3 fibroblasts by a cyclic GMP–independent mechanism. Biochem Biophys Res Commun 1990;171:474-9.

17. Moncada S, Palmer RM, Higgs EA. Nitric oxide: physiology, pathophysiology, and pharmacology. Pharmacol Rev 1991; 43:109-42.

18. Mirvish SS. Role of N-nitroso compound (NOC) and N-nitrosation in etiology of gastric, esophageal, nasopharyngeal and bladder cancer and the contribution of known exposure to NOC. Cancer Lett 1995;93:17-48.

19. Beckman JS, Koppenol WH. Nitric oxide, superoxide, and peroxynitrite: the good, the bad, and the ugly. Am J Physiol 1996;271:C1424-C1437.

20. Beckman JS, Beckman TW, Chen J, Marshall PA, Freeman BA. Apparent hydroxyl radical production by peroxynitrite: implications for endothelial injury from nitric oxide and superoxide. Proc Natl Acad Sci U S A 1990;87:1620-4.

21. Radi R, Beckman JS, Bush KM, Freeman BA. Peroxynitrite oxidation of sulfhydryls. The cytotoxic potential of superoxide and nitric oxide. J Biol Chem 1991;266:4244-50.

22. Bittrich H, Matik AK, Kraker I, Appel KE. NO_2 induced DNA single strand breaks are inhibited by antioxidative vitamins in V79 cells. Chem Biol Interact 1993;86:199-211.

23. Noronhadutra AA, Epperlein MM, Woold N. Reaction of nitric oxide synthase with hydrogen peroxide to produce potentially cytotoxic singlet oxygen as a model for nitric oxide–mediated killing. FEBS Lett 1993;321:59-62.

24. US-Japan Cooperative Cancer Research Program: seminar on nitric oxide synthase and carcinogenesis. Cancer Res 1994;54:297-301.

25. Chhatwal VJ, Ngoi SS, Chan ST, Chai YW, Moochhala SM. Aberrant expression of nitric oxide synthase in human polyps, neoplastic colonic mucosa and surrounding peritumoral normal mucosa. Carcinogenesis 1994;15:2081-5.

26. Calmels S, Hainaut P, Ohshima H. Nitric oxide induces conformational and functional modifications of wild-type p53 tumor suppressor protein. Cancer Res 1997;57:3365-9.

27. Forrester K, Ambs S, Lupold SE, et al. Nitric oxide–induced p53 accumulation and regulation of inducible nitric oxide synthase expression by wild-type p53. Proc Natl Acad Sci U S A 1996;93:2442-7.

28. Laval F, Wink DA. Inhibition by nitric oxide of the repair protein, O^6–methylguanine-DNA-methyltransferase. Carcinogenesis 1994;15:443-7.

29. Rosbe KW, Prazma J, Petrusz P, Mims W, Ball S, Weissler MC. Immunohistochemical characterization of nitric oxide synthase activity in squamous cell carcinoma of the head and neck. Otolaryngol Head Neck Surg 1995;113:541-9.

FIFTH INTERNATIONAL CONFERENCE ON HEAD AND NECK CANCER

The Fifth International Conference on Head and Neck Cancer will be held July 29–August 2, 2000, in San Francisco, California. For information, contact Concepts in Meetings & Events, Robin L. Wagner, President, 7819 Lloyd Ave, Pittsburgh, PA 15218-1941; telephone (412) 243-5156; fax (412) 243-5160; e-mail rlwa@med.pitt.edu.

CORRECTING VOCAL FOLD IMMOBILITY BY AUTOLOGOUS COLLAGEN INJECTION FOR VOICE REHABILITATION

A SHORT-TERM STUDY

MARC REMACLE, MD, PHD
MONIQUE DELOS, MD
GEORGES LAWSON, MD
JACQUES JAMART, MD
YVOIR, BELGIUM

We report on a short-term clinical study of injectable autologous collagen (Vocalogen) used to correct dysphonias arising from vocal fold immobility. The collagen is extracted from skin taken from the lower abdominal quadrant area or from just above the bikini line. About 30 cm^2 of skin are required to provide 2 mL of injectable collagen. The histologic examination of the preparation before injection disclosed the presence of elastin fibers and some clusters of epithelial cells, beside the collagen fibers. The collagen is naturally reticulated, and the molecule is preserved in its entirety. The technique is exactly the same as that reported for bovine collagen: injection into Reinke's space, under general anesthesia, monitored by direct microlaryngoscopy. The amount injected is also similar: 1.5 mL for correction of glottic insufficiency in which the immobile vocal fold is in the intermediate position. Eight patients were injected, and the average follow-up was 4.5 months. Voice assessments made before and after the treatment included stroboscopy, subjective and perceptual judgments, and aerodynamic and acoustic measurements. The functional results were similar to those obtained with bovine collagen. No complications arose. The probability of any hypersensitivity reaction, always a possibility to be feared with bovine collagen, is negligible with the autologous collagen. Long-term results are as yet unknown, but from the fact that the collagen molecular structure is intact and there is little risk of foreign body response, it would be expected that autologous preparations would be more stable than bovine collagen; this appears to be the case in cosmetic applications. Autologous collagen could be employed for the same indications as bovine collagen, provided that a delay of 45 days (the time required to prepare the injectable collagen) is acceptable. The amount of collagen required is also a limiting factor, since the patient's own skin is the starting donor material.

KEY WORDS — autologous collagen, injectable substance, vocal fold immobility, voice rehabilitation.

INTRODUCTION

Various clinical trials with injectable bovine collagen have indicated its usefulness for rehabilitation of the voice and deglutition in cases of glottic insufficiency or immobility[1-3] resulting from paralysis, atrophy, scarring, and ablative surgery of the larynx.[4] It has also been shown to be effective in cases of velopharyngeal insufficiency[5] and in cases of leakage around a vocal prosthesis after total laryngectomy.[6] No short- or long-term intolerance that could be directly attributed to the collagen has been reported to date.[7-9]

Injected in its reticulated form obtained by cross-linking with glutaraldehyde, GAX bovine collagen (Phonagel; Zyplast; Collagen Corporation, Palo Alto, Calif), when used to treat vocal fold immobility, has shown 20% degradation of functional results after 4 1/2 years of follow-up; this requires a 20% overinjection.[10] From a biological point of view, it behaves as an active bioimplant resembling human connective tissue, stimulating ingrowth and resulting in its partial replacement by host human connective tissue.[11,12]

Although widely employed in cosmetology with the approval of the Food and Drug Administration in the United States and authorized on the French market (AMM; Autorisation de Mise sur le Marché), the product has never received the same endorsement for use in the pharynx or the larynx, despite the fact that the immunologic risks are, for all practical purposes, identical. Further, the manufacturers have never undertaken the required premarketing authorization procedures.[13]

Injectable bovine collagen is, however, used in many countries. The outbreak in Europe, and particularly in Great Britain, of bovine spongiform encephalopathy, and the risk of its being transmitted to humans in the form of Creutzfeldt-Jakob disease, has increased patient fears of its use.

Ford et al[14] were the first to use injectable autologous collagen (Vocalogen; Collagenesis, Beverly, Mass) to correct glottic insufficiency. This product, prepared from the patient's own skin, eliminates the risk of an immune response. This is the same collagen that we have used, according to our technique and

From the Departments of Otorhinolaryngology–Head and Neck Surgery (Remacle, Lawson), Anatomopathology (Delos), and Biostatistics and Medical Documentation (Jamart), University Hospital of Louvain at Mont-Godinne, Yvoir, Belgium.

CORRESPONDENCE — Marc Remacle, MD, PhD, Dept of Otorhinolaryngology–Head and Neck Surgery, University Hospital of Louvain at Mont-Godinne, 5530 Yvoir, Belgium.

TABLE 1. POPULATION BREAKDOWN

Patient	Sex	Age (y)	Immobility			Complementary Treatment	Follow-up (mo)
			Side	Position	Cause		
1	M	72	Left	Intermediate	Pneumonectomy	Speech therapy	7
2	F	68	Left	Intermediate	Viral	Speech therapy	7
3	M	77	Left	Intermediate	Lung cancer	Speech therapy	6
4	M	71	Left	Intermediate	Aortic artery aneurysm		4
5	M	62	Left	Intermediate	Pneumonectomy	Speech therapy	4
6	M	67	Left	Intermediate	Pneumonectomy	Speech therapy	2
7	M	62	Left	Intermediate	Pneumonectomy	Speech therapy	5
8	M	52	Right	Intermediate	Jugulotympanic glomus	Speech therapy	0.5

indications, for voice rehabilitation in cases of vocal fold immobility.

MATERIALS AND METHODS

Our series consists of 8 patients (1 woman and 7 men) between 52 and 77 years of age (median 67.5 years) at the time of the injection. All 8 suffered from paralysis of 1 vocal fold (7 left, 1 right) in the intermediate position. The immobility was considered permanent (4 after lung lobectomy for cancer, 1 of viral origin, 1 due to a lung cancer, 1 the result of an aortic aneurysm, and 1 after resection of a jugulotympanic glomus; Table 1), and definitive treatment seemed indicated. The affected vocal folds were atrophic and bowed. According to the functional voice assessments (Table 2[10,15]) and the position of the paralyzed vocal fold, a satisfactory recovery was not expected with speech therapy alone. The preoperative and postoperative assessments were based on videostroboscopy as well as on data provided by the EVA (French acronym for Assisted Voice Evaluation) analyzer (National Center for Scientific Research [CNRS], Aix-en-Provence, France).[16] This analyzer provides measurement of the maximum phonation time, volume of air expired during phonation, mean flow rate, usual fundamental frequency, mean intensity, buccal airflow, jitter, and shimmer. Further, a histogram of intensity as a function of the frequency between 0 and 1,000 Hz, obtained with the BK 2033 high-frequency voice analyzer (Bruel & Kjaer, Naerum, Denmark), was marked on a 0 to 4 scale, according to our classification.[10,15]

The 3 options of surgery available in our department (type I thyroplasty according to Isshiki et al[17]; injection of bovine collagen; and injection of autologous collagen) were proposed to the patients, and they all chose and consented to an injection of autologous collagen.

The skin required for extraction of the collagen was taken, under local anesthesia, from either the lower abdominal quadrant, as recommended by Ford et al,[14] or just above the bikini line. A 1 × 5-in section (or 30 cm^2) of skin is necessary to produce 2 mL of injectable collagen, which was the amount necessary in this study for the treatment of paralysis in the intermediate position.[10] The skin sample was placed in sterile saline in a sterile container and frozen before being sent with coolant in a styrofoam container to Collagenesis. Once prepared, the collagen was returned, ready for use, in 1-mL tuberculin syringes. At present, it takes approximately 45 days for the skin sample to be turned into finished, ready-to-use collagen. The autologous collagen syringes can be stored for up to 6 months in a refrigerator at 2°C to 6°C.

TABLE 2. INDIVIDUAL RESULTS OF OBJECTIVE VOICE ASSESSMENT BEFORE AND AFTER COLLAGEN INJECTION

Patient	MPT (s)		PV (dm^3)		MFR (dm^3/s)		BAF (dm^3/s)		F0 (Hz)		Int (dB)		Jitter (%)		Shimmer (%)		Class	
	Pre	Post	Pre	Post	Pre	Post	Pre	Post	Pre	Post	Pre	Post	Pre	Post	Pre	Post	Pre	Post
1	2.1	4.6	0.82	0.86	0.39	0.19	0.58	0.22	113	121	67	68	1.3	0.7	0.3	0.3	2	3
2	10.0	14.0	0.30	0.17	0.02	0.01	0.09	0.01	220	259	68	65	0.3	2.9	0.1	0.2	3	3
3	5.8	10.1	0.54	0.12	0.09	0.01	0.03	0.10	247	157	85	82	2.5	2.9	0.2	0.4	3	3
4	7.0	26.9	1.18	1.27	0.17	0.05	0.26	0.05	93	165	59	83	12.1	20.9	0.8	0.4	1	2
5	5.0	14.0	1.05	0.89	0.21	0.06	0.03	0.10	225	155	67	71	1.9	1.3	0.3	0.1	2	3
6	1.9	8.8	0.93	1.07	0.50	0.12	0.70	0.10	139	134	67	75	20.4	0.5	0.2	0.3	1	2
7	4.2	8.7	1.92	2.14	0.46	0.25	0.65	0.17	180	167	72	82	3.2	0.4	0.2	0.2	2	4
8	3.0	7.3	0.53	0.54	0.27	0.07	0.25	0.06	152	133	65	76	15.3	19.5	0.5	0.8	2	3

MPT — maximum phonation time; PV — volume of air expired during phonation; MFR — mean flow rate; BAF — buccal airflow; F0 — fundamental frequency; Int — mean intensity; class — according to references 10 and 15.

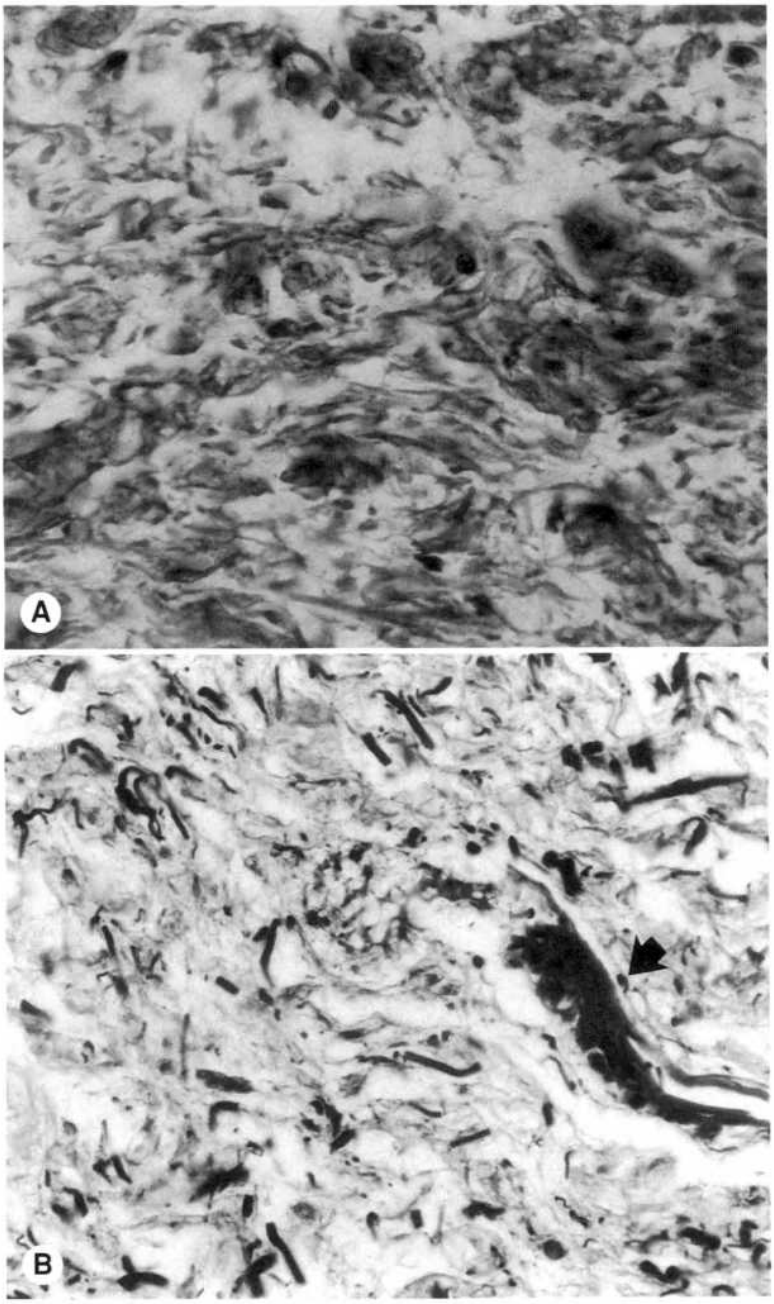

Fig 1. Histologic examination before injection. A) Bundles of collagen fibers (H & E, original ×400). B) Presence of elastin fibers and clusters of epithelial cells (arrow; orcein stain, original ×400).

The autologous collagen fibers are suspended in a neutral phosphate buffer. Electron microscopy has shown the collagen fibers to be intact, with normal banding and periodicity. Unlike bovine collagen, the autologous collagen is not solubilized by enzyme or chemical treatment. The collagen fibers appear identical to collagen fibers in dermal bundles.[14]

Macroscopically, autologous collagen is similar to bovine collagen. A histologic examination of this autologous collagen was carried out before injection (Fig 1). Besides the collagen fibers, elastin fibers and some clusters of epithelial cells were observed.

The injection was carried out under general anesthesia and high-frequency jet ventilation using direct laryngoscopy according to the technique we proposed for bovine collagen.[1] The injection was made into the lamina propria in 3 or 4 sites. The 2 main sites were situated anterior and lateral to the vocal process. It is also advisable to inject medial to the vocal process so as to obtain better glottic closure. A fourth injection site, more anteriorly, may be necessary if the diffusion of the collagen toward the anterior commissure from the first injection site in front of the vocal process is insufficient. The total amount injected was about 1.5 mL. It seems advisable to obtain a 20% hypercorrection, just as for bovine collagen. The remaining collagen in the syringe may be used to inject the other vocal fold if the patient is also suffering from presbyphonia with contralateral

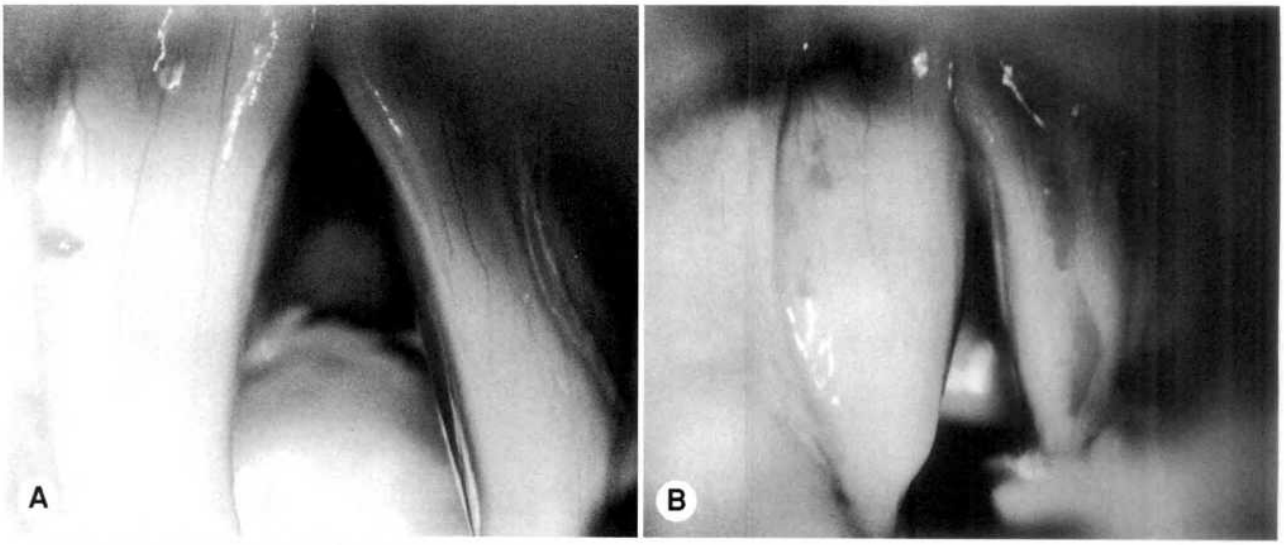

Fig 2. Direct laryngoscopy in patient with paralysis of left vocal fold. A) Aspect before injection. B) Aspect after injection. About 0.2 mL was also injected into right vocal fold (presbyphonia).

atrophy (Fig 2).

We use the injector we developed with a manufacturer (Remacle Injector; Pouret, Paris, France) for bovine collagen. The disposable needle has been modified and is 25-gauge (Fig 3).

Oral antibiotherapy (amoxicillin–clavulanic acid) was administered for 5 to 6 days. Voice rest was limited to the first day. Discharge from the hospital was allowed on the same day. The patients came for a first examination between 10 and 15 days after the operation. Speech therapy was advised as a supplement to the injection.

RESULTS

The 8 patients were neither concerned about the scar left after the skin removal, nor were they hampered in their daily activity. From the technical point of view, we did not encounter any inherent difficulty with the collagen preparation. The ready diffusion of the autologous collagen in Reinke's space was comparable to that of bovine collagen.

No postoperative complications arose. None of the 8 patients suffered any secondary local or general reaction either immediately or in the days that followed.

Resumption of speech, authorized on the first postoperative day, caused no problems, and an improvement of the quality of speech was noted immediately by the patients. Several sessions of speech therapy were, nonetheless, proposed to enable the patient to adapt to the changes. This addressed reducing compensatory laryngeal hyperfunction that had developed secondary to the paralysis.

Stroboscopy disclosed a reduction or correction of the glottic gap. The injected vocal folds kept their normal color and retained their vibratory amplitude. Asymmetry of the vibration phase without phonatory expression was, however, observed.

Individual measurements and summary values are reported in Tables 2 and 3, respectively. Table 3 shows a significant improvement of aerodynamic parameters such as maximum phonation time ($p = .012$), mean flow rate ($p = .012$), and buccal airflow ($p = .036$), but not for acoustic parameters measured by

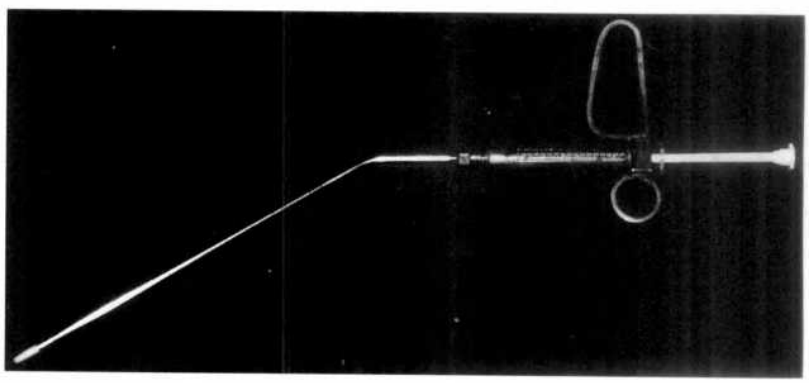

Fig 3. Injector for direct laryngoscopy mounted with disposable needle and syringe containing autologous collagen.

TABLE 3. MEAN AND MEDIAN VALUES OF OBJECTIVE VOICE ASSESSMENT BEFORE AND AFTER COLLAGEN INJECTION (N = 8)

	Pre		*Post*		*Wilcoxon Signed Rank Test*
	Mean ± SD	*Median*	*Mean ± SD*	*Median*	
MPT (s)	4.88 ± 2.73	4.60	11.79 ± 6.87	9.45	p = .012
PV (dm^3)	0.91 ± 0.50	0.88	0.88 ± 0.65	0.88	NS
MFR (dm^3/s)	0.26 ± 0.17	0.24	0.10 ± 0.09	0.07	p = .012
BAF (dm^3/s)	0.32 ± 0.28	0.26	0.10 ± 0.07	0.10	p = .036
F0 (Hz)	171 ± 56	166	161 ± 43	156	NS
Int (dB)	69 ± 8	67	75 ± 7	76	NS
Jitter (%)	7.1 ± 7.7	2.8	6.1 ± 8.7	2.1	NS
Shimmer (%)	0.3 ± 0.2	0.2	0.3 ± 0.2	0.3	NS
Class		2		3	p = .028

NS — not significant. See Table 2 for other abbreviations.

the EVA analyzer.

The use of our classification of spectral analysis graphs from 0 to 4[10,15] shows an improvement from 2 to 3 (median values, p = .028). We found the same values in bovine collagen studies.[1]

DISCUSSION

Concerning intensity, measurement of intensity range instead of mean intensity is perhaps a more sensitive assessment of improvement. Low- and high-intensity sound production with minimal subglottic air pressure requires good glottic closure during phonation and suppleness of the vocal folds.

As with the bovine preparation, the use of autologous collagen did not present a technical problem. Macroscopically, there are no differences between the 2 preparations. The same equipment, anesthesia, and injection technique can be employed as we described for bovine collagen.[1]

Injection in front of the vocal process is similar to the technique used by Ford et al,[2] monitored with indirect laryngoscopy. Injection lateral to the vocal process is especially useful if it concerns a paralysis without cricoarytenoid joint ankylosis. The medial displacement of the arytenoid body favors correction of the glottic gap. The injection in this site is not placed in Reinke's space, but between the vocal process and thyroid ala in the posterior part of the inferior thyroarytenoid muscle.

These first 2 points are often sufficient to obtain an adequate medialization. Injection with a 25-gauge needle allows easy diffusion of the collagen.

The same therapeutic indications as those presented previously for bovine collagen appear appropriate, including congenital or acquired atrophy, paralysis, and scars.

In case of paralysis, the algorithm proposed for bovine collagen, combining microsurgery and speech therapy, is applicable. Speech therapy is often sufficient in case of paralysis in the paramedian position. We inject only those patients complaining of vocal fatigue despite speech therapy, or patients who refuse speech therapy. On the other hand, for paralyses in the intermediate position or in complete abduction, speech therapy will be insufficient. Speech therapy is an indispensable complement to the injection procedure and is used routinely unless the patient refuses.

One of the limiting factors for using autologous collagen is the amount of skin available. Indeed, about 30 cm^2 of skin is required to provide 2 mL of injectable collagen. Certain indications, in which amounts of 5 to 8 mL are necessary, such as velopharyngeal insufficiency[5] or correcting aspiration following reconstructive surgery, can therefore pose a problem. Another limiting factor is, at present, the 45 days required to process the skin and provide the final collagen preparation. A third limiting factor is the abdominal scar, which, however, remains discreet if it is situated at the bikini line.

At present, when faced with the choice, patients prefer autologous rather than bovine collagen so as to avoid the risk of immune response or transmission of illness. It is noteworthy that no hypersensitivity reaction or any transmission of disease has yet been reported in large series using bovine collagen.[2,10]

Apart from there being a markedly reduced risk of immune reaction or transmissible disease compared to use of bovine collagen, it was primarily the likelihood of more stable results that attracted us to autologous collagen. The cross-linked form of bovine collagen (Zyplast and Phonagel) had already led to more stable results, without hypersensitivity reactions, than the earlier forms (Zyderm I and II). Thus, in the case of paralysis of the vocal fold, we had already observed quantitative improvements of speech

as measured by a phonatory quotient of 67% in the short term and 49% in the long term, after a median follow-up of 4 1/2 years.[10] A better persistence of results is expected with autologous collagen, because here the collagen molecule is left intact after the production process, maintaining the telopeptides or the nonhelicoidal parts of the collagen molecule. In the preparation of bovine collagen, these units have to be cleaved to reduce antigenicity and the risk of allergic reactions in the human host. On the other hand, the intact telopeptides are essential for the quarter-stagger formation of collagen fibers and the formation of intermolecular cross-links between adjacent collagen molecules. This organization is entirely preserved in Vocalogen, which provides more resistance to degradation by proteases than that obtained with reconstituted bovine collagen.[14]

The presence of elastin fibers that can be seen (Fig 1B) in the preparation does not create a problem, since these fibers are also a natural component of the lamina propria.

The presence of epithelial cells (Fig 1B) in the implant appears insignificant in the short term. However, the development of an epidermoid cyst could be feared in case of viability of these cells. According to our pathologist (M.D.), the absence of organization of these cells and their low number make this risk unlikely.

It seems to us that collagen is the least objectionable of the injectable bioimplants for the endoscopic treatment of glottic insufficiency. Fat has shown its effectiveness in correcting vocal fold paralysis,[18] but it is also susceptible to a relatively rapid resorption,[19] and it cannot be injected with 22-gauge or smaller needles, so its applications are limited. Teflon's potential to migrate and the inflammatory reactions it causes are well known.[20]

Autologous collagen, therefore, should be retained among the various solutions proposed for the treatment of glottic insufficiency. In our opinion, it is the bioimplant of choice among the proposed injectable substances.

REFERENCES

1. Remacle M, Marbaix E, Hamoir M, Bertrand B, van den Eeckhaut J. Correction of glottic insufficiency by collagen injection. Ann Otol Rhinol Laryngol 1990;99:438-44.

2. Ford CN, Bless DM, Loftus JM. Role of injectable collagen in the treatment of glottic insufficiency: a study of 119 patients. Ann Otol Rhinol Laryngol 1992;101:237-47.

3. Ford CN, Bless DM. Selected problems treated by vocal fold injection of collagen. Am J Otolaryngol 1993;14:257-61.

4. Remacle M, Hamoir M, Marbaix E. GAX-collagen injection to correct aspiration problems after subtotal laryngectomy. Laryngoscope 1990;100:663-9.

5. Remacle M, Bertrand B, Eloy P, Marbaix E. The use of injectable collagen to correct velopharyngeal insufficiency. Laryngoscope 1990;100:269-74.

6. Remacle MJM, Declaye XJM. GAX-collagen injection to correct an enlarged tracheoesophageal fistula for a vocal prosthesis. Laryngoscope 1988;98:1350-2.

7. Ford CN, Gilchrist KW, Bartell TE. Persistence of injectable collagen in the human larynx: a histopathological study. Laryngoscope 1987;97:724-7.

8. Remacle M, Marbaix E. Collagen implants in the human larynx. Pathological examinations of two cases. Arch Otorhinolaryngol 1988;245:203-9.

9. Marbaix E, Remacle M. GAX-collagen in the human vocal fold. Ear Nose Throat J 1991;70:857-60.

10. Remacle M, Dujardin J-M, Lawson G. Treatment of vocal fold immobility by glutaraldehyde–cross-linked collagen injection: long-term results. Ann Otol Rhinol Laryngol 1995;104:437-41.

11. Ford CN. Histologic studies on the fate of soluble collagen injected into canine vocal folds. Laryngoscope 1986;96:1248-57.

12. Remacle M, Marbaix E. Further morphologic studies on collagen injected into canine vocal folds. Ann Otol Rhinol Laryngol 1991;100:1007-14.

13. Remacle M. Injectable collagen, 10 years after... [Editorial]. Ann Otolaryngol Chir Cervicofac 1994;111:55-8.

14. Ford CN, Staskowski PA, Bless DM. Autologous collagen vocal fold injection: a preliminary clinical study. Laryngoscope 1995;105:944-8.

15. Remacle M, Millet B, van Heule P. Clinical application of the high-resolution frequency analyzer. First results. Folia Phoniatr (Basel) 1989;41:259-69.

16. Giovanni A, Robert D, Estublier N, Teston B, Zanaret M, Cannoni M. Objective evaluation of dysphonia: preliminary results of a device allowing simultaneous acoustic and aerodynamic measurements. Folia Phoniatr Logop 1996;48:175-85.

17. Isshiki N, Morita H, Okamura H, Hiramoto M. Thyroplasty as a new phonosurgical technique. Acta Otolaryngol (Stockh) 1974;78:451-7.

18. Brandenburg JH. Vocal cord augmentation with autogenous fat. Laryngoscope 1992;102:495-500.

19. Milkus JL, Koufman JA, Kilpatrick SE. Fate of liposuctioned and purified autologous fat injections in the canine vocal fold. Laryngoscope 1995;105:17-22.

20. Rubin HJ. Misadventures with injectable polytef (Teflon). Arch Otolaryngol 1976;101:114-6.

LEIOMYOSARCOMA OF THE LARYNX

CASE REPORT

SHAWN THOMAS, MS

HOWARD S. MCGUFF, DDS RANDAL A. OTTO, MD

SAN ANTONIO, TEXAS

Leiomyosarcoma involving the larynx is extremely rare and may be difficult to diagnose. Likewise, because of the rarity of this lesion, little information exists with regard to long-term follow-up or optimal management. Reported here is a review of the literature and a case report of a patient with leiomyosarcoma of the larynx treated by surgery alone with 5 years of follow-up.

KEY WORDS — larynx, leiomyosarcoma.

INTRODUCTION

Leiomyosarcoma (LMS) is a malignant soft tissue tumor of smooth muscle origin. The incidence of LMS is reported at 5% to 6% of all soft tissue sarcomas and occurs primarily in the uterus, gastrointestinal tract, and retroperitoneum.[1] There are 20 reported cases of LMS in the nose and paranasal sinuses.[2] However, there are only 5 reported cases of laryngeal LMS in the English-language literature, the first by Frank[3] in 1941 and the most recent by Chen et al[4] in 1991. The long-term results in these reports are even more limited, with only 1 report providing a 3-year follow-up.[5] Thus, due to the uncommon nature of this lesion, very little information exists regarding effective treatment modalities with reliable follow-up. We present a case of a T1N0M0 subglottic LMS treated by total laryngectomy with a 5-year follow-up.

CASE REPORT

A 72-year-old man presented in October 1992 with a 2-month history of increasing shortness of breath, hoarseness, stridor, and a foreign body sensation in his throat. His past medical history was negative for other illnesses, and the patient was a nonsmoker. On physical examination, the patient was mildly stridorous and short of breath. Fiberoptic laryngeal examination demonstrated a smooth, round, subglottic mass obstructing approximately 50% of the patient's airway. The remainder of the examination findings were unremarkable. An axial computed tomography (CT) scan (Fig 1) demonstrated a right subglottic soft tissue mass measuring approximately 2 cm with questionable involvement of the right true vocal cord. No cervical adenopathy was noted.

The patient was taken to the operating room, where a direct laryngoscopy and biopsy of the mass was performed. Subsequently, the subglottic mass was debulked with biopsy forceps and an yttrium-aluminum-garnet laser. A frozen section of the biopsy was interpreted as consistent with sarcoma. One week later, the patient was returned to the operating room, where he underwent a total laryngectomy (Fig 2) and primary tracheoesophageal puncture. Microscopic examination of the resection specimen revealed an exophytic polypoid cellular pleomorphic spindle cell neoplasm. The tumor cells exhibited elongated blunt vesicular nuclei, small nucleoli, focal multinucleation, and eosinophilic cytoplasm with an infiltrative fascicular to storiform growth pattern. Numerous atypical mitotic figures were noted, with a mitotic

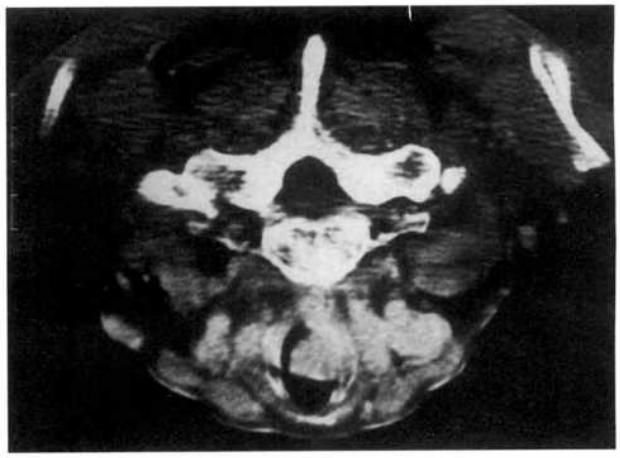

Fig 1. Axial computed tomography scan demonstrating right subglottic mass.

From the Department of Otolaryngology–Head and Neck Surgery, The University of Texas Health Science Center at San Antonio, San Antonio, Texas.

CORRESPONDENCE — Randal A. Otto, MD, Dept of Otolaryngology–Head and Neck Surgery, The University of Texas Health Science Center at San Antonio, 7703 Floyd Curl Dr, San Antonio, TX 78284-7777.

Fig 2. Laryngectomy specimen opened anteriorly, demonstrating lesion.

count of 98 mitoses per 50 high-power fields (HPFs; Fig 3). Immunohistochemical stains demonstrated the tumor to be positive for vimentin and smooth muscle actin. Stains for cytokeratin (AE1/3), epithelial membrane antigen, desmin, S-100 protein, and factor VIII were negative. No associated dysplastic mucosa, carcinoma in situ, or invasive squamous cell carcinoma was identified. A diagnosis of LMS was established. Histologically, the tumor extended into the paraglottic space, but did not invade the cricoid cartilage. The surgical resection margins were negative. The patient's postoperative course was unremarkable. He was sent for speech therapy and progressed well with his tracheoesophageal speech. The patient was followed closely over the next 5 years without complications. As of September 1997, the patient was doing well, without evidence of disease.

DISCUSSION

Cancers of the larynx account for about 2% of all reported malignancies: most of these are carcinomas. Fewer than 1% of laryngeal cancers are sarcomas or malignant tumors of mesenchymal origin.[6] In fact, primary laryngeal sarcomas collectively compose only 0.3% to 1% of laryngeal malignancies.[1] Since the majority of the smooth muscle in this region is found in the walls of blood vessels, LMS is rarely the first diagnosis considered for a mass in this region. The complex and often tedious measures needed for diagnosis make it hard to differentiate LMS from other spindle cell tumors found in this region.

The average age of presentation of LMS of the head and neck is the fifth to sixth decades of life.[4] There appears to be no association with smoking or alcohol use. Common presenting symptoms are those of dysphonia, dysphagia, and stridor. On gross examination, tumors are typically encapsulated and smooth on cut surface. On light microscopic examination the tumor shows interlacing bundles or fascicles of spindle-shaped cells with multinucleate, pleomorphic nuclei. On first inspection this may, as in our case, be initially labeled as a spindle cell tumor. However, when immunohistochemical studies are performed, the differences become more apparent. Immunohistochemistry shows that LMS is positive for vimentin, smooth muscle actin, and neuron-specific enolase while being negative for keratin, epithelial membrane antigen, desmin, S-100 protein, and

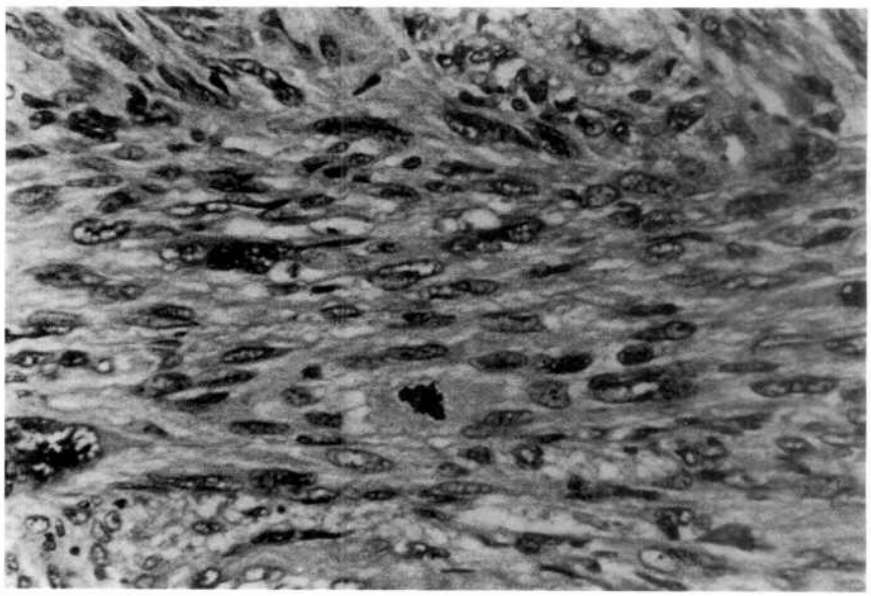

Fig 3. Histologic section demonstrating pleomorphic malignant spindle cell proliferation with high mitotic rate (H & E, original ×25).

factor VIII. It becomes apparent that immunohistochemical studies are a necessary component to the diagnosis of LMS. Electron microscopic examination is also a useful component to the diagnosis, since LMS may be confused with spindle cell carcinoma, fibrosarcoma, rhabdomyosarcoma, malignant fibrous histiocytoma, malignant peripheral nerve sheath tumors, neurofibrosarcoma, and synovial sarcoma. It is common to observe pinocytotic vesicles, dense bodies, basement membrane, and microfilaments under electron microscopy.[2,4]

Once the diagnosis is made, it is also important to characterize the tumor. It is generally agreed that the degree of mitotic activity and, to a lesser extent, tumor size are the most important prognostic indicators.[4] It is not uncommon to see many mitotic figures per HPF. Our specimen showed 98 mitotic figures per 50 HPF. According to Stout and Hill,[7] the number of mitotic figures per HPF is the most important criterion of malignancy, with benign tumors exhibiting 4 or fewer mitoses per HPF. Regarding tumor size, malignant tumors tend to be greater than 5 cm in diameter.[1]

Leiomyosarcomas of the head and neck tend to metastasize hematogenously to the lungs, and careful follow-up imaging is necessary. Regional lymph node involvement tends to occur late, unless the nodes are involved by direct extension, and does not exceed 10% to 15%.[1]

Once a proper assessment and staging has been completed, treatment must be addressed. The treatment of head and neck LMS by wide local extirpation is generally agreed to be the most appropriate therapy.[4,5,8]

Due to the limited number of reported cases, the survival statistics are inadequate. Chen et al[4] describe a successful 18-month postoperative follow-up, and Rowe-Jones et al[9] describe 3 months of follow-up. Both chose some form of extirpation with postoperative irradiation, with successful patient recovery. Tewary and Pahor[5] describe total laryngectomy without postoperative irradiation and a 3-year follow-up. Our case involved complete resection with no postoperative irradiation and a total of 5 years of follow-up. While the number of reported cases is too small to be conclusive, it appears that local resection of LMS of the larynx, where possible, is the appropriate therapy. Cervical lymph node dissection is usually not required. Generally, these are treated as if they are LMSs of some other area of the head and neck, for which more information exists. It has been shown that wide surgical resection is the most effective means of therapy for both primary and recurrent LMSs of the head and neck region.[8] This philosophy has been applied to those tumors that involve the larynx as well. The necessity of postoperative irradiation remains debatable, as LMS is reported to be minimally sensitive to both chemotherapy and irradiation.[10] Due to the rarity of this malignancy, there may never be a consensus on this issue, but confirmation of the diagnosis with immunohistochemical studies, removal by wide excision ensuring negative margins, and follow-up imaging to rule out metastasis appears to be the most prudent form of care. Additional treatment modalities should be tailored to the needs of the patient, since no specific protocol exists.

SUMMARY

Leiomyosarcoma of the larynx is quite rare and may be rather complicated to diagnose. Special histologic studies and electron microscopy are often required to establish the diagnosis. While there are no numbers to support any one standard of care, removal of the tumor by wide excision appears to be the common modality in all cases with any significant follow-up. Postoperative irradiation may prove to be helpful in cases of more conservative resections, when positive margins are encountered, or in cases of advanced or recurrent disease. However, at this time few data exist to clearly define radiotherapy's role in the management of these patients.

REFERENCES

1. Barnes L. Surgical pathology of the head and neck. 3rd ed. New York, NY: Marcel Dekker, 1985:814-9.

2. Kahn J, Korol H. Leiomyosarcoma of the nasal cavity. Arch Otolaryngol Head Neck Surg 1989;115:114-7.

3. Frank DL. Leiomyosarcoma of the larynx. Arch Otolaryngol 1941;34:493-500.

4. Chen JM, Novick WH, Logan CA. Leiomyosarcoma of the larynx. J Otolaryngol 1991;20:345-8.

5. Tewary AK, Pahor AL. Leiomyosarcoma of the larynx: emergency laryngectomy. J Laryngol Otol 1991;105:134-6.

6. Gorenstein A, Neel H, Weiland L, Devine K. Sarcoma of the larynx. Arch Otolaryngol 1980;106:8-11.

7. Stout A, Hill W. Leiomyosarcoma of the superficial soft tissues. Cancer 1958;11:844-54.

8. Mindell R, Calcaterra T, Ward P. Leiomyosarcoma of the head and neck: a review of the literature. Laryngoscope 1975;85:904-10.

9. Rowe-Jones JM, Solomons NB, Ratcliffe NA. Leiomyosarcoma of the larynx. J Laryngol Otol 1994;104:359-62.

10. Fu Y, Perzin K. Nonepithelial tumors of the nasal cavity, paranasal sinuses and nasopharynx; a clinicopathologic study, IV. Cancer 1975;35:1300-8.

QUANTITATIVE GLYCOHISTOCHEMICAL CHARACTERIZATION OF NORMAL NASAL MUCOSA, AND OF SINGLE AS OPPOSED TO MASSIVE NASAL POLYPS

SERGIO HASSID, MD, PHD
BRUSSELS, BELGIUM

GEORGES CHOUFANI, MD
BRUSSELS, BELGIUM

NATHALIE NAGY, MD
BRUSSELS, BELGIUM

HERBERT KALTNER, VMD
MUNICH, GERMANY

ANDRE DANGUY, PHD
BRUSSELS, BELGIUM

HANS-JOACHIM GABIUS, PHD
MUNICH, GERMANY

ROBERT KISS, PHD
BRUSSELS, BELGIUM

A series of 41 nasal polyps (23 single and 18 massive) and 6 normal nasal mucosa specimens was glycohistochemically investigated. Five plant lectins were used, ie, the peanut agglutinin (PNA), the wheat germ agglutinin (WGA), the gorse seed agglutinin (UEA-I), the *Maackia amurensis* agglutinin (MAA), and the elderberry bark agglutinin (SNA). A neoglycoconjugate and 2 animal lectins (CL-14 and CL-16) were also used. Three quantitative features were calculated by means of computer-assisted microscopy: the percentage of tissue area specifically stained by the histochemical probe, the staining intensity, and the heterogeneity level of the staining distribution. The results show that with respect to sialic acid–glycoprotein binding characteristics as determined by SNA, MAA, and WGA probes, the normal nasal mucosa differed markedly ($p < .00001$) from the polyposal one. The single nasal polyps exhibited glycohistochemical characteristics that differed markedly ($p = .0004$) from those exhibited by the massive ones. These differences related mainly to the UEA-I, PNA, and the Thomsen-Friedenreich antigen–exposing neoglycoprotein binding characteristics. In conclusion, the present study shows unambiguously that polyposal mucosa, whether of the single or the massive type, exhibits markedly distinct glycohistochemical characteristics when compared to normal nasal mucosa, and that single nasal polyps also differ markedly from massive ones.

KEY WORDS — computer-assisted microscopy, lectin, nasal mucosa, polyps.

INTRODUCTION

Nasal polyposis is a common disease that remains poorly understood. The polyps arise mainly from the ethmoid sinuses and then prolapse into the nasal cavity. Although various causes can be suspected, the clinical and histologic features of this disorder are rather similar.[1] This disease is frequently associated with sinusitis, asthma, aspirin intolerance, and cystic fibrosis. Systemic allergy and allergy in the nasal mucosa are still being debated as the underlying cause of nasal polyps.[2,3] From a histologic point of view, 4 different morphological types of nasal polyps are described,[4,5] but without any relationship with the different associated disorders.[6]

We recently proposed a classification for nasal polyps.[7] This classification relies mainly on morphological criteria relating to morphonuclear features from isolated Feulgen-stained nuclei (ie, quantitatively describing chromatin patterns), and only secondarily on glycohistochemical markers that include 3 lectins — the peanut (PNA; isolated from *Arachis hypogaea*), the wheat germ (WGA; isolated from *Triticum vulgaris*), and the gorse seed (UEA-I; isolated from *Ulex europaeus*) agglutinins — and 1 neoglycoconjugate carrying the galactose-β1-3-N-acetylgalactosamine epitope. This epitope represents the key saccharide unit of the Thomsen-Friedenreich (TF) antigen, which visualizes accessible acceptor sites for PNA-reactive glycoconjugates that are endogenously expressed by various tissues.[8] The data obtained showed that our morphological classification of nasal polyps fits in with the classification of nasal polyps defined on the basis of clinical criteria.[7] The gap in our knowledge that the present investigation aims to fill relates to the identification of various glycoproteins specifically expressed by certain groups of nasal polyps and not by others; our ultimate goal is to set up a robust classification for nasal polyps, because there is no consensus in the clinical classification of nasal polyps at the present time. The present study therefore represents a large ex-

From the Departments of Otorhinolaryngology (Hassid, Choufani) and Pathology (Nagy), Academic Erasmus Hospital, and the Laboratory of Histology, Faculty of Medicine (Danguy, Kiss), Université Libre de Bruxelles, Brussels, Belgium, and the Institute of Physiological Chemistry, Ludwig-Maximilians University, Munich, Germany (Kaltner, Gabius). Dr Kiss is a Senior Research Associate with the "Fonds National de la Recherche Scientifique" (FNRS, Brussels, Belgium). This work was carried out on the basis of grants awarded by the "Fonds de la Recherche Scientifique Médicale" (FRSM), Belgium.

CORRESPONDENCE — Robert Kiss, PhD, Laboratory of Histology, Faculty of Medicine, Université Libre de Bruxelles, 808 route de Lennik, 1070 Brussels, Belgium.

LISTING OF VARIOUS GLYCOHISTOCHEMICAL PROBES UNDER INVESTIGATION IN RELATION TO NATURE OF THEIR BINDING SITES

Origin of Probe	*Abbreviation*	*Nature of Binding Site*
Plant lectins		
Arachis hypogaea	PNA	TF antigen, ie, Galβ1-3GalNAc
Triticum vulgaris	WGA	GlcNAc/N-acetyl-neuraminic acid
Ulex europaeus	UEA-I	α-L-fucose
Maackia amurensis	MAA	Sialic acid in α2,3 linkage
Sambucus nigra	SNA	Sialic acid in α2,6 linkage
Animal lectins		
14 kd Galectin	CL-14	Subunit molecular weight of 14,000; from adult chicken intestine, which binds to β-galactosides
16 kd Galectin	CL-16	Subunit molecular weight of 16,000; from adult chicken liver, which binds to β-galactosides
Neoglycoprotein		
TF antigen–(Galβ1,3GalNAc) neoglycoprotein		TF antigen binding site(s)

tension of the first glycohistochemically related modifications evidenced in our previous study[7] on these various groups of nasal polyps.

Peanut agglutinin, WGA, and UEA-I, the glycohistochemical ligands used in the original histopathologic nasal polyp classification proposal[7] mentioned above, identify galactose-β1-3-N-acetylgalactosamine, N-acetylglucosamine/N-acetyl neuraminic acid, and α-L-fucose residues, respectively, on glycoproteins located at either the surface or the glandular epithelium of nasal polyps.[9] The aim of the present study is to further characterize the glycohistochemical characteristics of 2 specific groups of nasal polyps (single and massive) in comparison with normal nasal mucosa. Clinicians usually consider that single polyps develop into massive ones. We investigated, therefore, whether single and massive nasal polyps can exhibit distinct biological properties. In addition to the PNA, WGA, and UEA-I glycohistochemical probes and the TF antigen–related neoglycoprotein that we used previously[7,9] and that we use again in the present work to validate the methodology, we also used 4 other probes (2 sialic acid–binding plant lectins: MAA and SNA) to further characterize the expression of different sets of sialylated glycoproteins and 2 animal (chicken) lectins (galectins CL-14 and CL-16),[10,11] to study the display of β-galactoside–containing glycoconjugates. Like plant lectins with galactoside specificity, galectins are known to have immunomodulatory potency.[10,12-14] This potency may, in turn, have a bearing on the course of the development of nasal polyps.[2,3] The MAA (isolated from *Maackia amurensis*) and SNA (isolated from *Sambucus nigra*) probes identify sialic acid-α2,3-galactose-β1,4-N-acetylglucosamine and sialic acid-α2,6-galactose/N-acetylgalactosamine sequences, respectively. The β–galactoside-binding CL-14 and CL-16 galectins were isolated from chicken intestines and liver, respectively.[11]

MATERIALS AND METHODS

Histopathologic Diagnosis and Clinical Data. Medical records and samples of nasal polyps were obtained for 41 patients between 1993 and 1996. The polyposis diagnosis was made with a rigid endoscope. This method enabled us to distinguish between single polyps, typically found between the lateral nasal wall and the middle turbinate, and diffuse (eg, massive) polyposis, which involves the entire nasal and paranasal sinus mucosa. We excluded from our study polyposis relating to cystic fibrosis and the ASA (aspirin, sinusitis, asthma) triad because of the specific clinical features exhibited by these types of nasal polyps. The possibility remains that a single polyp could be the early stage of what would become massive polyposis in the absence of treatment. Such single polyps are usually found bilaterally in patients; when observed only unilaterally, they are associated with computed tomography scan opacities in the contralateral ethmoid sinus. On the other hand, there are strictly unilateral single polyps, the best-known of which is the antrochoanal polyp described by Killian. In the present study, the single polyps under investigation were always located bilaterally. Other, "single-type" polyps, like the Killian ones, were excluded and are under investigation in a separate study.

The histologic slides of all 41 cases were reviewed by 2 pathologists (to exclude interindividual variability) on the basis of the criteria described by Hyams et al.[5] The 6 normal samples came from the inferior turbinates of patients who had undergone septoplasties and who had proved to be free of any nasal and paranasal disease. We excluded allergic patients on the basis of the skin prick test and total and specific IgE expression.[15]

Specimen Preparations and Glycohistochemical Staining. Tissue specimens were fixed in 4% formaldehyde and embedded in paraffin. Five-micron-thick sections were then subjected to processing with the various histochemical probes and kit reagents under study. All the probes used in the present study are listed in the Table, along with the biochemical na-

ture of their binding sites. The 5 plant-related biotinylated probes were purchased from Vector Laboratories Inc (Burlingame, Calif). We also used 2 biotinylated β-galactoside–binding animal lectins, namely, 14 kd CL-14 and 16 kd CL-16. These proteins from the prototype group of the galectin family were isolated from adult chicken liver and intestine. The neoglycoconjugate related to the chemical grafting of Galβ1,3GalNAc (TF antigen) onto an inert glycohistochemical carrier (bovine serum albumin). As described elsewhere,[9,16] the animal lectins and the neoglycoconjugate were prepared and biotinylated under activity-preserving conditions. The extent of the specifically bound markers was revealed by avidin-biotin-peroxidase complex kit reagents (Vector Laboratories) with diaminobenzidine–hydrogen peroxide as the chromogenic substrate; this is detailed elsewhere.[17] Control reactions included 1) competitive inhibitions to ascertain the sugar specificity and 2) the omission of the incubation step with the labeled marker to exclude any staining by the binding of kit reagents such as the mannose-rich glycoproteins horseradish peroxidase and avidin. Counterstaining with hematoxylin concluded the processing.

Computer-Assisted Microscopy. The variables from the quantitative histochemical stainings were computed by means of a SAMBA 2005 computer-assisted microscope system (Alcatel-TITN, Grenoble, France) with a 20× (aperture 0.50) magnification lens. The way in which we used this system to quantify histochemical staining is detailed elsewhere, as are the ways in which we dealt with all the problems relating to quantitative histochemistry.[7,18] But briefly, and bearing in mind the quantitative histochemical measurements, the tissue-integrated optical densities (IODs) for the hematoxylin (blue) and the specific glycohistochemical (brown) staining were computed on 256 densitometric levels on each digitized pixel in 2 distinct color channels by means of a JVC KY-15 3CCD color camera.

The sum of all the IOD values computed for the whole area scanned per normal or pathological nasal mucosa is known as the labeling index (LI) feature. The cutoff value chosen to ascertain whether the histochemical staining was positive as compared to the negative control was the mean value of the integrated optical values of the negative control plus 2 standard deviations. The mean optical density (MOD) feature relates to staining intensity. It was calculated by dividing the LI value obtained for a given field on a given histologic slide by the area covered by this field. The concentration heterogeneity (CH) feature represents the value of the variance calculated for the MOD feature.

Fifteen fields of between 60,000 and 120,000 μm^2 each were scanned independently for the surface and glandular epithelium on each histologic slide.

Data Analysis. The assessment of the binding of the 8 glycohistochemical markers described above led to the acquisition of 3 quantitative parameters (the LI, MOD, and CH features) for each of the 47 nasal specimens under study. These parameters were computed independently at the surface and the glandular epithelium of each case. The degree of potential diagnostic value for the 48 quantitative glycohistochemical variables (3 quantitative features × 8 probes × 2 epithelia) was determined by means of discriminant analysis, a multivariate statistical type of analysis.[19,20] The variables identified as the most informative by discriminant analysis were also subjected to a process of monovariate analysis. The nonparametric Mann-Whitney U test was used, because the Levene test showed that the variances between the various groups were not equal. All the statistical analyses carried out in the present study were performed on the program in the Statistica (Statsoft, Tulsa, Okla) package.

RESULTS

Selection of Quantitative Variables Making It Possible to Distinguish Between Normal and Polyposal Nasal Mucosa. Of the 8 glycohistochemical probes under study (listed in the Table), 6 were used to investigate whether the surface (the SE tissue) and/or the glandular (the GE tissue) epithelia in polyposal nasal mucosa displayed significantly distinct carbohydrate moieties as compared to normal nasal mucosa. These 6 probes included PNA and the TF antigen–exposing neoglycoprotein (the so-called TF-NEO probe in our study), UEA-I, WGA, MAA, and SNA. Computer-assisted microscopy calculated 3 variables (LI, MOD, and CH) for each of these 6 probes in both epithelia. Six probes × 3 variables per probe × 2 epithelium types, ie, 36 quantitative variables, were therefore available to characterize the carbohydrate moieties and distinct sugar receptor types in normal as opposed to polyposal nasal mucosa on the one hand, and between single and massive nasal polyps on the other.

Of the 36 quantitative variables submitted to discriminant analysis, the 4 most discriminatory selected by this multivariate statistical analysis to distinguish between the 3 groups comprising normal (the NORM group; n = 6), single polyposal (the SIN group; n = 23), and massive polyposal (the MASS group; n = 18) nasal mucosa specimens were as follows, in order of decreasing discriminatory power.

1. The SNA_MOD_SE variable, ie, the mean op-

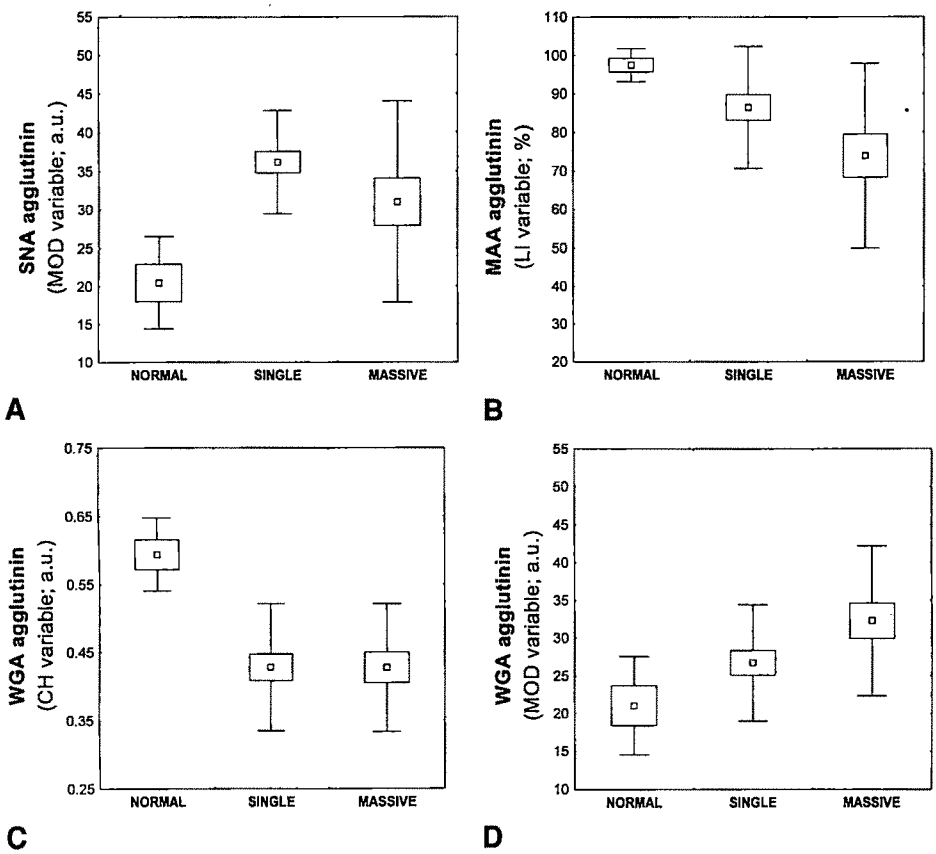

Fig 1. Illustration of mean (small squares) ± SEM (large squares) ± SD (bars) quantitative values obtained by means of computer-assisted microscopy with respect to 4 glycohistochemical binding properties in 6 normal nasal mucosa specimens (NORM group), and 23 single (SIN group) and 18 massive (MASS group) nasal polyps. Four quantitative glycohistochemical features are A) SNA_MOD_SE variable, ie, mean optical density (staining intensity in arbitrary units [a.u.]) of SNA in surface epithelium; B) MAA_LI_SE variable, ie, labeling index (labeled area) of MAA in surface epithelium; C) WGA_CH_GE variable, ie, heterogeneity level in WGA staining intensity in glandular epithelium; and D) WGA_MOD_GE variable, ie, mean optical density of WGA in glandular epithelium.

tical density (staining intensity) of SNA in the surface epithelium.

2. The MAA_LI_SE variable, ie, the labeling index (labeled area) of MAA in the surface epithelium.

3. The WGA_CH_GE variable, ie, the heterogeneity level of the WGA staining intensity in the glandular epithelium.

4. The WGA_MOD_GE variable, ie, the mean optical density of WGA in the glandular epithelium.

When these 4 quantitative variables were introduced into a new discriminant analysis, the NORM group differed markedly from the SIN ($p < .00001$) and the MASS ($p < .00001$) groups, while the SIN and the MASS groups did not significantly ($p = .144$) differ in these 3-group analyses. As shown below, the absence in the present 3-group analysis of any statistically significant differences between single and massive nasal polyps is due to the fact that the glycohistochemical characteristics of the normal nasal mucosa are so different from those exhibited either by the single or the massive nasal polyps that the information contributed by the normal nasal mucosa heavily outweighs that which might distinguish between single and massive polyps. This is the reason we performed a new discriminant analysis, in which the normal nasal mucosa specimens were not taken into account (see below).

Figure 1 illustrates the mean ± SEM ± SD values obtained for the SNA_MOD_SE, the MAA_LI_SE, the WGA_CH_GE, and the WGA_MOD_GE variables in the NORM, the SIN, and the MASS groups.

Monovariate statistical analyses (Mann-Whitney U test) revealed that the NORM group significantly ($p = .02$) differed from the SIN group, but not the MASS group, on the basis of the SNA staining intensity in the surface epithelium (SNA_MOD_SE variable; Fig 1A). The quantification of the MAA-labeled area in the surface epithelium (MAA_LI_SE variable) made it possible to distinguish between the NORM group and both the SIN ($p = .04$) and the MASS ($p = .004$) groups (Fig 1B).

The heterogeneity level of the WGA staining intensity in the glandular epithelium (WGA_CH_GE variable) was markedly higher in the NORM group than in both the SIN ($p = .007$) and the MASS ($p = .008$) groups (Fig 1C).

The WGA staining intensity in the glandular epithelium of the normal nasal mucosa was significantly ($p = .03$) lower than in the MASS group, but not lower ($p = .243$) than in the SIN group (Fig 1D).

Selection of Quantitative Variables to Distinguish Between Single and Massive Nasal Polyps and to Identify Typical Versus Atypical Single and Massive

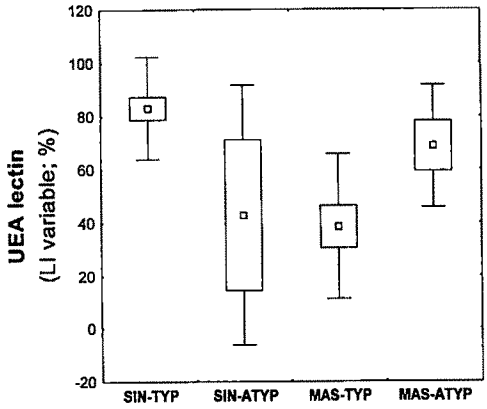

Fig 2. Illustration of mean (small squares) ± SEM (large squares) ± SD (bars) values obtained quantitatively by means of computer-assisted microscopy with respect to UEA-I_LI_SE variable. This variable describes UEA-I–labeled area in surface epithelium in 4 groups of nasal polyps, ie, typical (SIN_TYP group; n = 20) versus atypical (SIN_ATYP group; n = 3) single nasal polyps and typical (MASS_TYP group; n = 12) versus atypical (MASS_ATYP group; n = 6) massive ones.

Nasal Polyps. The 36 quantitative variables described above were further submitted to a discriminant analysis performed between the 2 groups of single and massive nasal polyps only. Of these 36 variables, the 4 most discriminatory in distinguishing between single and massive nasal polyps were as follows, in order of decreasing discriminatory power.

1. The UEA-I_LI_SE variable, which quantitatively described the UEA-I–labeled area in the surface epithelium and which was significantly (p = .004) weaker in the MASS group than in the SIN group (data not shown).

2. The PNA_CH_SE variable, which quantitatively described the heterogeneity level of the PNA staining in the surface epithelium and which was weaker (p = .04) in the MASS group than in the SIN group (data not shown).

3. The WGA_CH_SE variable, which quantitatively described the heterogeneity level of the WGA staining in the surface epithelium and which was higher in the MASS group than in the SIN group (data not shown).

4. The TF-NEO_MOD_SE variable, which quantitatively described the TF antigen–exposing neoglycoprotein staining intensity in the surface epithelium and which was weaker (p = .03) in the MASS group than in the SIN group (data not shown).

When we made use of these 4 quantitative variables in a new discriminant analysis, the SIN group markedly (p = .0004) differed from the MASS group.

In addition to making it possible to identify the most relevant informative variables in a large set of variables, discriminant analysis can also be used as a tool to classify cases across groups. Indeed, discriminant analysis enables data to be described in terms of "separability" between different a priori defined groups, eg, in the present cases the 2 groups containing the single polyps and the massive nasal polyps. Discriminant analysis is therefore able to generate a description of data as a function of discriminant factors that give prominence to the differential features of cases from distinct groups. As discriminant factors give the best representation for separating data into different classes, discriminant analysis uses these factors to allocate a case to one or another of them. The confusion matrix for the classifications produced by discriminant analysis on the 23 single polyps versus the 18 massive nasal polyps with the 4 quantitative variables described above is as follows. Of the 23 single nasal polyps, 20 were correctly classified as single polyps, while 3 single polyps were misclassified as massive ones on the basis of their glycohistochemical characteristics. The first group of 20 polyps was labeled as typical single nasal polyps (the SIN_TYP group), while the second group of 3 polyps was labeled as atypical single nasal polyps (the SIN_ATYP group). In the same way, discriminant analysis correctly classified 12 of the massive nasal polyps as massive (the MASS_TYP group) while misclassifying the remaining 6 as single (the MASS_ATYP group).

Figure 2 illustrates the mean ± SEM ± SD values of the quantitative glycohistochemical variable selected as the most informative by discriminant analysis, ie, the UEA-I_LI_SE variable, which quantitatively described the UEA-I–labeled area in the surface epithelium in the 4 groups described above, ie, the SIN_TYP versus the SIN_ATYP and the MASS_TYP versus the MASS_ATYP. With respect to this UEA-I_LI_SE variable, the SIN_TYP polyps differed markedly (p = .0004) from the MASS_TYP ones, while both the SIN_ATYP and MASS_ATYP polyps exhibited UEA-I_LI_SE values intermediate to those exhibited by the 2 typical groups.

Selection of Quantitative Variables to Distinguish Between Typical Versus Atypical Single Nasal Polyps and Between Typical Versus Atypical Massive Nasal Polyps. When discriminant analysis was performed on the 12 quantitative variables (3 quantitative features × 2 probes × 2 epithelium types) describing the CL-14 and CL-16 avian galectin stain (which had previously not been used to distinguish the atypical nasal polyps from their homologous typical counterparts), a significant (p = .003) difference between the galectin-related characteristics in the 3 atypical single polyps versus the 6 atypical massive

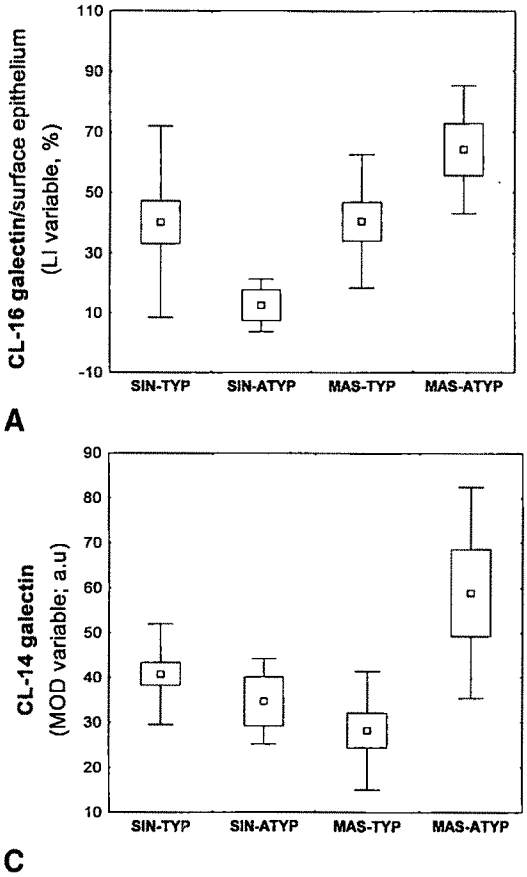

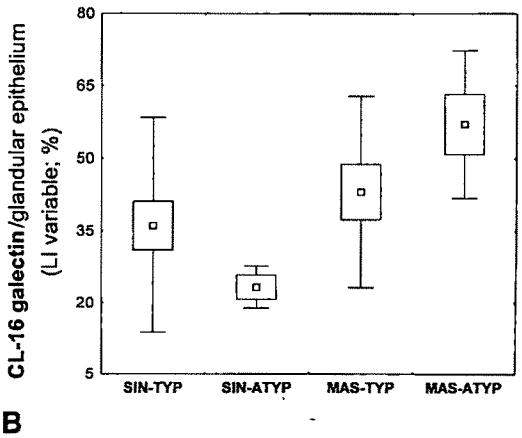

Fig 3. Illustration of mean (small squares) ± SEM (large squares) ± SD (bars) values obtained by means of computer-assisted microscopy with respect to 3 quantitative features describing CL-14 and CL-16 chicken galectin binding characteristics in 4 groups of nasal polyps, ie, typical (SIN_TYP group; n = 20) versus atypical (SIN_ATYP group; n = 3) single nasal polyps and typical (MASS_TYP group; n = 12) versus atypical (MASS_ATYP group; n = 6) massive ones. Three quantitative features relate to A) CL-16_LI_SE variable, which describes CL-16 galectin–labeled area in surface epithelium; B) CL-16_LI_GE variable, which describes CL-16 galectin–labeled area in glandular epithelium; and C) CL-14_MOD_SE variable, which describes CL-14 galectin–labeled area in surface epithelium.

polyps was obtained. This fact clearly indicates that atypical single and atypical massive nasal polyps do not represent an intermediate state between typical single and typical massive ones. Of the 12 quantitative variables, the 3 selected as the most informative by discriminant analysis are as follows, in order of decreasing discriminatory power.

1. The CL-16_LI_SE variable, which quantitatively described the CL-16 galectin–labeled area in the surface epithelium and which was higher (p = .02) in the atypical massive polyps than in the atypical single ones (Fig 3A).

2. The CL-16_LI_GE variable, which quantitatively described the CL-16 galectin–labeled area in the glandular epithelium and whose development was identical to that of CL-16_LI_SE (Fig 3B; SIN_ATYP versus MASS_ATYP, p = .02).

3. The CL-14_MOD_SE variable, which quantitatively described the CL-14 galectin–labeled area in the surface epithelium and which was significantly (p = .02) higher in the atypical massive polyps than in the atypical single nasal polyps (Fig 3C).

DISCUSSION

Polyps have a uniform histologic appearance and are usually considered to be single entities.[21] However, a nasal mucosa is only capable of acting in a limited number of ways, and the same histologic picture may be produced by a number of different disorders.[2,4,5] We recently presented a new classification of nasal polyps based on morphological criteria relating to morphonuclear features from isolated Feulgen-stained nuclei, as well as on glycohistochemical characteristics from histologic slides submitted to lectin and neoglycoconjugate glycohistochemical stainings.[7] In the present study we further investigated the glycohistochemical patterns of 2 groups of nasal polyps (single and massive) in comparison with normal nasal mucosa specimens. It should be emphasized that glycan moieties harbor the capacity to undergo modulations that can translate into altered recognition properties.[22] Furthermore, glycosylation is highly sensitive to alterations in cell function, and abnormal glycosylation is characteristic of a number of altered cell states.[23,24] Therefore, glycocompounds are used more and more in histochemical studies as probes to detect different types of glycans and sugar moieties in cell membranes and the histologic structures of tumoral tissues associated with various levels of malignancy.[15,25-28]

In addition to the 4 glycohistochemical probes described above, we made use of 2 plant lectins (SNA and MAA) that specifically bind to the abundant iso-

mers of sialyllactose. Sialoglycoconjugates play very important roles in the physiology of normal and transformed cells.[29-31] Sialic acids are 9-carbon monosaccharides usually found at the nonreducing terminus of the glycan side chains attached to glycoconjugates. The linkages of sialic acids to penultimate carbohydrates such as galactose, N-acetylgalactosamine, and N-acetylglucosamine are most commonly α2,3- and α2,6-links formed by the action of different sialyltransferases.[32] Of the lectins with well-characterized oligosaccharide-binding specificity, only a few exhibit any specificity for sialylated glycoconjugates. The lectin from elderberry (*Sambucus nigra*) bark (SNA) has been shown to bind with a high level of affinity to glycoconjugates containing the terminal sequence sialic acid-α2,6-galactose/N-acetylgalactosamine.[33] Investigations into the carbohydrate-binding specificity of the agglutinin from *Maackia amurensis* (MAA) have revealed that it binds with a high level of affinity to sialic acid-α2,3-galactose-β1,4-N-acetylglucosamine, but not to the sialic acid–α2,6–linked isomers.[34] It is therefore a most interesting complementary probe to SNA. In addition, WGA can also bind to N-acetylneuraminic acid in cellular glycoconjugates.[35]

Several interesting observations were made possible in the present study by the use of glycohistochemical probes that are not highly specific in terms of binding to sialic acid–related compounds like WGA and, in sharp contrast, the use of probes like SNA and MAA that exhibit highly specific binding properties (for instance, in distinguishing between α2,6- and α2,3-linked sialic acid and residues). In fact, the results show that the normal nasal mucosa differed markedly from the polyposal one in terms of SNA and MAA binding characteristics, and to a lesser extent in terms of WGA binding characteristics. A precise analysis of the quantitative data provided by computer-assisted microscopy showed that a polyposal mucosa, whether of the single or the massive type, is distinct from its normal counterpart in that it contains a higher proportion of epithelial cells exhibiting significant amounts of SNA-related acceptor sites (as revealed by the SNA_LI_SE variable; data not shown), in the shape of Neu5Ac-α2,6-linked residues, and that these SNA-positive surface epithelial cells in the polyposal mucosa contain a higher number of SNA acceptor sites than their homologs in the normal mucosa (as revealed by the SNA_MOD_SE variable; Fig 1A). A distinct feature was observed in the expression of terminal Neu5Ac-α2,3–linked sugar moieties constituting the MAA acceptor sites. Indeed, the epithelial cells in the surface epithelium of the polyposal mucosa exhibited a number of MAA acceptor sites similar to the one observed in the normal nasal mucosa (as revealed by the MAA_MOD_SE variable; data not shown), while the proportion of MAA-positive cells decreased in the surface epithelium of the polyposal mucosa as compared to what occurred in the normal mucosa (as revealed by the MAA_LI_SE variable; Fig 1B). The type of modification by sialylation occurring at the level of the linkage type (α2,3 versus α2,6) of terminal neuraminic acids therefore made it possible to distinguish between epithelial cells in the polyposal mucosa and the normal nasal mucosa. At the glandular epithelium level, there were modifications involving the amount of WGA acceptor sites (as revealed by the WGA_MOD_GE variable; Fig 1D) and their distribution in the glandular tissue (as revealed by the WGA_CH_GE variable; Fig 1C); these modifications enabled differences between the normal and the polyposal mucosae to be discerned.

The specificity of the glycohistochemical staining related to the SNA and MAA, but not the WGA, lectins seems to be extremely significant in terms of the distinction that can be made between normal and polyposal nasal mucosae, since these MAA and SNA probes were not selected by discriminant analysis when the normal nasal mucosa was no longer taken into account. Indeed, the quantitative computer-assisted microscopy–related variables enabling statistically significant glycohistochemical characteristics to be detected between single and massive nasal polyps included the UEA-I–labeled area in the surface epithelium, the heterogeneity level of the PNA staining in the surface epithelium, the heterogeneity level of the WGA staining in the surface epithelium, and the TF antigen–carrying neoglycoprotein staining intensity in the surface epithelium. These 4 variables refer to the surface and not the glandular epithelium. This means that we observed glycohistochemical modifications in the surface epithelium rather than in the glandular one. This enabled the single polyps to be distinguished from the massive ones.

A comment must be made on the origins of nasal polyps, ie, the ethmoid sinus mucosa (middle meatus), as opposed to the normal controls that we used and that included nasal mucosa from the inferior turbinate. Clinical experience clearly shows that both in single polyps and massive polyposis the inferior turbinate remains unaffected by the polyp disease. In fact, the mucosa in the inferior turbinate is so morphologically distinct from the nasal polyp mucosa (even if both epithelia are rather similar) that it comes as no surprise that nasal polyps generally arise from the middle meatus. As our investigation clearly shows, the normal controls that we used exhibited

markedly distinct glycohistochemical characteristics when compared to the various groups of nasal polyps. This is the reason why we used these controls, since we wanted to demonstrate the specificity of the glycohistochemical markers with respect to the different groups of nasal polyps and not to the distinction that can be drawn between normal mucosa and nasal polyps. To this end, we are conducting a separate study in which we characterize the glycohistochemical properties of normal mucosa from the inferior turbinate as opposed to that from the middle meatus. All these data will contribute to the understanding of nasal polyp etiopathogenesis.

The glycohistochemical variables decribed above relate to the staining of UEA-I, PNA, the TF antigen–exposing neoglycoprotein, and WGA. They not only enabled a very significant distinction to be drawn between the single and the massive polyps, but also made it possible to identify atypical cases in each of the 2 groups of polyps. At first sight, it could be imagined that the atypical cases might represent transitional stages between each of the 2 groups of single and massive nasal polyps, particularly in view of the results given in Fig 2. This is the reason why, in addition to the 6 probes already described (PNA and its corresponding TF antigen–exposing neoglycoprotein, UEA-I, WGA, MAA, and SNA), we also investigated further glycohistochemical properties. Since the terminal part of the sugar antennae of cell glycoconjugates is generally supposed to be accessible and suited to interactions, we deliberately employed 2 probes with affinities to β-galactosides and 3'-substituted derivatives thereof. We therefore used 2 avian lectins[10,11] belonging to the group of galectins in order to investigate whether atypical single and atypical massive nasal polyps represent transitional stages between typical single polyps and typical massive polyps, or if they represent distinct biological units.

Galectins are a family of proteins defined as having at least 1 characteristic carbohydrate recognition domain with an affinity for β-galactosides and sharing certain preserved sequence elements.[36] The most widely studied galectins include galectin-1 and galectin-3.[37] In some instances, these have been shown to modulate cell-cell interactions and cell growth.[38,39] Focusing on the related galectins used in this study, it is pertinent to recall that they have been shown to display nonidentical fine specificities that even translate into differential reactivities to specimens from advanced lung cancer cases.[11,19,40]

The results obtained here with the CL-14 and CL-16 avian galectins show that of the 12 quantitative variables describing the binding characteristics of these galectins, the 3 most informative for the characterization of the atypical specimens in both the single and the massive nasal polyps were the CL-16–labeled areas in the surface and glandular epithelium, and the CL-14–labeled area in the surface epithelium.

In conclusion, the present study clearly shows that in normal nasal mucosa, the surface epithelium and to a lesser extent, the glandular epithelium exhibit glycohistochemical characteristics markedly distinct from those of surface epithelium in polyposal nasal mucosa. In addition, single polyps also exhibit glycohistochemical characteristics very different from those exhibited by massive nasal polyps. These findings suggest that single and massive polyposis represent 2 distinct clinical entities. The clinical significance of the biological existence of atypical groups among single and massive polyps is not yet known. Further analyses of the patients' clinical histories are in progress in order to determine whether these atypical groups of nasal polyps have disparate clinical behavior patterns.

All the data reported in the present study strongly suggest that the specific modifications, in terms of glycohistochemical characteristics, that we identified in the various nasal polyp groups should relate to the etiopathogenesis of the different polyp types. However, significant conclusions concerning the relationship between specific glycohistochemical modifications and nasal polyp etiopathogenesis will be drawn only when data on other biological markers are available, and in particular, data on the level of expression of various adhesion molecules. We are accordingly conducting new experiments into the level of expression of various ICAM-1– and VCAM-1–related molecules in relation to the level of expression of the markers used in the present work.

REFERENCES

1. Jankowski R, Bene MC, Monoret-Vautrin AD, et al. Immunohistological characteristics of nasal polyps. Rhinology 1989;8:51-8.

2. Bernstein J, Gorfien J, Noble B. Role of allergy in nasal polyposis: a review. Otolaryngol Head Neck Surg 1995;113: 724-32.

3. Shatkin JS, Delsupehe KG, Thisted RA, Corey JP. Mucosal allergy in the absence of systemic allergy in nasal polyposis and rhinitis: a meta analysis. Otolaryngol Head Neck Surg 1994;111:553-6.

4. Hellquist HB. Pathology of the nose and paranasal sinuses. London, England: Butterworths, 1990:24-32.

5. Hyams VJ, Batsakis JG, Michaels L. Nasal and paranasal polyposis. In: Hyams VJ, Batsakis JG, Michaels L, eds. Tumors of the upper respiratory tract and ear. Fascicle 25. Second series. Washington, DC: Armed Forces Institute of Pathology,

1988:11.

6. Davidson A, Hellquist HB. The so-called "allergic" nasal polyp. ORL J Otorhinolaryngol Relat Spec 1993;55:30-5.

7. Hassid S, Decaestecker C, Hermans C, et al. Algorithm analysis of lectin glycohistochemistry and Feulgen cytometry for a new classification of nasal polyposis. Ann Otol Rhinol Laryngol 1997;106:1043-51.

8. Gabius HJ, Wosgien B, Brinck U, Schauer A. Localization of endogenous β-galactoside–specific lectins by neoglycoproteins, lectin-binding tissue glycoproteins and antibodies and of accessible lectin-specific ligands by mammalian lectin in human breast carcinomas. Pathol Res Pract 1991;187:839-47.

9. Hassid S, Salmon I, Brugmans M, et al. Histochemical study of epithelia of nasal polyps by biotinylated lectins and neoglycoproteins. A comparison with the normal respiratory epithelium. Eur J Morphol 1997;35:77-85.

10. Gabius HJ. Animal lectins. Eur J Biochem 1997;243: 543-76.

11. Schneller M, Andre S, Cihak J, et al. Differential binding of two chicken β-galactoside–specific lectins to homologous lymphocyte subpopulations and evidence for inhibitor activity of the dimeric lectin on stimulated T cells. Cell Immunol 1995;166:35-43.

12. Perillo NL, Pace KE, Seilhamer JJ, Baum LG. Apoptosis of T cells mediated by galectin-1. Nature 1995;378:736-9.

13. Yamaoka A, Kuwahara I, Frigeri LG, Liu FT. A human lectin, galectin-3 (εbp/Mac-2), stimulates superoxide production by neutrophils. J Immunol 1995;154:3479-87.

14. Yang RY, Hsu DK, Liu FT. Expression of galectin-3 modulates T-cell growth and apoptosis. Proc Natl Acad Sci U S A 1996;93:6737-42.

15. Dreborg S. Allergy diagnosis. In: Mygind N, Naclerio RM, eds. Allergic and non-allergic rhinitis. Clinical aspects. Copenhagen, Denmark: Munksgaard, 1993:82-4.

16. Solis D, Romero A, Kaltner H, Gabius HJ, Diaz-Maurino T. Different architecture of the combining site of the two chicken galectins revealed by chemical mapping studies with synthetic ligand derivatives. J Biol Chem 1996;271:12744-8.

17. Danguy A, Kayser K, Bovin NV, Gabius HJ. The relevance of neoglycoconjugates for histology and pathology. Trends Glycosci Glycotechnol 1995;7:261-75.

18. Goldschmidt D, Decaestecker C, Berthe JV, et al. The contribution of computer-assisted methods for histopathological classification of adipose tumors. Lab Invest 1996;75:295-306.

19. Johnson RA, Wicheren DW. Applied multivariate statistical analysis. 3rd ed. Englewood Cliffs, NJ: Prentice-Hall International Editions, 1992.

20. McLachlan GJ. Discriminant analysis and statistical pattern recognition. New York, NY: Wiley & Sons, 1992.

21. Drake-Lee AB. Nasal polyps. In: Mygind N, Naclerio RM, eds. Allergic and non-allergic rhinitis. Clinical aspects. Copenhagen, Denmark: Munksgaard, 1993:153-8.

22. Gabius HJ, Gabius S, eds. Glycosciences: status and perspectives. London, England: Chapman and Hall, 1997.

23. Hakomori S. Aberrant glycosylation in tumors and tumor-associated carbohydrate antigens. Adv Cancer Res 1989; 52:257-331.

24. Dabelsteen E. Cell surface carbohydrates as prognostic markers in human carcinomas. J Pathol 1996;179:358-69.

25. Jannot MC, Kruczynski A, Limouzy A, et al. Spontaneous evolution of cytoplasmic lectin binding and nuclear size and deoxyribonucleic acid content in human colorectal cancers grafted onto nude mice. Lab Invest 1993;68:446-55.

26. Kayser K, Bovin NV, Korchagina EY, Zeilinger C, Zeng FY, Gabius HJ. Correlation of expression of binding sites for the synthetic blood group A-, B-, and H-trisaccharides and for sarcolectin with survival of patients with bronchial carcinoma. Eur J Cancer 1994;30A:653-7.

27. Xu XC, El-Naggar AK, Lotan R. Differential expression of galectin-1 and galectin-3 in thyroid tumors. Potential diagnostic implications. Am J Pathol 1995;147:815-22.

28. Salmon I, Camby I, Remmelink M, et al. Lectin histochemistry, ploidy level and proliferation indices in meningioma subtypes. Neuropathol Appl Neurobiol 1996;22:68-76.

29. Roth J. Cellular sialoglycoconjugates: a histochemical perspective. Histochem J 1993;25:687-710.

30. Reuter G, Gabius HJ. Sialic acids: structure, analysis, metabolism, occurrence, recognition. Biol Chem Hoppe Seyler 1996;377:325-42.

31. Varki A. Sialic acids as ligands in recognition phenomena. FASEB J 1997;11:248-55.

32. Paulson JC, Colley KJ. Glycosyltransferases. Structure, localization and control of cell-type specific glycosylation. J Biol Chem 1989;264:17615-8.

33. Shibuya N, Goldstein IJ, Broekaert WF, Nsimba-Lubaki M, Peeters B, Peumans WJ. The elderberry (*Sambucus nigra*) bark lectin recognizes the Neu5Ac(α2,6)Gal/GalNAc sequence. J Biol Chem 1987;262:1596-601.

34. Wang WC, Cummings RD. The immobilized leukoagglutinin from the seeds of *Maackia amurensis* binds with high affinity to complex-type Asn-linked oligosaccharides containing terminal sialic acid-linked α2,3 to penultimate galactose residues. J Biol Chem 1988;263:4576-85.

35. Debray H, Decout D, Strecker G, Spik G, Montreuil J. Specificity of twelve lectins towards oligosaccharides and glycopeptides related to N-glycoproteins. Eur J Biochem 1981; 117:41-55.

36. Barondes SH, Castronovo V, Cooper DNW, et al. Galectins: a family of animal β-galactoside–binding lectins. Cell 1994;76:597-8.

37. Ohannesian DW, Lotan R. Galectins in tumor cells. In: Gabius HJ, Gabius S, eds. Glycosciences: status and perspectives. London, England: Chapman and Hall, 1997:459-69.

38. Kasai K, Hirabayashi J. Galectins: a family of animal lectins that decipher glycocodes. J Biochem (Tokyo) 1996;119: 1-8.

39. Hirabayashi J, ed. Recent topics on galectins. Trends Glycosci Glycotechnol 1997;9:1-179.

40. Kayser K, Kaltner H, Dong X, et al. Prognostic relevance of detection of ligands for vertebrate galectins and a Lewis^y-specific monoclonal antibody: a prospective study of bronchial carcinoma patients treated surgically. Int J Oncol 1996;9:893-900.

Ann Otol Rhinol Laryngol 108:1999

ESOPHAGEAL CONTRACTILITY SYNCHRONOUS WITH EXPIRATION

MITSUHIRO MOHRI, MD
NAOKI OHTSUKI, MD
MUTSUO AMATSU, MD
KOBE, JAPAN

On the basis of our previous finding that the cervical esophagus was closed during tracheoesophageal phonation, we postulated that the muscle of the cervical esophagus actually contracted during expiration and speculated on its possible regulation by the recurrent laryngeal nerve. Electromyography of the esophageal musculature and fluoroscopy of the esophagus were performed in laryngectomees to demonstrate whether the esophagus contracted during expiration or not. Electromyography, performed in 2 subjects, revealed a burst of discharges synchronous with expiration. Fluoroscopy during tracheoesophageal phonation was performed in 13 subjects to investigate the influence of resection of the esophageal branch of the recurrent nerve on esophageal motor activity. Among 13 subjects, 4 subjects who underwent paratracheal dissection (PTD) at the time of laryngectomy showed a lower superior limit of esophageal closure than did the 9 subjects without PTD, indicating that the cervical esophagus in PTD loses its contractility with the sacrifice of the esophageal branch of the recurrent nerve. We concluded that the cervical esophagus is closed by muscle contraction synchronous with expiration, preventing air entry into the stomach during deep expiration or phonation, and that the esophageal branch of the recurrent nerve is involved.

KEY WORDS — contraction, electromyography, esophagus, expiration, fluoroscopy.

INTRODUCTION

The main function of the esophagus is, needless to say, transport of food and liquids from the pharynx to the stomach. Although many studies have focused on the clarification of the mechanism of deglutition using manometric methods or electromyography (EMG),[1-5] less attention has been paid to esophageal movement during respiration.[1,2] In recent years, during fiberoptic examination of the esophagus, we have often observed closure and opening of the esophageal lumen occurring synchronously with the respiratory cycle. Such movement could represent either active contraction of the esophagus during respiration or passive movement following intrathoracic or tracheal pressure changes.

We previously reported closure of the cervical esophagus during phonation of the long vowel /a/ in patients using tracheoesophageal (TE) speech, a common technique for voice restoration after total laryngectomy.[6] The principle of TE phonation is to vibrate the pharyngeal mucosa at the neoglottis by the expiratory air diverted into the esophagus through a surgically constructed fistula between the trachea and the cervical esophagus.[7] The diverted air enlarges the subneoglottic lumen composed of the hypopharynx and the upper esophagus. Fiberoptic examination and fluoroscopy in that study revealed closure of the esophagus at the bottom of the ballooned subneoglottic lumen. Explaining this closure, we proposed that the normal cervical esophagus is closed during laryngeal phonation and that such motility is preserved after laryngectomy. The esophageal branch of the recurrent laryngeal nerve (RLN), which innervates the cervical esophagus, was assumed to regulate this closure.

It is well known that the upper third of the esophagus, including the cervical esophagus, is composed of striated muscle, while the lower two thirds is composed mainly of smooth muscle. The striated muscle part may play a functional role different from that of the smooth muscle part. Closure of the esophagus during TE phonation may depend on contraction of the striated muscle of the cervical esophagus during expiration, since TE phonation utilizes expiratory air. The purpose of this study is to clarify whether the muscle of the cervical esophagus contracts during expiration and which nerve is responsible.

SUBJECTS AND METHODS

This study protocol consisted of EMG of the musculature of the cervical esophagus during deep respiration, and fluoroscopy of the hypopharynx and esophagus during TE phonation. The EMG was performed to clarify whether the striated muscle of the cervical esophagus contracted during expiration. One man and 1 woman with temporary salivary fistulas after laryngectomy were studied by EMG after giving written informed consent. In both subjects, the pharynx and the cervical esophagus opened separately to the cervical skin. The equipment arrangement

From the Department of Otorhinolaryngology–Head and Neck Surgery, Kobe University School of Medicine, Kobe, Japan. This research was supported by a Grant-in-Aid for Scientific Research (C) from the Ministry of Education, Science and Culture, Japan (No. 07671855).

CORRESPONDENCE — Mitsuhiro Mohri, MD, Dept of Otorhinolaryngology–Head and Neck Surgery, Kobe University School of Medicine, 7-5-2 Kusunoki-cho, Chuo-ku, Kobe 650-0017, Japan.

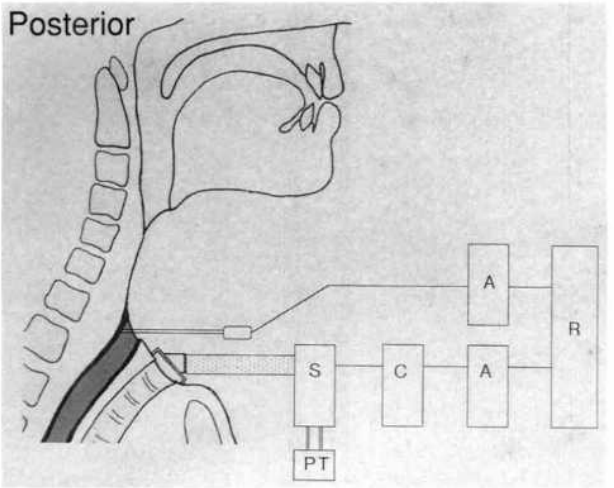

Fig 1. Apparatus for esophageal electromyography during respiration. PT — pressure transducer; S — sensor; C — control box; A — amplifier; R — recorder.

for data recording is shown in Fig 1. The tracheal opening was sealed by a Blom-Singer tracheostoma valve. A corrugated tube about 1 m long was interposed between the valve and a flow-rate measuring unit composed of a sensor (TV 112T, Nihon-Koden, Japan), a pressure transducer (TP 602T, Nihon-Koden), a control box (RY-111S, Nihon-Koden), and a respiratory amplifier (AR-601G, Nihon-Koden). A bipolar needle electrode was inserted through the fistulous opening into the striated muscle of the cervical esophagus under direct visualization. Subjects were instructed to take deep breaths. The EMG activity during respiration was amplified and recorded simultaneously with the flow rate curve.

Fluoroscopy was performed to investigate the influence of the resection of the esophageal branch of the RLN on esophageal motor activity. In cases of subglottic extension of laryngeal cancer, paratracheal dissection (PTD) is usually performed along with total laryngectomy. In cases with PTD, the RLN with its esophageal branch is usually sacrificed more extensively than in cases without PTD. Thus, paralysis of the cervical esophagus might be expected in PTD cases.

Fluoroscopically studied subjects included 12 men and 1 woman (all Japanese) with a mean age of 62 years who underwent total laryngectomy at Kobe University Hospital. Each subject underwent TE fistulization at the time of laryngectomy as described elsewhere.[7] Four of these 13 subjects underwent PTD at the time of laryngectomy, while 9 did not. In all subjects, healing occurred without complications. All subjects were examined over 6 months postoperatively, and they could converse well in TE speech without impediments. They were instructed to swallow a high-density barium solution to coat the lumen of the hypopharynx and the esophagus, and were instructed to phonate the long vowel /a/ during the examination. In each subject, a lateral radiograph obtained during phonation was evaluated to determine the location of the proximal limit of esophageal closure by level of vertebral body. The mean location of this limit was compared between groups with and without PTD.

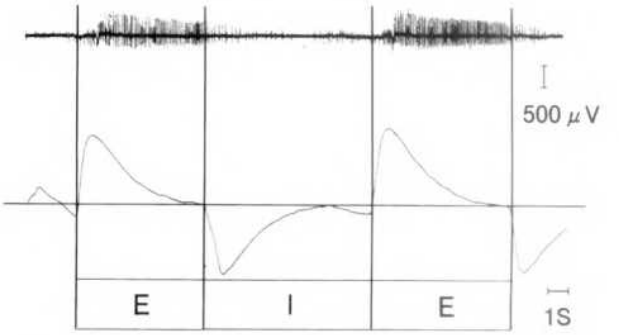

Fig 2. Electromyography during deep breathing. Note bursts of discharges synchronous with expirations. E — expiratory phase; I — inspiratory phase.

RESULTS

The EMG activity synchronous with expiration was recorded in both subjects (Fig 2). Closure of the esophageal lumen synchronous with expiration was clearly observed (Fig 3). This closure was entirely extrathoracic.

Fluoroscopy during TE phonation revealed variation in the superior limit of esophageal closure (Fig 4). These anatomic levels are diagrammed in Fig 5. A difference was apparent between patients with and without PTD. In those without PTD, the superior closure limit ranged from the level of the lower border of C6 to the center of T2, being most frequently seen at the lower border of C7. In the group with PTD, the superior closure limit ranged from the level of the lower border of T1 to the lower border of T3. The superior closure limit in the group with PTD was located more distally than in most patients without PTD.

DISCUSSION

The esophagus is a muscular tube transporting food from the pharynx to the stomach. While many radiographic, manometric, or EMG investigations have characterized the bolus transport function of the esophagus, few reports have mentioned respiratory effects on esophageal activity[2] or on deglutition.[1] Inouye[2] recorded action potentials synchronized with inspiration from the lower esophagus of dogs and cats, with no apparent respiratory effects in the middle and upper esophagus. He also reported contraction of the esophagus caused by electrical stimula-

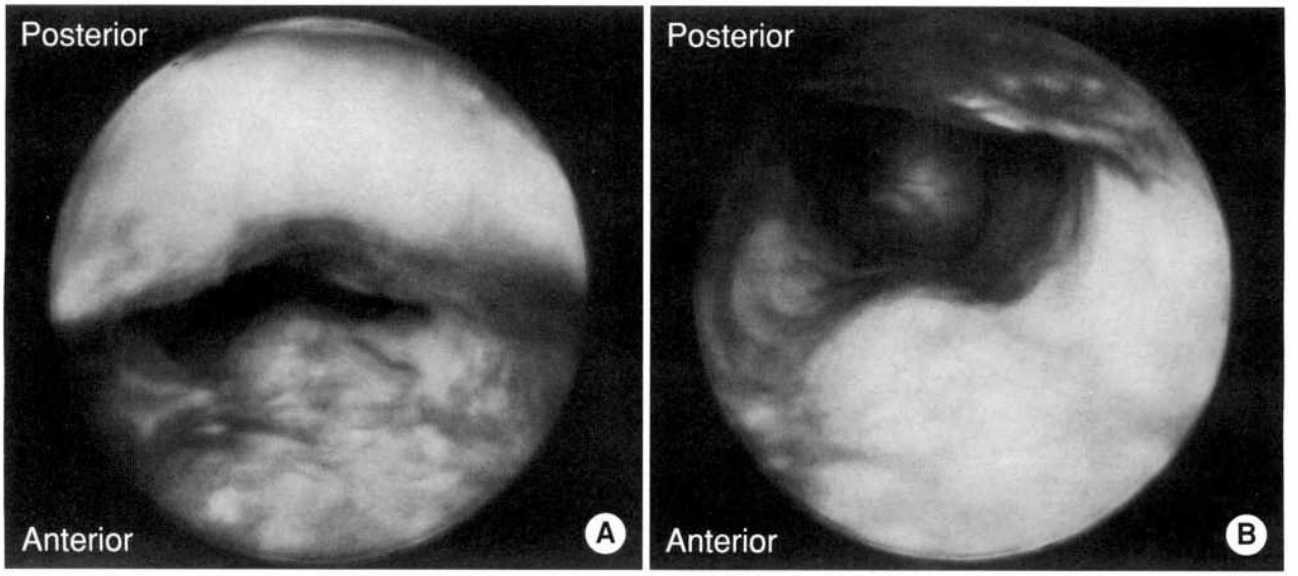

Fig 3. Concentric pattern of closure and opening of cervical esophagus seen through salivary fistula. A) Closure during expiration. B) Opening during inspiration.

tion of the vagus nerve.

In the present study, we recorded the discharges in striated muscle of the cervical esophagus occurring synchronously with expiration in 2 laryngectomees. This finding indicates that the cervical esophagus in humans contracts actively with expiration. Thus, the extrathoracic closure of the esophagus seen during expiration is not passive movement following intrathoracic pressure change, but derives from contraction of the esophageal muscle. The closure pattern of the esophagus suggests that the origin of this contraction may be the circular layer of the esophageal muscle. This closure pattern was nearly the same as the esophageal closure during TE phonation observed fiberoptically in our previous report.[6] The closure of the esophagus during TE phonation, then, derives from the contraction of the striated muscle of the esophagus during expiration.

The results of fluoroscopy indicate that PTD has considerable influence on the location of the superior limit of esophageal closure. This influence may be explained by the following considerations. In total laryngectomy, the esophageal branch of the RLN is sacrificed with the resection of the RLN. Resec-

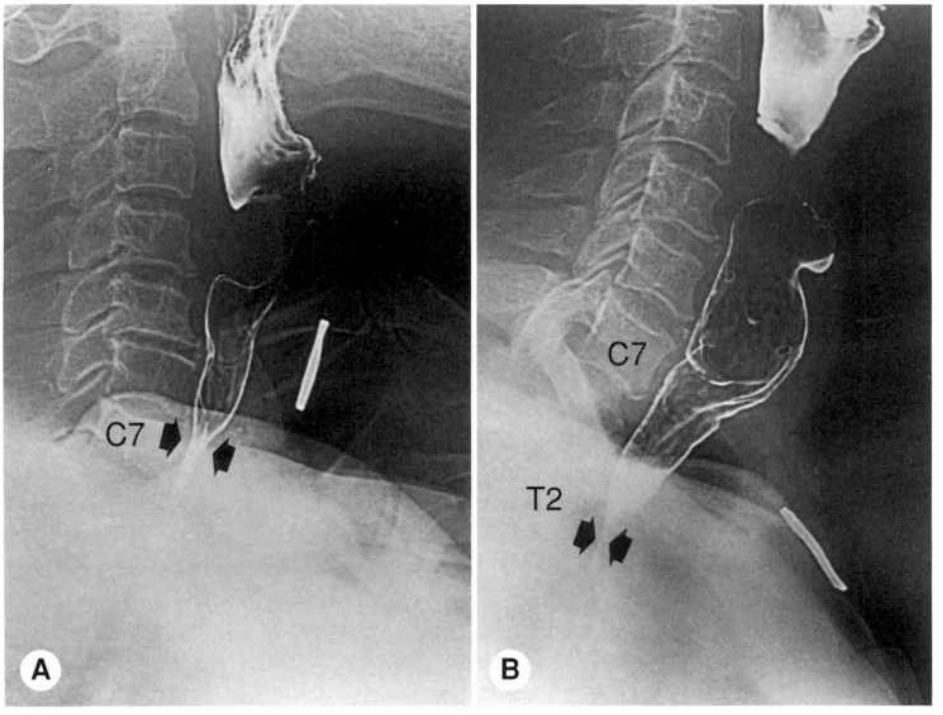

Fig 4. Various levels of superior limit of esophageal closure (arrows). A) Upper border of C7 in patient without paratracheal dissection. B) Middle of T2 in patient with paratracheal dissection.

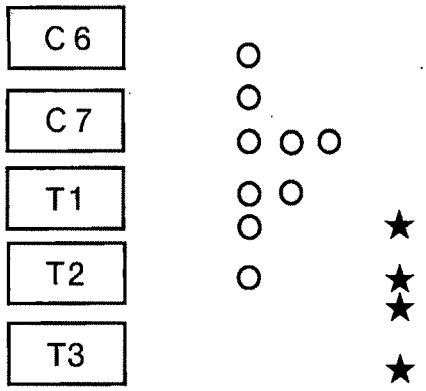

Fig 5. Histogram of upper border of closure of esophagus in all subjects without (circles) and with (stars) paratracheal dissection.

tion of the esophageal branch results in loss of contraction of the innervated portion of the cervical esophagus. The portion in which the innervation is intact preserves its contractility during expiration after surgery. Thus, during TE phonation, the denervated part of the esophagus is ballooned by expiratory air diverted into the esophageal lumen, while the intact part is closed by the contraction of the esophageal muscle. This ballooning sharply distinguishes the denervated portion from the innervated portion. The inferior limit of the ballooned portion shown by fluoroscopy is thought to represent the level of nerve resection. As described above, more extensive resection of the RLN in cases with PTD results in more sacrifice of the esophageal branch than in laryngectomy alone. Thus, in the subjects with PTD, these limits were located more inferiorly than in subjects without PTD.

Therefore, it may be concluded that contraction and closure of the cervical esophagus is regulated by the esophageal branch of the RLN.

Esophageal pressure has been measured for indirect determination of subglottic pressure,[8] since good correlation exists between the two pressures.[9] However, Ladefoged[9] noticed considerable differences in pressures recorded in different parts of the esophagus, especially toward the end of expiration. He mentioned a progressive increase of pressure in the upper esophagus as expiration proceeded, while the central portion did not show such a pressure change. Closure of the cervical esophagus caused by muscle contraction synchronized with expiration may account for the increased pressure. Absence of a pressure increase in the mid-esophagus suggests that contraction is restricted to the cervical portion. Thus, as mentioned above, the upper third of the esophagus, composed of striated muscle, is not the same functional unit as the lower two thirds, composed of smooth muscle.

The functions of the cricopharyngeus muscle, regarded as the main component of the upper esophageal sphincter, are to control passage of food and liquid down to the esophagus, to prevent reflux of fluid from the esophagus, and to prevent passage of air into the esophagus.[10] The physiological significance of contraction of the cervical esophageal muscle is believed to resemble the third of these functions. This protective mechanism, which remains intact after total laryngectomy, has proven important for effective TE phonation.

In esophageal speech, another major means for voice restoration, air is ingested and trapped in the esophagus and expelled into the oral cavity for phonation. The dynamics of the esophageal lumen in such phonation depend upon the contraction of the esophageal muscle. Since the esophageal voice is produced during the expiratory phase, such contraction presumably derives from the contraction that occurs in synchrony with expiration. Considering that esophageal speakers use less air for phonation than TE speakers, we conclude that expiratory esophageal contraction is probably more important for esophageal speech than for TE speech.

REFERENCES

1. Kawasaki M, Ogura JH, Takenouchi S. Neurophysiologic observations of normal deglutition. Its relationship to the respiratory cycle. Laryngoscope 1964;74:1747-65.

2. Inouye T. Electromyographic investigation of the esophagus in animals. Laryngoscope 1966;76:1502-18.

3. Shipp T, Deatsch WW, Robertson K. Pharyngoesophageal muscle activity during swallowing in man. Laryngoscope 1970;80:1-16.

4. Asoh R, Goyal RK. Manometry and electromyography of the upper esophageal sphincter in the opossum. Gastroenterology 1978;74:514-20.

5. Van Overbeek JJM, Wit HP, Paping RH, Segenhout HM. Simultaneous manometry and electromyography in the pharyngoesophageal segment. Laryngoscope 1985;95:582-4.

6. Mohri M, Kinishi M, Amatsu M. Dynamics of subneoglottic lumen in tracheoesophageal phonation. Ann Otol Rhinol Laryngol 1998;107:974-6.

7. Amatsu M, Makino K, Kinishi M, Tani M, Kokubu M. Primary tracheoesophageal shunt operation for postlaryngectomy speech with sphincter mechanism. Ann Otol Rhinol Laryngol 1986;95:373-6.

8. Van Den Berg JW. Direct and indirect determination of the mean subglottic pressure. Folia Phoniatr (Basel) 1956;8:1-24.

9. Ladefoged P. The regulation of subglottal pressure. Folia Phoniatr (Basel) 1960;12:169-75.

10. Carlborg BIR, Uddman R. Physiology of the esophagus. In: Cummings CW, Fredrickson JM, Harker LA, Krause CJ, Schuller DE, eds. Otolaryngology–head and neck surgery. 2nd ed. St Louis, Mo: Mosby–Year Book, 1993:2217-28.

ENDOSCOPIC DIVERTICULOTOMY FOR THE TREATMENT OF ZENKER'S DIVERTICULUM: RESULTS IN 102 PATIENTS WITH STAPLE-ASSISTED ENDOSCOPY

SURENDRA NARNE, MD
PADUA, ITALY

CESARE CUTRONE, MD
PADUA, ITALY

LUIGI BONAVINA, MD
MILAN, ITALY

BARBARA CHELLA, MD
MILAN, ITALY

ALBERTO PERACCHIA, MD
MILAN, ITALY

Endoscopic diverticulotomy for the treatment of Zenker's diverticulum has been reported infrequently in the literature and has engendered considerable controversy. Between March 1992 and September 1996, we attempted to treat 102 patients with endoscopic treatment for pharyngoesophageal diverticula. In 98 patients, the endoscopic surgery was successfully completed. Conversion to open surgery was required in 4 patients (3.92%). One cartridge of staples in 16 patients (16.32%), 2 cartridges in 78 patients (79.59%), and 3 cartridges in 4 patients (4.08%) were used, according to the size of the diverticulum; the median duration of the procedure was 20 minutes (10 to 60 minutes). No postoperative morbidity or mortality was recorded. Oral feeding was started following radiologic control after a median of 2 days; the median hospital stay was 4 days. The median follow-up is 16 months (1 to 45 months). Four patients operated on before the introduction of the modified stapler showed a persistent diverticular pouch: 3 underwent repeat endoscopic operation, and 1 underwent conventional open surgery. All treated patients are asymptomatic. Manometric study performed in 15 patients showed a significant reduction of basal upper esophageal sphincter pressure compared to preoperative data (48.30 ± 21.74 versus 29.38 ± 5.68 mm Hg; $p < .01$). We therefore recommend endoscopic diverticulotomy, considering that the procedure is relatively safe and effective, with minimal patient discomfort, and the results are equal to those of the external approach. This procedure offers the advantages of short hospitalization, rapid convalescence, brief operative time, absence of skin incision, predictable resolution of symptoms, and reduced morbidity.

KEY WORDS — endoscopic diverticulotomy, pharyngoesophageal diverticulum, Zenker's diverticulum.

INTRODUCTION

Zenker's diverticulum or pharyngoesophageal diverticulum is a mucosal pouch bulging from the posterior pharyngeal wall, between the fibers of the inferior constrictor and the cricopharyngeal muscles (Killian's triangle)[1] (Fig 1A). The roles of esophageal dysfunction (such as hypertonia, incoordination, or incomplete relaxation of the upper esophageal sphincter [UES]) and of anatomic defects (weakness of Killian's triangle and cricopharyngeal fibrosis) in the pathogenesis of Zenker's diverticulum are not completely understood. Surgery is indicated to relieve symptoms such as dysphagia and regurgitation and to prevent aspiration. Standard surgical treatment includes cricopharyngeal myotomy and diverticulectomy through cervicotomy,[2,3] although myotomy alone may be sufficient in small diverticula.[4] The endoscopic approach first proposed by Mosher[5] consists of division of the septum between the cervical esophagus and the pouch, thus allowing opening of the diverticulum into the esophageal lumen (esophagodiverticulotomy) and achieving partial section of the UES fibers. This operation has been performed with electrocoagulation or laser in several patients[6-9]; although reported results are satisfactory, potential complications such as bleeding, perforation, and mediastinitis limited its application in elderly and high-risk patients. Recent introduction of endoscopic stapling devices (introduced by Collard from Belgium) allowing tissue sealing and better hemostasis renewed the interest in endoscopic surgery for Zenker's diverticulum.[10-15] We report results of the transoral approach to pharyngoesophageal diverticulum with the use of an endoscopic stapler in 102 patients.

MATERIALS AND METHODS

Between March 1992 and September 1996, 102 patients with Zenker's diverticulum were treated at the Padua and Milan medical schools. There were 78 men and 24 women with a median age of 66 years (range 38 to 92 years), all complaining of dysphagia and food regurgitation. The preoperative workup in-

From the Emergency Endoscopic Service, University of Padua, Padua (Narne, Cutrone), and the Department of General Surgery and Surgical Oncology, University of Milan, Milan (Bonavina, Chella, Peracchia), Italy.

CORRESPONDENCE — Surendra Narne, MD, Emergency Endoscopic Service, Via Giustiniani 2, Azienda Ospedaliera di Padova, 35127 Padova, Italy.

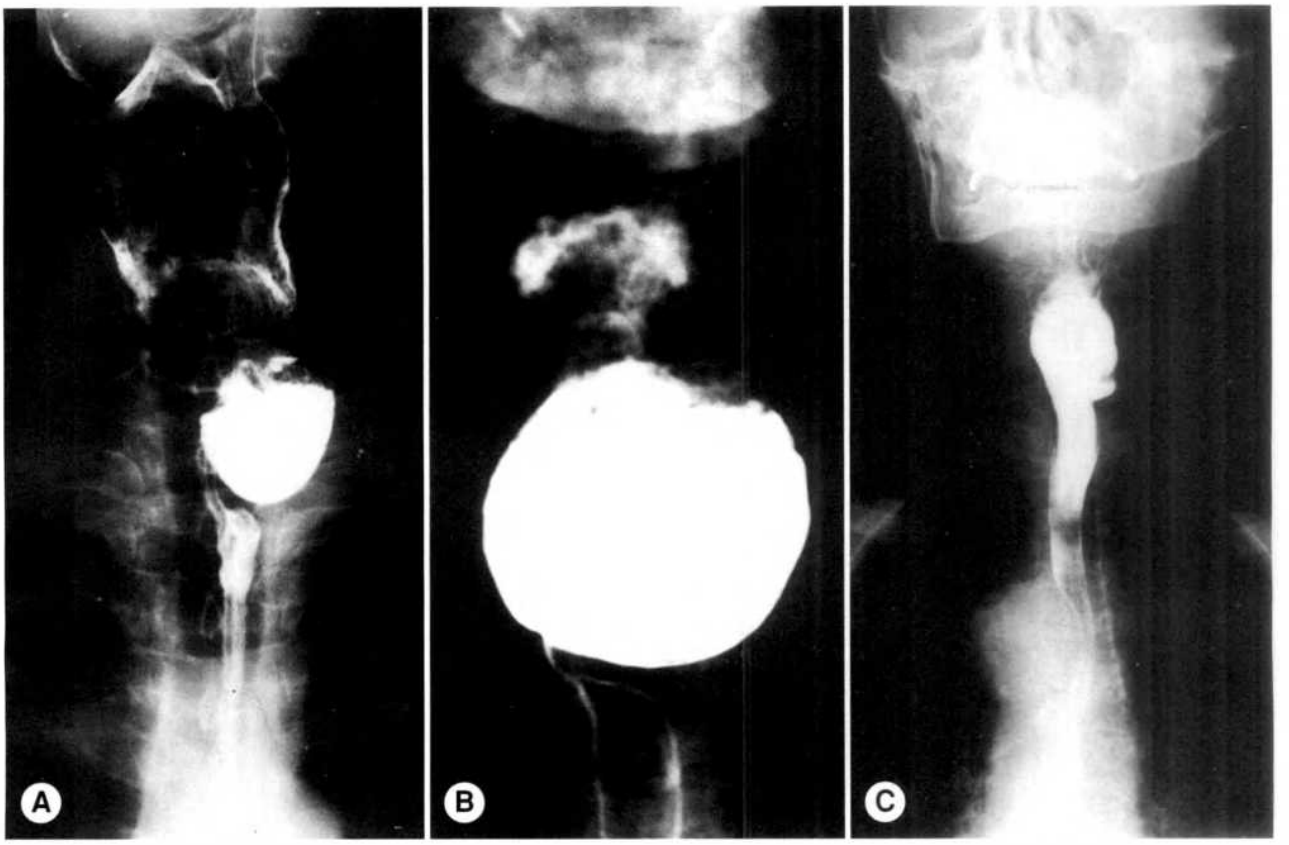

Fig 1. Radiographs. A) Pharyngoesophageal diverticulum in anterior view. B) Large diverticulum longer than 6 cm, contraindicating endoscopic treatment. C) Postoperative anterior view showing complete absence of diverticulum.

cluded barium swallow study, upper gastrointestinal tract endoscopy, and esophageal manometry in all cases. The median size of the diverticulum pouch measured by flexible or rigid endoscopy was 4.0 cm (range 2 to 8 cm). A radiologic study with water-soluble contrast was performed in all patients before resumption of oral feeding. Clinical evaluation was scheduled at 1 and 4 weeks from the operation and every 6 months thereafter. Fifteen patients underwent manometry during follow-up: the mean values of basal and residual UES pressure and mean UES length were compared to preoperative data. Student's *t*-test was used for statistical analysis.

The procedure is performed with the patient under general anesthesia with nasotracheal or orotracheal intubation. The patient is placed supine on the operating table with the neck hyperextended and the surgeon sitting behind the patient's head. The Weerda distending diverticuloscope (Karl Storz, Tuttlingen, Germany; Fig 2A,B) is introduced under direct vision into the oral cavity, allowing the double-lipped diverticuloscope to enter with the upper blade in the esophageal lumen and the lower blade in the diverticulum (Fig 3A). Visualization was increased by maximum expansion after insertion and optimum adaptation by 2 turn-screw mechanisms. Moving the lateral turn-screw lifts the lower blade in parallel from 18 mm to 30 mm, and abduction of the lower blade is performed by moving the frontal turn-screw. After clear visualization of the esophageal lumen, the diverticulum pouch, and the interposed septum, the diverticuloscope is fixed and held in place by means of a Benjamin-Parsons laryngoscope holder and chest support. A 4-mm wide-angle 0° telescope is inserted through the diverticuloscope, which is connected to a cold light source and to a Telecam Pal video camera in order to achieve magnified vision of the operative field on a video monitor placed at the patient's left side. The retained food material and saliva in the diverticular sac is suctioned and the mucosa is carefully inspected (Fig 4A). The depth of the diverticulum may be checked with a graduated rod (Fig 5). Esophagodiverticulostomy is performed with a modified disposable Endo-GIA 30 stapler (USSC, Norwalk, Conn) with a shorter anvil (Fig 2C), thus allowing tissue stapling and sectioning down to the bottom of the septum. The instrument blades are placed across the septum along the midline before "firing" (Fig 3B). Multiple applications may be necessary according to the size of the diverticulum. Straight endoscopic insulated scissors with slim jaws may be used to complete the section at the distal end of the staple line (Fig 4B). Finally, the suture line is checked

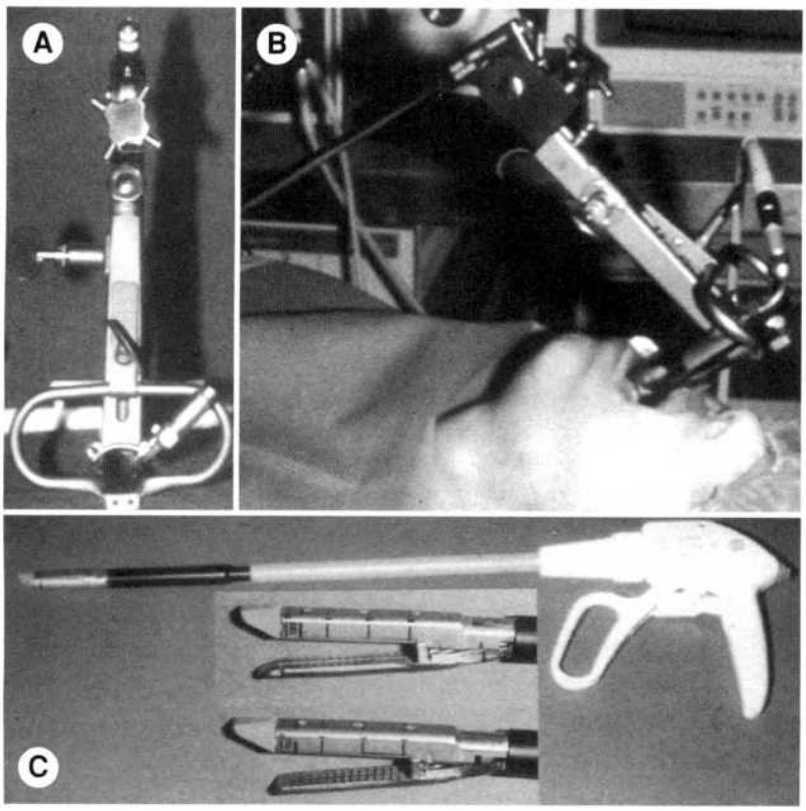

Fig 2. Instruments. A,B) Weerda distending diverticuloscope. A) Front view of endoscope. B) Correct position of endoscope introduced in oral cavity. C) Disposable Endo-GIA 30 stapler. Inset) At top is original anvil of distal end of disposable Endo-GIA 30; at bottom is modified distal end of stapler with part of anvil sawed off.

for hemostasis and the hypopharynx is irrigated with saline solution. The use of electrocautery is limited to a minimum: low voltage and the use of fully insulated instruments are mandatory. Positioning of a nasogastric tube at the end of the procedure is optional.

RESULTS

The procedure was successfully completed endoscopically in 98 patients out of 102 affected with Zenker's diverticulum, whereas conventional left cervicotomy was required in 4 patients: in 1 due to limited neck extension in an 85-year-old woman, in 1 due to persistence of the diverticular pouch after the second endoscopic attempt, and in 2 due to the occurrence of a mucosal tear during stapler insertion (1.96% conversion rate). One single application of the linear stapler was used in 16 patients (diverticula ranging between 2 and 2.5 cm), 2 applications were used in 78 patients, and 3 applications were used in 4 patients (larger diverticula). The median duration of the endoscopic procedure was 20 minutes (range 10 to 60 minutes). No postoperative morbidity or mortality was recorded. Analgesic medications were administered during the first 24 hours upon the patient's request. A nasogastric tube was left in place in the first 51 patients and removed after Gastrografin

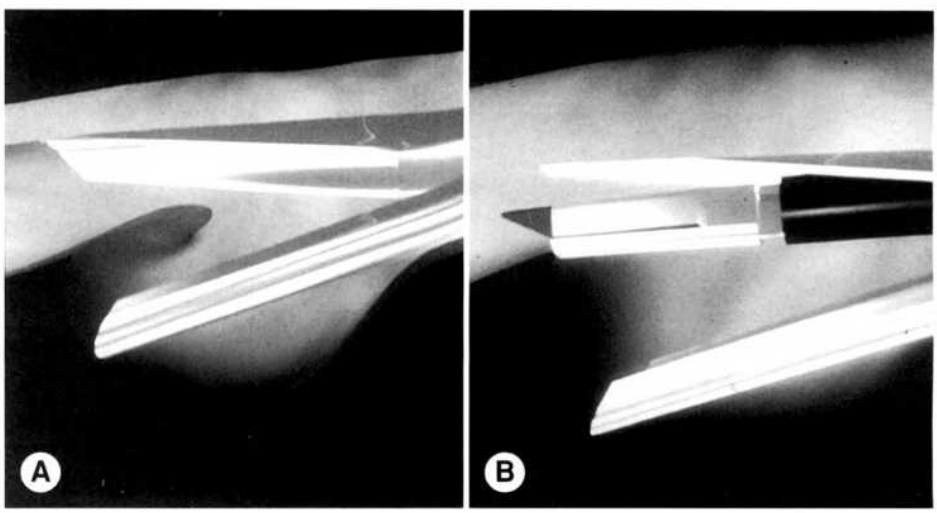

Fig 3. Schematic renderings of instrument positioning. A) Endoscopic position of diverticuloscope; upper blade is in esophageal lumen, and lower blade is in diverticulum. B) Correct position of modified Endo-GIA blades before esophagodiverticulostomy.

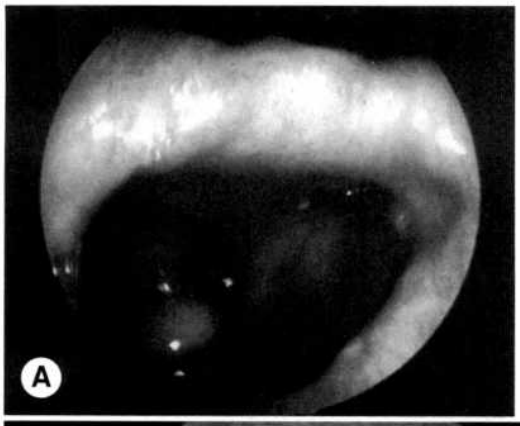

Fig 4. Endoscopic views. A) Diverticulum pouch and interposed septum. B) Section of distal end of staple line with straight endoscopic insulated scissors. C) After dividing cricopharyngeal muscle with Endo-GIA 30, triple line of staples ensures hemostasis of 2 wound edges.

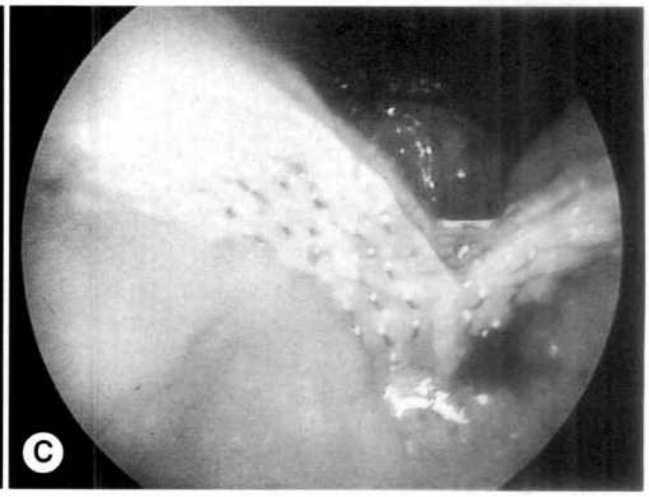

swallow after a median delay of 48 hours, and in the other 51 patients, a nasogastric tube was not positioned. A soft diet was resumed thereafter, and patients were discharged on the following day. The median postoperative hospital stay was 4 days.

All patients were asymptomatic after a median follow-up of 16 months (range 1 to 45 months). Four patients among those who were operated on before the introduction of the modified stapler had recurrent symptoms due to persistence of a small residual diverticular pouch; 3 of them underwent a second endoscopic treatment for completion of the esophagodiverticulotomy, and 1 eventually required open diverticulectomy and myotomy. Two patients required conversion to open surgery due to a mucosal tear that occurred during use of the endoscopic stapler. Postoperative radiologic study revealed free flow of the contrast medium through the pharyngoesophageal junction in all patients, despite evidence of a short spur between the diverticulum and the esophageal lumen in most lateral views. These results were confirmed by videofluorographic evaluation obtained in 5 patients. Four further patients underwent radionuclide study, showing that 50% of pharyngeal clearance was reached in a mean delay of 2.1 seconds. Comparison of manometric data in a group of 15 patients who underwent both preoperative and postoperative motility studies yielded the following results (mean ± SD): basal UES pressure, 48.30 ± 21.74 versus 29.38 ± 5.68 mm Hg ($p < .01$); residual UES pressure, 4.9 ± 3.41 versus 2.53 ± 3.23 mm Hg (not significant); and UES length, 2.37 ± 0.94 versus 1.91 ± 0.46 cm (not significant).

Fig 5. Graduated rod in diverticulum, measuring depth of pouch.

DISCUSSION

Physiological study of the pharyngoesophageal

junction indicates that normalization of the underlying motor disorder through cricopharyngeal myotomy is the main step in management of Zenker's diverticulum,[16,17] while excision of the pouch is indicated to prevent food retention and aspiration. The endoscopic approach fulfills these criteria, creating a common cavity and reducing the functional outflow obstruction, thus allowing free transit of the bolus into the esophageal lumen.[18,19] Expected advantages over open diverticulectomy include shorter operative time, absence of skin incision, minimal postoperative pain, quicker resumption of oral feeding, and shorter hospital stay. Complications such as bleeding, salivary fistula, vocal cord palsy, surgical emphysema, neck abscess, esophageal stenosis, and mediastinitis resulting from perforation have been reported with the standard surgical treatment, use of electrocoagulation, and laser.[18]

Endoscopic linear staplers represent an elegant solution to these potential risks.[20] At each "firing," the instrument places 2 triple staggered rows of titanium staples, achieving perfect hemostasis while the knife cuts between them; neither bleeding nor suture leakage occurred in our series (Fig 4C). The early postoperative outcome observed in these patients confirms improvement of the patient's comfort and a quicker recovery compared to myotomy and diverticulectomy performed through cervicotomy. Although this represents an advantage for elderly and compromised patients, it is not possible to perform the operation under simple local anesthesia.

Correct positioning of the diverticuloscope blades across the septum is essential. Reaching the bottom of the pouch may be difficult and hazardous in case of diverticula developing toward the left side of the esophagus, which should therefore be regarded as a relative contraindication to the endoscopic approach. Moreover, stapler manipulation may prove difficult in patients with limited mouth opening or reduced neck extension — often occurring in elderly patients. Two patients in our series required conversion to open surgery due to difficulties in stapler introduction, resulting in a mucosal tear. The operation was completed through a left cervicotomy, and the postoperative course was uneventful in both cases. Clinical and radiologic evaluation of the cervical spine is therefore recommended whenever osteoarthritis is suspected.

Diverticula smaller than 2 cm cannot be successfully treated with this method, because the section line is too short to allow division of the UES fibers. The length of the staple line is approximately 3 cm, and multiple applications may be required to complete esophagodiverticulotomy in cases of deeper diverticula. In fact, 2 cartridges were used in 79.59% of patients, and the median diverticulum size in our series was 4 cm. On the other hand, diverticula longer than 6 cm (Fig 1B) and large diverticula represent in our opinion a relative contraindication to endoscopic treatment, since the residual pharyngeal cavity may be too large to allow easy emptying upon swallowing.

The instrument anvil (which is pushed against the bottom of the diverticulum) is a few millimeters longer than the staple line; the distal part of the septum may thus be left intact, resulting in a residual spur responsible for persistent symptoms. This shortcoming, observed in 4 of our early cases, prompted us to modify the stapler by cutting off the distal end of the anvil in order to allow staple application to the very bottom of the diverticulum. Complete symptom relief was achieved in all patients operated on with the modified stapler. Postoperative radiologic evaluation often shows a small spur on lateral views, which may be misinterpreted as a persistent diverticulum by an inexperienced radiologist (Fig 1C). Such a finding has no clinical significance; in fact, videofluorographic and radionuclide studies confirm normal pharyngoesophageal clearance, and patients are asymptomatic. Comparison of manometric data obtained before and after endoscopic stapled esophagodiverticulostomy in 15 patients showed a significant reduction of basal UES pressure, confirming the effectiveness of cricopharyngeal myotomy performed endoscopically, as previously demonstrated in our laboratory.

In conclusion, early results achieved with endoscopic surgery for Zenker's diverticulum using a mechanical stapler are promising. The procedure seems to be relatively safe and effective and minimally invasive. The postoperative course is undoubtedly simplified, and the patient's comfort is greatly improved.

REFERENCES

1. Holinger PH, Johnston KC. Endoscopic surgery of Zenker's diverticula. Experience with the Dohlman technique. Ann Otol Rhinol Laryngol 1961;70:1117-23.

2. Grégorie J, Duranceau A. Surgical management of Zenker's diverticulum. Hepatogastroenterology 1992;39:32-8.

3. Payne WS. Treatment of pharyngo-oesophageal diverticulum: the simple and complex. Hepatogastroenterology 1992; 39:109-14.

4. Bonavina L, Khan NA, DeMeester TR. Pharyngo-esophageal dysfunctions. The role of cricopharyngeal dysfunction. Arch Surg 1985;120:541-9.

5. Mosher HP. Webs and pouches of the oesophagus, their diagnosis and treatment. Surg Gynecol Obstet 1917;25:175-87.

6. Benjamin B, Innocenti M. Laser treatment of pharyngeal

pouch. Aust N Z J Surg 1991;61:909-13.

7. Knegt PP, Jone PC, van der Schans EJ. Endoscopic treatment of the hypopharyngeal diverticulum with the CO_2 laser. Endoscopy 1985;17:205-6.

8. Kuhn FA, Bent JP. Zenker's diverticulotomy using the KTP/532 laser. Laryngoscope 1992;102:946-50.

9. Svendstrup F, Hansen LT, Petersen SV. CO_2 laser treatment of proximal pharyngo-esophageal diverticula (Zenker's diverticula). Ugeskr Laeger 1992;154:2418-20.

10. Collard JM, Otte JB, Kestens PJ. Endoscopic stapling technique of esophagodiverticulostomy for Zenker's diverticulum. Ann Thorac Surg 1993;56:573-6.

11. Narne S, Bonavina L, Guido E, Peracchia A. Treatment of Zenker's diverticulum by endoscopic stapling. Endosurgery 1993;1:118-20.

12. Peracchia A, Bonavina L, Narne S, Bona S, Pagani M, Venturi M. Physiological effects of video-assisted trans-oral stapling for Zenker's diverticulum: a prospective clinical study [Abstract]. Gastroenterology 1995;108(suppl 4):A189.

13. Ishioka S, Sakai P, Maluf Filho F, Melo JM. Endoscopic incision of Zenker's diverticula. Endoscopy 1995;27:433-7.

14. Spiro SA, Berg HM. Applying the endoscopic stapler in excision of Zenker's diverticulum: a solution for two intraoperative problems. Otolaryngol Head Neck Surg 1994;110:603-4.

15. Bonavina L, Bettineschi F, Fontebasso V, Ruol A, Nosadini A, Peracchia A. Cricopharyngeal myotomy and stapling: treatment of choice for Zenker's diverticulum. In: Nabeya K, Hanaoka T, Nogami H, eds. Recent advances in diseases of the oesophagus. Tokyo, Japan: Springer Verlag, 1993:207-11.

16. Scher RL, Richtsmeier WJ. Endoscopic staple-assisted esophagodiverticulostomy for Zenker's diverticulum. Laryngoscope 1996;106:951-6.

17. Fulp SR, Castell DO. Manometric aspects of Zenker's diverticulum. Hepatogastroenterology 1992;39:123-6.

18. Dohlman G, Mattson O. The endoscopic operation for hypopharyngeal diverticula. Arch Otolaryngol 1960;71:744-52.

19. van Overbeek JJM. Meditation on the pathogenesis of hypopharyngeal (Zenker's) diverticulum and a report of endoscopic treatment in 545 patients. Ann Otol Rhinol Laryngol 1994;103:178-85.

20. Dorion D, Brown DH, Gullane PJ. Zenker's stapler diverticulectomy. J Otolaryngol 1994;23:145-7.

PERIOCULAR REGION AND THE EYE: WHAT'S IMPORTANT FOR THE GENERAL OPHTHALMOLOGIST

Periocular Region and the Eye: What's Important for the General Ophthalmologist will be held in Toronto, Canada, December 3-4, 1999. For information, contact Continuing Education, Faculty of Medicine, University of Toronto, 150 College St, Room 121, Toronto, Ontario M5S 3E2, Canada; telephone (416) 978-2719; fax (416) 971-2200; e-mail audrea.martin@utoronto.ca; web site www.cme.utoronto.ca.

IMAGING CASE STUDY OF THE MONTH

HIGH-RESOLUTION MAGNETIC RESONANCE IMAGING OF RECURRENT PNEUMOPAROTITIS

CHRISTIAN SITTEL, MD
MARKUS JUNGEHÜLSING, MD
ROMAN FISCHBACH, MD
COLOGNE, GERMANY

INTRODUCTION

For the workup of patients with swelling of the parotid glands, several diagnostic imaging modalities are available. X-ray sialography, introduced in the 1920s,[1] is still the gold standard for demonstration of sialectasis, radiolucent calculi, duct strictures, and inflammatory diseases of the salivary gland duct system. However, in the last few decades, ultrasound and cross-sectional imaging techniques such as computed tomography and magnetic resonance imaging (MRI) have gained increasing importance in the clinical evaluation of such entities.

Magnetic resonance imaging reliably identifies parenchymal lesions in the salivary glands.[2,3] Recently, the diagnostic scope of MRI in salivary gland disease has been expanded by the introduction of magnetic resonance (MR) sialography, a noninvasive technique to visualize the parotid duct system. With a T2-weighted sequence and an exceptionally long echo time, images are produced in which almost all remaining image intensity originates from static or nearly static fluid with long T2 relaxation times. Human saliva in the duct system of the large salivary glands will be depicted as a bright structure, while signals originating from surrounding solid tissue have mostly decayed at these echo times. The technique is described elsewhere in detail.[4-6]

Pneumoparotitis results from increased intrabuccal pressure and insufflation of air through Stensen's duct. It may occur during dental instrumentation or general anesthesia and can be an occupational hazard among glassblowers and wind instrumentalists. Far more difficult in diagnosis is habitual autoinsufflation of the gland that may be encountered in adolescents, who often have psychological problems.

CASE REPORT

A 14-year-old girl presented to the otolaryngology service with a 3-year history of multiple episodes of sudden preauricular swelling. Acute exacerbation occurred at intervals of several weeks, with resolution of symptoms under oral antibiotics over the ensuing few days. On examination, both parotid glands were noted to be enlarged significantly, but did not show signs of inflammation at that time. In the oral cavity, frothy, air-filled saliva was exuding from the orifices of the left and right Stensen's ducts. Playing of a wind instrument was denied. On further questioning the girl complained of a constant itching in both external ear canals that had been unresponsive to treatment for years. On further careful questioning, the patient admitted to puffing her cheeks whenever the itching became unbearable. She claimed to get some relief from her discomfort by using this maneuver. After she had demonstrated the maneuver, pressure over the left parotid gland caused a flow of saliva mixed with many air bubbles from Stensen's duct.

High-Resolution Magnetic Resonance Imaging. The MRI examination was performed on a 1.0-T whole body MRI system (Gyroscan T10-NT; Philips, Best, the Netherlands) with a standard circular surface coil that had an inner diameter of 8 cm. The patient was examined in the supine position with the head positioned in a headrest. The surface coil was placed over the parotid region. After an axial survey scan, the morphology of the parotid gland was depicted with a T2-weighted fast spin echo sequence (TR/TE = 2,500 milliseconds [ms]/110 ms). Coronal and axial images with 22 sections of 3-mm slice thickness were obtained. The field of view was 90 × 72 mm, measured with a matrix of 256 × 144. With an echo train length of 13 and 4 signal averages, the total scan duration was 3 minutes 53 seconds. Figure 1 shows massive luminal widening of Stensen's duct between the parotid gland, masseter muscle, and buccal muscle. There is complete loss of signal in-

From the Departments of Otorhinolaryngology–Head and Neck Surgery (Sittel, Jungehülsing) and Diagnostic Radiology (Fischbach), University of Cologne, Cologne, Germany.
CORRESPONDENCE — Christian Sittel, MD, Universitäts-HNO-Klinik, J-Stelzmann-Straße 9, 50924 Cologne, Germany.

Fig 1. Axial magnetic resonance image (TE/TR = 110/2,500 milliseconds) of left parotid gland. Shows massive luminal widening of Stensen's duct (arrows) between parotid gland (1), masseter muscle (2), and buccal muscle (3). There is complete loss of signal inside parotid duct due to air insufflation. V — ventral, D — dorsal, L — lateral, A — anterior.

side the parotid duct due to air insufflation. The parotid gland shows a normal diameter and inner structure without insufflated air or typical signs for acute or chronic inflammation.

Magnetic Resonance Imaging Sialography. Following the acquisition of the axial and coronal morphologic images, a single 30-mm-thick oblique sagittal slab through the parotid gland, including the region of Stensen's duct, was obtained. A heavily T2-weighted fast spin echo sequence with a TR of 3,600 ms and a very long TE of 800 ms was used with a field of view of 120 × 96 mm, measured in a matrix of 512 × 287. Applying an echo train length of 77, the scan time was 4 minutes 51 seconds with 16 signal averages. A presaturation slab was positioned in the direction of the phase-encoding gradient to prevent fold-over.

Prior to MR sialography, the patient was asked to puff her cheeks repeatedly in order to provoke autoinsufflation. Figure 2 shows the subsequently performed MR sialography. Stensen's duct shows pronounced widening in its peripheral segment, and returns to normal diameter only at the first bifurcation. High signal intensity shows that the insufflated air has already been replaced by saliva. The image

Fig 2. Maximum-intensity projection (lateral image) of left Stensen's duct on magnetic resonance sialography. Orientation is comparable to that of conventional sialography. Shows pronounced widening of Stensen's duct in its peripheral segment (arrows) and normal diameter only at first bifurcation (1). High signal intensity shows that insufflated air has already been replaced by saliva. v — ventral, d — dorsal.

quality is restricted due to slight motion artifacts; nevertheless, primary and secondary branching ducts are clearly depicted, and segmental duct strictures and an irregular lumen width can be excluded.

Since thorough otoscopic examination revealed no sign of inflammation in the external ear canals, a referral for psychiatric counseling was suggested to the girl and her parents. This, however, was ultimately refused. She was advised to change her behavior, but was later lost to follow-up.

DISCUSSION

Pneumoparotitis is a rare cause of enlargement of the parotid gland that results from insufflation of air into the ductal system. It may be a transient phenomenon due to increase of intrabuccal pressure for different reasons (see Goguen et al[7] for an overview). Recurrent pneumoparotitis is highly suspect to be self-induced. It may be an unconscious habit or a deliberate attempt. A famous example of the latter is the case of several French Foreign Legion soldiers at the turn of the century who induced pneumoparotitis by blowing into a small bottle to avoid unwanted duty.[8] In adolescents the phenomenon is usually associated with psychosocial problems and may be seen as an expression of Munchausen syndrome.[9] Identification of the inciting maneuver, together with psychiatric therapy designed to curb the habit, is the treatment of choice. In our example, however, the patient did not comply.

High-resolution MRI using a surface coil and MR sialography, if available, can be a very helpful diag-

nostic tool in this group of patients, from our point of view. In contrast to x-ray sialography, it is absolutely painless, an advantage that should not be underestimated in patients with alleged psychiatric disorders. Duct cannulation, often difficult and potentially leading to duct stricture,[10] is unnecessary, and there is no injection of contrast agents. Further advantages of this new technique are the lack of radiation exposure and its feasibility even in the presence of acute inflammation of the gland, which is considered a contraindication for x-ray sialography. However, it must be admitted that a good-quality computed tomography scan would most likely render an accurate diagnosis of pneumoparotitis as well.

We conclude that high-resolution MRI combined with MR sialography is a valuable tool in the workup of suspected recurrent pneumoparotitis. The technique is free from side effects and can be performed with standard equipment. In combination with careful questioning of the patient, the often difficult diagnosis can be established definitively. Thus, unnecessary and potentially harmful diagnostic tests and incorrect treatment can be avoided.

REFERENCES

1. Arcelin L. Radiographie d'un calcul salivaire de la glande sublinguale. Lyon Med 1921;118:769-73.

2. Tabor EK, Curtin HD. MR of the salivary glands. Radiol Clin North Am 1989;27:379-92.

3. Vogl TJ, Dresel SH, Spath M, et al. Parotid gland: plain and gadolinium-enhanced MR imaging. Radiology 1990;177:667-74.

4. Fischbach R, Kugel H, Ernst S, et al. MR sialography: initial experience using a T2-weighted fast SE sequence. J Comput Assist Tomogr 1997;21:826-30.

5. Lomas DJ, Carroll NR, Johnson G, Antoun NM, Freer CE. MR sialography. Work in progress. Radiology 1996;200:129-33.

6. Treumann T, Lenz M. MR-Sialographie: erste Erfahrungen mit einer neuen Methode [MR-sialography: initial experiences with a new method]. Rontgenpraxis 1996;49:135-8.

7. Goguen LA, April MM, Karmody CS, Carter BL. Self-induced pneumoparotitis. Arch Otolaryngol Head Neck Surg 1995;121:1426-9.

8. Hemphill RA. Wind parotitis [Letter]. N Engl J Med 1973;289:1094-5.

9. Nassimbeni G, Ventura A, Boehm P, Guastalla P, Zocconi E. Self-induced pneumoparotitis. Clin Pediatr (Phila) 1995;34:160-2.

10. Kress E, Schulz HG, Neumann T. Die Diagnostik der Erkrankungen der großen Kopfspeicheldrüsen durch Sonographie, Sialographie und CT-Sialographie. Ein Methodenvergleich [Diagnosis of diseases of the large salivary glands of the head by ultrasound, sialography and CT-sialography. A comparison of methods]. HNO 1993;41:345-51.

INSTRUCTIONS TO AUTHORS

SUBMISSION

Send manuscripts to Editor Brian F. McCabe, MD, Department of Otolaryngology–Head and Neck Surgery, The University of Iowa Hospitals and Clinics, Iowa City, IA 52242. Original manuscripts dealing with clinical and scientific aspects of otolaryngology, bronchoesophagology, head and neck medicine and surgery, maxillofacial and plastic surgery, audiology, speech pathology, and related specialties are considered for publication. All materials submitted for publication undergo peer review. All manuscripts must be accompanied by a signed copyright transfer (see "Copyright," below).

Written permission from both senior author and publisher must be provided to the *Annals* in order to republish materials copyrighted elsewhere. Submit this permission with the manuscript.

Papers are scheduled for publication in chronologic order of acceptance. Manuscripts received in improper form require longer production time, which may delay publication. Manuscripts are edited in accordance with the *AMA Manual of Style*, 8th edition (1989), and with the *Uniform Requirements for Manuscripts Submitted to Biomedical Journals* (*Ann Intern Med* 1988;108:258-65).

MANUSCRIPT PREPARATION

Limit papers to a size that will make up to no more than six printed pages, figuring three double-spaced typewritten pages of text to one typeset page; see the journal for estimating space required for references, illustrations, and tables. If a manuscript of greater length is accepted for publication by the Editor, all typeset pages over six are charged to the author at the publisher's cost of $150 per page. Submit an original and two copies of the manuscript, typed on white bond paper with margins of at least 25 mm (1 in), double-spaced throughout, including abstract, references, tables, and legends. Use a type size no smaller than 10 points, preferably 12. Begin each component on a new page in the following sequence: title page, abstract, text, acknowledgments, references, tables, and figure legends. Number pages consecutively in the upper right corner, beginning with the title page. Avoid the use of staples.

The author is responsible for all statements in the paper, as approved on the copyedited galley proofs. Alterations made by the author after the paper has been typeset are charged to the author.

Use standard abbreviations given in *Uniform Requirements*. Express all measurements in metric terms; if original measurements were made in another system, include these parenthetically. Plot audiograms according to ISO standards. Use generic names whenever possible.

Title page must include 1) a concise but informative title, worded to facilitate indexing; 2) an abbreviated form of the title to be used as a running head; 3) authors' full names (no more than seven authors are permitted) and no more than two academic degrees per author; 4) department(s) and institution(s) to which the work is attributed, with authors' present affiliations and addresses, if different, separately noted; 5) statement of grant or other support; 6) name and address of author to whom reprint requests should be sent; and 7) name, address, and telephone and fax numbers of corresponding author. Manuscripts that report animal research performed in the United States must carry the following statement on the title page: "This study was performed in accordance with the PHS Policy on Humane Care and Use of Laboratory Animals, the NIH *Guide for the Care and Use of Laboratory Animals*, and the Animal Welfare Act (7 U.S.C. et seq.); the animal use protocol was approved by the Institutional Animal Care and Use Committee (IACUC) of _____ University (or institution)."

Abstracts contain no more than 150 words and state the goal of the study, primary procedures, main findings, and principal conclusions.

Key Words, chosen as far as possible from the National Library of Medicine *Medical Subject Headings*, are listed after the abstract.

References, double-spaced, are numbered consecutively in the order in which they are cited in the text. Primary references should be used whenever possible. The author is charged $1.50 for each reference over 30. Use the style of references given in *Uniform Requirements* or a current issue of the *Annals*. In-

clude the names of all authors and the inclusive page numbers of an article. If a manuscript accepted but not yet published is included in the reference list, give the accepting journal's name, followed by "in press." Manuscripts still in review or not yet accepted formally are cited within the text as "unpublished observations." A reference to a personal communication is also placed in the text, accompanied by a date (year). Papers presented at scholarly meetings but not published are considered "unpublished observations." Papers published only in abstract form are listed as references with "[Abstract]" after the title.

Tables should be on separate sheets, numbered consecutively and headed by a concise title. Put explanatory matter in footnotes. Tables are adjuncts to the text and should not repeat material presented therein. The cost of typesetting tables is billed to the author.

Illustrations must be submitted in three complete sets, unmounted. Only professional-quality glossy photographs and black and white line drawings are acceptable. Computer-generated graphs are acceptable only if they are clear and will reproduce well. Letters, numbers, and symbols should be clear and of uniform size throughout, large enough that each item is legible when reduced for publication. Put legends (detailed explanations) to the photographs on a separate page in the manuscript. Affix a label to the reverse side of each illustration indicating figure number, first author's name, and top of the figure. For radiographs, photomicrographs, CT scans, etc, give indications for maximum cropping and labeling on an overlay or photocopy. Cite each figure in the text in consecutive order. Written permission from identifiable subjects is required. The cost of preparing illustrations for publication (sizing to fit journal, and preparation of negatives for printing) is charged to the author without exception. Color illustrations are accepted; cost estimates for color separations and printing are provided on an individual basis. Illustrations should enhance, not repeat, material presented in the manuscript, and should be kept to a minimum.

MANUSCRIPTS ON SOFTWARE REVIEW AND COMPUTER APPLICATIONS

Programs submitted for review must be compatible with an IBM or Macintosh computer, and the author must specify hardware and system requirements. The following operating systems will be supported: MS-DOS; MS-DOS with Windows; and MAC-OS. Submit the software on either a 3.5" or 5.25" disk. If the program is a template, submit also a runtime version of the source program. Software considered for review includes educational software, artificial intelligence software to aid in the diagnosis of otolaryngic disorders, software for logging operations, software to aid in research, and software that addresses specific problems in otolaryngology. Also, manuscripts reviewing software and computer applications relating directly to otolaryngology are considered for publication. See *Ann Otol Rhinol Laryngol* 1991; 100:876 for specific instructions.

SUPPLEMENTS

A manuscript too long for inclusion in the *Annals* (over 12 typeset pages) may be published as a supplement if approved by the Editor. All costs are borne by the author and estimates are provided upon request. Supplements have the advantages of separate identification and rapid publication, but undergo the same critical review as journal articles.

REPRINTS

Rates are quoted when galley proofs are sent to the author. Orders are signed by the author and returned with the proofs.

COPYRIGHT

The following statements should accompany the manuscript, signed by all authors: 1) "This paper has not been published or submitted for publication elsewhere, other than as stated in a separate letter to the Editor." 2) [*For papers with more than one author*] "I have contributed substantively to the development of the content of this paper and have agreed to have my name listed as an author in the final, revised version." 3) "In consideration of the *Annals of Otology, Rhinology & Laryngology* taking action in reviewing and editing my (our) submission, I hereby transfer, assign, or otherwise convey all copyright ownership to the Annals Publishing Company in the event such work is published in the *Annals of Otology, Rhinology & Laryngology*."